



Pan African Urological Surgeons' Association

African Journal of Urology

[www.ees.elsevier.com/afju](http://www.ees.elsevier.com/afju)  
[www.sciencedirect.com](http://www.sciencedirect.com)



Original article

# Incised plate urethroplasty in perineal and perineo-scrotal hypospadias



A. Bhat<sup>a,\*</sup>, M. Singla<sup>a</sup>, M. Bhat<sup>b</sup>, K. Sabharwal<sup>a</sup>, R. Upadhaya<sup>a</sup>,  
V. Kumar<sup>a</sup>

<sup>a</sup> Department of Urology, S.P. Medical College, Bikaner, Rajasthan 334003, India

<sup>b</sup> Department of Preventive and Social Medicine, S.P. Medical College, Bikaner, Rajasthan 334003, India

Received 2 May 2014; received in revised form 2 October 2014; accepted 3 December 2014

## KEYWORDS

Congenital anomaly;  
Perineal hypospadias;  
Urethroplasty;  
Tubularized incised plate  
urethroplasty;  
Chordee;  
Mobilization of urethral  
plate and urethra;  
Spongioplasty  
preputioplasty

## Abstract

**Objective:** The ideal replacement of the urethra is the urethra itself. However, when the urethra is not available, flaps or tubes are used as substitutes in hypospadias repair. The urethral plate, when preserved, is an excellent tool for tubularization and urethral reconstruction. Tubularized incise plate (TIP) repair has become increasingly popular for the treatment of proximal hypospadias, with encouraging results. The objective of this study was to assess the feasibility and results of TIP in perineal and perineo-scrotal hypospadias.

**Subjects and methods:** Out of a total of 262 hypospadias cases treated at our clinic between January 2006 and June 2010, 35 patients had perineal and perineo-scrotal hypospadias. Of these, 21 cases with a narrow and/or poorly developed urethral plate and residual curvature after penile degloving and urethral mobilization underwent hypospadias repair using proximal TIP combined with a distal Duckett tube made from the inner prepuce after transection of the urethral plate at the corona. The present study was conducted on the remaining 14 cases treated with TIP alone. We retrospectively reviewed their case sheets, operative photographs and videos. Chordee was corrected by penile degloving and mobilization of the urethral plate with the corpus spongiosum, followed by proximal urethral mobilization with or without single-stitch dorsal plication. After incision of the urethral plate and tubularization, the neourethra was covered with a dorsal dartos/tunica flap. Two glanular wings were raised for glanuloplasty. Scrotoplasty was performed to cover the proximal urethra.

\* Corresponding author.

E-mail addresses: [amilalbhat@rediffmail.com](mailto:amilalbhat@rediffmail.com), [bhatamilal@gmail.com](mailto:bhatamilal@gmail.com) (A. Bhat), [drmanishsingla@gmail.com](mailto:drmanishsingla@gmail.com) (M. Singla), [mahak199027@gmail.com](mailto:mahak199027@gmail.com) (M. Bhat), [drkvsabharwal@gmail.com](mailto:drkvsabharwal@gmail.com) (K. Sabharwal), [surgeon.ups@gmail.com](mailto:surgeon.ups@gmail.com) (R. Upadhaya), [vinaysinghkgmc99@gmail.com](mailto:vinaysinghkgmc99@gmail.com) (V. Kumar).

Peer review under responsibility of Pan African Urological Surgeons' Association.

<http://dx.doi.org/10.1016/j.afju.2014.12.003>

1110-5704/© 2015 Pan African Urological Surgeons' Association. Production and hosting by Elsevier B.V. All rights reserved.

**Results:** The patients' age ranged from 1 to 23 (mean 13) years. Of the 14 cases studied, 4 had perineo-scrotal and 10 perineal hypospadias. Correction of the curvature was possible by penile degloving and urethral plate mobilization in 12 patients, while two required single-stitch dorsal plication. The length of the urethral plate varied from 5 to 16 (average 9) cm. The neourethra was covered with a dorsal dartos flap in nine and with a tunica vaginalis flap in six cases. None of the patients had residual curvature or stricture. Two patients developed a fistula which required re-do surgery.

**Conclusions:** Tubularized incised plate urethroplasty is an effective method for the repair of perineal and perineo-scrotal hypospadias with an acceptable complication rate.

© 2015 Pan African Urological Surgeons' Association. Production and hosting by Elsevier B.V. All rights reserved.

## Introduction

Single-stage surgical reconstruction of distal penile hypospadias is the technique of choice for managing anterior hypospadias. But applying the same principle to proximal or more severe hypospadias is difficult. In fact, there is hardly any consensus among urologists as to whether a single- or multi-stage operation is indicated in such cases. Tubularized incised plate (TIP) urethroplasty is the method of choice for all kinds of hypospadias repair, either alone or in combination with other techniques [1]. The use of TIP repair for distal or midshaft hypospadias has been well established with good results. This has encouraged urologists to attempt TIP urethroplasty in proximal penile hypospadias, also with satisfactory results [2,3]. Traditionally, the methods of choice for perineal and perineo-scrotal hypospadias repair have been double island flap urethroplasty or two-stage procedures, the use of an inner preputial flap, and Koyanagi repair [4]. Complications are higher in all methods using tubes as compared to flaps and TIP [5]. Though TIP repair is the method of choice for distal hypospadias repair, its application in penoscrotal or perineal hypospadias repair remains controversial, and only few reports with small numbers of patients have been published in the literature so far [6–8]. During the study period we treated 35 patients with perineal and perineo-scrotal hypospadias, but only 14 qualified for TIP urethroplasty. The objective of this study was to evaluate the feasibility and results of TIP urethroplasty in perineal and perineo-scrotal hypospadias.

## Subjects and methods

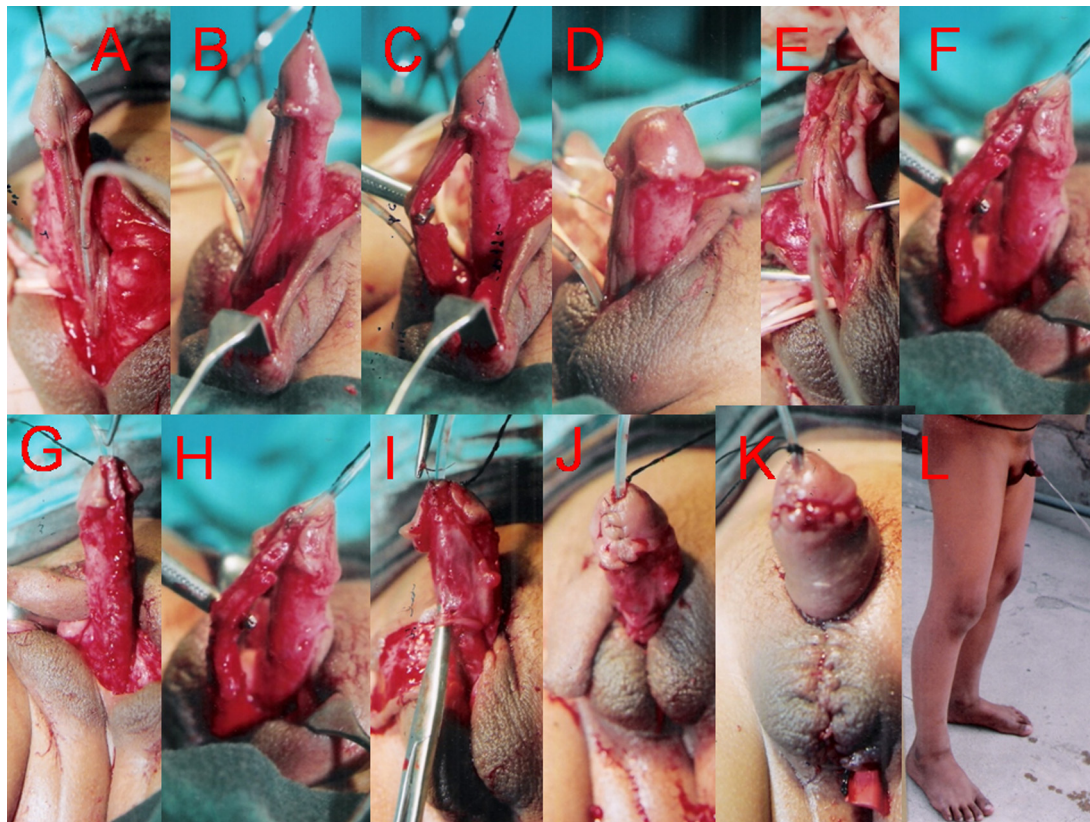
Out of a total of 262 hypospadias cases treated at our clinic between January 2006 and June 2010, 35 patients had perineal and perineo-scrotal hypospadias. Of these, 21 cases with a narrow and/or poorly developed urethral plate and residual curvature after penile degloving and urethral mobilization underwent hypospadias repair using proximal TIP combined with a distal Duckett tube made from the inner prepuce after transection of the urethral plate at the corona. The present retrospective study was conducted on the remaining 14 cases treated with TIP alone. In all cases, surgery was performed by the same surgeon (ALB). Only patients with a wide and well developed urethral plate and a good spongiosum, in whom curvature could be corrected with preservation of the urethral plate, and who had had at least three follow-up examinations were included in the study. Their case sheets, operative photographs and videos were evaluated for the patients' age, the site of the meatus, the severity of chordee, associated anomalies, the duration of follow-up and post-operative complications such as meatal stenosis, wound infection, hematoma, residual chordee, torsion and fistula.

## Surgical technique

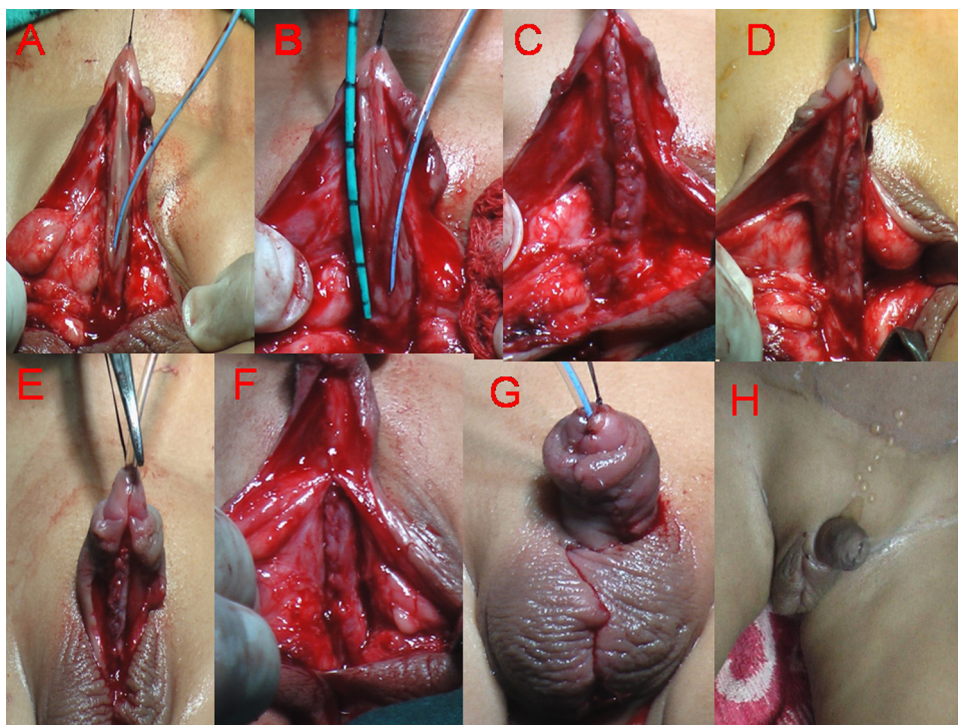
A stay suture was placed in the dorsal glans to aid in traction of the phallus and to fix the urethral stent later. An inverted U-shaped incision encircling the meatus and preserving the urethral plate was extended circumferentially around the corona. Penile degloving was done down to the root of the penis (Fig. 1A) to correct chordee. Then, the chordee was evaluated using the Gittes test (Fig. 1B). After creating a plane, the urethral plate and corpus spongiosum were mobilized (Fig. 1C) starting just proximal to the meatus. When chordee persisted, single-stitch dorsal plication was done. Glanular chordee was corrected by mobilizing the urethral plate into the glans, followed by the Gittes test to assess the final chordee correction. The urethra was calibrated with the largest possible urethral size catheter in order to tubularize the urethral plate. After placing a deep midline incision, taking care not to cut through the urethral plate (Fig. 1E), the urethral plate was tubularized using 7/0 PDS continuous sutures, irrespective of the patient's age (Figs. 1D, E and 2C). Spongioplasty and glansplasty (Figs. 1G and 2D) were carried out using 6/0 Vicryl interrupted sutures to complete urethroplasty. The neourethra was covered with a dorsal dartos flap in cases without preputioplasty (Figs. 1F and 2E) or with a tunica vaginalis flap. A 6–10 Fr urethral catheter (infant feeding tube), smaller than the catheter over which the urethral plate was tubularized (depending on the patient's age), was left in situ. Scrotoplasty (Figs. 1H and 2F) was done to cover the proximal urethra. Depending on the patients' or parents' wish, preputioplasty was performed, provided there was sufficient preputial tissue left. All patients received a compression dressing. The urethral catheter was removed between the 10th and 14th postoperative day. Follow-up was done at 1, 3, 6 and 12 months postoperatively, and then yearly for the assessment of the cosmetic appearance and possible development of fistula, meatal stenosis or other complication. At each visit the patients were asked to void in order to visualize the stream and to make sure that there was no leakage or stream from other sites than the meatus (suggestive of a fistula). In addition, the urethra was calibrated to check for urethral stricture and meatal stenosis.

## Results

The patients' age ranged from 1 to 23 (mean 13) years. Of the 14 cases studied, 4 had perineo-scrotal and 10 perineal hypospadias. Other associated anomalies were undescended testis and inguinal hernia in 1 patient each. None of the patients had received preoperative hormone therapy. The degree of chordee varied from moderate to severe (30–70°). Correction of the curvature was possible by

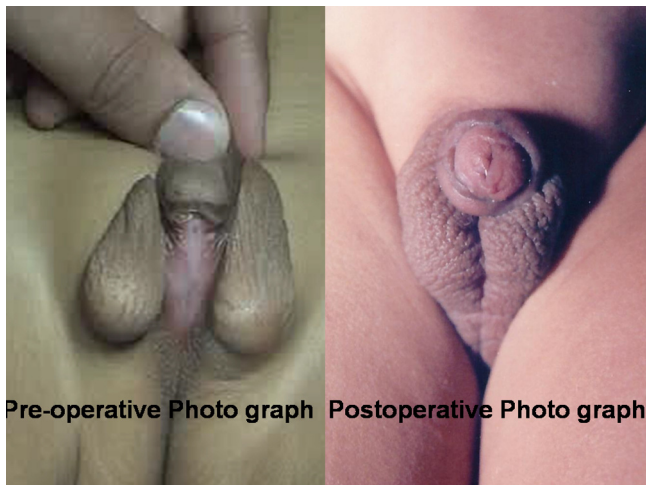


**Figure 1** Steps of tubularized incised plate urethroplasty in perineal hypospadias. (A) Penile degloving. (B and C) Mobilization of the urethral plate with the corpus spongiosum. (D) Gittes test showing correction of the chordee. (E) Incision of the urethral plate. (F) Tubularization of the urethral plate. (G and H) Spongioplasty. (I) Coverage of the neo-urethra with a dorsal dartos flap. (J) Glanuloplasty. (K) Skin closure. (L) Patient projecting the urinary stream from the tip postoperatively.



**Figure 2** Steps of tubularized incised plate urethroplasty with preputioplasty in perineo-scrotal hypospadias. (A and B) Penile degloving and mobilization of the urethral plate. (C) Tubularization of the urethral plate. (D) Spongioplasty. (E) Glanuloplasty. (F) Coverage of the neo-urethra with a ventral dartos flap. (G) Skin closure and preputioplasty. (H) Patient projecting the urinary stream from the tip postoperatively.





**Figure 3** Preoperative and postoperative aspects.

penile degloving and urethral plate mobilization in 12 patients, while two required single-stitch dorsal plication with ventral corporotomy at the point of maximum curvature. The length of the urethral plate varied from 5 to 16 (average 9) cm (Fig. 2A and B). After spongioplasty, the neourethra was covered with a dorsal dartos flap in nine and with a tunica vaginalis flap in three cases. According to the patients' or their parents' wish, preputioplasty (Fig. 2G) was done in four patients in whom the tunica vaginalis was used to cover the neourethra. Preputioplasty did not affect the complication rate in our series. During the follow-up period, none of the patients had residual curvature, torsion or spraying or dribbling urine (Figs. 1I and 2G). The urethral stent was kept for 10–14 days. Two patients (14.28%) developed a fistula which required redo surgery. One patient (7.1%) had a meatal stenosis which responded to meatal dilation. Follow-up varied from 18 to 60 (mean 30) months. Although we did not apply the HOSE (hypospadias objective scoring evaluation) score for postoperative results, the cosmetic outcome was very good as shown in Fig. 3.

## Discussion

Regarding the management of perineal hypospadias, there is some controversy as to whether single-stage or multi-stage repair should be preferred. Traditionally, two-stage repair has been advocated in patients with severe hypospadias because it allows for an effective correction of chordee and a nearly normal phallic cosmetic appearance with a low complication rate [9]. Staged repair methods entail the use of either flaps or grafts (skin or buccal mucosa) after division of the urethral plate with excision of the hypoplastic ventral structures in the first stage, followed by urethroplasty in the second stage [10]. The disadvantages of the multi-stage procedure lie in the fact that the child is exposed to more surgeries, leading to an increased risk of anesthesia-related morbidity and higher costs, along with problems encountered with graft take, donor site morbidity and voiding and ejaculatory problems due to the lack of spongiosum support [11].

Gershbaum et al. who performed two-stage repair using a dermal graft in 11 patients with perineo-scrotal hypospadias reported a complication rate of 18%. After the planned stage-two intervention, seven (63%) children were able to void with a normal stream,

while four (37%) had difficulties with terminal voiding and spraying [12].

In another study, Moursy compared the results of TIP urethroplasty, onlay island flap (OIF) urethroplasty and two-stage repair in patients with proximal penile (98), penoscrotal (64), scrotal (30) and perineal (2) hypospadias. He reported complication rates of 13.6%, 14% and 15% for TIP repair, onlay flap and two-stage repair, respectively. Complications were significantly higher in patients with scrotal and perineal hypospadias [13].

Similarly, Aseem et al. [14] operated on 10 children with penoscrotal or scrotal hypospadias using two-stage repair which consisted of mobilizing the skin to the ventrum of the penis in a first stage, followed by urethroplasty 6–12 months later. After a mean follow-up of 41.5 months, seven patients encountered complications: all of them developed fistula, three presented with meatal stenosis and one with a urethral diverticulum.

These results show that complication rates after multi-stage procedures vary greatly (15–70%).

The advantage of single-stage repair is the fact that the surgeon works in a virgin tissue plane, obviating the need for multi-stage repair and, thus, decreasing the costs and the risk of anesthesia-related morbidity, which offers a certain convenience to the patient, parents and surgeon [13], likewise. The overall complication rate of single-stage flap urethroplasty procedures has been reported to vary from 20% to 61.5% [9,15–18]. Macedo et al. [17] reported a complication rate of 37% (4 meatal stenoses, 4 diverticula, 5 fistulae and 2 residual penile curvatures) and a re-operation rate of 31.5% when using a one-stage repair concept he calls “three-in-one” technique (reconstruction of the urethral plate with buccal mucosa graft and onlay transverse preputial flap anastomosis protected by a tunica vaginalis flap) in patients with primary scrotal (21), penoscrotal (10) and perineal hypospadias (4). Emir et al. [9] reported a complication rate of 20% (mainly fistulae) using a modified Koyanagi procedure in 20 patients with primary proximal to penoscrotal hypospadias. Similarly, De Mattos e Silva et al. [18] compared the outcomes of three different urethroplasty techniques (onlay (133), buccal mucosa (25), Koyanagi type I (26)) for the reconstruction of severe hypospadias. They encountered complications, mainly fistulae, dehiscence, stricture and urethrocele, in 38 cases (28.5%) with onlay urethroplasty, in 14 (56%) cases with buccal mucosa graft and in 16 cases (61.5%) managed with Koyanagi urethroplasty.

When the urethral plate is wide and well developed, the spongiosum is well developed as well, and ventral curvature can be corrected without transecting the plate. In this case, TIP urethroplasty may well prove to be a good option. It may even yield better results than onlay flap repair, because flap repairs have a poor mechanical support and tend to become patulous with time. The patients may then have to put up with problems such as poor ejaculation, post-micturition dribble and asymmetric rotation of flaps which may cause penile torsion [19,20].

In view of the above mentioned complications of one-stage and two-stage repair techniques, a modern approach in hypospadias repair should aim at preserving the urethral plate, if possible [21]. The urethral plate, when preserved, is an excellent tool for tubularization and urethral reconstruction in proximal hypospadias [21]. TIP urethroplasty is the main technique because it is versatile [22,23]. No tissue

is as good as the urethra, and TIP repair with spongioplasty reconstructs a near normal urethra. Its results are good and reproducible [4]. Advantages of spongioplasty include the presence of well vascularized, natural, locally available tissue to cover the neourethra, which may aid in the natural propulsion of urine and semen. The risk of complications is minimal in cases of TIP urethroplasty with spongioplasty. Spongioplasty also decreases the tension on the midline suture line of urethroplasty, especially during erections. With scrotoplasty, the neourethra is covered with a thick layer of healthy tissue up to the penoscrotal junction, which helps to prevent fistula formation. None of our patients had a fistula in the scrotal region. In patients with an intact prepuce preputioplasty is feasible. We did preputioplasty in four cases.

TIP urethroplasty is less favorable in severe hypospadias, as ventral chordee correction is difficult. Causes of curvature may originate at the level of the skin, dartos fascia, Buck's fascia, the corpus spongiosum, the urethral plate, the urethra or the corpora [24]. Methods of correction include penile degloving, TAP (tunica albuginea plication), dorsal midline plication, MPP (multiple parallel suture plication), ventral grafts, extended urethral mobilization [22], division of the urethral plate and penile disassembly [25].

With mobilization of the urethral plate and spongiosum with or without single-stitch dorsal plication, preservation of the urethral plate provides the chance of TIP urethroplasty in cases with severe hypospadias [22].

Kajbafzadeh et al. [26] were able to correct severe chordee by corpus spongiosum/urethral plate elevation combined with ventral corporotomy and tunica vaginalis grafting, which successfully preserved the plate for TIP urethroplasty in 13 of 18 cases (perineal 6 and penoscrotal 12). The blood supply of the urethral plate and urethra derives from the bulbar artery which is maintained as the urethral plate is lifted with the corpus spongiosum, and the proximal and distal ends are kept attached, maintaining the continuity of the corpus spongiosum [22]. It is important not to damage the corpus spongiosum or corpus cavernosum [15].

The gain in urethral length achieved by mobilization will help to correct curvature and make TIP urethroplasty feasible. However, if the curvature still persists after proximal urethral mobilization up to the bulb or dorsal stitch plication, then transection of the urethral plate is required. We perform the Gittes test to confirm correction of the curvature before proceeding to urethroplasty.

Common complications of TIP urethroplasty are fistula, meatal stenosis, stricture, glans dehiscence and residual curvature. Their incidence varies from 13% to 60% in the literature [1,7,8,20]. Chen et al. [7] performed TIP urethroplasty in 19 patients with posterior hypospadias, (penoscrotal 16, scrotal 2 and perineal one) and reported an overall complication rate of 21% including fistula and meatal stenosis. We encountered stricture in 14.2% and fistula and meatal stenosis in 7.1% which is similar to the rates reported by Chen et al. None of our patients had residual curvature or glans dehiscence, and none of our seven adult patients complained of post-void dribbling or spraying of urine or during ejaculation.

There is a larger possibility of stricture formation with mobilization of the urethra and the spongiosum [27]. In our study group stricture was encountered in 14.28%. Our selection of patients with a well-developed wide urethral plate and a well-developed spongiosum, as

well as proper mobilization of the urethral plate and spongiosum, taking care not to damage the blood supply of the urethral plate, probably helped us to minimize the incidence of urethral strictures. According to El-Kassaby et al. [28], various studies describing the use of dartos-based flaps, tunica vaginalis and subcutaneous tissue flaps mention a fistula rate of 2–33%. In our series, the neourethra was covered with spongioplasty and dorsal dartos/tunica vaginalis flaps which helped to reduce fistula formation. Similar observations were noted by Sarhan et al. [29] who used a dartos flap, spongioplasty, or a combination of these techniques in addition to TIP urethroplasty. They observed a statistically significant decrease in fistula formation in cases in which spongioplasty was implemented compared to cases in which it was not.

To the best of our knowledge, this is the largest series of TIP urethroplasty in perineal hypospadias described as yet. The excellent functional and cosmetic results achieved with a single-stage procedure in 85.8% of our patients compare favorably with the results of two-stage procedures reported in the literature. Repairing severe hypospadias in a single stage using TIP urethroplasty seems to be preferable from an anesthetic, safety and economic perspective, especially in this era where cost reduction is getting more and more important. One limitation of our study is the lack of evaluation of the outcome using the HOSE system score, while we consider it an advantage that all operations were conducted in similar conditions by the same surgeon with the same suture material and instruments.

## Conclusion

Mobilization of the urethral plate with the corpus spongiosum and mobilization of the proximal urethra, combined with spongioplasty and glanuloplasty, adds length to the urethra. This helps to correct ventral curvature, to preserve the urethral plate and to perform TIP urethroplasty with spongioplasty, and thus to reconstruct a near normal urethra. Provided the urethral plate is well-developed and wide and the corpus spongiosum is moderately to well developed, TIP urethroplasty can be done in perineal and perineo-scrotal hypospadias with an acceptable complication rate.

## Conflict of interest

None declared.

## References

- [1] Snodgrass W, Koyle M, Manzoni G, Hurwitz R, Caldamone A, Ehrlich R. Tubularized incised plate hypospadias repair for proximal hypospadias. *J Urol* 1998;159:2129–31.
- [2] Elbakry A. Further experience with the tubularized incised urethral plate technique for hypospadias repair. *BJU Int* 2002;89:291–4.
- [3] Cheng EY, Vemulapalli SN, Kropp BP, Pope JC, Furness PD, Kaplan WE, et al. Snodgrass hypospadias repair with vascularised dartos flap: the perfect repair for virgin cases of hypospadias? *J Urol* 2002;168:1723–6.
- [4] Retik AB, Borer JG. Hypospadias. In: Walsh PC, Retik AB, Vaughan Jr ED, Wein AJ, editors. *Campbell's urology*. 8th ed. Philadelphia: WB Saunders Co.; 2002. p. 2302–33.
- [5] Retik AB, Atala A. Complications of hypospadias repair. *Urol Clin North Am* 2002;29:329–39.
- [6] Snodgrass WT, Lorenzo A. Tubularized incised-plate urethroplasty for proximal hypospadias. *BJU Int* 2002;89:90–3.

- [7] Chen SC, Yang SS, Hsieh CH, Chen YT. Tubularized incised plate urethroplasty for proximal hypospadias. *BJU Int* 2000;86:1050–3.
- [8] Palmer LS, Palmer JS, Franco I, Friedman SC, Kolligian ME, Gill B, et al. The “long Snodgrass”: applying the tubularized incised plate urethroplasty to penoscrotal hypospadias in 1-stage or 2-stage repairs. *J Urol* 2002;168:1748–9.
- [9] Emir H, Jayanthi VR, Nitahara K, Danismend N, Koff SA. Modification of the Koyanagi technique for the single stage repair of proximal hypospadias. *J Urol* 2000;164:973–5.
- [10] Jayanthi VR. The modified Koyanagi hypospadias repair for the one stage repair of proximal hypospadias. *Indian J Urol* 2008;24:206–9.
- [11] Haxhirekha KN, Castagnetti M, Rigamonti W, Manzoni GA. Two-Stage repair in hypospadias. *Indian J Urol* 2008;24:226–32.
- [12] Gershbaum MD, Stock JA, Hanna MK. A case for 2-stage repair of perineoscrotal hypospadias with severe chordee. *J Urol* 2002;168:1727–8.
- [13] Moursy EE. Outcome of proximal hypospadias repair using three different techniques. *J Pediatr Urol* 2010;6:45–53.
- [14] Aseem RS, Rakesh PP, Douglas AC. The 2-stage hypospadias repair. Is it a misnomer? *J Urol* 2004;172:1714–6.
- [15] Bhat A, Patni M, Saxena G, Kumar P, Arya M. Bhat’s technique of chordee correction and onlay flap urethroplasty in cases of hypospadias with chordee. *BJU Int* 2002;90(Suppl.):67.
- [16] Duckett JW, Baskin LS. Hypospadias. In: Gillenwater JY, Grayback JT, Howards SS, Duckett JW, editors. *Adult and pediatric urology*. 3rd ed. St. Louis: Mosby-Year Book; 1996. p. 2549–89.
- [17] Macedo Jr A, Liguori R, Ottoni SL, Garrone G, Damazio E, Mattos RM, et al. Long-term results with a one-stage complex primary hypospadias repair strategy (the three-in-one technique). *J Pediatr Urol* 2011;7:299–304.
- [18] De Mattos e Silva E, Gorduzo DB, Catti M, Valmalle AF, Demède D, Hameury F, et al. Outcome of severe hypospadias repair using three different techniques. *J Pediatr Urol* 2009;5:205–11.
- [19] Bracka A. The role of two-stage repair in modern hypospadiology. *Indian J Urol* 2008;24:210–8.
- [20] Braga LH, Pippi Salle JL, Lorenzo AJ, Skeldon S, Dave S, Farhat WA, et al. Comparative analysis of tubularized incised plate versus onlay island flap urethroplasty for penoscrotal hypospadias. *J Urol* 2007;178:1451–7.
- [21] Upadhyay J, Shekarriz B, Khoury AE. Midshaft hypospadias. *Urol Clin North Am* 2002;29:299–310.
- [22] Bhat A. Extended urethral mobilization in incised plate urethroplasty for severe hypospadias: a variation in technique to improve chordee correction. *J Urol* 2007;178:1031–5.
- [23] Borer JG, Bauer SB, Peters CA, Diamond DA, Atala A, Cilento Jr BG, et al. Tubularized incised plate urethroplasty: expanded use in primary and repeat surgery for hypospadias. *J Urol* 2001;165:581–5.
- [24] Snodgrass W, Yucel S. Tubularized incised plate for mid shaft and proximal hypospadias repair. *J Urol* 2007;177:698–702.
- [25] Mingin G, Baskin LS. Management of chordee in children and young adults. *Urol Clin North Am* 2002;29:277–84.
- [26] Kajbafzadeh AM, Arshadi H, Payabvash S, Salmasi AH, Najjaran-Tousi V, Sahebpor AR. Proximal hypospadias with severe chordee: single stage repair using corporeal tunica vaginalis free graft. *J Urol* 2007;178:1036–42.
- [27] Snodgrass WT, Granberg C, Bush NC. Urethral strictures following urethral plate and proximal urethral elevation during proximal TIP hypospadias repair. *J Pediatr Urol* 2013;9:990–4.
- [28] El-Kassaby AW, Al-Kandari AM, Elzayat T, Shokeir AA. Modified tubularized incised plate urethroplasty for hypospadias repair. A long-term results of 764 patients. *Urology* 2008;71:611–5.
- [29] Sarhan OM, El-Hefnawy AS, Hafez AT, Elsherbiny MT, Dawaba ME, Ghali AM. Factors affecting outcome of tubularized incised (TIP) urethroplasty: single centre experience of 500 cases. *J Paediatr Urol* 2009;5:378–82.