



Pan African Urological Surgeons' Association

African Journal of Urology

www.ees.elsevier.com/afju
www.sciencedirect.com



Review

Congenital obstructive uropathy – Diagnostics for optimal treatment



Christian Radmayr

Department of Paediatric Urology, Medical University Innsbruck, Austria

Received 4 March 2015; accepted 31 March 2015

KEYWORDS

Congenital obstructive uropathy;
Diagnosis;
Treatment

Abstract

Antenatal ultrasound screening techniques reveal urological abnormalities in about 1 of 500 cases with half of which belonging to hydronephrosis. Postnatal appropriate diagnostic modalities are obligatory for proper diagnosis. Nowadays, ultrasound is definitively one of the most useful imaging modalities for the upper tract in children with hydronephrosis. It is non-invasive, radiation free and can be repeated. In addition, ultrasound also offers excellent images of the lower urinary tract in the diagnosis of posterior urethral valves or ureteroceles for example.

An additional tool is isotope renal scintigraphy which is method to analyse differential renal function and drainage of the kidney as well as functioning cortical mass with an accurate image of renal parenchyma.

Today MRI studies are becoming more and more popular. This technique is particularly suited to urological imaging, because of its excellent delineation of water/urine-containing structures.

The micturating cystourethrogram is still the gold standard in imaging the bladder and the urethra. It also serves as a functional investigation while the patient is voiding. The technique consists of catheterizing the person in order to fill the bladder with a radiocontrast agent and is, therefore, an invasive method.

Since there is a risk of an increase in severity and functional deterioration with time on the one hand but also improvement and stable function on the other hand, suitable diagnosis is mandatory in order to rule out the children at risk.

© 2015 Pan African Urological Surgeons' Association. Production and hosting by Elsevier B.V. All rights reserved.

Natural history of prenatally diagnosed hydronephrosis

Routine antenatal ultrasound screening was introduced 30 years ago, and rapidly gained wide acceptance in some countries. Urological

abnormalities are detected in 1 in 500 pregnancies [1,2], among which half are unilateral hydronephrosis (Fig. 1).

Before the era of prenatal ultrasound, hydronephrosis was mainly diagnosed in symptomatic older children presenting with loin pain, stones, haematuria, or pyelonephritis. Antenatal diagnosis has brought into light a unique and unknown population of healthy and asymptomatic infants having mild to severe hydronephrosis, with variable outcome [3].

E-mail address: christian.radmayr@i-med.ac.at

Peer review under responsibility of Pan African Urological Surgeons' Association.

<http://dx.doi.org/10.1016/j.afju.2015.03.006>

1110-5704/© 2015 Pan African Urological Surgeons' Association. Production and hosting by Elsevier B.V. All rights reserved.

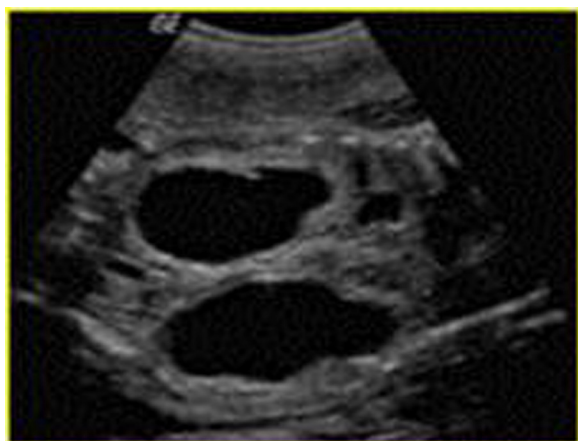

Figure 1 Antenatal ultrasound showing bilateral hydronephrosis.

It is known that prenatally diagnosed hydronephrosis may increase in severity and show functional deterioration with time, consistent with the definition of obstruction. It has also been reported that such a dilatation may remain stable (in fact the majority of cases), or improve with time, although it is unknown whether a true obstruction was present and vanished, or if the dilated but non obstructed system simply improved [4,5]. The potential for spontaneous resolution of unilateral hydronephrosis thus questions the necessity of surgical treatment, and the true nature of this dilatation if not obstruction.

Tribute must be paid to HK Dhillon and the perinatal urologists team of the Great Ormond Street Hospital for the outstanding amount of work dedicated to the follow-up of prenatally diagnosed hydronephrosis over a 25 years period. In their “natural history” series with conservative management, they showed that:

- Follow-up based on ultrasound is safe.
- Virtually all infants requiring pyeloplasty [6,7] for impaired renal function at birth had pelvic AP diameter >20 mm (Fig. 2).
- The vast majority of children born with normally functioning kidney, but who required surgery for deteriorating function had pelvic AP diameter >20 mm at birth.
- When deterioration of the function occurs, it is usually preceded by a worsening of the dilatation.

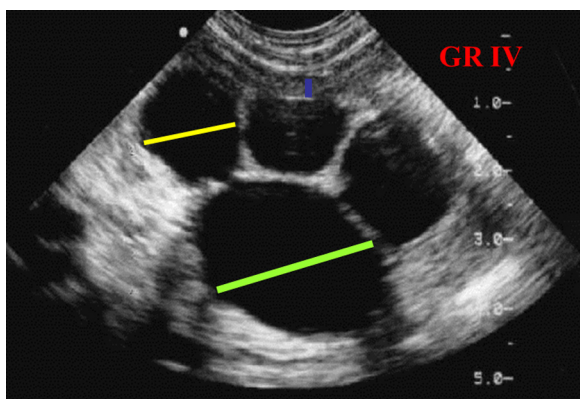


Figure 2 Grade IV hydronephrosis with an AP diameter above 20 mm.

The same authors showed that ultrasound is the most useful imaging study to differentiate infants with PUJ obstruction who (will) require surgery from those who have pelvi-calyceal dilatation of no clinical significance. Among infants with unilateral hydronephrosis and normally functioning kidney on the postnatal MAG-3 renal scan, 90% of those with renal pelvis between 30 and 40 mm, and virtually all of those with renal pelvis >40 mm will eventually deteriorate. In contrast, among those with hydronephrosis <20 mm at birth, only 11% will eventually require surgery (they usually have major calyceal involvement, intra-renal pelvis, and often early prenatal diagnosis during the second trimester). The “grey zone” lies between 20 and 30 mm, where 40% may eventually deteriorate, but the same proportion may also improve spontaneously.

Other authors have also studied the natural history of prenatally diagnosed hydronephrosis with regard to the potential deterioration of renal function [8–11]. Koff followed non-operatively 104 neonates with unilateral hydronephrosis regardless of the degree of dilatation and of the initial degree of functional impairment. A large proportion of those with initial impairment of DRF rapidly improved spontaneously. Twenty-three of 104 (22%) ultimately required surgery for deterioration of either DRF, dilatation, or both, always before 18 months of age. Of those requiring pyeloplasty, there was no permanent loss of renal function and DRF eventually returned to exceed predeterioration levels.

Natural history series have provided very useful informations regarding to prenatal counselling and postnatal management strategy. The main points arising from these natural history studies are

- The majority of prenatal unilateral hydronephrosis (75%) will either remain stable or improve spontaneously
- Some of them will show increase of dilatation and/or deterioration of the renal function, and will ultimately require surgery [12–14]
- It is probably safe to closely follow-up dilated kidneys with ultrasound alone, and perform isotope imaging if hydronephrosis worsens
- The risk of deterioration correlates with the degree of dilatation of both pelvis and calyces. The threshold above which the risk of deterioration during follow-up seems unreasonable is about 30 mm.
- When normally functioning kidneys deteriorate during follow-up, many of them will recover preoperative function level after pyeloplasty.
- Management of kidneys with initial functional impairment is debated. Some of them may see their DRF improve spontaneously with time. In contradiction, even when surgery is performed, this subgroup of congenitally damaged kidneys seem not to improve as much after pyeloplasty as the ones with sudden deterioration. It is probably safe (and easier to follow-up) to perform pyeloplasty in infants with initial renal differential function impairment, although the renal outcome may not be different.

Symptomatic hydronephrosis

Symptomatic hydronephrosis has long been the main clinical presentation leading to the diagnosis of PUJ obstruction. Different complication could be observed, like febrile UTI, symptomatic stones, or intermittent abdominal pain. In a number of cases, the latter takes part of a very specific clinical picture named “acute intermittent hydronephrosis” [15,16]. Typically, these children (usually

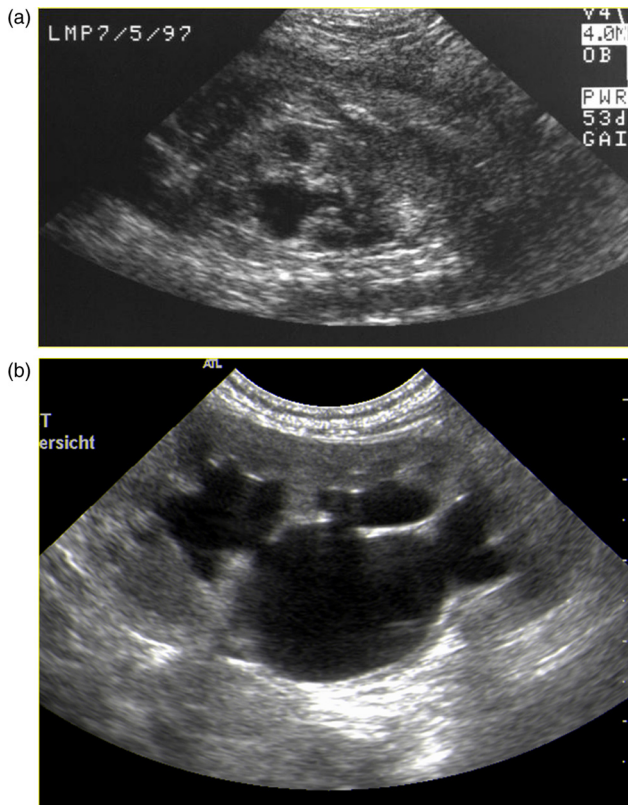


Figure 3 (a) Mild hydronephrosis – asymptomatic. (b) Severe hydronephrosis of the same child while symptomatic.

old children or adolescents) will present with intermittent abdominal and loin pain, vomiting, and intermittent hydronephrosis usually related to lower-pole crossing vessels. It is important to note that ultrasound may display considerable variability of dilatation with time, and may be strictly normal between the crisis (Fig. 3a and b). The frequency of the crisis will increase progressively if the diagnosis is not recognised. The majority of these children are thought to have no intrinsic PUJ obstruction.

Preoperative workup including US (during and out of crisis) studies MAG-3 functional assessment, but an angio-MRI may also be useful to assess the presence of crossing vessels, if not seen on ultrasound.

Imaging studies

Ultrasonography

Renal ultrasound is the cornerstone in the diagnostic pathway of children with hydronephrosis. During the prenatal period, one useful and reproducible method to assess hydronephrosis uses the Society for Foetal Urology (SFU) criteria [17], which grade the renal pelvis dilatation, the number of calyces seen and parenchymal atrophy within five grades of increasing severity (Fig. 4).

After birth and throughout childhood, the most reliable and reproducible measurement remains the antero-posterior (AP) diameter of the pelvis. Pelvic AP diameter greater than 7 mm at 18–23 weeks’ gestation, 10 mm during the last trimester, and 12 mm at birth should be considered as abnormal. One must take into account the variability of the AP diameter in a same child, in relation to the degree of hydration, degree of bladder fullness, and renal function.

Grade 0	No hydro
Grade I	Renal pelvis is visualized
Grade II	Renal pelvis and some calyces are visualized
Grade III	Renal pelvis and all calyces are visualized
Grade IV	Grade III plus parenchymal thinning

Figure 4 SFU Grading System.

The degree of dilatation of the calyces, their size and shape, although more subjective, also appear very important in the analysis of the degree of dilatation. Knowing the anatomical variant of extra-renal dilated (but non obstructed) pelvis with normal calyces and parenchyma, we tend to define hydronephrosis as a dilated pelvis with some calyceal dilatation. Other criteria, like calyces/parenchymal thickness ratio, have proven less effective in determining the degree of dilatation.

In addition, ultrasound also offers excellent images of the lower urinary tract in the diagnosis of posterior urethral valves (Fig. 5) or ureteroceles (Fig. 6) for example.

Isotope renography: MAG-3 Renal scan

Dynamic diuretic isotope renal scintigraphy is a non-invasive method to analyse differential renal function and drainage of the kidney [18]. The radiopharmaceutical agent of choice is the ^{99m}Tc-mercaptoacetyltriglycerine (MAG-3), especially in infants: it is a tubular agent, with high protein binding, high tubular extraction, and low distribution in the extra-vascular space and subsequently low background activity. Serial dynamic acquisition show two distinct phases on a time-activity curve: an uptake phase with a rapid rise of activity as the tracer is delivered to the kidney, and a clearance phase as the tracer is excreted in the collecting system (Fig. 7).

Differential renal function (DRF)

Isotope renography provides a quantification of the differential renal function by comparing the slope of the time-activity curves of each kidney during the uptake phase. MAG-3 renal scan may also provide

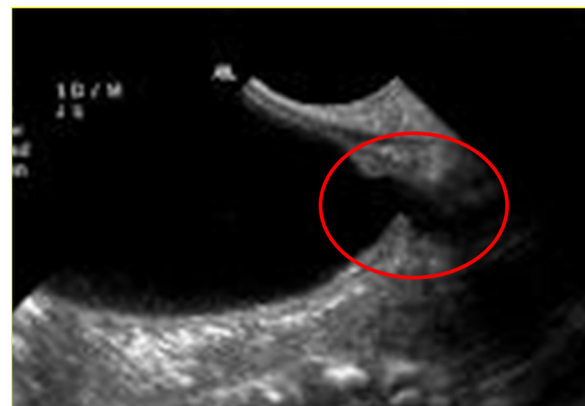

Figure 5 Bladder ultrasound with keyhole sign in PUV.

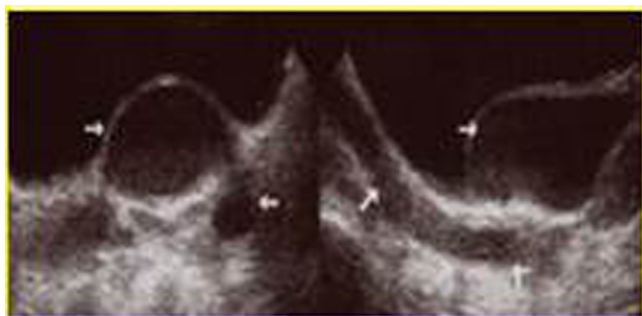

Figure 6 Bladder ultrasound revealing an ureterocele and a dilated ureter.

an estimate of the absolute renal function, although much less reliable than a glomerular filtration rate study using ⁵¹Cr-EDTA. In the assessment of unilateral uropathies, one has to keep in mind that DRF is a comparative analysis, even though the contralateral kidney is not normal. Hence, equilibrate split function does not always mean normally functioning kidneys, but sometimes equally impaired kidneys [19]. In addition, it is admitted that “static” DMSA renal scan provides a more accurate evaluation of the differential renal function especially with poorly functioning kidneys, whilst the irradiation dose delivered is also significantly higher.

Clearance phase

The decrease of activity in the region of interest, also called “drainage curve”, traduces the urine washout though the collecting

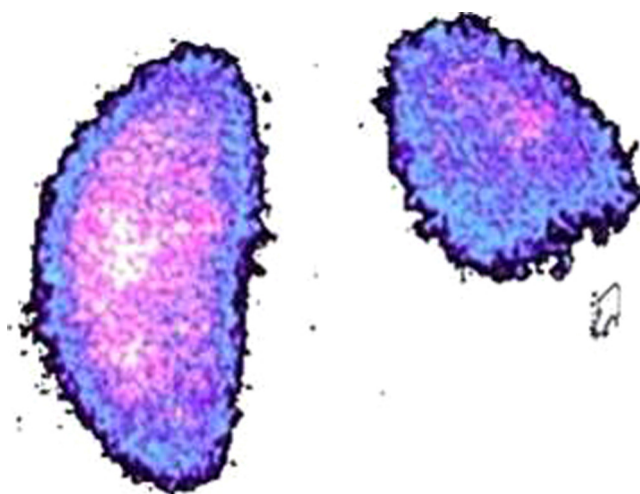


Figure 8 DMSA scan with a lower pole scar on the right side.

system. There has been considerable debate regarding whether poor washout truly indicated the presence of obstruction in a dilated collecting system, or only delayed emptying. There are indeed several parameters involved, among which the degree of dilatation, the degree of maturation of the kidney, the degree of hydration, individual kidney function, urine flow rate, the timing of administration of the diuretic, the fullness of the bladder, and the timing of post-micturition images. It is now widely admitted that only looking at the slope of the drainage curve is a simplistic approach to a complex parameter.

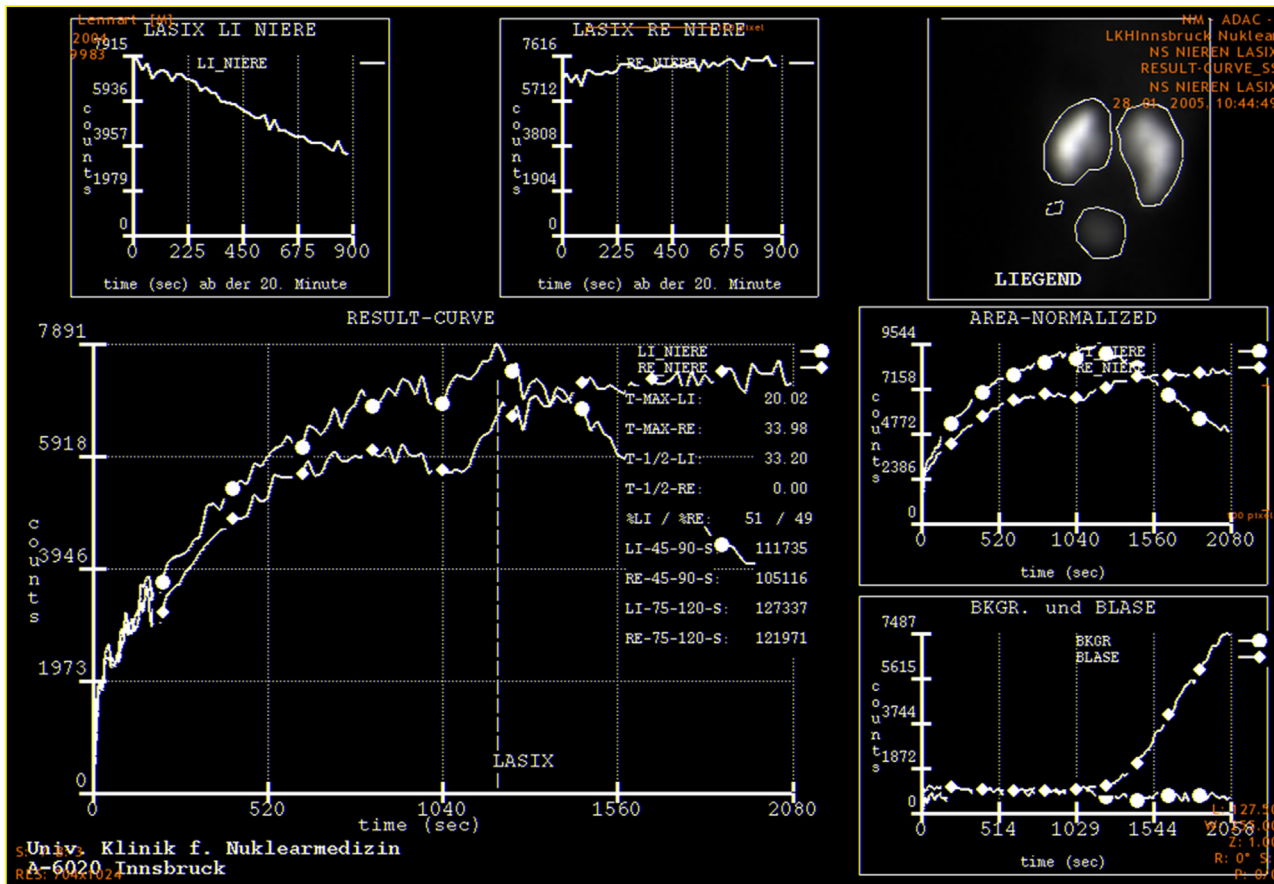


Figure 7 MAG3 scan in unilateral hydronephrosis showing obstruction.

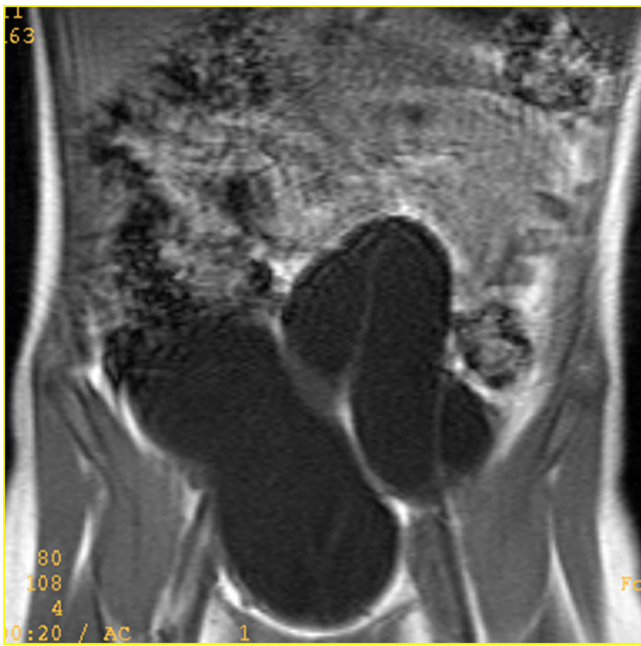


Figure 9 Hydronephrosis in an ectopic megaureter.

The most obvious criterion is the dilatation: one cannot expect a large dilated pelvis to drain as quickly as a smaller volume pelvis [20]. It has also been shown that a full bladder will inhibit drainage from the pelvis, as well as the supine position; no conclusion on the drainage should be drawn without a post-micturition image and a change in posture.

Objective measurements, like half-time after diuretic injection, output efficiency, normalised renal activity, or pelvic excretion efficiency before and after voiding, have not proven more effective to assert PUJ obstruction. Studies looking at the natural history of unilateral hydronephrosis have reported several examples of impaired

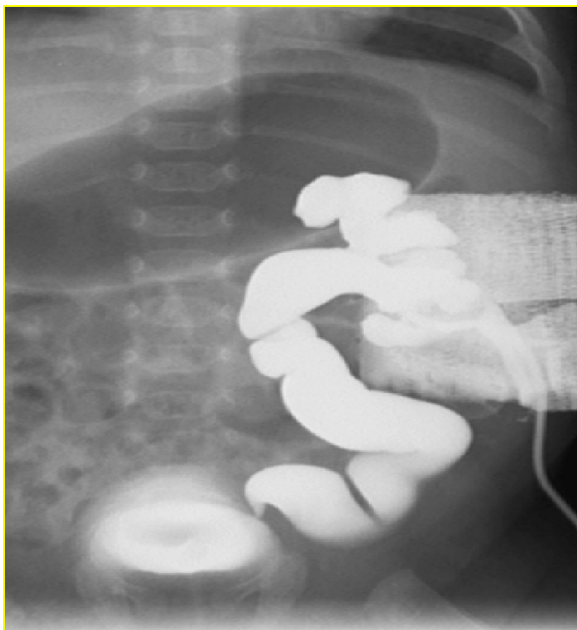


Figure 10 Antegrade pyelogram.

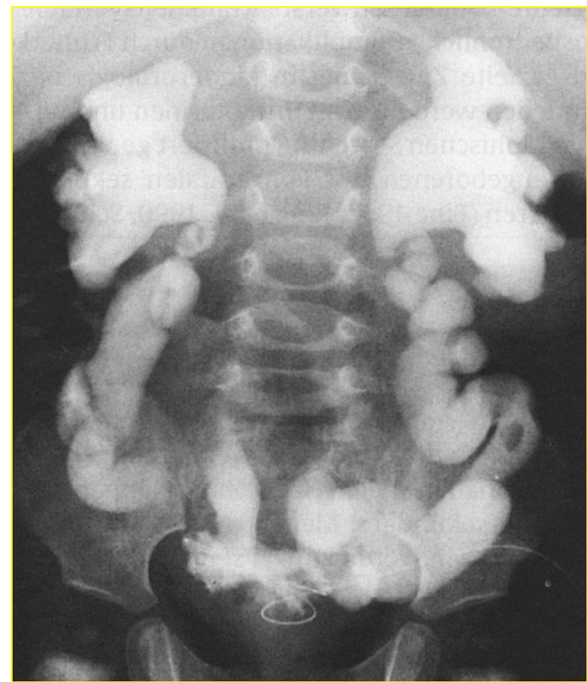


Figure 11 Hydronephrosis caused by bilateral dilating reflux due to PUV.

drainage curves in children whose dilatation and differential function remained stable over time, with no need for intervention (i.e. meeting the definition criteria of no obstruction).

In conclusion, there is little doubt that impaired drainage on diuretic renography is not synonymous of an obstruction in unilateral hydronephrosis, but may only reflect delayed emptying of a dilated system [8]. In contrast, good drainage on renography is surely a definite sign of the absence of obstruction.

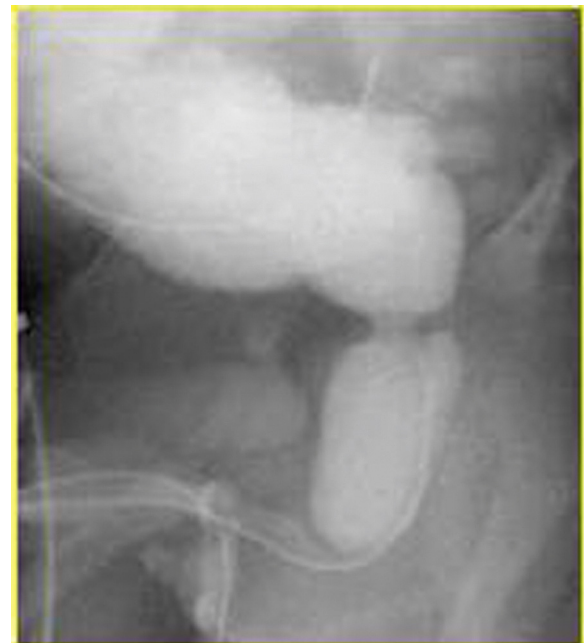

Figure 12 Dilated posterior urethra while voiding in a PUV.

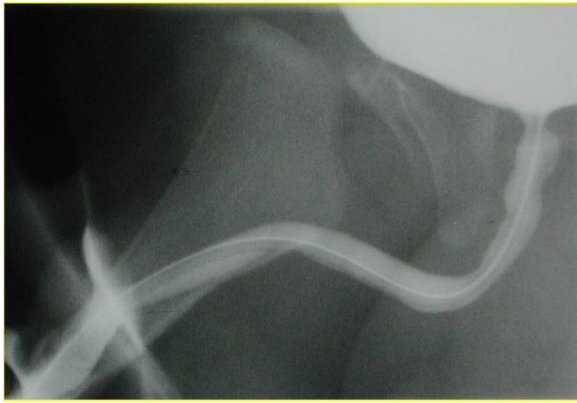


Figure 13 Transurethral catheter in place during VCUG.

Isotope renography: DMSA scan

Static renal scintigraphy is a non-invasive delivering images representing functioning cortical mass and therefore providing an accurate image of renal parenchyma [9]. The tracer bind to the proximal tubules and offers a high sensitivity in the detection of parenchymal pathology (Fig. 8).

Magnetic resonance imaging (MRI)

MRI is particularly suited to urological imaging, because of its excellent delineation of water/urine-containing structures. There has been great expectation that dynamic contrast enhanced MRI would

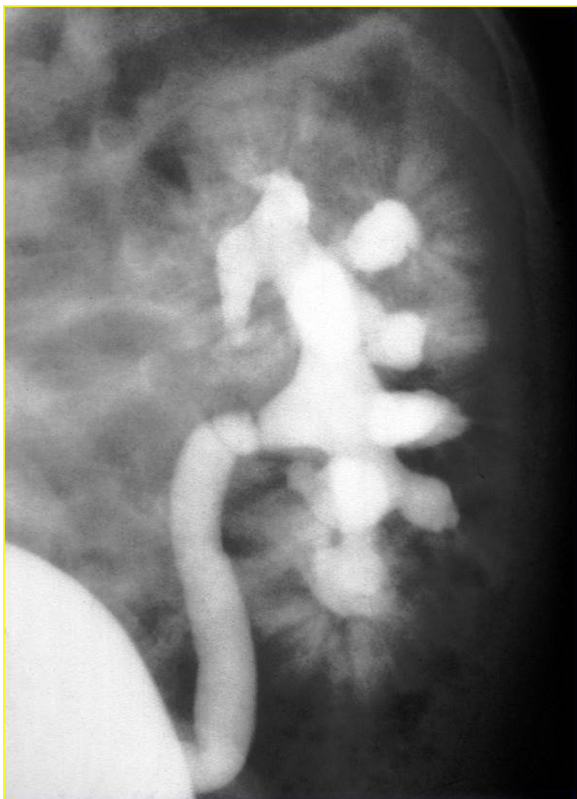

Figure 14 High grade reflux showing intrarenal reflux into the collecting ducts.

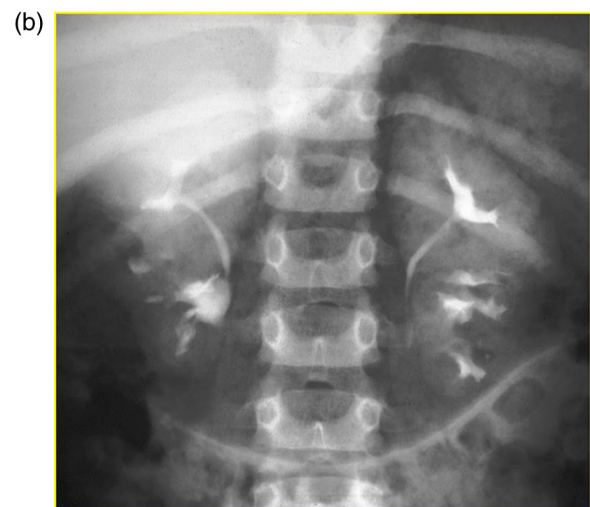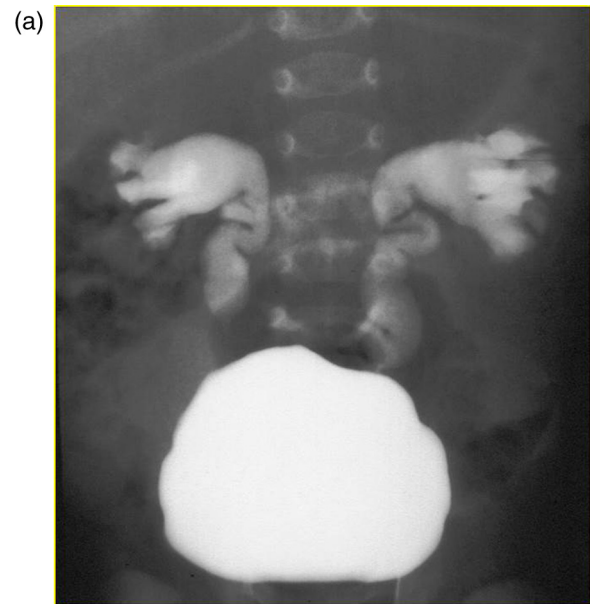


Figure 15 (a) Reflux to both lower poles in case of complete duplication. (b) Reflux to both poles on either side due to incomplete duplication.

be able to substitute to both renal ultrasonography and scintigraphy. Indeed, MRI has the ability to provide very detailed anatomical description (Fig. 9), combined with a functional evaluation. This promising technique, which has been under evaluation for more than 10 years, still struggles to provide functional informations as accurate as conventional isotope studies. Additional drawbacks are the costs, and the need for sedation or general anaesthesia after 6 months of age.

Pressure-flow studies

Whitaker first described this testing in the early 70s, which involved percutaneous nephrostomy, infusion of extrinsic flow (10 mL/mn) and monitoring of intrapelvic pressures [21]. Not only this test was invasive, required general anaesthesia, and simultaneous monitoring with ultrasonography and fluoroscopy, but also appeared poorly discriminant and reproducible.

Nevertheless, refinements in the techniques of pressure flow studies allowed to show that renal pelvic pressures could remain normal at low infusion flow even in severely obstructed systems, giving support to the intuitive clinical impression that some collecting systems can remain equilibrated although obstructed, and that increased workload may lead to decompensation of pelvic pressures to dangerous levels [22].

Antegrade pyelogram

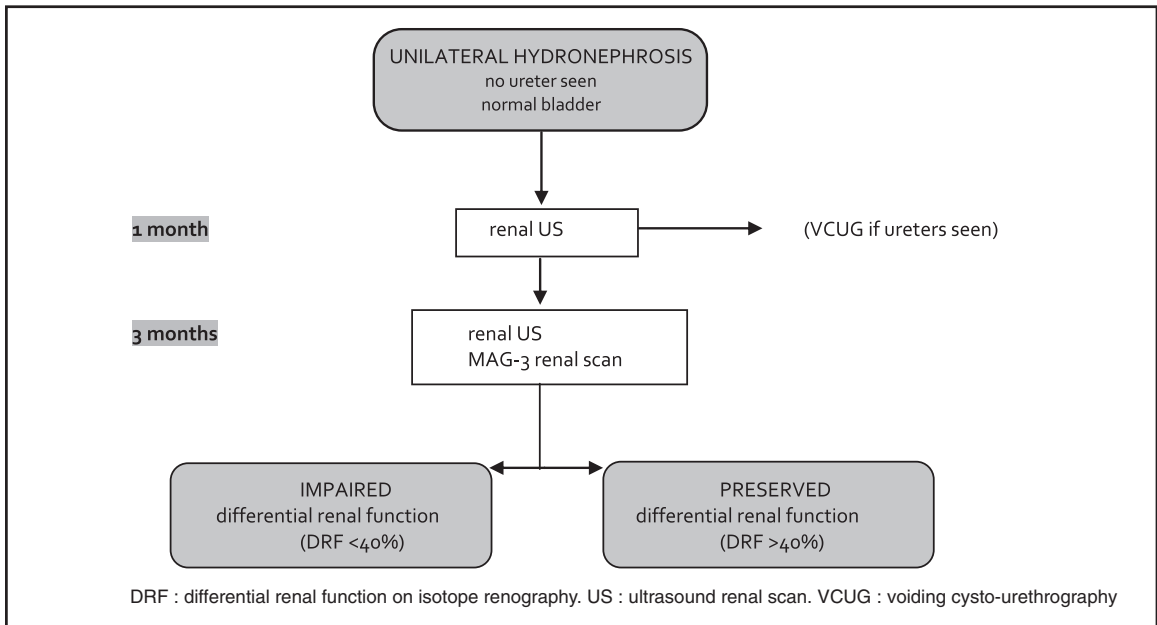
Percutaneous US guided puncture with antegrade pyelogram is rarely necessary but may be helpful in some confusing cases, when there is a doubt about the exact level of obstruction (Fig. 10).

Voiding Cystourethrogram

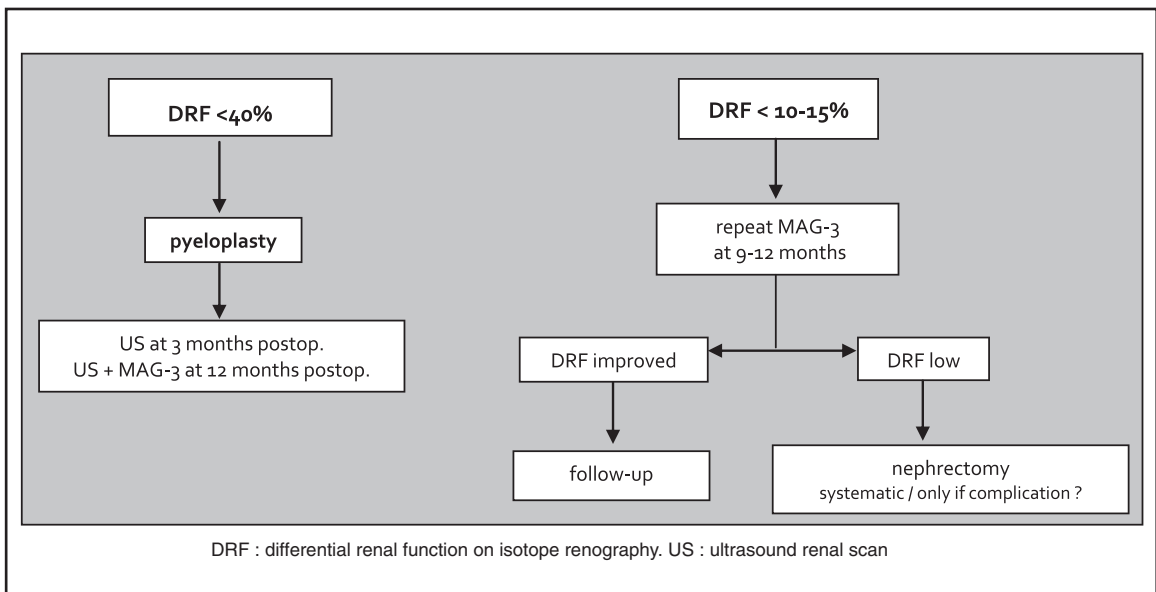
This radiologic methodology (also micturating cystourethrogram – MCUG), is still the gold standard in imaging the bladder and the

urethra (Fig. 11). It also serves as a functional investigation while the patient is voiding (Fig. 12). The technique consists of catheterizing the person in order to fill the bladder with a radiocontrast agent [23–25] (Fig. 13). Under fluoroscopy (real time X-rays) the investigator watches the contrast enter the bladder and looks at the anatomy. If the contrast moves into the ureters and back into the kidneys, the diagnosis of vesicoureteral reflux is made. The degree of severity can be given ranging from grade I to V according to the scoring system of the International Reflux Study Group (Fig. 14). Additionally, it gives excellent information on duplex systems as well (Fig. 15a and b). The exam ends when the patient voids while the while watching under fluoroscopy allowing to get exact images of the urethra. It is important to watch the contrast during voiding, because this is when the bladder has the most pressure, and it is most likely this is when reflux will occur.

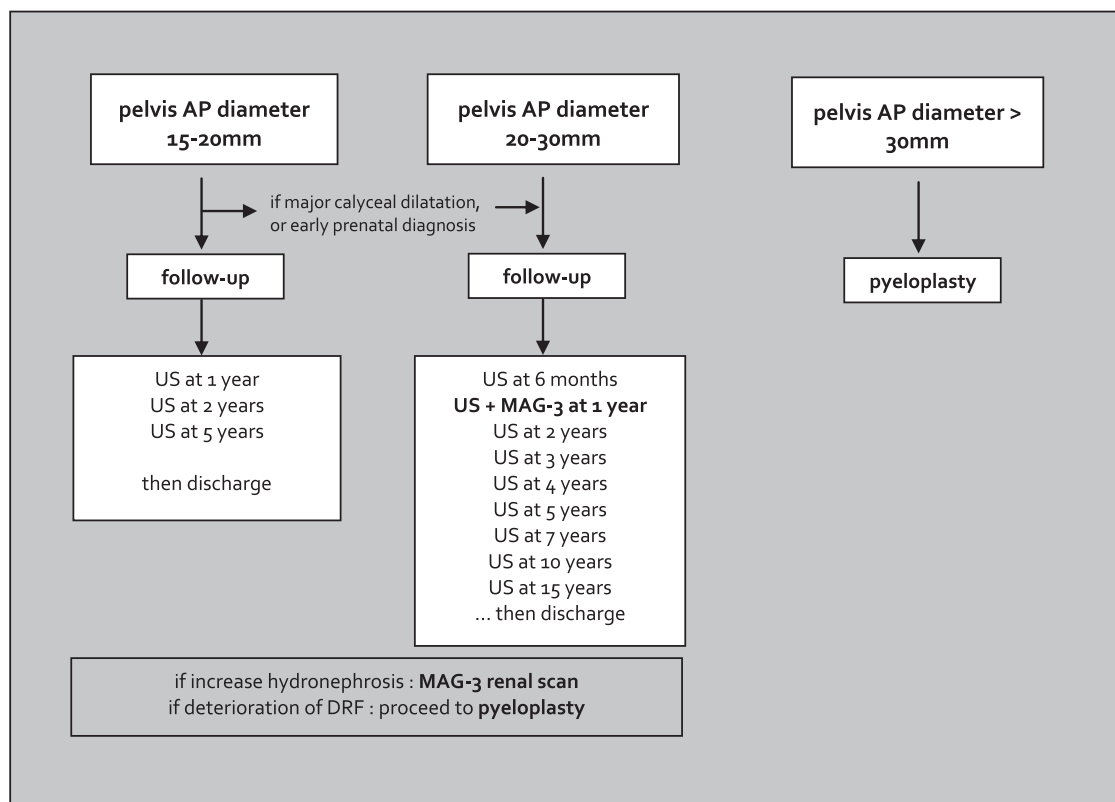
Proposed pathway for prenatally diagnosed unilateral hydronephrosis



Impaired differential function



Normal differential function



DRF : differential renal function on isotope renography. US : ultrasound renal scan. AP diameter : antero-posterior diameter

Conflict of interest

None declared.

References

- [1] Churchill BM, Feng WC. Ureteropelvic junction anomalies: congenital PUJ problems in children. In: Gearhart JP, Rink RC, Mouriquand PDE, editors. *Pediatric urology*. Philadelphia: WB Saunders; 2001. p. 318–46.
- [2] Thomas DFM. Upper tract obstruction. In: Thomas DFM, Duffy PG, Rickwood AMK, editors. *Essentials of paediatric urology*. 2nd ed. London: Informa Healthcare; 2008. p. 73–92.
- [3] Yiee J, Wilcox DT. Ureteropelvic junction obstruction. In: Wilcox DT, Godbole P, Koyle MA, editors. *Pediatric urology: surgical complications and management*. London: Wiley-Blackwell; 2008. p. 58–66.
- [4] Jayanthi VR, Koff SA. Upper tract dilatation. In: Stringer MD, Oldham KT, Mouriquand PDE, editors. *Pediatric surgery and urology. Long term outcome*. 2nd ed. Cambridge: Cambridge University Press; 2006. p. 533–9.
- [5] Fembach SK, Maizels M, Conway JJ. Ultrasound grading of hydronephrosis: introduction to the system used by the Society for Fetal Urology. *Pediatr Radiol* 1993;23(6):478–80.
- [6] Gordon I, Colarinha P, Fettich J, Fischer S, Frökier J, Hahn K, et al. Guidelines for standard and diuretic renography in children. *Eur J Nucl Med* 2001;28(March (3)):BP21–30.
- [7] Amarante J, Anderson PJ, Gordon I. Impaired drainage on diuretic renography using half-time or pelvic excretion efficiency is not a sign of obstruction in children with prenatal diagnosis of unilateral renal pelvic dilatation. *J Urol* 2003;169:1828–31.
- [8] Eskild-Jensen A, Gordon I, Piepsz A, Frøkiaer J. Interpretation of the renogram: problems and pitfalls in hydronephrosis in children. *BJU Int* 2004;94(October (6)):887–92.
- [9] Gordon I. Pathophysiology of renal function and its effect on isotope studies in the workup of hydronephrosis. *World J Urol* 2004;22:411–4.
- [10] Whitaker RH. An evaluation of 170 diagnostic pressure flow studies of the upper urinary tract. *J Urol* 1979;121:602–4.
- [11] Fung LC, Khoury AE, McLorie GA, Chait PG, Churchill BM. Evaluation of pediatric hydronephrosis using individualized pressure flow criteria. *J Urol* 1995;154(2, Pt 2):671–6.
- [12] Dhillon HK. Prenatally diagnosed hydronephrosis: the Great Ormond Street experience. *Br J Urol* 1998;81(Suppl. 2):39–44.
- [13] Ransley PG, Dhillon HK, Gordon I, Duffy PG, Dillon MJ, Barratt TM. The postnatal management of hydronephrosis diagnosed by prenatal ultrasound. *J Urol* 1990;144(2, Pt. 2):584–7, discussion 593–4.
- [14] Koff SA, Campbell KD. The nonoperative management of unilateral neonatal hydronephrosis: natural history of poorly functioning kidneys. *J Urol* 1994;152(2, Pt 2):593–5.
- [15] Ulman I, Jayanthi VR, Koff SA. The long-term followup of newborns with severe unilateral hydronephrosis initially treated nonoperatively. *J Urol* 2000;164(3, Pt 2):1101–5.
- [16] Cartwright PC, Duckett JW, Keating MA, Snyder 3rd HM, Escala J, Blyth B, et al. Managing apparent ureteropelvic junction obstruction in the newborn. *J Urol* 1992;148(October (4)): 1224–8.
- [17] Sidhu H, Beyene J, Rosenblum ND. Outcome of isolated antenatal hydronephrosis: a systematic review and meta-analysis. *Pediatr Nephrol* 2006;21:218–24.
- [18] Yeung CK, Tam YH, Sihoe JD, Lee KH, Liu KW. Retroperitoneoscopic dismembered pyeloplasty for pelvi-ureteric junction obstruction in infants and children. *BJU Int* 2001;87(April (6)):509–13.

- [19] Metzelder ML, Schier F, Petersen C, Truss M, Ure BM. Laparoscopic transabdominal pyeloplasty in children is feasible irrespective of age. *J Urol* 2006;175(February (2)):688–91.
- [20] Bonnard A, Fouquet V, Carricaburu E, Aigrain Y, El-Ghoneimi A. Retroperitoneal laparoscopic vs open pyeloplasty in children. *J Urol* 2005;173(5):1710–3.
- [21] Olsen LH, Rawashdeh YF, Jorgensen TM. Pediatric robot assisted retroperitoneoscopic pyeloplasty: a 5-year experience. *J Urol* 2007;178(November (5)):2137–41, discussion 2141.
- [22] Culp OS, De Weerd JH. A pelvic flap operation for certain types of ureteropelvic obstruction. Observations after two years experience. *J Urol* 1951;71:523–9.
- [23] Rohrmann D, Snyder 3rd HM, Duckett Jr JW, Canning DA, Zderic SA. The operative management of recurrent ureteropelvic junction obstruction. *J Urol* 1997;158(3, Pt. 2):1257–9.
- [24] Gundeti MS, Reynolds WS, Duffy PG, Mushtaq I. Further experience with the vascular hitch (laparoscopic transposition of lower pole crossing vessels): an alternate treatment for pediatric ureterovascular ureteropelvic junction obstruction. *J Urol* 2008;180:1832–6.
- [25] Leclair MD, Gundeti MS, Heloury Y, Duffy P, Mushtaq I. PUJ obstruction and lower pole crossing vessels: further experience with the laparoscopic vascular hitch. *J Pediatr Urol* 2009;5(1):44.