



Pan African Urological Surgeons' Association

African Journal of Urology

[www.ees.elsevier.com/afju](http://www.ees.elsevier.com/afju)  
[www.sciencedirect.com](http://www.sciencedirect.com)



Case report

# Disintegrating perineal disease: A variant of watering-can perineum



N. Abrol\*, A. Devasia

Department of Urology, Christian Medical College, Vellore, India

Received 11 January 2014; received in revised form 11 January 2014; accepted 11 March 2014

**KEYWORDS**

Watering can perineum;  
Disintegrating perineal  
disease;  
Stricture urethra

**Abstract**

Watering-can perineum is a known complication of inflammatory urethral stricture disease. We report a case of disintegrating perineal disease, a fulminant variant of watering-can perineum, in an immunocompetent patient.

© 2014 Pan African Urological Surgeons' Association. Production and hosting by Elsevier B.V. All rights reserved.

**Case**

A 66-year-old male presented with swelling of scrotum and multiple discharging sinuses in inguinal region, scrotum, and perineum for last five years. He gave history of difficulty in voiding thirteen years ago. He underwent multiple urethral dilatations for his voiding difficulty thirteen years ago. After urethral dilatations he was apparently voiding with satisfactory flow. Five years ago he developed swelling in penoscrotal region that gradually increased with appearance of multiple discharging sinuses. On examination whole of scrotal, perineal, and inguinal skin was showing scarring, inflammation, induration, and disfigurement (Fig. 1). His evaluation

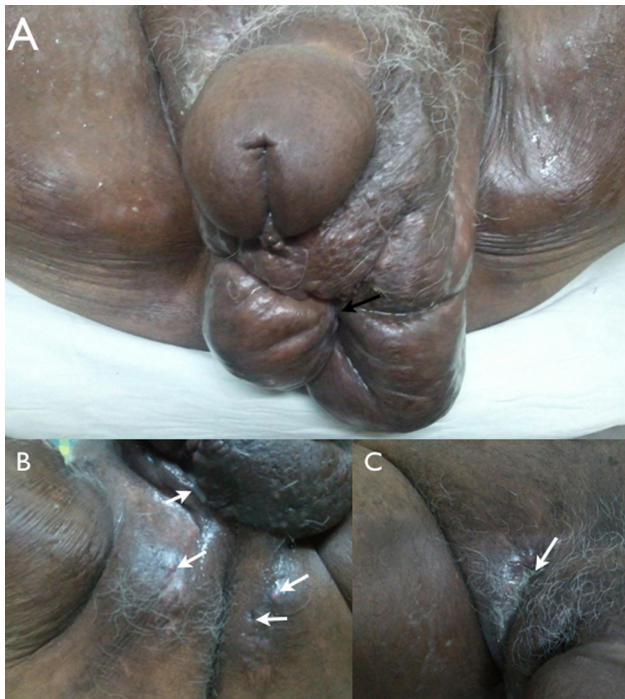for urinary tract tuberculosis, actinomycosis was negative. Micturating cystogram showed multiple intercommunicating fistulae in perineum (Fig. 2).

**Discussion**

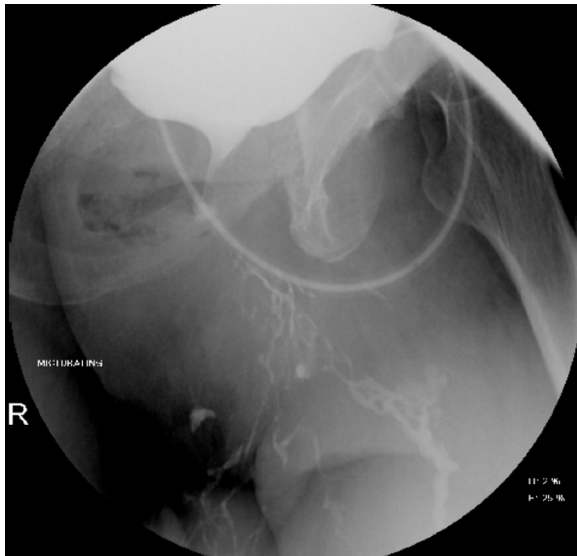
Watering-can perineum refers to urination through multiple urethrocutaneous fistulae in perineal region. Fulminant, long-standing purulent inflammation associated with watering-can perineum has been described in immunocompromised patients [1]. Due to stricture urine extravasates into periurethral glands leading to periurethral abscesses, that when burst on skin, form urethrocutaneous fistulae. Entity was common in the era of gonococcal urethritis [1]. Other described causes of watering can perineum are balanitis xerotica obliterans, tuberculosis of urethra or schistosomiasis [2]. Fungal infections (Eumycotic mycetoma or Actinomycotic mycetoma) and Lymphogranuloma venereum (LGV) infections can mimic watering can perineum by presenting as multiple discharging sinuses [3]. However these sinuses discharge black, pale, or red grains without

\* Corresponding author at: Department of Urology, Christian Medical College, Ida Scudder Road, Vellore 632004, India. Tel.: +91 416 2282055. E-mail addresses: [nitinabrol@cmcvellore.ac.in](mailto:nitinabrol@cmcvellore.ac.in), [dmabrol@yahoo.co.in](mailto:dmabrol@yahoo.co.in) (N. Abrol).

Peer review under responsibility of Pan African Urological Surgeons' Association.



**Figure 1** (Panel A) Scarring (black arrow), inflammation, and disfigurement of scrotal skin, (Panel B) multiple urethrocutaneous fistulae (white arrows), and (Panel C) purulent discharge from fistula.



**Figure 2** Micturating cystogram through suprapubic cystostomy showing contrast from proximal urethra extravasating to skin through multiple intercommunicating tracts.

showing any communication with urethra. Treatment of watering can perineum is suprapubic urinary diversion and delayed urethral reconstruction once infection and inflammation is settled.

### Conclusion

Patients with urethral stricture should be on long-term follow up. Early recognition and management of stricture disease can prevent devastating morbidity associated with disintegrating perineal disease.

### Funding

None.

### Conflict of interest

None.

### References

- [1] Classen FM, Wentzel SW, Greunen NV, Heyns CF. Disintegrating perineal disease in patients with urethral stricture and HIV infection: a review of 12 cases. *South Afr J Epidemiol Infect* 2013;28:91–5.
- [2] Gupta N, Mandal AK, Singh SK. Tuberculosis of the prostate and urethra: a review. *Indian J Urol* 2008;24:388–91.
- [3] Gupta S, Jain K, Parmar C, Shah P, Raval RC. Mycetoma: nonvenereal perineal lesions. *Indian J Sex Transm Dis* 2010;31:39–41.