



Pan African Urological Surgeons' Association

African Journal of Urology

[www.ees.elsevier.com/afju](http://www.ees.elsevier.com/afju)  
[www.sciencedirect.com](http://www.sciencedirect.com)



## Case report

# Multiple *Echinococcosis* with an unusual location in the spermatic cord treated successfully by Albendazole: A case report



A. Ksia<sup>a,\*</sup>, S. Mosbahi<sup>a</sup>, S. Belhassen<sup>a</sup>, A. Alaya<sup>b</sup>, L. Sahnoun<sup>a</sup>,  
S. Sfar<sup>a</sup>, K. Maazoun<sup>a</sup>, R. Laamiri<sup>a</sup>, J. Chahed<sup>a</sup>, I. Krichene<sup>a</sup>,  
M. Mekki<sup>a</sup>, M. Belghith<sup>a</sup>, A. Nouri<sup>a</sup>

<sup>a</sup> *Hopital Fattouma Bourguiba, Department of Pediatric Surgery, Medical school of Monastir, Monastir, Tunisia*

<sup>b</sup> *Hopital Fattouma Bourguiba, Department of biochemistry, Monastir, Tunisia*

Received 13 February 2013; received in revised form 26 September 2013; accepted 26 September 2013

### KEYWORDS

Echinococcal cyst;  
Spermatic cord;  
Albendazole;  
Surgery

### Abstract

Hydatid cysts are endemic in certain regions of the world. It can affect any organ. However, the primary site to the spermatic cord is an unusual location. Hydatid disease has been reported 5 times in the spermatic cord. The purpose of this study was to report a new case of a child with hydatid disease in the spermatic cord. This cyst is the first case treated successfully by Albendazole without surgery.

© 2013 Pan African Urological Surgeons' Association. Production and hosting by Elsevier B.V. All rights reserved.

### Introduction

Hydatid disease is due to an anthroozoonosis, caused by *Echinococcus granulosus* [1]. It is endemic in North Africa and the

Mediterranean [1]. Over 90% of human hydatid cysts are located in the liver and lungs. The aim of this work is to report an unusual location of echinococcosis at the spermatic cord and discuss the therapeutic management.

### Observation

The study case is a five-year-old boy with a history of bilateral vaginal hydrocele spontaneously cured and a left testicular ectopia for which he was operated at the age of three years with no complications. He was readmitted two years later for a right scrotal mass that has appeared one year ago and has gradually kept on increasing in volume since. On physical examination, the patient was afebrile, without cardiopulmonary auscultation abnormalities. Presence of a right lower thoracic parietal swelling of approximately 1.5 cm in diameter, firm, mobile, without silk signs. The abdomen

\* Corresponding author. Tel.: +216 97523763; fax: +216 73460678.

E-mail address: [amineks@yahoo.fr](mailto:amineks@yahoo.fr) (A. Ksia).

Peer review under responsibility of Pan African Urological Surgeons' Association.

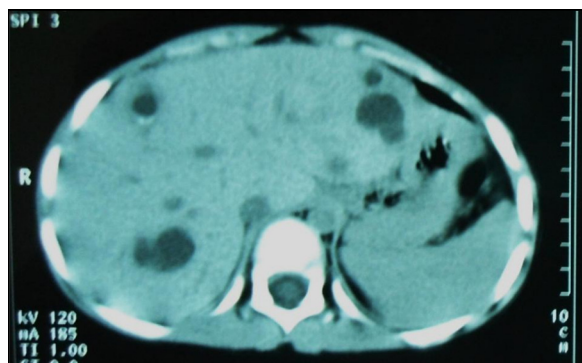


Production and hosting by Elsevier

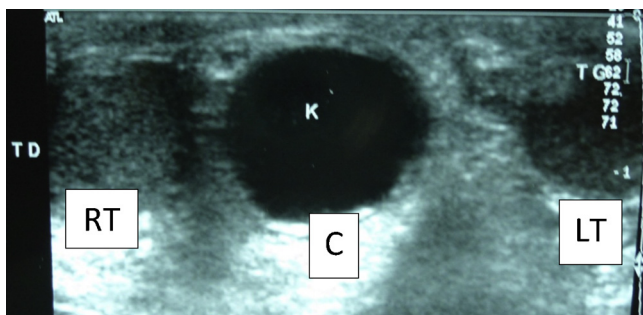
1110-5704 © 2013 Pan African Urological Surgeons' Association.

Production and hosting by Elsevier B.V. All rights reserved.

<http://dx.doi.org/10.1016/j.afju.2013.09.002>



**Figure 1** Axial contrast-enhanced CT image shows multiple hydatid cysts in the liver.



**Figure 2** Ultrasonographic appearance of the two. The cysts are independent of the right testicle. RT: right testicle; LT: left testicle, C: cyst.

was soft. On the examination of the external genitalia: both testicles had normal size and location, we identified a right scrotal bilobed mass of 3 cm in diameter, firm, mobile, testicle-independent and painless. Radiologic explorations: ultrasonography and thoraco-abdomino-pelvic scan showed multiple hydatid cysts: in the right lung (only one cyst of 1.5 cm in diameter), in the liver (at least 11 cysts of varying size, the largest is of 2.5 cm) (Fig. 1), one parietal cyst 2 cm in diameter and one exceptional location of hydatid larva in the right scrotum (two adjoining cysts of 2 cm and 1.5 cm in diameter) (Fig. 2). The therapeutic decision was to begin a medical treatment based on Albendazole (10 mg/kg) daily for six months. The evolution was marked by the complete collapse of the parietal cyst and complete regression of the scrotal and pulmonary cysts. As for the cysts in the liver, they involuted with calcification of most of them. We decided to continue treatment with Albendazole. The treatment was well tolerated by the patient. A regular assessment was made based on blood count, transaminases and renal function.

## Discussion

Hydatid disease is a parasitic disease widespread in North Africa and the Mediterranean. The liver and lungs are the most affected organs by the parasite. However, echinococcal cysts can be seen in every part of the body, when both filters are exceeded [2].

Usually, the kidney is the most common location genitourinary tract. It ranks third after lung and liver and represents 4–5% of visceral

location [1]. The first hydatid cyst of the spermatic cord was published by Chandra in 1951 [3]. This location is exceptional since only 5 cases have been reported in the literature occurring in two boys (ages: 4 and 9 years) [4,5] and three adults (ages: 26, 75, and 40 years) [3,6,7]. Scrotal location was primitive in all these patients.

Early hematogenous dissemination of hexacanth embryos seems to be the exclusive mechanism for their implementation in the spermatic cord. Moreover, it should be noted that, knowing the parasites, their life cycles very complex and their high capacity for adaptation, we think that the final location of *E. granulosus* in its intermediate host is not only the result of chance and simple anatomical filters. Molecular and enzymatic potential of the embryo intervene in determining its final destination [1]. Clinically the spermatic cord hydatid cyst is manifested by an inguinal or scrotal mass, mobile, painless, variable in size, causing a problem of differential diagnosis with other causes of inguinal masses including hernia, hydrocele, spermatic cord cyst, undescended testes, lymphadenopathy, lymphangioma cyst and abscess [3,4]. Ultrasound can identify the location of the lesion, guide to the diagnosis of hydatid cyst and classify it according to Gharbi classification [8]. Nonetheless the diagnosis is far from being obvious especially for the first type of this classification that is difficult to distinguish from a simple cyst of the spermatic cord or hydrocele. The fourth type is also difficult to diagnose because of its pseudotumoral appearance, posing the problem of differential diagnosis with other neoplasms of the spermatic cord. However, CT is necessary whenever the diagnosis is uncertain [8]. Biologically, hyper-eosinophilia is suggestive in 33–53% [9]. In any case, it has little value because of its non-specificity. Hydatid serology is currently positive in 81–94% and its specificity is 84–100% [10]. In fact, this simple and inexpensive test is of great interest both in the diagnosis of the disease and its follow-up.

The treatment of the hydatid cyst of spermatic cord is usually surgical. It should be conservative: preserving the testicular vasculature and maintaining a functional vas deferens. In the absence of adhesions with the noble elements (spermatic vessels, vas deferens), the peri-cystectomy must be total. This surgical treatment is required in order to stop the inexorable evolution of the cyst toward mechanical, infectious and immunological complications [11].

In 1977 was the first successful use of medical treatment in humans [12]. Since that date, several studies using benzimidazole carbamates constantly bring interesting results [13]. This therapy was initially used for patients considered inoperable [12]. In our case, Albendazole was prescribed for hydatid multiple locations scattered with small sizes. Other studies have confirmed the efficacy and feasibility of this therapy in multiple hydatidosis. The results of medical treatment of hydatid disease are variable depending on the series with a good response rate from 43.5 to 80% [14,15]. The best results are observed in patients who are less than 20 years, carrying small-sized cysts without daughter cysts or calcifications and that have been developing for less than two years [14]. The location of the cysts appears to have little influence on their evolution under Albendazole [14] however, cysts located near or on an epithelial structure disappear more easily [16]. Nonetheless, in the literature there are no cases of hydatid cyst of the spermatic cord treated solely with Albendazole. Our case is the first one. The evaluation of this treatment therefore, requires an extensive study on a larger number of patients.

## Conclusion

Spermatic cord hydatid cyst is an unusual location of *echinococcosis*. However, in endemic countries such as Tunisia, this entity should always be considered when a spermatic cord cyst is identified. Anthelmintic therapy may be an effective solution that avoids surgery. Finally, prophylactic measures and control should be used, which are the only guarantee to reduce the incidence of hydatidosis in our country and therefore the morbidity and cost.

## Conflict of interest

None.

## Acknowledgment

The authors thank Professor Mokhless Chaari for proofreading this article.

## References

- [1] Ameer A, Lezrek M, Boundin H, Touiti D, Abbar M, Beddouch AA. Hydatid cyst of the kidney: treatment about 34 cases. *Prog Urol* 2002;12:409–14.
- [2] Ben Abdallah R, Hajri M, Aoun K, Ayed M. Hydatid retro bladder, retroperitoneal and extrarenal cyst: descriptive study of 9 cases. *Prog Urol* 2000;10:424–31.
- [3] Chandra H, Dutt RL. Hydatid cyst of the spermatic cord. *Ind Med Gaz* 1951;86(February (2)):49–50.
- [4] Hakami M. An unusual case of hydatid cyst of spermatic cord. *Rev Med Moyen Orient* 1963;20(May–June):268–70.
- [5] Yurtçu M, Gündüz M, Toy H, Günel E. Spermatic Cord hydatid cyst: an unusual localization. *J Pediat Surg* 2007;42:E15–6.
- [6] Hamdane MM, Bougrine F, Msakni I, Dhaoui-Ghozzi A, Bouziani A. The hydatid cyst of the spermatic cord: an exceptional localization. *Pan Afr Med J* 2011;10:58.
- [7] Haouas N, Sahraoui W, Youssef A, Thabet I, Ben sorba N, Jaidane M, et al. Spermatic Cord hydatid cyst. *Prog Urol* 2006;16:499–501.
- [8] Hassine W, Dupuch K, Gharbi HA. Contribution of ultrasonography in hydatid disease of the liver in children: about 42 cases. *J Radiol* 1980;61:323–7.
- [9] Horchani A, Noura Y, Kbaïer I, Attyaoui F, Zribi AS. Hydatid cyst of the kidney: a report of 147 controlled cases. *Eur Urol* 2000;38:461–7.
- [10] Manterola C, Cuadra A, Munoz S, Sanhueza A, Bustos L, Vial M, et al. In a diagnostic test study the validity of three sero-diagnostic test was compared in patients with liver *Echinococcosis*. *J Clin Epidemiol* 2005;58:401–6.
- [11] Bennani S, El Mrini M, Raji A, Meziane F, Benjalloun S. Hydatid retro-bladder and retroperitoneal cysts isolated (about 5 cases). *Ann Urol* 1992;26:344–9.
- [12] Sherlock S. Hydatid disease: disease of liver and biliary system. Oxford: Blackwell Scientific Publications; 1981. p. 247–452.
- [13] Ben Brahim M, Nouri A, Ksia A, El Ezzi O, Krichene I, Mekki M, et al. Management of multiple echinococcosis in childhood with albendazole and surgery. *J Pediat surg* 2008;43:2024–30.
- [14] Morris DL, Gould SE. Serum and cyst concentrations of mebendazole and flubendazole in hydatid disease. *Br Med J Clin Res, Edinburgh* 1982;285:175.
- [15] Teggi A, Lastilla MG, Derossa F. Therapy of human hydatid disease with mebendazole and albendazole. *Antimicrob Agents Chemother* 1993;37:1679–84.
- [16] Milicevic MN, I Blumgart LH, Fong Y. Hydatid disease: surgery of liver and biliary tract. 3rd ed. London: WB Saunders Company Ltd.; 2000.