



Pan African Urological Surgeons' Association

African Journal of Urology

[www.ees.elsevier.com/afju](http://www.ees.elsevier.com/afju)  
[www.sciencedirect.com](http://www.sciencedirect.com)



## Case report

# Fibroepithelial polyps of the urethra in infants: A report of three cases



A. Ksia<sup>a,\*</sup>, M. Ben saad<sup>a</sup>, M. Mekki<sup>a</sup>, W. Mnari<sup>b</sup>, L. Sahnoun<sup>a</sup>,  
S. Sfar<sup>a</sup>, K. Maazoun<sup>a</sup>, J. Chahed<sup>a</sup>, I. Krichene<sup>a</sup>, M. Belghith<sup>a</sup>,  
A. Zakhama<sup>b</sup>, M. Golli<sup>c</sup>, A. Nouri<sup>a</sup>

<sup>a</sup> Department of Pediatric Surgery, Hospital Fattouma Bourguiba, Monastir, Tunisia

<sup>b</sup> Department of Radiology, Hospital Fattouma Bourguiba, Monastir, Tunisia

<sup>c</sup> Department of Anatomic-Pathology, Hospital Fattouma Bourguiba, Monastir, Tunisia

Received 27 September 2013; received in revised form 29 November 2013; accepted 1st December 2013

### KEYWORDS

Infant;  
Fibroepithelial polyp;  
Urinary retention;  
Benign tumor

### Abstract

Fibroepithelial polyps of the urethra (FEPUs) are rare entity in infancy. They are congenital benign tumors. Most patients present with acute retention, hematuria or intermittent bladder outlet obstruction. The treatment of choice is transurethral endoscopic resection. Histological study confirms the diagnosis and the prognosis is excellent.

We retrospectively reviewed the medical records of three male patients with fibroepithelial polyps of the urethra that were diagnosed and treated in the department of pediatric surgery of Monastir. The diagnosis was based on voiding cystourethrogram and cystourethroscopy. The treatment was endoscopic resection and histology confirmed the diagnosis in all cases.

© 2014 Pan African Urological Surgeons' Association. Production and hosting by Elsevier B.V. All rights reserved.

### Introduction

Fibroepithelial polyps of the urethra (FEPUs) are rare benign epithelial tumors, more frequently encountered in males and in the posterior urethra. In this paper, we report our experience with three patients having FEPUs (between January 2006 and December 2012) and discuss the etiology, clinical presentations, diagnosis, and treatment of these polyps.

### Case presentation

#### Case 1

A previously healthy 21 months old boy was admitted to our hospital for acute urinary retention. Clinical examination revealed a

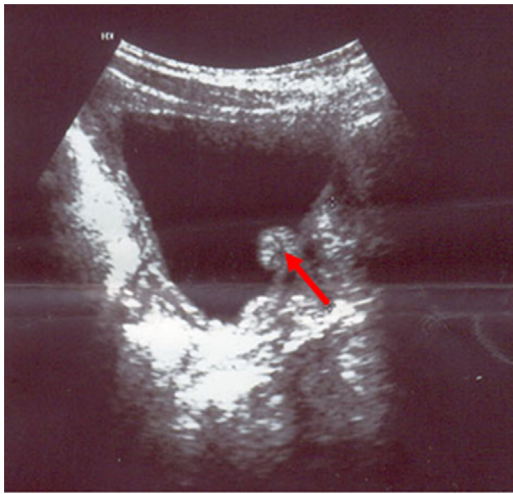
\* Corresponding author at: Department of Pediatric Surgery, Hospital Fattouma Bourguiba, 5000 Monastir, Tunisia. Tel.: +216 97523763; fax: +216 73460678.

E-mail address: [amineks@yahoo.fr](mailto:amineks@yahoo.fr) (A. Ksia).

Peer review under responsibility of Pan African Urological Surgeons' Association.



Production and hosting by Elsevier

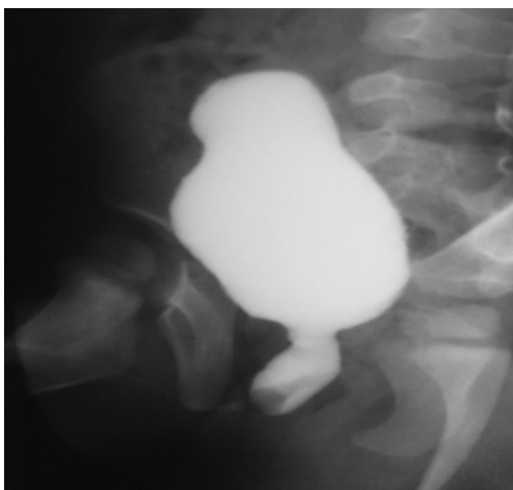


**Figure 1** Ultrasonography showing a polyp that extended to the bladder neck as nodular mobile hyperechoic nodular image.

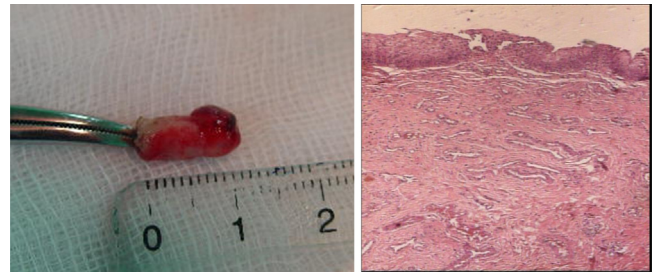
palpable urinary bladder. Ultrasonography showed a mobile polyp that extended to the bladder neck (Fig. 1). The bladder showed moderate trabeculation. Voiding cystourethrogram demonstrated pedunculated polyp showing as a filling defect in the posterior urethra (Fig. 2). Urthro-cystoscopy revealed a 10-mm-diameter pedunculated polyp attached to the wall of the urethra just distal to the verumontanum. Following transurethral resection of this polypoid mass, the diagnosis of a congenital fibroepithelial polyp of the urethra was rendered by pathologic examination that found that the polyp was covered by a transitional urothelium. The stroma consisted of loose connective tissue with bundles of smooth muscle and some small blood vessels (Fig. 3).

#### Case 2

A 17-month old male patient with a history of recurrent urinary infection presented to our department with dysuria. Urine analysis showed mild microscopic hematuria. Ultrasonography revealed a 9 mm nodular image in the bladder. Voiding cystourethrogram showed a filling defect in the posterior urethra (Fig. 4).



**Figure 2** Voiding cystourethrogram demonstrating a fibroepithelial polyp in proximal urethra with filling defects.



**Figure 3** Macroscopic and microscopic picture of the FEP.

Cystourethroscopy showed a pedunculated polyp based distally to the verumontanum (Fig. 5).

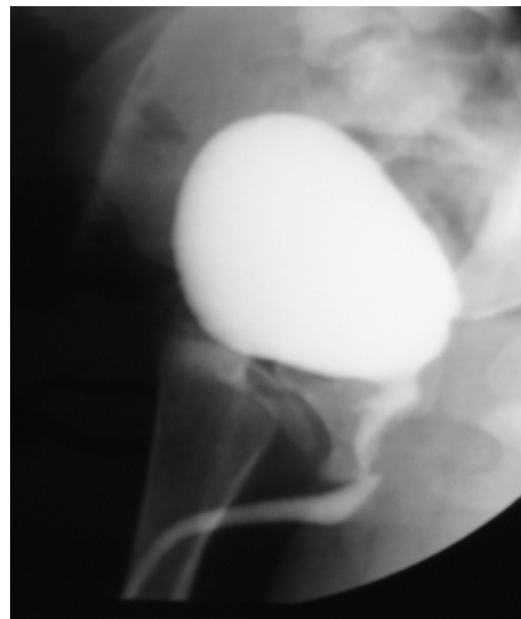
A transurethral resection was performed and the pathological diagnosis was of a fibroepithelial polyp of the urethra that consisted of fibrous stroma covered by a normal urothelium.

#### Case 3

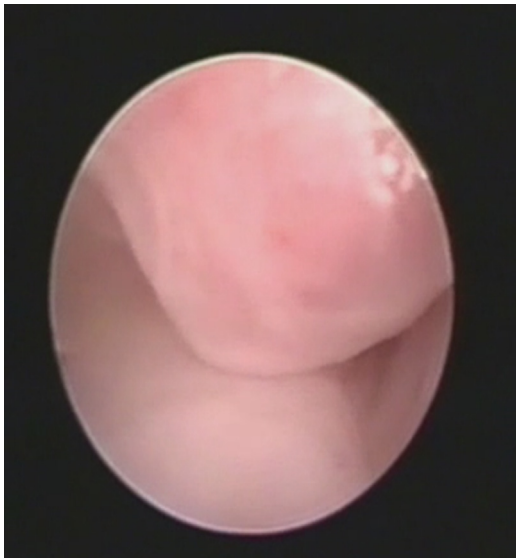
A 15-month-old boy with a history of dysuria presented to our department with urinary infection. Ultrasonography showed a small hyperechoic nodule in the bladder (Fig. 6). Voiding cystourethrogram revealed a 15 mm filling defect in the bladder neck (Fig. 7). The cystourethroscopy showed a pediculate polyp located distally from the verumontanum. The polyp was resected endoscopically and the histological analysis revealed that it was a fibroepithelial polyp of ureter that has a loose fibrovascular stroma and was covered by transitional epithelium. The follow-up was uneventful.

#### Discussion

Fibroepithelial polyps of the urethra (FEP) are rare congenital tumors arising from the mesodermal tissue in the ureteral wall [1].



**Figure 4** Voiding cystourethrogram showing a filling defect in the posterior urethra.



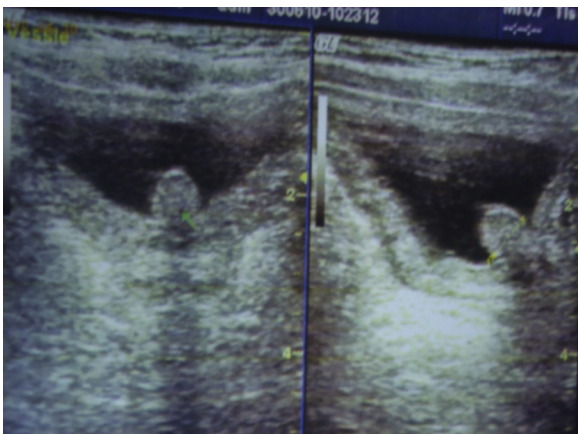
**Figure 5** Cystourethroscopy view showing a pedunculated polyp.

Their exact incidence is unknown. They may remain asymptomatic for years.

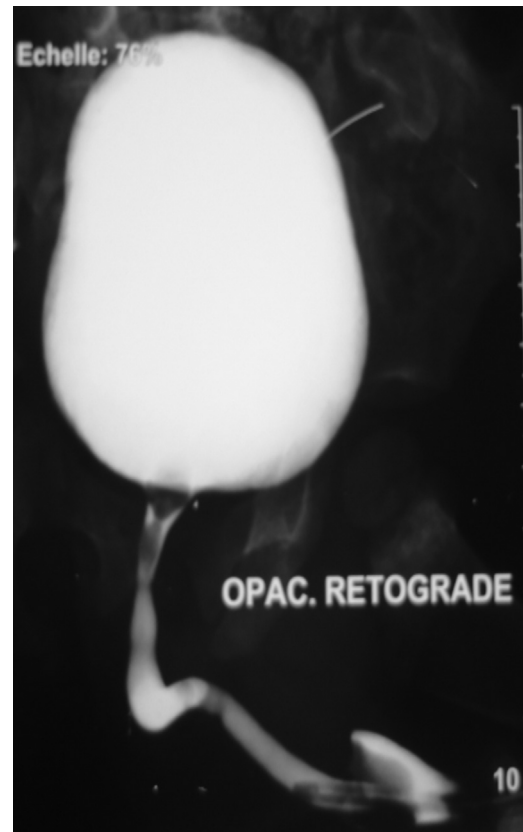
They are more common in boys than girls [2]. Most patients present with hematuria and obstructive urinary symptoms: dysuria, acute urinary retention, post void dribbling and urinary hesitancy. Other modes of presentation are recurrent urinary infection and painful interlabial mass in girls due to the prolapsing of a pedunculated polyp out of the external urethral meatus [3]. Most of lower tract urothelial polyps arise from posterior urethra. An anterior urethral location of polyps is very rare and more seen in girls.

The etiology of FEPUs has not been elucidated. Posterior urethral polyps are considered vestiges of Müller's tubercle that fail to regress, whereas anterior urethral polyps have all arisen from dorsal 12-o'clock position deep in the bulbar urethra. Anterior urethral polyps may be congenital or acquired [4].

Differential diagnosis of fibroepithelial polyps of the urethra are inflammatory polypoid lesions, pseudopolyps, embryonal rests, hamartomas and prolapsed ectopic ureterocele. In girls, prolapsing



**Figure 6** Ultrasonography showing a small *hyperechoic* nodule in the bladder.



**Figure 7** Voiding cystourethrogram revealing a filling defect in the bladder neck.

anterior urethral urothelial polyps can present like urethral prolapse, paraurethral Skene cysts, hydrometrocolpos, urothelial papilloma, rhabdomyosarcoma and botryoid sarcoma [5].

Urothelial polyps are benign. There is no association with malignant degeneration.

Histologically, FEPUs are polypoid lesions lined by transitional urothelium or squamous epithelium over a fibrovascular stalk [6].

Ultrasonography is a valuable tool of diagnosis. It can show the polyp as a mobile nodule. Voiding cystourethrogram provides the diagnosis in most cases showing a movable filling defect in the posterior urethra usually based near the verumontanum. On voiding cystourethrogram, mobility of the lesion is almost pathognomonic. FEPUs may be associated with varying degrees of hydronephrosis and vesico-ureteral reflux [7]. Cystourethroscopy confirms the diagnosis and allows the direct visualization of the lesion [8].

The treatment of choice is transurethral endoscopic resection [5,9]. The prognosis of fibroepithelial polyp of the urethra is excellent. No recurrences have been reported.

### Conclusion

Despite being uncommon, fibroepithelial polyps of the urethra should be kept in mind in case of acute urinary retention in infancy.

**Conflict of interest**

None.

**Acknowledgment**

This work was supported by the Tunisian Ministry of Scientific Research (scientific laboratory LR 12 SP 13).

**References**

- [1] Downs RA. Congenital polyps of the prostatic urethra. A review of the literature and report of two cases. *Br J Urol* 1970;42:76.
- [2] Yamashita T, Masuda H, Yano M, Kobayashi T, Kawano K, Kihara K. Female urethral fibroepithelial polyp with stricture. *J Urol* 2004;171:357.
- [3] Isaac J, Snow B, Lowichik A. Fibroepithelial polyp of the prostatic urethra in an adolescent. *J Pediatr Surg* 2006;41(December (12)):e29–31.
- [4] Sitapara A, Popat S. Urethral polyp in neonate: a rare occurrence. *J Pediatr Surg* 2005;40:E73–4.
- [5] Aita GA, Begliomini H, Demerval Jr M. Fibroepithelial polyp of the urethra. *Int Braz J Urol* 2005;31(2):155–6.
- [6] Tokunaga S, Shirai K. Benign prostatic epithelial polyp of urethra. *Urology* 1987;29(January (1)):73–5.
- [7] Stadaas JO. Pedunculated polyp of posterior urethra in children causing reflux and hydronephrosis. *J Pediatr Surg* 1973;8(August (4)): 517–21.
- [8] Demircan M, Ceran C, Karaman A, Uguralp S, Mizrak B. Urethral polyps in children: a review of the literature and report of two cases. *Int J Urol* 2006;13:841–3.
- [9] Carey RL, Bird VG. Endoscopic management of 10 separate fibroepithelial polyps arising in a single ureter. *Urology* 2006;67:413–5.