



Pan African Urological Surgeons' Association

African Journal of Urology

[www.ees.elsevier.com/afju](http://www.ees.elsevier.com/afju)  
[www.sciencedirect.com](http://www.sciencedirect.com)



## Case report

# Testicular tuberculosis in an HIV positive patient mimicking malignancy: A case report



B.A. Ojo<sup>a,\*</sup>, E.I. Ogwuche<sup>b</sup>, B.M. Duduyemi<sup>c</sup>, C. Okani<sup>a</sup>,  
E.O. Umobong<sup>d</sup>, G.T.A. Jombo<sup>e</sup>

<sup>a</sup> Department of Anatomical Pathology, College of Health Science, Benue State University, Makurdi, Nigeria

<sup>b</sup> Department of Surgery, College of Health-Sciences Benue State University, Makurdi, Nigeria

<sup>c</sup> Department of Anatomic Pathology, College of Medicine, Ekiti State University, Ado-Ekiti, Nigeria

<sup>d</sup> Department of Laboratory Medicine, State House Medical Centre, Abuja, Nigeria

<sup>e</sup> Department of Medical Microbiology and Parasitology, College of Health Sciences, Benue State University, Makurdi, Nigeria

Received 28 June 2013; received in revised form 13 November 2013; accepted 15 November 2013

### KEYWORDS

Tuberculosis;  
Testicular swelling;  
Human Immune Deficiency  
Virus (HIV)

### Abstract

With the upsurge of tuberculosis infection compounded by the pandemic Human Immune Deficiency Virus (HIV), isolated testicular tuberculosis though a rarity, should be a differential diagnosis especially in the atypical age group of patients presenting with testicular swelling and in areas with high prevalence rate for tuberculosis.

We present a 22 years old male with a year history of progressively increasing painless left testicular swelling with no constitutional symptoms. Both the ultrasound imaging study and fine needle aspiration cytology were equivocal. Diagnosis was established at surgical pathology after a left transinguinal orchidectomy. In areas endemic for tuberculosis an infective aetiology should always be considered for a testicular mass.

© 2014 Pan African Urological Surgeons' Association. Production and hosting by Elsevier B.V. All rights reserved.

### Introduction

While genitourinary tuberculosis (TB) is the most common extra pulmonary site of tuberculosis [1,2], isolated TB orchitis without epididymal involvement is rare [3]. The kidney is the most commonly affected genitourinary organ [4]. Tuberculous infections of the scrotum are rare and occur in approximately 70% of patients with extra pulmonary disease [5]. When the scrotal content is involved, the epididymis is the most frequent site, with epididymo-orchitis as the usual presentation [6,7]. Orchitis without epididymal involvement is rare [4].

\* Corresponding author. Tel.: +234 8050773926.

E-mail address: [babarinde@yahoo.com](mailto:babarinde@yahoo.com) (B.A. Ojo).

Peer review under responsibility of Pan African Urological Surgeons' Association.



Production and hosting by Elsevier

By the 1980s, the availability of antituberculosis chemotherapy reduced the incidence and prevalence of tuberculosis. Changing pattern of population emigration and the development of large-pools of immuno-compromised individuals reversed the downward trend of tuberculosis [2]. Genitourinary involvement can be found in extensive pulmonary tuberculous disease or present as a primary genital lesions [1]. The incidence of TB infection of scrotal content is increasing in association with HIV. The patient with TB may have genital diseases that simulate sexually transmitted diseases or scrotal tumours. Awareness of environmental factors and patient history should alert the urologist to the wide array of clinical findings in the genitourinary system that can be caused by tuberculosis.

### Case report

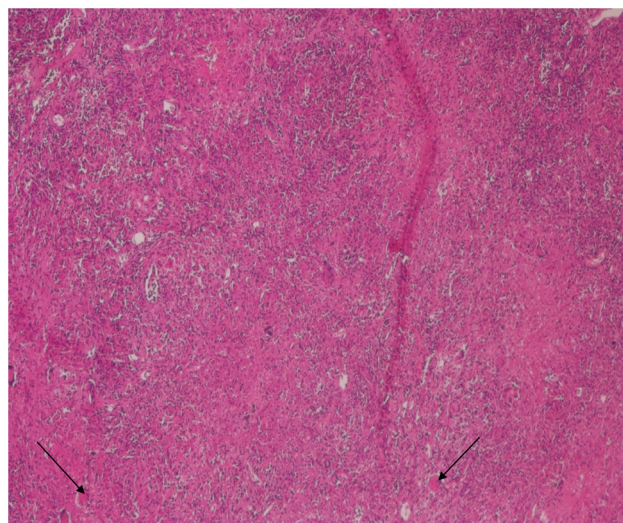
A 22-year-old male presented with a progressively increasing painless left testicular swelling of one year duration. There was no associated history of cough, fever or loss of appetite. He noticed weight loss but cannot quantify its extent. He went to a peripheral hospital where he was operated on, and same week, the swelling increased in size with associated pain in the contra lateral testis. The general examination was unremarkable. Upon genital examination, there was a left testicular mass measuring 8.00 cm × 6.00 cm. There was a 1 cm long healing scar at the root of the left scrotal wall. This was from the attempted solution to the mass by non qualified medical personnel. The right testis was also enlarged with a cystic mass and area of firm consistency and tenderness. Both epididymes were clinically normal.

The PCV was 30% and ESR was 75 mm in 1 h. Patient was reactive for HIV, negative for Hepatitis C virus and had a positive serology test for Hepatitis B surface antigen. Urinalysis was normal. Fine needle aspiration cytology result was inconclusive. Scrotal ultrasound revealed an enlarged left testis measuring 6.34 cm × 3.89 cm with no focal mass within it. The right testis measured 3.93 cm × 2.42 cm with normal echo texture. Fluids with septations were seen in the scrotal mass, worse around the right testis. The epididymis appeared normal. An ultrasound diagnosis of enlarged left testis with bilateral hydrocoele was made.

A clinical assessment of left testicular malignancy was made and he was scheduled for scrotal exploration and left transinguinal orchidectomy. Findings at operation included grossly enlarged left testis measuring 12 cm in its largest diameter with its capsule adherent to the skin. Post-op surgical pathology revealed a caseating granulomatous lesion consistent with TB orchitis. The testicular parenchyma was completely replaced by caseating granulomas consisting of epithelioid histocytes, and Langhans multinucleated giant cells surrounded by plasma cells and lymphocytes (Fig. 1). The granulomatous infiltrate extended into the spermatic cord (Fig. 2).

### Discussion

Tuberculosis still remains a major disease worldwide and this is being compounded by HIV pandemic that has now made it a common opportunistic infection. Our patient was positive for HIV. Scrotal tuberculosis usually affects men between ages 20 and 70 years [8,9]. Our patient age is 22 years. Patients may present with painful or painless enlargement of the scrotum [10]. He presented with painless scrotal mass of one year duration.

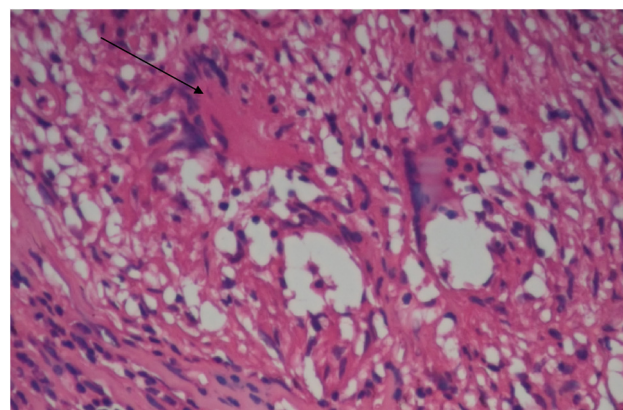


**Figure 1** Section shows chronic granulomatous inflammation with Langhans giant cells (arrow) consistent with TB orchitis (H&E×40).

The epididymes is the most common site of genital tuberculosis [6–8,11]. Testicular involvement is rare but can occur if there are extensive epididymal masses or abscesses [7]. Orchitis without epididymal involvement is rare [4,12].

Scrotal involvement in tuberculosis is typically haematogenous from a primary source which is usually the lung or kidney. Retrograde extension from the prostate and seminal vesicles to the epididymis and testicles may also occur [13]. Pathologically, the earliest lesions are seen as discrete or conglomerate yellowish necrotic areas in the tail of the epididymis. From here it could extend to the testis. Mycobacterium tuberculosis resulting from haematogenous spread without epididymal involvement is rare [12].

The major clinical differential diagnosis of scrotal mass with or without pain is inflammatory processes, torsions, and testicular tumour. Ultrasound is currently the imaging modality of choice when evaluating the scrotum and its content [14]. The ultrasound pattern of tuberculous orchitis includes diffusely enlarged heterogeneously hypo echoic testis, diffusely enlarged homogeneously hypo echoic testis, nodular enlarged heterogeneously hypo echoic testis, and presence of multiple small hypo echoic nodules in an enlarged testis (miliary pattern) [11,15–17].



**Figure 2** Section of the spermatic cord showing typical horse-shoe shaped Langhan's giant cells (arrow) consistent with TB (H&E×100).

At ultrasonography, testicular tumour appears as discrete masses or the entire testis may be involved diffusely or heterogeneously hypoechoic texture. Seminomas and lymphomas tend to be homogenous, while non-seminomatous tumours tend to be heterogeneous [10,18].

The presence of epididymal enlargement in conjunction with a testicular lesion is suggestive of an infection rather than a neoplastic case at ultrasonography. Ultrasonographic appearances of testicular torsion are variable, and depend on the duration of torsion. In the acute phase, the testis is enlarged and diffusely hypoechoic. Later, the testis may appear heterogeneous due to haemorrhage and necrosis. Reactive hydrocoele and skin thickening may also occur. In such circumstances, colour Doppler ultrasound is useful, as blood flow within subjects with testicular torsion is reduced or absent, whereas, it is increased in subjects with inflamed testis [19,20]. Generally with careful interpretation of ultrasound images, differentiation of testicular tumour and testicular torsion caused by infection is not difficult [10]. The ultrasound report for our patient was equivocal. When ultrasound imaging is equivocal, MRI may represent as efficient supplemental technique owing to its wide field of multiplanar capabilities and intrinsic high contrast [21]. We do not have MRI facility in our centre.

Kundu et al. [22] have reported a case of testicular TB diagnosed by fine needle aspirations cytology. Our aspiration cytology result though suggesting an inflammatory process was not conclusive.

Because the patient's presentation typically mimics a testicular tumour, patient did not have any constitutional symptoms of TB, left transinguinal orchidectomy was done and surgical pathology report confirmed TB orchitis.

A search for the primary source was negative. Kumar et al. [23] have reported a case of acquired immune deficiency syndrome (AIDS) presenting as testicular TB. Our patient was last seen about four months post operation. Except for a small area of discharging exudates from the surgical site, he was doing fine. He was subsequently enrolled into the Highly Active Antiretroviral Therapy (HAART) clinic. It is at this clinic that patients are started on anti-retroviral and anti TB therapy. He is yet to keep an appointment at the clinic.

With the upsurge of TB in our environment, compounded by HIV pandemics, the isolated testicular tuberculosis though a rare condition, should be considered when assessing focal abnormalities of the testis. Definitive diagnosis of tuberculosis although established by culture, histology or surgical examination, is often difficult and delayed. In the atypical age group of patients presenting with testicular swelling in areas with high prevention rate for tuberculosis, infective aetiology should be considered.

#### Conflict of interest

None.

#### Acknowledgement

We are grateful to the Departments of Surgery and Histopathology, Benue State University Teaching Hospital, Makurdi, Nigeria for allowing us access to their data and patient.

#### References

- [1] Chirindel A, Martinez F, Gaglidardi JA, Armm MF. Testicular tuberculosis without epididymitis simulating neoplasm. *Radiol Case Rep (Online)* 2008;3:133.
- [2] Wise GJ, Marrella VK. urinary manifestation of tuberculosis. *Urol Clin North Am Genit* 2003;30(1):111–21.
- [3] McAleer SJ, Johnson CW, Johnson Jr WD. Tuberculosis and parasitic and fungal infections of the genitourinary system. *Campbell-Walsh Urology*, vol. 1, 9th ed. Canada: Elsevier; 2007. p. 1440.
- [4] Madeb R, Marshall J, Nativ O, Erturk E. Epididymal tuberculosis. *Urology* 2005;65:798.
- [5] Druid FM, Laghi A, Iannicelli E, Di Nardo R, Occhiato R, Poggi R, et al. Tubercular epididymitis and orchitis: US patterns. *Eur Radiol* 1997;7:1076–8.
- [6] Engin G, Acunas B, Acunas G, Tunaci M. Imaging of extrapulmonary tuberculosis. *Radiographics* 2000;20:471–88.
- [7] Chung JJ, Kim MJ, Lee T, Yoo HS, Lee JT. Sonographic findings in tuberculosis epididymitis and epididymis orchitis. *J Clin Ultrasound* 1997;25:390–4.
- [8] Ferrie BG, Roundle JS. Tuberculosis epididymo-orchitis. A review of 20 cases. *Br J Urol* 1993;55:437–9.
- [9] Heaton ND, Hogan B, Michell M, Thomson P, Yates-Bell AJ. Tuberculosis epididymo-orchitis: clinical and ultrasound observations. *Br J Urol* 1989;64:305–9.
- [10] Mottarak MM, Peh WCG. Case 91: tuberculosis epididymo-orchitis. *Radiology* 2006;238:748–51.
- [11] Kumar V, Abbas Ak, Fausto N. The lower urinary tract and male genital tract: pathologic Basic of Disease. 7th ed. Saunders: Elsevier; 2005. p. 1039.
- [12] Tessler FN, Tublin ME, Rifkin MD. US case of the day. Tuberculosis epididymo-orchitis. *Radiographics* 1998;18:251–3.
- [13] Jaffar A, Mehta JB, Godfrey JH. Tuberculosis epididymo-orchitis and granulomatous prostatitis mimicking neoplasia. *J Tenn Med Assoc* 1990;83:605–6.
- [14] Dogra VS, Gottlieb RH, Oka M, Rubens DJ. Sonography of the scrotum. *Radiology* 2003;227:1836.
- [15] Muttark M, Peh WC, Lojanapiwat B, Chaiwun B. Tuberculosis epididymitis and epididymo-orchitis: sonographic appearances. *AJR Am J Roentgenol* 2001;176:1459–66.
- [16] Kim SH, Pllack HM, Cho KS, Pollack MS, Han MC. Tuberculosis epididymitis and epididymo-orchitis, sonographic findings. *J Urol* 1993;150:81–4.
- [17] Briceno-Garcia EM, Gomez-Pardal A, Alvarez-Bustos G, Artero-Muñoz I, Molinero MM, Seara-Valero R, et al. Tuberculous orchiepididymitis after BCG therapy for bladder cancer. *J Ultrasound Med* 2007;26:977–9.
- [18] Nachtsheim DA, Schieible FW, Gosink B. Ultrasonography of testis tumours. *J Urol* 1983;129:978–81.
- [19] Pavliva P, Barozzi L. Imaging of the acute scrotum. *Eur Radiol* 2001;11:220–8.
- [20] Martin B, Conte BJ. Ultrasonography of acute Scrotum. *J Clin Ultrasound* 1987;15:37–44.
- [21] Cramer BM, Schegel EA, Thueroff JW. MR imaging in the differential diagnosis of scrotal and testicular disease. *Radiographics* 1991;11:9–21.
- [22] Kundu S, Sengupta A, Dey A, Thakur SB. Testicular tuberculosis mimicking malignancy. *J Indian Med Assoc* 2003;101:240–5.
- [23] Kumar P, Shashikala P, Chandrashekar HR, Alva NK. Acquired immunodeficiency syndrome presenting as testicular tuberculosis. *J Assoc Physicians India* 2000;48:1111–2.