

Case Report

Prostatic Duct Adenocarcinoma with Endometrioid Features: Report of a Rare Case and Brief Review of the Literature

E. Bekar¹, T. Yalta¹ and S. Erdil²

Departments of ¹Pathology and ²Urology, Sivas State Hospital, Sivas, Turkey

ABSTRACT

We report the case of a 78-year-old male patient who presented with dysuria and lower urinary tract symptoms (LUTS). After routine blood and urine analysis, the patient underwent ultrasonography which revealed a hypertrophied and inhomogenous prostate extending to the bladder neck. Open biopsy from the bladder neck was performed. The histopathological findings were found to be consistent with prostatic duct adenocarcinoma with endometrioid features.

Key Words: Prostate, duct, carcinoma, endometrioid, lower urinary tract symptoms (LUTS), dysuria

Corresponding Author: Dr. Tulin Yalta, Pathology Department, Sivas State Hospital, Sivas, 58100, Turkey, Email: tdeyalta@gmail.com

Article Info : Date received: 21/4/2009

Date accepted (after revision): 30/12/2009

INTRODUCTION

Prostatic duct adenocarcinoma with endometrioid features (PDAE) is a very rare tumor which is thought to arise from the prostatic utricle (a Müllerian remnant analogous to the female uterus and vagina)¹. Lower urinary tract symptoms (LUTS) are the most common presentation.

CASE REPORT

A 78-year-old man was admitted to our clinic with dysuria and LUTS. Routine physical examination and serum biochemistry were normal. Urinalysis revealed proteinuria and hematuria. Total prostate specific antigen (PSA) was 15.29 ng/ml while free PSA was 6.47 ng/ml. Ultrasonography demonstrated an inhomogenous prostate measuring 40 x 47 x 59 mm with an irregular surface and prostatic tissue extending to the bladder neck. Open bladder neck biopsy was performed. Macroscopically, there were brownish tissue fragments weighing about 6 grams. Histological examination demonstrated closely packed glandular structures lined by pseudostratified, tall columnar cells with

papillary projections and intraglandular bridging, consistent with PDAE (Fig 1).

DISCUSSION

PDAE has long been considered to originate from the Müllerian remnant. However, Ro et al. have suggested that this entity should be accepted as an adenocarcinoma of prostatic duct origin². Zaloudek et al. pointed out that the presence of strong acid phosphatase staining and multi-vacuolated, lysosome containing tumor cells strongly suggests a prostatic duct origin³. Therefore, the term 'ductal adenocarcinoma' has been suggested.

The histopathology of ductal adenocarcinoma is generally characterized by a cribriform pattern with large slit-like lumina, tall columnar cells and papillary fronds with fibrovascular cores. The gland structures in these tumors are significantly larger than in common acinar carcinoma⁴. Since the term 'endometrial carcinoma arising from the prostatic utricle' was initially coined, there has been growing evidence that the presence

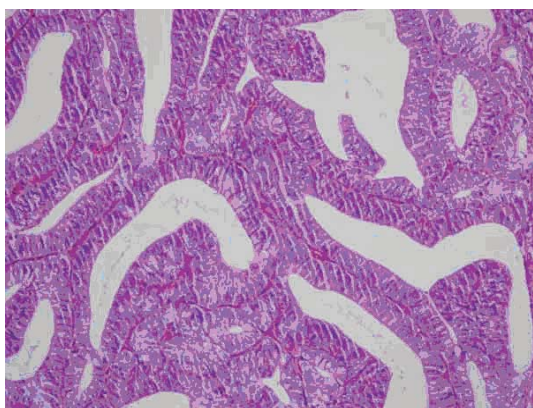


Fig. 1: Photomicrograph showing prostatic duct adenocarcinoma with endometrioid features (HE 50X).

of cribriform pattern in prostate cancers may indicate a proclivity to intraductal invasion⁴.

In contrast to malignant lesions, benign proliferative lesions of the prostate are characterized by the presence of basal cells. However, some cases of cribriform carcinoma comprising Gleason 3 and 4 histopathological grades have been demonstrated to have basal cells on immunohistochemistry⁴. Therefore, a cribriform carcinoma without basal cells may be interpreted as an invasive carcinoma with Gleason pattern 3 or 4, whereas it is generally termed high-grade prostatic intraepithelial neoplasia (HG-PIN) in the presence of basal cells⁴. The identification of basal cells is clinically important, and may help rule out infiltrating acinar prostatic adenocarcinoma⁵. PDAE has a patchy basal cell layer and immunohistochemically expresses PSA⁶. It is mostly equivalent to Gleason pattern 4⁶.

There are few case reports of this entity in the literature. Hideto et al. reported a 58-year-old man with PDAE leading to symptoms of hematuria and bladder outlet obstruction¹. Fukui et al. reported a 64-year-old man with the same tumor who underwent total cystoprostatectomy and urethrectomy⁷. This tumor has highly aggressive clinical behavior with high local recurrence rates⁴. The 5-year survival rate is 24% for adenocarcinomas that invade peripheral prostatic ducts⁸. Though surgery is the mainstay of treatment, external beam radiotherapy (EBR) has emerged as an important adjunctive modality. Androgen deprivation therapy may provide palliation⁹.

Eade et al. reported successful clinical outcomes with EBR in a series of 6 patients, in which 5 were treated definitively and the sixth patient was treated for local recurrence after radical prostatectomy¹⁰.

This case demonstrates the importance of thorough investigation of LUTS, where the differential diagnosis includes infection, stone disease or tumor, which may on occasion be a rare entity such as PDAE¹¹.

REFERENCES

1. Hideto S, Mitsuko H, Takehiko I, Mayumi O, Takashi Y, Yasuhiko K, et al. A case of endometrioid carcinoma of the prostate. Cytological features of exfoliative cells in urine collected by catheterization in the urinary bladder. *J.Japanese Soc.Clin.Cytol.* 2002;41(3):186-9.
2. Ro JY, Ayala AG, Wishnow KI, Ordenez NG. Prostatic duct adenocarcinoma with endometrioid features: Immunohistochemical and electron microscopic study. *Semin.Diagn.Pathol.* 1988; Aug;5(3):301-11.
3. Zaloudek C, Williams JW, Kempson RL. «Endometrial» adenocarcinoma of the prostate: A distinctive tumor of probable prostatic duct origin. *Cancer.* 1976; May;37(5):2255-62.
4. Cohen RJ, Wheeler TM, Bonkhoff H, Rubin MA. A proposal on the identification, histologic reporting and implications of intraductal prostatic carcinoma. *Arch. Pathol.Lab.Med.* 2007; Jul;131(7):1103-9.
5. Guo CC, Epstein JI. Intraductal carcinoma of the prostate on needle biopsy: Histologic features and clinical significance. *Mod.Pathol.* 2006; Dec;19(12):1528-35.
6. Epstein JI. Prostatic ductal adenocarcinoma: A mini review. *Med.Princ.Pract.* 2010;19(1):82-5.
7. Fukui J, Kiyota A, Nishikawa K, Nishimoto K, Nishio S, Maekawa T, et al. [A case of endometrioid carcinoma of the prostate]. *Hinyokika Kiyo.* 1998; May;44(5):335-7.
8. Colpaert C, Gentens P, Van Marck E. Ductal («endometrioid») adenocarcinoma of the prostate. *Acta Urol.Belg.* 1998; Dec;66(4):29-32.
9. Cheng CJ, Chen KC, Chen WY, Su SJ. Ductal adenocarcinoma of the prostate with endometrioid features in a 69-year-old man. *J.Formos.Med.Assoc.* 2001; Oct;100(10):707-11.
10. Eade TN, Al Saleem T, Horwitz EM, Buyyounouski MK, Chen DY, Pollack A. Role of radiotherapy in ductal (endometrioid) carcinoma of the prostate. *Cancer.* 2007; May 15;109(10):2011-5.
11. Tarcan T. Differential diagnosis of lower urinary tract symptoms in men. *Turk. Klin. J. Surg. Med. Sci.* 2005;1(1):30-7.