

ERRATUM

Rajasekaran et al., Afr., J. Tradit Complement Altern Med. 2013; 10(1): 102–112

Published online 2012 Oct 1.

doi: 10.4314/ajtcam.v10i1.14

PROAPOPTOTIC, ANTI-CELL PROLIFERATIVE, ANTI-INFLAMMATORY AND ANTI-ANGIOGENIC POTENTIAL OF CARNOSIC ACID DURING 7,12 DIMETHYLBENZ[A]ANTHRACENE-INDUCED HAMSTER BUCCAL POUCH CARCINOGENESIS

Rajasekaran D¹, Manoharan S¹, Silvan S¹, Vasudevan K², Baskaran N¹, Palanimuthu D¹

¹Department of Biochemistry and Biotechnology, Faculty of Science, Annamalai University, Annamalainagar, Tamil Nadu, India, ²Department of Zoology, Faculty of Science, Annamalai University, Annamalainagar, Tamil Nadu, India

Corresponding author's E-mail: rasmanshisak@gmail.com, sakshiman@rediffmail.com

In the above mentioned article initially published, some of the images in the figure 1 (**Panel A**: Image A- PCNA expression in control; **Panel-D**: Images M and P – Bax expression in control and carnosic acid alone; **Panel-E**: Image Q-VEGF expression in control) are noticed as incorrect due to possible overlapping between the images. The corrected figure 1 has been now included to rectify this inadvertent error. The authors assure that this correction does not affect the ethics, original findings, discussion or conclusions of the published article.

Figure 1: Images with error

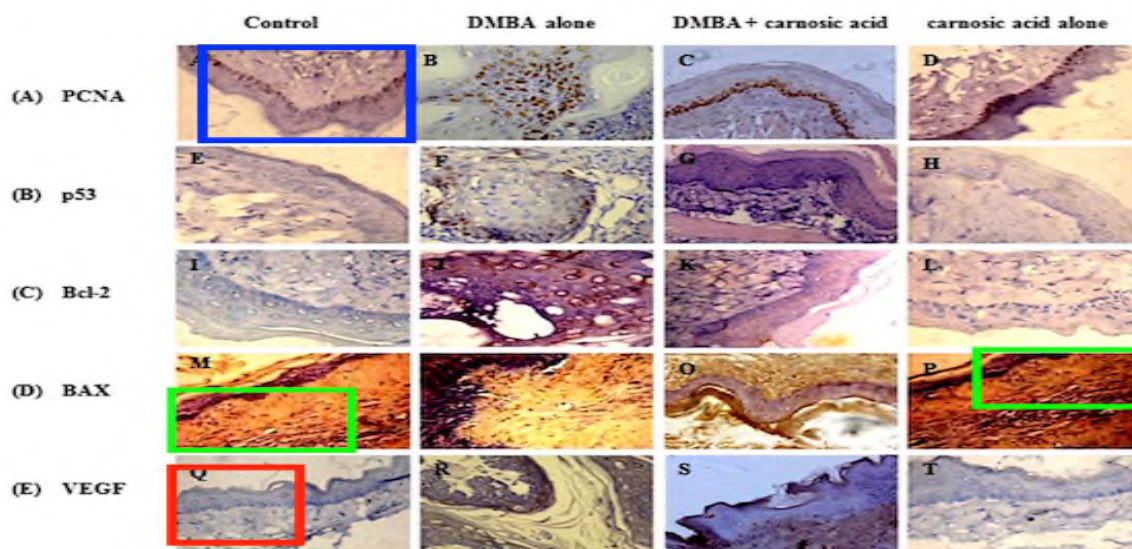


Figure 1: Corrected images

