

REDUCTION OF INTRA-ARTICULAR ADHESION BY TOPICAL APPLICATION OF DAIDZEIN
FOLLOWING KNEE SURGERY IN RABBITS

Xiangchun Liu^{1*}, Heng Jia², Hongsheng Xia³

¹Orthopedics Department, Dongzhimen Hospital, Beijing University of Chinese Medicine, Beijing 100007, China. ²Department of Joint Surgery, Chinese Medicine Hospital of the Xinjiang Uygur Autonomous Region, Urumqi 830000. ³Orthopedics Department, Huguosi Hospital Beijing University of Chinese Medicine, Beijing 100035, China.

*Corresponding Author Email: xiangchunliu43@hotmail.com

Abstract

Background: Intra-articular adhesion is the commonest complication that is faced by orthopedic surgeons after knee surgery. Thus, the present investigation evaluates the effect of daidzein on intra-articular adhesion in rabbits.

Material and methods: All the rabbits were separated in to four different groups each group carries ten rabbits. Cancellous bone was exposed in each rabbit by removing cortical bone from both side of the femoral condyle. Following daidzein (2.5, 5 and 10 mg/ml) was topically applied for the duration of 10 min to the decorticated areas. Thereafter for the period of 4 week surgical limb was fixed. Effect of daidzein on intra articular adhesion was estimated by visual score through macroscopic examination, histopathology study, hydroxyproline content, fibroblast and collagen density.

Results: Data obtained in the study suggest that topical application of daidzein (5 and 10 mg/ml) loose the collagen and significantly decreases the adhesion at the decorticated areas. Moreover there were significant reduction in the fibroblast density, hydroxyproline content and optical density of collagen tissue in daidzein (5 and 10 mg/ml) treated group than control.

Conclusion: Thus present study concludes that topical application of daidzein reduces intra-articular adhesion around the knee.

Keywords: Daidzein, articular adhesion, fibroblast, chondrocyte

Introduction

The commonest complication and challenge faced by orthopedic surgeons after knee surgery is intra-articular adhesion (Kocaoglu et al, 2011). Exact mechanism of formation of adhesion is not understood. Injury result in increase in stimulation and migration of fibroblast and cytokines at the same site and thus start the production of extracellular matrix and collagen, which forms adhesion and scar (Hayashi et al, 2004; Hildebrand et al, 2008; Monument et al, 2012). It is observed that intra articular adhesion alters the functions of knee by cartilage degeneration, stiffness, and arthralgia, all these event results in the surgery failure (Li et al, 2013).

Treatment for intra-articular adhesion is not yet accepted throughout the globe. Lots of methods are available for intra articular adhesion prevention such as hyaluronan derivative gel, administration of corticosteroid, mitomycin C application and arthroscopic lysis of adhesions (Jerosch & Aldawoudy, 2007; Liu et al, 2008; Riccio et al, 2010). But intra articular adhesion was not able prevent by any of these methods completely.

Isoflavones are known to produce strong antioxidant and anti-inflammatory activities, moreover, isoflavones, like daidzein and genistein, have been reported to have similar effects as those of estrogen (Hämäläinen et al, 2007). Daidzein is an isoflavones isolated from *Pueraria lobata* (Fabaceae) (Fedoreyev et al, 2000). Literature suggested that daidzein was used for the management of alcohol dependence and neurodegenerative disorders on the basis of its antioxidant and anti-inflammatory property (Rezvani et al, 2003; Zhao et al, 2008). Daidzein inhibits the pro inflammatory mediators by inhibits the activation of NF- κ B and STAT-1 (Hämäläinen et al, 2007). Thus, present investigation evaluates the effect of daidzein on intra articular adhesion after knee surgery.

Material and Methods

Animal

New Zealand rabbits (3-4 kg) were used in this study. All the rabbits were kept in the standard laboratory condition of a 12-hour light-dark cycle and room temperature 20 to 25°C. Rabbits were kept in the lab 10 days before the experiment to acclimatize to the environment. All the rabbits were kept under an environmental condition given in the guidelines. All the protocols used in this study were approved by animal ethical committee of Dongzhimen Hospital Beijing University of Chinese Medicine, China.

Experimental design

All the rabbits were divided into four groups (n=10) such as Control group: treated with vehicle; daidzein treated groups which receives 2.5, 5 and 10 mg/ml dose in different group. In this study intra articular adhesion was produced in as per the previously reported study. 20 % of urethane was administered intravenously to produce anesthesia in all the rabbits used in this investigation. Later fur was removed from the knee and iodophor was used to sterilize it. Medial parapatellar method was used to expose the knee from lateral and medial side of the femoral condyle. Further cancellous bone was exposed using dental burr by removing cortical bone from both side of the femoral condyle. Thereafter 2.5, 5 and 10 mg/ml of daidzein soaked cotton were applied for 10 min on the decorticated area and later cotton was withdrawn from it. Silk suture was used to close skin and articular capsule. Kirschner wires were used to immobilize extra-articular knee-joint of surgical limb for the duration of 4 weeks. All the rabbits were kept in the cage individually and free access to standard chow and water.

Evaluation of microscopic characteristics of joint

Microscopic evaluation was done on randomly selected six rabbits from each group. All the selected rabbits were anesthetized by intravenous injection of urethane and assessment of intra articular adhesion was done on the basis of below given scoring (Table 1).

Table 1: Visual scoring pattern

| Score | Pattern of intra articular adhesion |
|-------|---|
| 1 | No intra articular adhesion |
| 2 | Weak, mild, filmy adhesions that were eliminated by minimal manual traction |
| 3 | Moderate adhesions that were eliminated by manual traction |
| 4 | Dense and firm adhesions that had to be removed surgically |

Estimation of hydroxyproline content

Macroscopic assessment was done by estimating the hydroxyproline content in the rabbit. Hydroxyproline content was estimated in the scar tissue of the decorticated areas as per the previously reported studies. In this study scar tissue of 20 mg wet weight was taken from decorticated area of knee and lyophilized ground, and hydrolyzed for 12 hr at 130 °C with HCl (6 mol/l). NaOH was used to neutralize the sample and methyl red was used as an indicator. Later in standard and test sample 1 ml of chloramine T solution was added and incubated at room temperature for the duration of 20 min. thereafter in standard and test sample 1 ml of β -dimethylaminobenzaldehyde was added and absorbance was estimated at a wavelength of 550 nm.

Histopathological study

Post operation four rabbits from each group were used for the histological study. All the selected rabbits were sacrificed, knee joints completely removed with connective tissue and fibrotic adhesive scar tissue. Formaldehyde solution (10%) was used to fix the sample. Cal-Ex II solution was used for 1 week for decalcification and dehydration of samples. Later all the samples were embedded in paraffin and sample of 5- μ m axial sections was used.

Hematoxylin-eosin (H&E) staining was used to stain six even numbers of sections of each sample. Evaluation of intra articular adhesion was achieved at 200 \times . Fibroblast count in every section was defined as the average count from 3 different fields randomly selected at the margins and in the middle of the decorticated sites within every section. Density of fibroblast was quantified by performing vimentin immunohistochemistry. The number of vimentin was estimated as three areas were selected.

Masson's trichrome staining was used to stain seven odd-numbers of sections of each sample and light microscope was used for the estimation of fibrous adhesion at 200 \times . Densitometric analysis of collagen tissue was also performed. Presence of fibers at the surface of the knee articular cartilage was confirmed the fibrous adhesion positive.

Statistical analysis

Data of given manuscript represented as mean \pm SD (n=10). All the results were analyzed statistically by one way ANOVA and post hoc study by Dunnett. In this study values $p < 0.05$ was considered as significant.

Result

Effect of daidzein on microscopic characteristic of joints

Effects of daidzein on microscopic characteristics of joints are shown in Fig. 1. It was observed that topical application of daidzein at a dose of 5 and 10 mg/ml significantly ($p < 0.05$) decreases the visual scoring as there is alteration in the microscopic characteristics of the joint compared to control group.

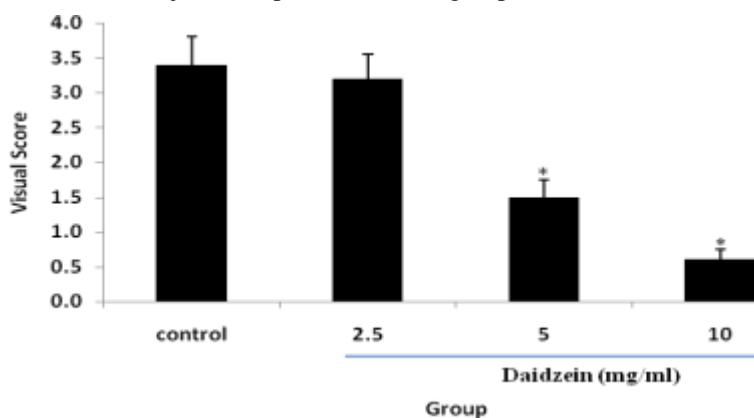


Figure 1: Effect of daidzein on visual score of microscopic characteristic of joints
Values are means \pm SD; * $p < 0.05$ (vs. Control group)

Effect of daidzein on hydroxyproline content

Effect of daidzein on hydroxyproline content in the scar tissues of rabbit is shown in Fig 2. There were significant ($p < 0.05$) decrease in the hydroxyproline content in daidzein (5 and 10 mg/ml) treated rabbits compared to control group. Hydroxyproline content decreases in daidzein treated groups in a dose dependent manner.

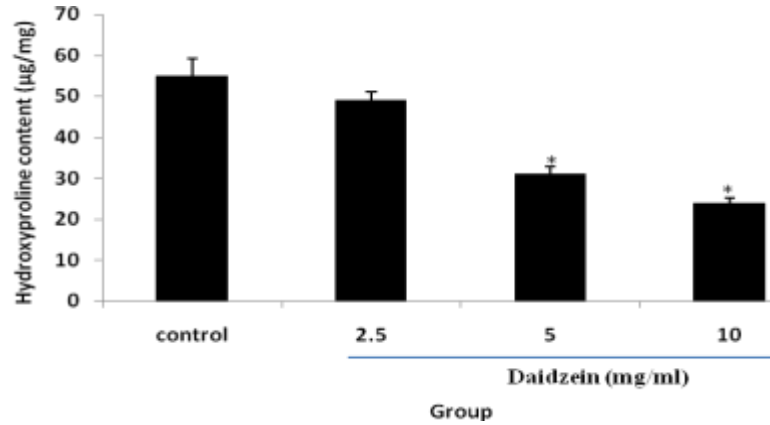


Figure 2: Effect of daidzein on hydroxyproline content in scar tissue
Values are means \pm SD; * $p < 0.05$ (vs. Control group)

Effect of daidzein histopathology of scar tissue

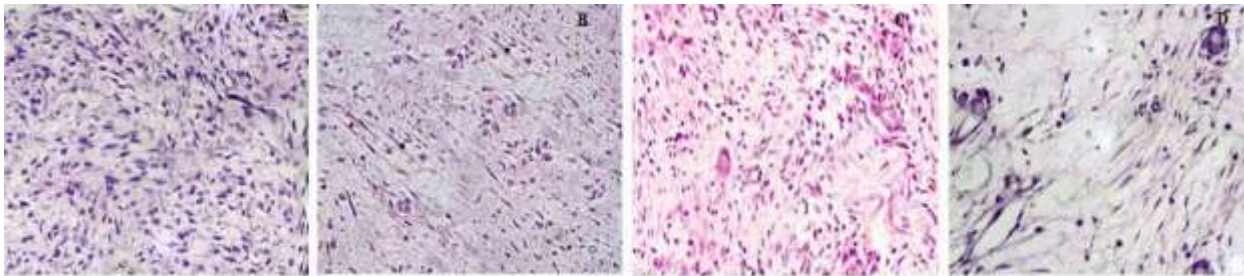


Figure 3: Effect of daidzein on fibroblast in scar tissue by H & E staining (400 \times). A: Control; B: Daidzein 2.5 mg/ml; C: Daidzein 5 mg/ml; D: Daidzein 10 mg/ml

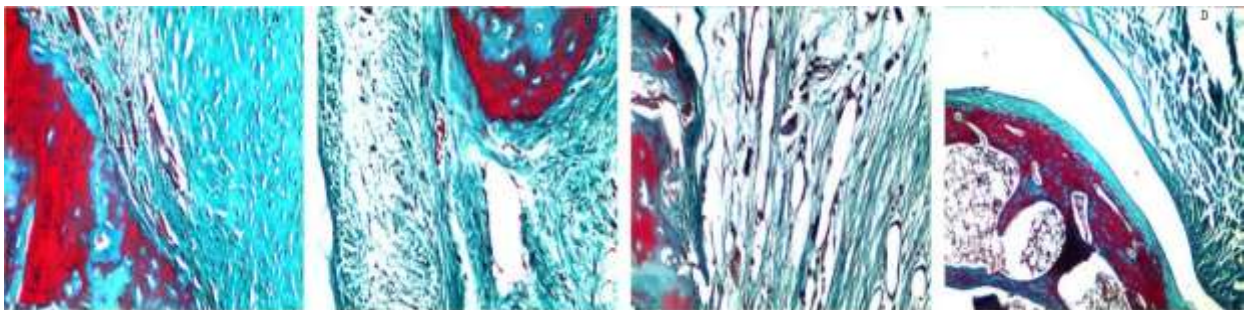


Figure 4: Effect of daidzein on adhesion in scar tissue by Masson's trichrome staining (400 \times). A: Control; B: Daidzein 2.5 mg/ml; C: Daidzein 5 mg/ml; D: Daidzein 10 mg/ml

In control group of rabbits decorticated area was found to be dense adhesion around the joints and scar tissues surround to it. Moreover, observation of decorticated area suggested the development of hyperplasia of collagen tissues and fibroblast. Topical application of daidzein (5mg/ml) to decorticated areas decreases the scar tissue along with collagen-tissue hyperplasia and amount of fibroblast compared to control group. However, by increasing the concentration of daidzein to 10 mg/ml significantly decreases the hyperplasia of collagen-tissue and fibroblast than control group. In

addition treatment with daidzein 10 mg/ml decreases the density of scar tissue and adhesion to decorticated area as shown in Fig 3 and 4.

Effect of daidzein on density of fibroblast

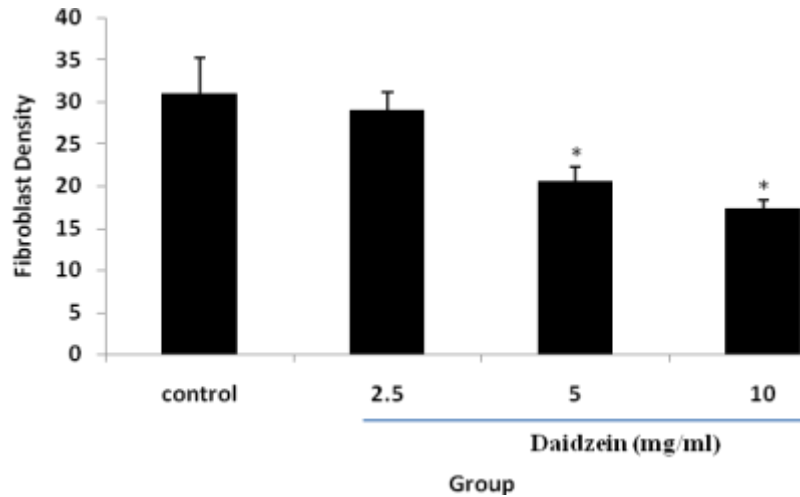


Figure 5: Effect of daidzein on density of fibroblast in each group
Values are means ± SD; *p < 0.05 (vs. Control group)

Effect of daidzein on density of fibroblast was shown in Fig. 5. There were significant (p<0.05) decrease in the density of fibroblast in intra articular scar tissue in daidzein (5 and 10 mg/ml) treated group than control group. This decrease in the density of fibroblast after topical application daidzein was found to be in a dose dependent manner.

Effect of daidzein on optical density of collagen tissue

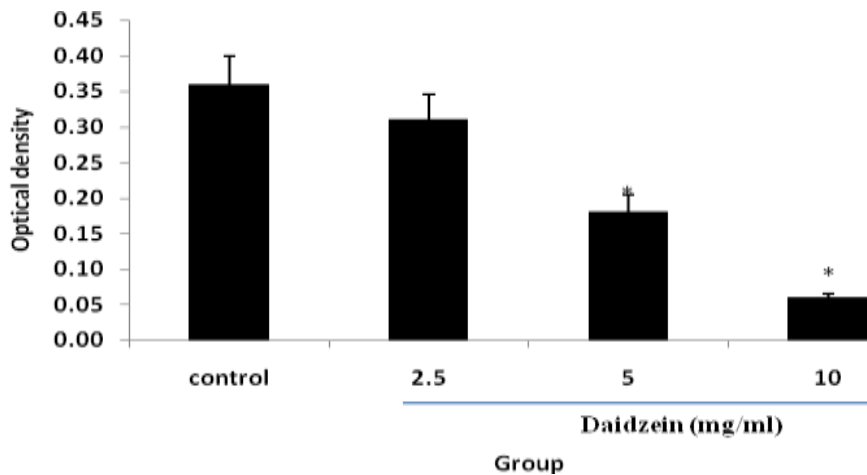


Figure 6: Effect of daidzein on optical density of collagen tissue
Values are means ± SD; *p < 0.05 (vs. Control group)

It was observed that treatment with daidzein (5 and 10 mg/ml) significantly decreases the optical density of collagen tissue compared to control group. Effect of daidzein on optical density of collagen tissue was shown in Fig. 6.

Discussion

The present investigation evaluates the effects of daidzein on intra-articular adhesion following knee surgery. Knee surgery was performed on the rabbits and later daidzein was applied at the site of injury by soaking in to a cotton swab for 10 min. effect of daidzein was evaluated by estimating presence and severity of intra articular adhesion by visual score, hydroxyproline content in scar tissue and histopathological study was performed by using Masson's trichrome and hematoxylin-eosin staining. Moreover, effect of daidzein on fibroblast density and optical density of collagen tissues were estimated by histopathology study too.

Exact cause of adhesion is yet to know completely. Hyperplasia of fibrous tissue was reported to cause of intra articular adhesion. Literature suggested that the drug that inhibit collagen synthesis and thereby reduces fibrosis in fibroblast used in the management of intra articular adhesion in post surgery (Cosgarea et al, 1994; Fukui et al, 2001). The result of present investigation shows that topical application of daidzein significantly reduces ($p < 0.05$) the fibroblast density and collagen synthesis in scar tissue compared to control group.

Daidzein reported to possess strong anti-proliferative, anti-inflammatory and anti-fibrinolytic activity (Choi et al, 2013; Danyelle et al, 2008). Thus, in this study results of different evaluation such as visual score, histological analysis and hydroxyproline content suggested the potential effect of daidzein against the intra articular adhesion in post operative case. As here daidzein decreases the fibrosis and adhesion of tissue to joint, this study postulates the possible mechanism of daidzein against the intra articular adhesion on the basis of its anti-proliferative, anti-inflammatory and anti-fibrinolytic activity.

Conclusion

Present study concludes that topical application of daidzein reduces intra-articular adhesion in post knee surgery in rabbits.

Reference

1. Choi EJ, Kim GH. Antiproliferative activity of daidzein and genistein may be related to ER α /c-erbB-2 expression in human breast cancer cells. *Mol Med Rep.* 2013;7(3):781-4.
2. Cosgarea AJ, DeHaven KE, Lovelock JE. The surgical treatment of arthrofibrosis of the knee. *Am J Sport Med.* 1994;22(2):184-91.
3. Danyelle R.A. Rios, Edna T. Rodrigues, Ana P.Z. Cardoso, Marlise B.A. Montes, Sílvia A. Franceschini, Maria R.T. Tolo, Effects of isoflavones on the coagulation and fibrinolytic system of postmenopausal women. *Nutrition*, 2008; 24: 120-126.
4. Fedoreyev SA, Pokushalov TV, Veselova MV, Glebko LI, Kulesh NI, Muzarok TI, Seletskaya LD, Bulgakov VP and Zhuravlev YN, Isoflavonoid production by callus cultures of *Maackia amurensis*. *Fitoterapia*, 2000; 71: 365-372.
5. Fukui N, Fukuda A, Kojima K, Nakajima K, Oda H, Nakamura K. Suppression of fibrous adhesion by proteoglycan decorin. *J Orthop Res.* 2001;19(3):456-62.
6. Hämäläinen M, Nieminen R, Vuorela P, Heinonen M, Moilanen E. Anti-inflammatory effects of flavonoids: genistein, kaempferol, quercetin, and daidzein inhibit STAT-1 and NF-kappaB activations, whereas flavone, isorhamnetin, naringenin, and pelargonidin inhibit only NF-kappaB activation along with their inhibitory effect on iNOS expression and NO production in activated macrophages. *Mediators Inflamm.* 2007; 2007: 45673.
7. Hayashi, M., Sekiya, H., Takatoku, K., Kariya, Y. & Hoshino, Y. Experimental model of knee contracture in extension: its prevention using a sheet made from hyaluronic acid and carboxymethylcellulose. *Knee Surg Sports Traumatol Arthrosc* 2004; 12: 545-551.
8. Hildebrand, K. A., Zhang, M., Germscheid, N. M., Wang, C. & Hart, D. A. Cellular, matrix, and growth factor components of the joint capsule are modified early in the process of posttraumatic contracture formation in a rabbit model. *Acta Orthop* 2008; 79: 116-125.
9. Jerosch, J, Aldawoudy AM: Arthroscopic treatment of patients with moderate arthrofibrosis after total knee replacement. *Knee Surgery Sports Traumatology Arthroscopy*, 2007; 15: 71-77.
10. Kocaoglu B, Akgun U, Nalbantoglu U et al: Adhesion reduction after knee surgery in a rat model by mitomycin C. *Knee Surg Sports Traumatol Arthrosc*, 2011; 19: 94-98
11. Li X, Yan L, Wang J et al: Comparison of the effects of mitomycin C and 10-hydroxycamptothecin on an experimental intraarticular adhesion model in rabbits. *Eur J Pharmacol*, 2013; 703: 42-45.

12. Liu Y, Skardal A, Shu XZ et al: Prevention of peritendinous adhesions using a hyaluronan-derived hydrogel film following partial-thickness flexor tendon injury. *J Orthop Res*, 2008; 26: 562–69.
13. Monument, M. J. et al. The mast cell stabilizer ketotifen reduces joint capsule fibrosis in a rabbit model of post-traumatic joint contractures. *Inflamm Res* 2012; 61: 285–292.
14. Rezvani AH, Overstreet DH, Perfumi M, Massi M. Plant derivatives in the treatment of alcohol dependency. *Pharmacol. Biochem. Behav.* 2003; 75: 593–606.
15. Riccio M, Battiston B, Pajardi G et al: Efficiency of Hyaloglide in the prevention of the recurrence of adhesions after tenolysis of flexor tendons in zone II: a randomized, controlled, multicentre clinical trial. *J Hand Surg Eur*, 2010; 35: 130–38.
16. Zhao L, Chen Q and Brinton RD. Neuroprotective and neurotrophic efficacy of phytoestrogens in cultured hippocampal neurons. *Exp. Biol. Med.* 2008; 227:509-519.