

BIOCHEMICAL AND HISTOLOGICAL EVIDENCES FOR THE ANTITUMOR POTENTIAL OF TEUCRIUM OLIVERIANUM AND RHAZYA STRICTA IN CHEMICALLY-INDUCED HEPATOCELLULAR CARCINOMA

Abdelaaty A. Shahat^{1,2}, Mansour S. Alsaid¹, Soheir E. Kotob³, Husseiny A. Husseiny⁴, Amal A. M. Al-Ghamdi⁵ and Hanaa H. Ahmed³

¹Pharmacognosy Department, College of Pharmacy, King Saud University, PO Box 2457, Riyadh 11451, Saudi Arabia, ²Phytochemisrty Department, ³Hormones Department, National Research Centre, 33 El Bohouth st. (former El Tahrir st.) Dokki, Giza, Egypt, P. O. 12622. ⁴Faculty of Pharmacy, Misr University for Science and Technology (MUST), 6th of October City, Giza, Egypt, ⁵Botany Division, Department of Biology Sciences, Faculty of Science, King Abdulaziz University, Jeddah, Saudi Arabia

*Corresponding author E-mail: E-mail: aashahat@hotmail.com

Abstract

Background: *Teucrium oliverianum* and *Rhazya stricta* are medicinal plants used in traditional and herbal medicine for the treatment of diabetes, liver diseases and inflammatory conditions. The present study was planned to investigate the antitumor efficacy of *Teucrium oliverianum* and *Rhazya stricta* in chemically-induced hepatocellular carcinoma (HCC) in rats.

Materials and Methods: Forty adult male rats weighing 170-200 g were divided into four groups; each group was comprised of ten rats: (1): Normal healthy animals served as negative control group, (2): Hepatocellular carcinoma (HCC) group in which the rats were orally administered N-nitrosodiethylamine (dissolved in 0.9% normal saline), in a dose of 20 mg/kg b.wt. five times a week for six weeks, (3): HCC group treated with *Teucrium oliverianum* extract in a dose of 600 mg/kg b.wt for two months and (4): HCC group treated with *Rhazya stricta* extract in a dose of 750 mg/kg b.wt for two months. Serum alanine aminotransferase (ALT), asparatate aminotransferase (AST), alkaline phosphatase (ALP) and gamma-glutamyl transferase (γ -GT) activities were estimated. Serum carcinoembryonic antigen (CEA), alpha-fetoprotein (AFP), alpha-L-fucosidase (AFU), glypican-3 (GPC-3), golgi protein 73 (Gp-73) and vascular endothelial growth factor (VEGF) levels were determined. Histopathological examination of liver tissue sections was also carried out.

Results: The HCC group showed significant elevation in serum AST, ALT, ALP and γ -GT activities as well as CEA, AFP, AFU, Gpc-3, Gp 73 and VEGF levels versus the negative control group. Photomicrograph of liver tissue sections of rats in HCC revealed hepatic parenchyma with foci of anaplastic hepatocellular carcinoma as well as other foci of cystic cholangio carcinoma associated with areas of telangiectasis with haemorrhage as well as individual hepatocellular necrosis.

Conclusion: Treatment of HCC groups with *Teucrium oliverianum* or *Rhazya stricta* extract experienced significant improvement in the measured biochemical parameters as well as in the structural organization of the liver. In conclusion, the current study provided experimental evidences for the antitumor efficacy of *Teucrium oliverianum* and *Rhazya stricta* against hepatocellular carcinoma. Such effect could be attributed to hepatoprotective properties, antiproliferative activity and antiangiogenic potential.

Keywords: Hepatocellular carcinoma, *Teucrium oliverianum*, *Rhazya stricta*, rats

Introduction

There has long been standing interest in the identification of natural products for the treatment of various diseases for thousands of years. Natural products possess immense pharmacological significance in the development of drugs including cancer (Kuetze et al., 2013; Alil et al., 2014). Natural products with potential bioactivity compounds have received major attention of many researchers. They have been shown to be an excellent source for the development of food additives in food industry, and new drugs in medical fields (Zhang et al., 2007). *Teucrium* species have been used as medicinal plants for more than 2000 years and some of them are still used in folk medicine as antispasmodic, tonic, antipyretic and antiseptic. Many *Teucrium* species are known for their medicinal utilisation and exhibit interesting biological properties such as hypoglycaemic, hypolipidemic, hepatoprotective, antipyretic, anti-inflammatory, antiulcer, antitumor, antibacterial and insect antifeedant activities (Bagci1 et al., 2010). The genus *Teucrium* (family Labiatae) is one of the richest sources of diterpenes, with a neoclerodane skeleton and more than 220 diterpenes have been described (Piozzi et al., 2005). Also, essential oils have been reported from the aerial parts of several *Teucrium* spp. The oils showed different yields in the various species, ranging between 0.5% and 1.5%, and the percentage of the major chemical constituents (mainly monoterpene/sesquiterpenes hydrocarbons and oxygenated sesquiterpenes) differs notably from species to species (Saroglou et al., 2007). *Rhazya stricta* Decne (Harmal), a member of Apocynaceae family, is an important medicinal species used in folkloric medicine to cure various diseases in South Asia and in the Middle East (Gilani et al., 2007). Extracts of *R. stricta* leaves have been prescribed for the treatment of various disorders such as diabetes, sore throat, helminthiasis, inflammatory conditions, stomach problems, liver diseases and rheumatism (Marwat et al., 2012). It has been reported that *R. stricta* is a good source of antioxidants (Iqbal et al., 2006). Some of the chemical constituents of *R. stricta* and their pharmacological activities have been reviewed (Ali et al., 2000; Marwat et al., 2011). The plant extract contains many alkaloids, glycosides, flavonoids, tannins and triterpenes (Al-Yahya et al., 1990).

The effective uses of *R. stricta* described in traditional medicine have been attributed to the presence of indole alkaloids. Indeed, the activity-guided phytochemical analysis of *R. stricta* extract has shown that the alkaloidal fraction has the highest biological activity (Tanira *et al.*, 2000). Interestingly, two indole alkaloids, 16-epi-Z-isositsirikine and didemethoxycarbonyl tetrahydrosecamine, isolated from *R. stricta* experienced antineoplastic activity (Atta-ur-Rahman and Zaman, 1986). Previous work has shown that the aqueous extract of *R. stricta*, acting as a single agent, inhibited cell proliferation in the breast cancer cell lines MCF-7 and MDA MB-231 (Baeshen *et al.*, 2012). However, the aqueous methanol extract of *Teucrium oliverianum* and *Rhazya stricta* exhibited antitumor activity against murine hepatoma cells due to their ability to induce NAD(P)H:quinoneoxidoreductase (Shahat *et al.* 2013).

Hepatocellular carcinoma is a major health problem worldwide, due to its high incidence and high rates of mortality (Alves *et al.*, 2011). Major risk factors for HCC include chronic infection with HBV or HCV, alcoholic liver disease, and most probably nonalcoholic fatty liver disease. Less common causes include hereditary hemochromatosis, alpha1-antitrypsin deficiency, autoimmune hepatitis, some porphyrias, and Wilson's disease. The distribution of these risk factors among patients with hepatocellular carcinoma is highly variable, depending on geographic region and race or ethnic group (El-Serag, 2011). Most of these risk factors lead to the formation and progression of cirrhosis, which is present in 80 to 90% of patients with hepatocellular carcinoma (Minguez *et al.*, 2009). The treatment of hepatocellular carcinoma (HCC) remains a dismal, with 1- and 3-year survival rates of 20% and 5%, respectively and a median survival of 8 months. The current therapies for HCC include hepatic artery embolization, chemotherapy, radiofrequency ablation, and cryoablation (Befeler and Di Bisceglie, 2002) as well as liver transplantation which can provide survival rate of 28% at 3 years (Rougier *et al.*, 2007). Although these therapies play an important role in HCC treatment, but their therapeutic outcome remains very poor due to its toxic side effects. Moreover, there is a significant resistance to available chemotherapeutic agents and liver tolerate frequent doses of radiation (Chau *et al.*, 2006). Therefore; there is an urgent need for naturally occurring products that have anticancer activity with low toxicity and side effects (Wang *et al.*, 2010). The current study was undertaken to elucidate the antitumor potential of, *Teucrium oliverianum* and *Rhazya stricta* aqueous, methanolic extract against diethylnitrosamine-induced hepatocellular carcinoma in male rats with special concern on their mechanism of action.

Materials and Methods

Chemicals

N-nitrosodiethylamine (NDEA) (CAS no. 55-18-5) was purchased from Sigma-Aldrich Chemicals Co. (St Louis, MO, USA). All other chemicals and solvents were of analytical grade.

Plant Materials

Teucrium oliverianum and *Rhazya stricta* were collected from the Tanhat protected area, Saudi Arabia in April 2012. The plants were identified by the Plants Taxonomist at the Herbarium Unit. The voucher specimens (15970 and 15957) were deposited at the Herbarium of the Faculty of Pharmacy, King Saud University, Riyadh, Saudi Arabia.

Extract preparation

The aerial part *T. oliverianum* and *R. stricta* were dried under shade. The dried samples were powdered and used for solvent extraction. 1 kg of the dried sample was extracted twice with 3 L of 80% methanol. The methanolic extracts were filtered through Whatman No. 1 filter paper and concentrated using a rotary evaporator under reduced pressure at 40 °C. to obtain residue with yields of 20 % for *T. oliverianum* and 22% for *R. stricta*

Experimental protocol

Forty adult male Wistar rats weighing 170-200 g were obtained from the Animal House Colony of the National Research Centre, Cairo, Egypt. The animals were housed in polypropylene cages in an environmentally controlled clean air room with a temperature of 25±1°C, an alternating 12h light/12h dark cycle, a relative humidity of 60 ± 5% and free access to tap water and a standard rodent chow (Wadi El Kabda Co., Cairo, Egypt). Rats were allowed to adapt to these conditions for 2 weeks before beginning the experimental protocol. The animal experimental protocol was approved by the Ethical Committee for Medical Research, National Research Centre, Egypt. After the acclimatization period, the animals were divided into four groups; each group was comprised of ten rats: (1): Normal healthy animals served as negative control group, (2): Hepatocellular carcinoma (HCC) group in which rats were orally administered N-nitrosodiethylamine (dissolved in 0.9% normal saline), in a dose of 20 mg/kg b.wt. five times a week for six weeks according to the modified method of Darwish and El-Boghdady (2011), (3) HCC group treated with *T. oliverianum* extract in a dose of 600 mg/kg b.wt (Arzi *et al.*, 2011) daily for two months (4) HCC group treated with *R. stricta* extract in a dose of 750 mg/kg b.wt (Baeshen *et al.*, 2010) daily for two months.

Samples collection

After animal treatment was over, the animals were fasted overnight (12-14 h) and the blood samples were collected, under diethyl ether anesthesia, from the retroorbital venous plexus in a clean dry centrifuge tubes without any anticoagulant agent and allowed to coagulate for 45 minutes at room temperature to obtain sera to be used for biochemical analysis. Serum samples were separated by centrifugation at 1800 xg for 15 minutes at 4°C using cooling centrifuge. Aliquots of serum were frozen and stored at -20°C pending further biochemical analyses.

After collection of the blood samples, the animals were scarified by cervical dislocation and the liver from experimental animals were quickly excised, washed in saline blotted dry and fixed in 10 % formalin saline solution for histological examination.

Biochemical Analyses

Serum alanine aminotransferase (ALT) and asparatate aminotransferase (AST) activities were estimated using colorimetric kit purchased from Salucea Co. Ltd (Netherlands) according to ECCLS (1989) method. Serum alkaline phosphatase (ALP) and gamma-glutamyl transferase (γ -GT) activities were determined using colorimetric kit purchased from Reactivos GPL Co. Ltd (Barcelona) according to Tietz et al. (1995) method. Serum carcinoembryonic (CEA) was quantified by enzyme linked immunosorbent assay (ELISA) technique using a kit purchased from Immunospec Co., Ltd (USA), according to Schwartz (1987) method. Serum alpha-fetoprotein (AFP) level was measured by ELISA technique using ELISA kit purchased from Immunospec Co., Ltd (USA), according to the method of Hirai (1982). Serum alpha-L-fucosidase (AFU) activity was evaluated by ELISA technique using a kit purchased from Glory Science Co., Ltd (USA), according to the manufacturer's instructions provided with AFU assay kit. Serum glypican-3 (GPC-3) level was assayed by ELISA technique using a kit purchased from Glory Science Co., Ltd (USA), according to the manufacturer's instructions provided with GPC-3 assay kit. Serum golgi protein 73 (Gp-73) level was detected by ELISA technique using a kit purchased from Glory Science Co., Ltd (USA), according to the manufacturer's instructions provided with Gp-73 assay kit. Serum vascular endothelial growth factor (VEGF) level was estimated by ELISA technique using a kit purchased from Glory Science Co., Ltd (USA), according to the manufacturer's instructions provided with VEGF assay kit.

Histopathological examination

After fixation of the liver specimens in formal saline (10%) for 24 hours, the tissues were then washed in running tap water, dehydrated in series of alcohol (methyl, ethyl and absolute alcohol). The specimens were cleared in xylene and embedded in paraffin at 56 degree in hot air oven for twenty four hours. The paraffin wax tissue blocks were sectioned by slidge microtome at thickness of 4 μ m. The obtained tissue sections were collected on clean glass slides and left in the oven at 40°C for dryness before examination under the electric light microscope (Banchroft et al., 1996).

Statistical analysis

In the present study, the results were expressed as Mean + S.E of the mean. Data were analyzed by one way analysis of variance (ANOVA) using the Statistical Package for the Social Sciences (SPSS) program, version 14 followed by least significant difference (LSD) to compare significance between groups (Armitage and Berry, 1987). Difference was considered significant when P value was < 0.05. Percentage difference representing the percent of variation with respect to the corresponding control group was also calculated using the following formula:

$$\% \text{ difference} = \frac{\text{Treated value} - \text{Control value}}{\text{Control value}} \times 100$$

Results

Biochemical Results

The data in Table (1) illustrated the effect of treatment with *T. oliverianum* and *R. stricta* extracts on serum liver enzymes (AST, ALT, ALP and γ -GT) activity in HCC bearing rats. HCC group showed significant elevation (P< 0.05) in serum AST, ALT, ALP and γ -GT activity with respect to the negative control group. Treatment of HCC group with *R. stricta* extract experienced significant decrease (P< 0.05) in serum AST activity HCC group treated with *T. oliverianum* extract revealed insignificant decrease (P> 0.05) on serum AST activity as compared to the untreated HCC group (Table 1). Nevertheless treatment of HCC groups with *T. oliverianum* or *R. stricta* extract displayed significant decrease (P< 0.05) in serum ALT, ALP and γ -GT activity relative to the untreated HCC group (Table 1).

The results depicted in Table (2) represented the effect of treatment with *T. oliverianum* and *R. stricta* on serum tumor markers (CEA, AFP and AFU) levels in HCC bearing rats. The HCC group showed significant elevation (P< 0.05) in serum CEA, AFP and AFU levels as compared to the negative control group (Table 2). On the other side, treatment of the HCC group with *T. oliverianum* or *R. stricta* extract revealed significant decrease (P< 0.05) in serum CEA, AFP and AFU levels versus to the untreated HCC group (Table 2).

The effect of treatment with *T. oliverianum* and *R. stricta* extracts on serum glypican 3 and golgi 73 levels in HCC bearing rats is illustrated in Table (3). The HCC group exhibited significant elevation (P< 0.05) in serum glypican 3 and golgi 73 levels as compared to the negative control group (Table 3). However, treatment of the HCC groups with *T. oliverianum* or *R. stricta* extract produced significant decrease (P< 0.05) in serum glypican 3 while they elicited insignificant (P> 0.05) decrease in serum golgi 73 levels in comparison with the untreated HCC group (Table 3).

Table 1: Effect of treatment of with *T. oliverianum* and *R. stricta* extracts on serum liver enzymes activity in HCC bearing rats

Parameters Groups	AST (U/L)	ALT (U/L)	ALP (U/L)	γ-GT (U/L)
Negative control group	84.0±1.53	44.7±1.05	109.5±7.11	14.48±1.06
HCC group	125.8±13.2 ^a (49.79 %)	88.9±4.31 ^a (98.85 %)	255.6±12.6 ^a (133.43 %)	39.55±1.91 ^a (173.17 %)
HCC+ <i>T. oliverianum</i> extract group	111.2±6.37 (-11.61 %)	69.9±2.76 ^b (-21.39 %)	199.5±12.26 ^b (-21.93 %)	29.35±1.38 ^b (-25.78 %)
HCC+ <i>R. stricta</i> extract group	100.7±5.5 ^b (-19.95 %)	64.8±2.93 ^b (-27.15 %)	186.5±8.13 ^b (-27.02 %)	30.14±0.77 ^b (-23.8 %)

Data were expressed as means± standard error (SE) for 10 animals / group.

a: P< 0.05 vs negative control; **b:** P< 0.05 vs HCC group.

Table 2: Effect of treatment with *T. oliverianum* and *R. stricta* extracts on serum tumor marker levels in HCC bearing rats

Parameters Groups	CEA (ng/ml)	AFP (ng/ml)	AFU (pg/ml)
Negative control group	0.12±1.250×10 ⁻²	19.03±1.52	32.33±3.07
HCC group	0.60±6.0×10 ⁻² ^a (500 %)	40.07±2.98 ^a (111.05 %)	121.2±6.14 ^a (275 %)
HCC+ <i>T. oliverianum</i> extract group	0.31±0.41×10 ⁻² ^b (-47.5 %)	36.56±0.58 ^b (-8.82 %)	80.69±4.91 ^b (-33.44 %)
HCC+ <i>R. stricta</i> extract group	0.26±0.86×10 ⁻² ^b (-55.55 %)	34.64±1.37 ^b (-13.61 %)	71.86±6.59 ^b (-40.73 %)

Data were expressed as means ± standard error (SE) for 10 animals / group.

a: P< 0.05 vs negative control. **b:** P< 0.05 vs HCC group.

Table 3: Effect of treatment with *T. oliverianum* and *R. stricta* extracts on serum glypican 3 and golgi 73 levels in HCC bearing rats.

Parameters Groups	Glypican 3 (pg/ml)	Golgi 73 (ng/ml)
Negative control group	2.96±0.18	231.0±7.35
HCC group	4.85±0.13 ^a (63.68 %)	322.0±3.74 ^a (39.393 %)
HCC+ <i>T. oliverianum</i> extract group	4.03±0.24 ^b (-16.81 %)	315.3±19.13 (-2.07 %)
HCC+ <i>R. stricta</i> extract group	3.63±0.21 ^b (-25.16 %)	297.3±7.15 (-7.67 %)

Data were expressed as means ± standard error (SE) for 10 animals / group.

a: P< 0.05 vs negative control. **b:** P< 0.05 vs HCC group.

Table (4) illustrated the effect of treatment with *T. oliverianum* and *R. stricta* extracts on serum VEGF level in HCC bearing rats. The HCC group revealed significant elevation (P< 0.05) in serum VEGF level as compared to the negative control group (Table 4). While, treatment of the HCC group with *T. oliverianum* or *R. stricta* extract caused significant decrease (P< 0.05) in serum VEGF level with respect to the untreated HCC

group (Table 4).

Table 4: Effect of treatment with *T. oliverianum* and *R. stricta* extracts on serum VEGF level in HCC bearing rats.

Groups	Parameters	VEGF (ng/L)
Negative control group		91.66±2.61
HCC group		129.3±2.09 ^a (41.06 %)
HCC+ <i>T. oliverianum</i> extract group		102.01±0.82 ^b (-21.1 %)
HCC+ <i>R. stricta</i> extract group		101.29±0.62 ^b (-21.66 %)

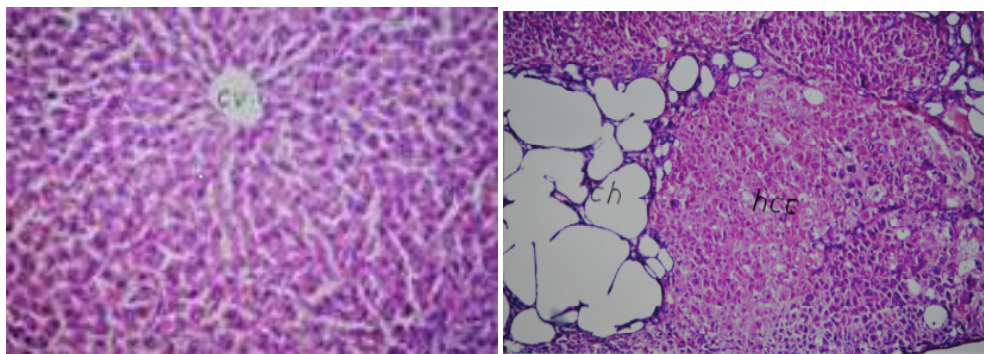
Data were expressed as means ± standard error (SE) for 10 animals / group.

a: P< 0.05 vs negative control.

b: P< 0.05 vs HCC group.

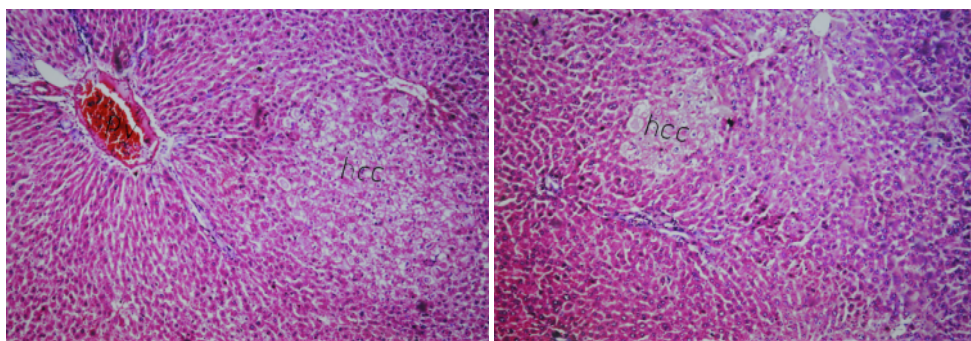
Histopathological Results

Photomicrograph of liver tissue section of rat in the negative control group showed no histopathological alteration and the normal histological structure of the central vein and the surrounding hepatocytes in the hepatic parenchyma (Fig.1). Photomicrograph of liver tissue section of rat HCC group showed hepatic parenchyma with foci of anaplastic hepatocellular carcinoma as well as other foci of cystic cholangio carcinoma associated with areas of telangiectasis with haemorrhage as well as individual hepatocellular necrosis (Fig. 2). Photomicrograph of liver tissue section of rat in HCC group treated with *T. oliverianum* extract showed very few foci of anaplastic hepatocytes (Fig. 3). Photomicrograph of liver tissue section of rat in HCC group treated with *R. stricta* extract showed focal of anaplastic hepatocytes associated with congestion in the portal vein (Fig. 4).



(1)

(2)



(3)

(4)

(1): Photomicrograph of liver tissue section of rat in the negative control group showing normal histological structure of the central vein and the surrounding hepatocytes in the hepatic parenchyma (H&E x 40).

(2): Photomicrograph of liver tissue section of rat in HCC group showing foci of anaplastic hepatocellular carcinoma with other foci of cystic cholangio carcinoma (ch) (H&E x 16).

(3): Photomicrograph of liver tissue section of rat in HCC group treated with *T. oliverianum* extract showing very few foci of hepatocellular carcinoma (H&E x 16).

(4): Photomicrograph of liver tissue section of rat in HCC group treated with *R. stricta* extract showing focal area of anaplastic hepatocyte (hcc) with congestion in the portal vein (H&E 16).

Discussion

The present study results demonstrated that HCC group displayed significant elevation in serum AST, ALT, ALP and γ -GT activity as compared to the negative control group. AST elevations often predominate in patients with cirrhosis and even in liver diseases that typically have increased ALT level (Green and Flamm, 2002). Recent studies have suggested that preoperative ALP levels could be utilized to monitor and predict recurrence in high risk HCC patients (Kim et al., 2013). Chemical carcinogens may initiate some systematic effects that induce GGT synthesis (Vanisree and Shyamaladevi, 1998). The elevated levels of GGT reflect the progress of carcinogenesis, since its activity correlates with tumor growth rate, differentiation and survival of the host (Koss and Greengurd, 1982). The results of the current study revealed that the treatment of HCC group with *T. oliverianum* extract produced significant decrease in serum AST, ALT, ALP and γ -GT activity as compared to the untreated HCC group. These results are in agreement with Amini and Yazdanparast (2009) who reported that the beneficial effect of *T. polium* might be attributed to its strong antioxidant and anti-inflammatory properties. Ethyl acetate extract of *T. polium*, with strong antioxidant property and high polyphenolic content, exerted several favorable effects on experimental non-alcoholic steatohepatitis (NASH) disease. It caused a significant decrease in serum liver enzymes with accompanying improvement in the histopathological patterns regarding steatosis, ballooning degeneration and lobular inflammation (Amini and Yazdanparast 2009). In accordance with our results, Forouzandeh et al. (2013) reported that *T. polium* treated group showed significantly lower serum AST, ALT and ALP activity. The current study demonstrated that the treatment of the HCC group with *R. stricta* extract elicited significant decrease in serum AST, ALT, ALP and γ -GT activity as compared to the untreated HCC group. This effect may be attributed to the antioxidants activity of *R. stricta* (Iqbal et al., 2006).

In the present work HCC group showed significant elevation in serum CEA, AFP and AFU levels as compared to the negative control group. In agreement with Ahmed et al. (2013) who recorded significant increase in these tumor markers in HCC bearing rats induced by N-nitrosodiethylamine. Li et al. (2008) reported that when the rat liver tumor induced by DENA appeared, the CEA content in serum elevated. Song et al. (2013) also recorded significant increase in serum AFP in HCC bearing rats induced by mucopolysaccharide. Moreover, It has long been recognized that exposure of rats to certain carcinogens like NDEA caused an elevation of circulating AFP levels (Sell et al., 1983). The upregulation of AFP gene expression in NDEA challenged rats might be due to necrosis of hepatocytes caused by NDEA. Hepatocyte localization within or outside the liver plate is the defining factor that regulates the activity of AFP synthesis on a cellular level (Lazarevich, 2000). The increased serum value of AFU in HCC group in the current work is in agreement with the prior study of Chen et al. (2012). Although the mechanism by which AFU increases in HCC is still unknown, but the possible mechanism for that increase could be attributed to the increased synthesis of proteins by tumor with a consequent increase in fucose turnover (Deugnier, 1984).

Herein, the treatment of the HCC group with *T. oliverianum* extract resulted in significant decrease in serum CEA, AFP and AFU levels as compared to the untreated HCC group. The decreased AFP in *T. oliverianum* treated group is in conformity with Hanachi et al. (2008). It has been found that antioxidants decreased the level of AFP, therefore the antioxidant active constitute of *T. oliverianum* might affect the AFP level and could express this beneficial effect (Fouad et al., 2013). In addition, *T. oliverianum* has been shown to be considered as an effective and safe chemosensitizer agent for cancer therapy (Rajabalian, 2008). This could be due to its contents from diterpenoids, flavonoids, iridoids, sterols and terpenoids (Bedir et al., 1999). Moreover, the anti-inflammatory and cytotoxic activities of *Teucrium* essential oils were evaluated to obtain an insight on the beneficial effects of this species in conditions related to inflammation, cardiovascular diseases and cancer prevention. The previous results demonstrated that oils of *T. oliverianum* exhibited strong anti-inflammatory and cytotoxic activity against the three human tumour cell lines. This biological activity could be partly explained by the presence of sesquiterpenes, such as spathulenol, d-cadinene, caryophyllene, caryophyllene oxide, α -humulene, and torreyol (Menichini et al., 2009). The present data revealed that the treatment of the HCC group with *R. stricta* extract induced significant decrease in serum CEA, AFP and AFU levels as compared to the untreated HCC group. *R. stricta* is an alkaloid rich herb; alkaloids are among the most important active components in natural herbs, which showed antiproliferation and antimetastasis effects on various types of cancers both *in vitro* and *in vivo* (Lu et al., 2012). It has been revealed that the treatment with alkaloids significantly decrease the tumor markers and suppressed HCC growth *in vitro* and *in vivo*, and increased the survival of HCC-bearing treated mice.

The anti-tumour effect may be attributed to direct and systemic anti-tumour activities (Nagler et al., 2004). In view of our data HCC group showed significant increase in serum glypican 3 and golgi 73 levels as compared to the negative control group. Coston et al. (2008) demonstrated that the sensitivity and specificity of GPC3 for HCC was 88% and 97%, respectively. GPC3 is a very specific marker not only for differentiating HCC from non hepatic tumors with epithelial differentiation, but also for differentiating HCC from hepatic adenoma (HA) and focal nodular hyperplasia (FNH). Golgiprotein-73(GP73) is a resident Golgi glycoprotein expressed in epithelial cells. GP73 serum levels are higher in early HCC patients than in cirrhotic patients. GP73 is considered as a possible tumor marker for HCC and it showed a specificity of 75% and a sensitivity of 69% (Malaguamera et al., 2010). Serum GP73 is dramatically elevated in patients with HCC, and the sensitivity and specificity of GP73 for HCC might be superior to those of AFP (Willyard, 2007). Treatment of the HCC group with *T. oliverianum* extract produced significant decrease in serum glypican 3 level while induced insignificant decrease in serum golgi 73 level as compared to the untreated HCC group. The therapeutic benefit of *teucrium* is often attributed to its antioxidant properties (Dixon et al., 2005).

A methanolic extract of *T. polium* has been shown to protect red blood cells (RBCs) against lipid peroxidation (Suboh et al., 2004). It is believed that oxidative stress plays critical roles in the initiation and progression of hepatocarcinogenesis. It has been hypothesized that polymorphisms that impair anti-oxidative capacity may influence HCC risk. Moreover, Reactive oxygen species have been related to the aetiology of cancer as they are known to be mitogenic and therefore capable of tumour promotion. Thus, it is possible that cumulative defects in protection from oxidative stress may result in increased risk of liver cancer in the Moroccan population (Ezzikouri et al., 2010). Treatment of the HCC group with *R. stricta* extract led

to significant decrease in serum glypican 3 level while it produced insignificant decrease in serum golgi 73 level as compared to the untreated HCC group. It has reported that the aqueous extract of *R. stricta* inhibited cell proliferation and induced apoptotic cell death in the breast cancer cell lines MCF-7 and MDA MB-231 (Huang et al., 2007). It has been demonstrated that the basic alkaloid fraction of *R. stricta* induced the chemopreventative enzyme, NQO1, which could be, at least in part, a novel mechanism for the traditional use of *R. stricta*'s alkaloid as an antitumor agent (El Gendy et al., 2012). This may be the underlying mechanism for the reduction of these tumor markers by *R. stricta* extract supplementation. Also, it has been found that a crude alkaloid extract from *R. stricta* inhibited cell growth and sensitized human lung cancer cells, A549, to cisplatin through induction of apoptosis (Elkady, 2013).

In light of the present results serum VEGF level in rats of HCC group showed significant increase which is in agreement with the result of Ahmed et al. (2013) and El-Shahat et al. (2012). This result might be attributed to the high angiogenic activity in rats with hepatocellular carcinoma induced by NDEA. This finding has been explained previously by that NDEA could increase No level which play a key role in enhancing angiogenesis by stimulating the synthesis of VEGF (Jozkowicz et al., 2001). As Hiramoto et al (2002) showed that NDEA is decomposed, in concomitant with the release of nitric oxide. Moreover, NDEA administration has been found to increase nitric oxide synthase-2 (NOS2) activity indicating the generation of reactive oxygen species (ROS), promoting carcinogenesis and possibly leading towards angiogenesis (Fontanini et al., 1997). Treatment of HCC group with *T. oliverianum* extract elicited significant decrease in serum VEGF level relative to the untreated HCC group. This may be attributed to the antioxidant property of this extract due to its chemical constituents of flavonoids (Yazdanparast and Ardestani, 2009), and antiproliferative (Kandouz et al., 2010) properties of *T. oliverianum* extract. Rajabalian (2008) reported that combinations of *T. polium* extract induce a massive apoptosis in several human cancer cell lines such as MCF7, A431, SW480 and Skmel-3. The bioactive compounds of *T. polium*, flavonoids and neo-clerodane diterpenoids have an important effect on cell proliferation and cell cycle deregulation of human prostate cancer cells as well as other human cancer cells (Kandouz et al., 2010). In addition, the *Teucrium polium* possesses anti-inflammatory activities (Esmaili and Yazdanparast, 2004).

In addition to its content of diterpenes which possess anti-angiogenic effect causing vascular shutdown in tumors and resulting in tumor necrosis (Cragg et al., 2002). Treatment of HCC group with *R. stricta* extract exhibited significant decrease in serum VEGF level versus the untreated HCC group. This may be attributed to indole alkaloids in *R. stricta* which have been found to possess numerous biological activities and anticancer potentiality (Gilani et al., 2007). It has been found that a crude alkaloid extract from *R. stricta* inhibited cell growth and sensitized human lung cancer cells, A549, to cisplatin through induction of apoptosis (Elkady, 2013). Photomicrograph of liver tissue section of rat in HCC group showed hepatic parenchyma with foci of anaplastic hepatocellular carcinoma as well as other foci of cystic cholangio carcinoma associated with areas of telangiectasis with haemorrhage as well as individual hepatocellular necrosis (Fig. 2). These remarkable features of hepatocellular carcinoma are in agreement with the studies of Abdallah and Khattab, (2004). Moreover, Seufi et al. (2009) reported that histological examination of liver tissue of HCC group showed inflammatory cells infiltration and fibroblastic cells proliferation that divide the cancer and necrosed hepatocytes of the parenchyma into nodules with hyperchromatic nuclei as well as cellular pleomorphism and polarity.

Photomicrograph of liver tissue section of rat in HCC group treated with *T. oliverianum* extract showed Very few foci of anaplastic hepatocytes. The livers of rats treated with *T. oliverianum* extract exhibited an almost normal architecture, with the presence of double nucleus hepatocytes, except for a slight deformity of hepatocytes with pyknosis and clearing of cytoplasm. These histological findings asserted the hepatoprotective and anticancer efficacy of *T. oliverianum* (Panovska et al., 2007). Photomicrograph of liver tissue section of rat in HCC group treated with *R. stricta* extract showed focal of anaplastic hepatocytes associated with congestion in the portal vein. This antitumor capability of *R. stricta* extract could be due to its anticancer potentiality (Gilani et al., 2007) as well as antioxidants activity (Iqbal et al., 2006).

Conclusion

The present study provided experimental evidences for the antitumor potential of *T. oliverianum* and *R. stricta* against HCC induced in rats. This action could be attributed to their potent hepatoprotective properties, antiproliferative activity and antiangiogenic effect.

Acknowledgements

The authors would like to extend their sincere appreciation to the Deanship of Scientific Research at King Saud University for funding of this research through the Research Group Project no. **RGP-VPP-262**.

References

1. Abdallah IZ and Khattab HA (2004). Protective role of lycopene against diethylnitrosamine induced experimental hepatocarcinogenesis. Egypt J Hosp Med, 16:1- 13.
2. Ahmed HH, Shousha WG, El-Mezayen HA, Ismaiel NN, Mahmoud NS (2013). *In vivo* antitumor potential of carvacrol against hepatocellular carcinoma in rat moderl. World Journal of Pharmacy and Pharmaceutical Sciences. 2(5):2367-2396.
3. Ali BH, Al-Qarawi AA, Bashir AK and Tanira MO (2000). Phytochemistry, pharmacology and toxicity of *Rhazya stricta* Decne: A review. Phytother Res., 14:229-234.
4. Alil MA, Abul Farah M, Al-Hemaid FM, Abou-Tarboush, FM (2014). In Vitro cytotoxicity screening of wild plant extracts from Saudi Arabia on human breast adenocarcinoma cells. Genetics and Molecular Research, 13: 3981-3990.
5. Alves RCP, Alves D, Guz B, Matos C, Viana M, Harriz M, Terrabuio D, Kondo M, Gampel O, and Polleti P(2011). Advanced hepatocellular carcinoma. Review of targeted molecular drugs. Ann. Hepatol., 10: 21-27.
6. Al-Yahya MA, Al-Meshal IA, Mossa JS, Al-Badr AA and Tariq M (1990). Saudi Plants: A Phytochemical and Biochemical Approach. King Saud University Press, Riyadh, 123-129.

7. Amini R and Yazdanparast R (2009). Suppression of hepatic TNF- α and TGF- β gene expressions in rats with induced nonalcoholic steatohepatitis. *Pharmacology online*, 3: 340-350.
8. Armitage P, Berry G (1987). Comparison of several groups. In: statistical method in medical research. 2nd ed., Oxford; Blackwell significant publication, 186-213.
9. Arzi A, Namjouyan F, Sarahroodi S, Khorasgani ZN and Macvandi E (2011). The study of antinociceptive effect of hydroalcoholic extract of *Teucrium oliverianum* (A plant use in southern Iranian traditional medicine) in rat by formalin test. *Pakistan journal of Biological Sciences*. 14(23): 1066-1069.
10. Atta-ur-Rahman and Zaman K (1986). 1, 2-Dehydroaspido-spermidine N-oxide, an alkaloid from *Rhazya stricta*. *Phytochemistry* 25:1779-1780.
11. Baeshen NA, Elkady AI, Abuzinadah OA and Mutwakil MH (2012). Potential anticancer activity of medicinal herb, *Rhazya stricta*, against human breast cancer. *Afr J Biotechnol.*, 11:8960-8972
12. Baeshen NA, Lari SA, Aldoghather HA and Elkady AI (2010). Biochemical evaluation of the effect of *Rhazya stricta* aqueous leaves extract in liver and kidney function in rats. *Nature and Science* 8(4):136-142.
13. Bagcil E, Yazginl A, Hayta S (2010). Composition of the essential Oil of *Teucrium chamaedrys* L. (Lamiaceae) from Turkey and Ugur Cakilcioglu. *Journal of Medicinal Plants Research Vol.* 4(23): 2587-2589.
14. Bancroft JD, Stevens A, (1996). *Theory and Practice of Histological Techniques*. 4th ed., New York, London, San Francisco, Tokyo; Churchill Livingstone: 1996
15. Befeler, A.S. and Di Bisceglie, A.M. (2002). Hepatocellular carcinoma: diagnosis and treatment. *Gastroenterology*, 122: 1609-1619.
16. Chau GY, Lui WY, Tsay SHm Chao Y, King KL and Wu CW (2006). Post resectional adjuvant intra portal chemotherapy in patients with hepatocellular carcinoma: a case-control study. *Ann.Surg. Oncol.*, 13: 1329-1337.
17. Chen B, Ning M, Yang G (2012). Effect of paeonol on antioxidant and immune regulatory activity in hepatocellular carcinoma in rats. *Molecules*, 17: 4672-4683.
18. Coston WM, Loera S, Lau SK, Ishizawa S, Jiang Z, Wu CL, Yen Y, Weiss LM, Chu PG. (2008). Distinction of hepatocellular carcinoma from benign hepatic mimickers using glypican-3 and CD34 immunohistochemistry. *Am J Surg Pathol*. 32(3): 433-44.
19. Cragg GM, DJ Newmann S Holbeck. (2002). Natural products and derivatives as leads to cell cycle pathway targets in cancer chemotherapy. *Curent Cancer drug targets*, 2: 279-308.
20. Darwish HA, El-Boghdady NA (2011). Possible involvement of oxidative stress in diethylnitrosamine induced hepatocarcinogenesis: chemopreventive effect of curcumin. *J Food Biochem*, 37: 353-361.
21. Deugnier Y (1984). Serum α -L-fucosidase: A new marker for the diagnosis of primary hepatic Carcinoma. *Hepato*, 4:889-892.
22. ECCLS. (1989). Determination of the catalytic activity concentration in serum on L-aspartate aminotransferase (EC 2.6.1.1., AST). *Clin Chem*. 20: 204-211.
23. Elkady AI (2013). "Crude alkaloid extract of *Rhazya stricta* inhibits cell growth and sensitizes human lung cancer cells to cisplatin through induction of apoptosis," *Genetics and Molecular Biology*, 36(1): 12–21.
24. El-Serag HB (2011). Hepatocellular carcinoma: current concepts. *N. Engl. J. Med.*, 365:1118-1127.
25. El-Serag H.B, Mason AC and Key C (2001). Trends in survival of patients with hepatocellular carcinoma between 1977 and 1996 in the United States. *Hepatology* 33: 62-65.
26. El-Shahat M, El-Abda S, Alkafafyb M , El-Khatiba G. (2012). Potential chemoprevention of diethylnitrosamine-induced hepatocarcinogenesis in rats: Myrrh (*Commiphora molmol*) vs. turmeric (*Curcuma longa*). *Acta Histochemica*, 114: 421-428.
27. Ernst E (2009). Complementary and alternative medicine (CAM) and cancer: The kind face of complementary medicine. *Int. J. Surg*. 7: 499-500
28. Ezzikouri S, El Feydi AE, Afifi R, Benazzouz M, Hassar M, Pineau P, Benjelloun S. (2010). Polymorphisms in antioxidant defence genes and susceptibility to hepatocellular carcinoma in a Moroccan population. *Free Radic Res. Feb*;44(2):208-16.
29. Fontanini G, Vignati S, Boldrini L, Chine S, Silvestri V, Lucchi M, et al. (1997). Vascular endothelial growth factor is associated with neovascularization and influences progression of non-small cell lung carcinoma. *Clin Cancer Res*, 3: 861-5.
30. Forouzandeh H, Azemi MME, Rashidi I, Goudarzi M, Kalantari H. (2013). Study of the protective effect of *Teucrium polium* L. extract on acetaminophen-induced hepatotoxicity in mice. *Iran J Pharm Res.*, 12:123-9.
31. Fouad AA, Al-Mulhim AS, Jresat I (2013). Therapeutic effect of coenzyme Q10 against experimentally-induced hepatocellular carcinoma in rats. *Environ Toxicol Pharmacol* 35(1):100–8.
32. Green RM, Flamm S (2002). AGA technical review on the evaluation of liver chemistry tests. *Gastroenterology*, 123 (4):1367–84.
33. Hanachi P, Othman F, Motaleb G (2008). Effect of Berberis vulgaris Aqueous Extract on the Apoptosis, Sodium and Potassium in Hepatocarcinogenic Rats. *Iran J Basic Med Sci.*, 1: 49–54.
34. Hirai H (1982). Alpha fetoprotein. In: Chu T M, ed. *Biochemical markers for cancer*. New York: Marcel Dekker, 23-59.
35. Hiramoto K, Ryuno Y, Kikugawa K (2002). Decomposition of N-nitrosamines, and concomitant release of nitric oxide by Fenton reagent under physiological conditions. *Mutat Res*, 520:103-111.
36. Holmes EH, Hakomori SI (1982). Isolation and characterization of a new fucoganglioside accumulated in precancerous rat liver and in rat hepatoma induced by N-2-acetylaminofluorene. *J Biol Chem*, 257:7698-7703.
37. Iqbal S, Bhangar MI, Akhtar M, Anwar F, Ahmed KR, Anwer T, (2006). Antioxidant properties of methanolic extracts from leaves of *Rhazya stricta*, *Journal of Medicinal Food*, 9: 270-275.
38. Jozkowicz A, Cooke JP, Guevara I, Huk I, Funovics P, Pachinger O, Weidinger F , Dulac J. (2001). Genetic augmentation of nitric oxide synthase increases the vascular generation of VEGF. *Cardiovasc Res.*, 51:773-783.
39. Kalra M, Mayes J, Assefa S, Kaul AK and Kaul R (2008). Role of sex steroid receptors in pathobiology of hepatocellular carcinoma. *World J. Gastroenterol.*, 14: 5945-5961.
40. Kandouz M, Alachkar A, Zhang L, Dekhil H, Chehna F, Yasmeen A, Al Moustafa AE. (2010).Teucrium polium plant extract inhibits cell invasion and motility of human prostate cancer cells via the restoration of the E-cadherin/catenin complex. *Journal of Ethnopharmacology* 129: 410–415
41. Khan TH (2012). Soy diet diminish oxidative injure and early promotional events induced by CCl4 in rat liver. *Int J Pharmacol.*, 8(1): 30-38.
42. Kim JM, Kwon CHD, Joh J-W, Park JB, Ko JS, Lee JH. (2013). The effect of alkaline phosphatase and intrahepatic metastases in large hepatocellular carcinoma. *World J Surg Oncol* 11(1):40.
43. Koss B, Greengurd O. (1982). Effect of neoplasma on the content and activity of alkaline phosphatase and gamma glutamyl transpeptidase in uninvolved host tissues. *Cancer Res*, 42: 2146–2151.
44. Kuete V, Wiench B, Alsaid S Mansour, Alyahya A Mhammad Fankam G Aimé, Shahat A Abdelaaty, Efferth (2013). Cytotoxicity, mode of action and antibacterial activities of selected Saudi Arabian medicinal plants. *BMC Complementary and Alternative Medicine*, 13: 354.
45. Ladd, J, Lu H, Taylor AD (2009). Direct detection of carcinoembryonic antigen autoantibodies in clinical human serum samples using a surface plasmon resonance sensor. *Colloids SurfB: Biointerfaces*, 70:1-6.
46. Lazarevich NL (2000). Review: Molecular mechanisms of alpha-fetoprotein gene expression. *Biochemistry (Moscow)*; 65:117-133.
47. Li CJ, Wang C, Padee AB (1995). Induction of apoptosis by beta-lapachone in human prostate cancer cells. *Cancer Res*, 55: 3712–3715.
48. Li N, Xiao B, Chen XB (2008): Relationship between expression of CEA, E-cadherin and liver metastasis in colorectal cancer. *Chin J Clin Oncol.*, 5:429-32.

49. Malaguamera G, Giordano M, Paladina I, Berretta M, Cappellani A and Malaguamera M (2010). Serum markers of hepatocellular carcinoma. Dig. Dis.Sci., 55: 2744-2755
50. Maria ND, Manno M and Villa E (2002). Sex hormones and liver cancer. Mol. Cell. Endocrinol. , 193: 59-63.
51. Marwat SK, Rehman F, Usman K, Shah SS, Anwar N, Ullah I (2012) A review of phytoemchistry, bioactivities and ethno-medicinal uses of *R. stricta* Decsne (Apocynaceae). African Journal of Microbiology Research, 68:1629–1641.
52. Menichini F, Conforti F, Rigano D, Formisano C., Piozzi F, Senatore F. (2009). Phytochemical composition, anti-inflammatory and antitumour activities of four *Teucrium* essential oils from Greece Food Chemistry, 115: 679-686
53. Minguez, B.; Tovar, V.; Chiang, D.; Villanueva, A. and Llovet, J.M. (2009). Pathogenesis of hepatocellular carcinoma and molecular therapies. Cur Opin. Gastroenterol., 25:186-194.
54. Nagler A, Ohana M, Shibolet O, Shapira MY, Alper R, Vlodavsky I, Pines M, Ilan Y. (2004). Suppression of hepatocellular carcinoma growth in mice by the alkaloid coccidiostat halofuginone. Eur J Cancer.; 40(9):1397-403.
55. Narasinga Rao Bs (2003). Bioactive phytochemicals in Indian foods and their potential in health promotion and disease prevention, Asia Pacific J Clin Nutr., 12 (1): 9-22
56. Panovska TK, Ulevanova S, jorgoski I, Bogdanova M, Petrushevska G (2007). Hepatoprotective effect of the ethyl acetate extract of *Teucrium polium* L. against carbontetrachloride-induced hepatic injury in rats. Acta Pharm., 57 241–248
57. Piozzi F, Bruno M, Rosselli S, & Maggio A (2005). Advances on the chemistry of furano-diterpenoids from *Teucrium* genus. Heterocycles, 65, 1221–1234.
58. Rajabalian S (2008). Methanolic extract of *Teucrium polium* L. potentiates the cytotoxic and apoptotic effects of anticancer drugs of vincristine, vinblastine and doxorubicin against a panel of cancerous cell lines. Experimental Oncology 30: 133–138.
59. Rougier P, Mitry E, Barbare JC, Taieb J (2007). Hepatocellular carcinoma (HCC): an update. Semin. Oncol., 34: 12-20.
60. Saroglou V, Arfan M, Shabir A, Hadjipavlou-Litina, D., Skaltsa, H. (2007). Composition and antioxidant activity of the essential oil of *Teucrium royleanum* wall. ex benth growing in Pakistan. Flavour and Fragrance Journal, 22, 154–157.
61. Schwartz MK (1987). Tumor markers in diagnosis and screening. In: Ting SW, Chen JS, Schwartz MK, eds. Human tumor markers, Amsterdam: Elsevier Science, 3-16.
62. Sell S, Becker F, Leffert HL, sborn KO, Salman J, ombardi BL, Shinozuka H, Reddy J, oushlahti ER, Sala-Trepat J. (1983). α -Fetoprotein as a marker for early events and carcinoma development during chemical hepatocarcinogenesis. Environ Sci Res, 29: 271–293.
63. Seufi A, Safinz S, Ibrahim S, Elmaghraby TK , Hafez EE. (2009). Preventive effect of the flavonoid, quercetin, on hepatic cancer in rats via oxidant/antioxidant activity: molecular and histological evidences. J Exp Clin Canc Res, 28:80-86.
64. Shahat AA, Alsaid SM Alyahya AM, Higgins M and Dinkova-Kostova TA (2013) NAD(P)H:quinoneoxidoreductase 1 (NQO1) inducer activity of some Saudi Arabian medicinal plants. Planta Medica, 79: 459-464
65. Song Y, Jin S, Cui L, Ji X , Yang F (2013). Immunomodulatory effect of *stichopus japonicus* acid mucopolysaccharide on experimental hepatocellular carcinoma in rats. Molecules, 18: 7179-7193.
66. Tanira MO, Ali BH, Bashir AK, Dhanasekaran S, Tibricia EM and Elves LM (2000). Mechanism of the hypotensive activity of the alkaloidal fraction of *Rhazya stricta*. Pharmacol Res, 41:369-378.
67. Tietz NW (1995).Clinical Guide to Laboratory Tests, 3rd ed. W.B. Sanuders Co. Philadelphia PA.
68. Vanisree AJ, Shyamaladevi CS (1998). Effect of therapeutic strategy established by N-acetyl cystine and vitamin C on the activities of tumour marker enzymes in vitro. Ind J Pharmacol., 31: 275-278.
69. Vischer PT, Reutter W (1978). Specific alterations of fucoprotein biosynthesis in the plasma membrane of Morris hepatoma 7777. Eur J Biochem., 84:363-368.
70. Wang S, Penchala S, Prabhu S, Wang, J and Huang Y (2010). Molecular basis dtraditional Chinese medicine incancer chemoprevention. Curr. Drug Discovery Technol., 7: 67-75.
71. Willyard C. (2007). Researchers look for 'sweet' method to diagnose cancer. Nat Med., 13:1267
72. Zhang M, Cui SW, Cheung PCK, and Wang Q Antitumor (2007). Polysaccharides from mushrooms: a review on their isolation process structural characteristics and antitumor activity. Trends Food Sci. Technol., 18: 4-19.