

Yi Liu¹, Jian Song*², Li -Li Xu³, Xiao-jun Huang⁴, Hai-tao Lan⁴, Wen-gang Qin⁵ Mendame Ehya Regis Ernest²

¹The fifth Department of Orthopedics, Taihe Hospital Affiliated to Hubei University of Medicine, Shiyan City, Hubei Province, China 731171798@qq.com.

²Department of Orthopedics, Zhongnan Hospital of Wuhan University, No 169 Donghu Road, Wuchang District, 430071, Wuhan, China songjianwhu@sina.com.

³Department of Neurology, Taihe Hospital Affiliated to Hubei University of Medicine, Shiyan City, Hubei Province, China

⁴Department of Urology, Dongfeng Hospital, Hubei University of medicine, Shiyan City, Hubei Province, China.

⁵Department of Scientific Research and Education, Dongfeng Hospital, Hubei University of medicine, Shiyan City, Hubei Province, China.

Corresponding *E-mail: songjianwhu@sina.com

Abstract

Background: To investigate the application of Flow-through free vascularized fibular graft combined with Vacuum Assisted Closure for the patients suffering from tibial defects caused by chronic osteomyelitis.

Methods: We retrospectively analysed 20 cases of patients who accepted this operation in the treatment of tibial defects. Among the tibial defects, six cases resulted from blood stream infection while 14 cases resulted from comminuted fractures. All the patients included in the study were accompanied with 1 to 3 sinuses. The length of the defects ranged from 6cm to 16cm, with an average of 11.3cm. 6 patients were also faced with soft tissues defects combined with tendon or bone exposures, and the defects areas ranged from 11cm×7cm to 19cm×14cm. There were 5 patients suffering from fibular fractures at the same side of the defects. The courses of this disease were 5.5 -15 months, with an average of 9.8 months.

Results: The patients included in the study were followed up from 10 months to 4 years, with an average of 1.9 years. Sinuses of 18 patients healed within 4 weeks, giving a primary healing rate of 90%. We undertook debridement of the remaining sinuses and they healed within 2 weeks. All skin flaps grafted to the patients survived, thus the survival rate was 100%. The radiographs indicated that 18 patients had good prognosis and the primary union time of grafting fibula were from 4 to 8 months, with average of 6.3 months. The healing patients achieved an average of 25.6 points based on the Enneking evaluation system which was used to evaluate the function of limbs after the operation, indicating that 85.9% of the limb function recovered. 4 patients required revision surgery for complications resulting from the operation: 1 wound breakdown, 2 bone non-unions, 1 graft fracture. Infection occurred only as a pin-tract infection, and was controlled with oral antibiotics and repeated dressing; there was no deep infection out of control in any of these patients.

Conclusion: The flow-through free vascularized fibular graft did not only repair tibial defects, but retained the continuity of trunk vessels. The flow-through fibular graft combined with Vacuum Assisted Closure (VAC) controlled the infection, shortened the course of treatment, and effectively restored limb function when applied to the treatment of tibial defects.

Key words: Tibial defect, Flow-through fibular graft, Vacuum Assisted Closure, Chronic Osteomyelitis.

Introduction

As the society and industry develop, chronic osteomyelitis resulting from blood stream infection and comminuted fractures have become big problems in the clinic, and resection of the dead bone caused by chronic osteomyelitis often leads to bone defects and non-union (Templeman et al., 1998; Watson et al., 1995; Muhr et al., 1998.). Reconstruction of the tibial defect is difficult and the common therapies included vascularized/non-vascularized bone auto-graft and allograft. Non-vascularized bone grafts may lead to non-union and repeated fractures and they do not exhibit compensatory hypertrophy, so the method is only suitable for the small tibial defects; Vascularized fibular grafts based on the peroneal vessels have been recognized to be useful for reconstructing large tibial defects following chronic osteomyelitis (Brigman et al., 2004; Kinkel et al., 2010; Rodl et al., 2000). Vascularized fibular graft was used to recover the integrity of grafting trunk vessel by anastomosing both extremities. The operation does not only reconstruct the tibial defects, but increases the blood supply to the distal limb, especially for the patients with only one trunk vessel left.

We treated the patients suffering from large tibial defects with flow-through fibular graft combined with Vacuum Assisted Closure, which provides intermittent or continuous sub-atmospheric pressure through a specialized pump, which was connected to a resilient, open-celled, foam-surface dressing covered with a semipermeable membrane to maintain a closed environment. Twenty cases of patients treated with flow-through vascularized fibular graft in combination with VAC between 2004 and 2014 were enrolled in the study.

Materials and Methods

The 20 patients with tibial defects included 11 males and 9 females. Their average age was 31.5 years (range 15 to 49 years). The causes of the defects were as follows: 6 resulted from chronic osteomyelitis caused by blood stream infection, 14 resulted from chronic osteomyelitis caused by comminuted fracture. Of the 20 defects, 12 were located on left tibia while 8 were located on right tibia. All the 20 patients were accompanied with 1 to 3 sinuses. The length of the defects ranged of 6 -16cm, with average of 11.3 cm. 6 patients were also faced with soft tissue defects combined with

tendon or bone exposures; the defect areas ranged from 11 cm × 7 cm to 19 cm × 14 cm. 5 patients suffered from fracture of fibula on the same side of the tibial defects. Bacterial culture of the necrotic bone comes up positive. Twelve cases were *Staphylococcus aureus*, 6 cases were *Bacillus coli*, 2 cases were *Pseudomonas aeruginosa*. The courses of this disease were 5.5 -15 months, with an average of 9.8 months.

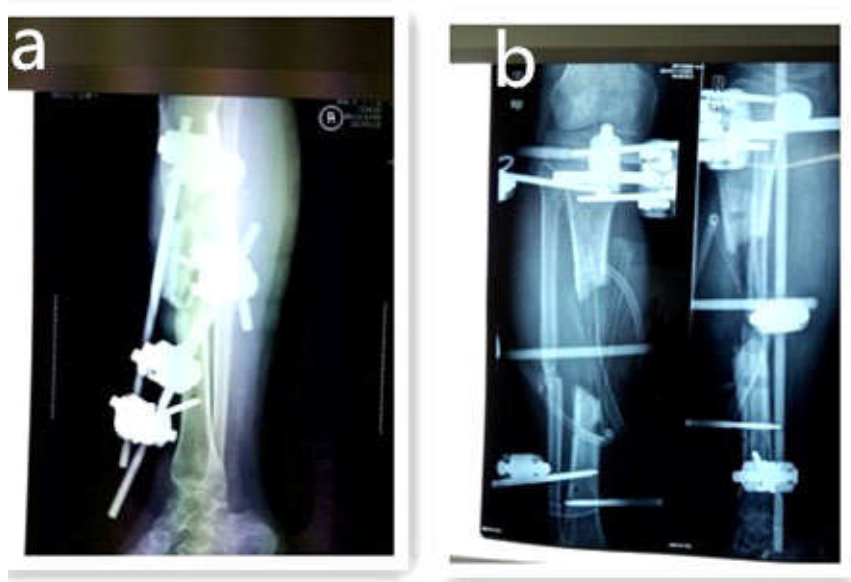


Figure 1: A 23 year old male patient with a comminuted fracture of the tibia, a. The radiograph 1 month after the fracture b. The radiograph, after clearance of the necrotic bone

All patients received antibiotic therapy targeted for the specific bacteria for more than 2 weeks before the operation. The operation was carried out with either general or epidural anaesthesia; 2-3 ml methylene blue was injected into the sinus to stain the dead bones. The patients were placed in the supine position. An anterolateral crural incision was made and granulation tissue, necrotic bone were removed from the defects. The remaining fragments of dead bones stained with methylene blue were also cleared away. 3% hydrogen peroxide solution and iodophor were used to clean the wound three times and the remaining tissues were soaked in the saline containing sensitive antibiotics. Sclerotic bones near the fracture were removed and the bone marrow cavities were opened again. We identified and isolated the anterior artery and tibial vein between anterior tibial muscles and extensor *digitorum longus*; the separated blood vessels were carefully protected.

Fourteen fibular flaps were removed from the uninjured side to reconstruct the tibial defects. 6 fibular flaps combined with skin flaps were also used to treat the tibial defects accompanied by skin defects and bone exposures. The following points must be given special attention when the fibula is resected: (1) The incision starts from posterolateral fibulae capitulum to expose the common peroneal nerve, the soleus muscle attached to the upper part of the fibula should be cut apart to expose the beginning of the artery and peroneal vein; (2) For the patients accepting skin flap graft, we should lanced trailing edge of the skin flaps, adjust their position according to the starting points of the cutaneous arteries and musculo-cutaneous arteries, to ensure that the vessels were located in the centre of the skin flaps; (3) Muscular sleeves about 0.5 - 1 cm thick should be retained to the surface of fibula, to achieve the purpose of making the arcuate arteries between muscular sleeve and periosteum, to avoid being stimulated by inflammatory exudates; (4) The both extremities of arteries and peroneal veins should be long enough to avoid tension on the anastomosis.

Different kinds of fixation methods were used based on specific position of the tibial defects: (1) Plate fixation was adopted to fix the grafting fibula when the defects were accompanied with fractures of the fibulas at the same side; (2) When the defects area was located in the upper and middle tibia, 2 - 3 cm long bone marrow cavity was reamed near the proximal defect and a slotting was made in the distal defect, the fibula was inserted into the cavity and the slotting, 1 to 2 screws were used to fix the grafting fibula at both extremities of the defect area; (3) When the defects area was located in the lower and middle tibia, the position of reaming bone marrow cavity and slotting changed and others operation was just as was mentioned above. We anastomosed skin flaps with surrounding skin near the defects area without tension for the patients accepting skin flap grafts. The proximal peroneal artery of the grafting fibula was anastomosed with the proximal anterior tibial artery of the tibial defects area; the distal peroneal artery was anastomosed with the distal anterior tibial artery to achieve the effects of blood flow-through. One peroneal vein of the graft was anastomosed with the anterior tibial vein and the other one was anastomosed with peroneal vein near the defect area. We checked for patency at the anastomoses, also, the colour and elasticity of the skin flaps grafted to the skin defects.

Vacuum-Assisted Closure therapy has been applied to the fibular graft for patients suffering from tibial defects. The devices consists of four components: a negative pressure generating unit with a disposable canister, a pad with evacuation tube, and a reticulated, open cell sterile polyurethane or a dense open-pore polyvinyl alcohol foam dressing which were cut to fit the wound, transparent membranes were used to cover the wound and block the contact between the wound and external environment. The system unit was programmed to deliver specific negative pressure ranging from 50 to 200 mmHg. VAC should be used for 7 to 14 days based on condition of the grafting zone and healing of the grafting fibula.

Ethical approval of the project proposal was given by the medical ethics committee of Wuhan University (AF/SC-03/02.0). All the enrolled individuals were based on records and then followed up to give their consent as the notion is created that they had the procedure already knowing that they had been enrolled on this study. And all the enrolled studies were retrospective. Verbal informed consent about the research was obtained because the patients could not write and the others were written in Chinese and kept in the medical record room. All the consent on behalf of the children enrolled was written and kept in the medical records room and is only made available when there is a medical dispute and would be provided to the judge.

Results

After 10 months to 5 years follow-up, with an average of 1.9 years, Sinus of the 18 patients healed within 4 weeks and the healing rate was 90%. We undertook debridement of the unhealed sinuses and they also healed within 2 weeks. All the skin flaps grafted to the patients survived and the survival rate was 100%. The radiograph indicated that the 18 patients had good prognosis of the grafting fibulas and the primary union time ranged from 4 to 8 months, the average time was 6.3 months: 4 were from 4.1 to 5.0 months, 4 were from 5.1 to 6.0 months, 3 were from 6.1 to 7.0 months, 7 were from 7.1 to 8.0 months. The healing patients of the grafting fibula achieved an average of 25.6 points with full marks of 30 based on the Enneking evaluation system (Enneking et al., 1993) which was usually used to evaluate limbs function after the graft, indicating that 85.9% of the limbs function recovered: (13 were from 26 to 30 points, 3 were from 21 to 25 points, 1 was from 16 to 20, 1 case was below 16 points). The grafting fibulas of the patients less than 18 years grew faster than that of the patients more than 18 years according to the radiological evaluation method for the vascularized fibular graft (Chew et al., 1995). Four patients required revision surgery for complications resulting from the graft: 1 from wound breakdown, 2 from bone non-union, and 1 from graft fracture. Infection occurred only as a pin-tract infection, and was controlled with oral antibiotics and repeated dressing, but there was no deep infection out of control in any of these patients.

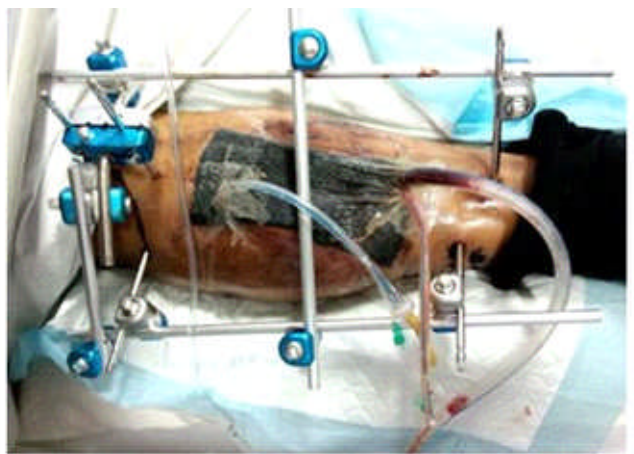


Figure 2: Grafting area covered with VAC after the operation

Discussion

Tibial defect caused by chronic osteomyelitis is a refractory disease - the patients suffering from it were faced with long time of hospitalization, high expense and poor prognosis. In the past 30 years, orthopaedists used the following principles: removal of the granulation tissue(s) and dead bone, elimination of the cavities, and use of vasodilators to improve blood circulation. Reconstruction of tibial defects after removal of the necrotic bone is rather difficult, but great progress has been made. Depending on various parameters such as length of the defects and patient age, there are different reconstruction techniques that can be adopted, each of which has its advantages and disadvantages. Non-vascularized bone auto-graft and allograft are adopted to reconstruct defects less than 5cm while vascularized fibular grafts are the most common treatment for necrotic tibial defects greater than 5cm (Brigman et al. 2004; Kinkel et al., 2010; Rodl et al., 2000; Enneking et al., 1993. The advantage of vascularized periosteal graft is that they provide the non-union focus and surrounding tissues a more extensive contact with the cambium layer and its stem cells. The cambium layer, in intimate contact with the non-union focus and the poorly vascularized surrounding tissues, might promote bone revascularization and healing more efficiently (Soldado et al., 2012). The fibula owns a triangular cross-section with characteristics of resisting angular and rotational stresses, consequently, the grafting fibula owned the function of internal fixation (Ma et al., 2014). The grafting fibular flap owned strong adaptability, providing up to 25 cm long high density straight cortical bone with a good vascular pedicle, providing rapid union in a short time between the graft and the recipient bone (Zaretski et al., 2004).

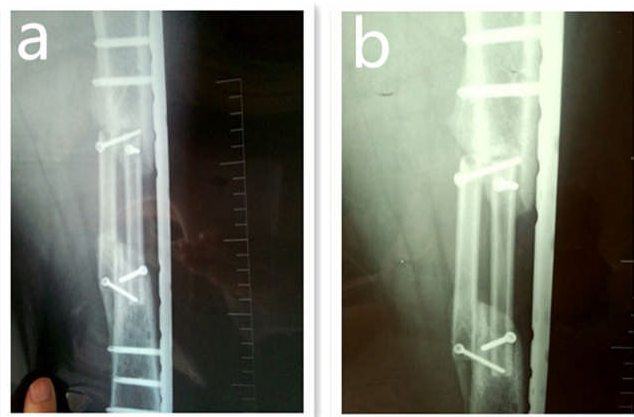


Figure 3: a. Radiograph: 6 months after the graft b. Radiograph: 12 months after the graft

The grafting fibula was constantly thickening with new bone creeping along it - the thickening parts were cortical bone, the tibial defects were finally replaced by grafting fibula (Chen et al., 2014; Tanaka et al., 2012). However, the grafting fibula would not grow indefinitely and the maximum value of the diameter was no more than the tibia (Li et al. 2011). The grafting fibula grew slowly for the patients more than 18 years old and we concluded that age was an important factor influencing the growth of grafting fibula. Studies also showed that periosteum in young people were quite thick, relatively easy to harvest, and exhibited greater osteogenic power than in adults (Soldado et al., 2012; Critchlow et al., 1994). However, the conventional fibular graft sacrifices a major vessel of the grafting fibula; it also requires immediate postoperative monitoring of circulation to the graft, demanding another team skilled in this micro-vascular technique, involving a long operative time (Germain et al., 2007).

Table 1: Data for all of the patients included in this study

Pt.no	Age	Sex	Histology	Fracture of fibula	Bone defects(cm)	side of defect	Soft tissues defects (cm ²)	Disease course(month)
1	23	Male	comminuted fractures	No	7.5	Left	11cm×7cm	5.5
2	35	Female	comminuted fractures	No	12	Left	14cm×12cm	6
3	43	Female	comminuted fractures	No	11	Right	15cm×9cm	7
4	27	Female	blood stream infection	Yes	15	Right	13cm×11cm	9
5	19	Male	blood stream infection	No	6	Left	12cm×12cm	13
6	42	Male	comminuted fractures	Yes	15	Left	19cm×14cm	15
7	33	Female	comminuted fractures	No	12.5	Right	12cm×10cm	12
8	25	Female	blood stream infection	No	11	Right	15cm×9cm	10
9	15	Male	comminuted fractures	Yes	8	Left	17cm×9cm	7.5
10	44	Male	comminuted fractures	No	9	Left	15cm×14cm	9.5
11	28	Male	comminuted fractures	Yes	14	Left	18cm×9cm	13
12	34	Female	comminuted fractures	No	12	Right	16cm×12cm	8.5
13	49	Male	blood stream infection	Yes	15	Left	14cm×8cm	6.5
14	36	Male	comminuted fractures	No	11	Left	14cm×11cm	11
15	33	Female	comminuted fractures	No	8	Right	17cm×14cm	8.5
16	41	Female	comminuted fractures	No	12	Left	12cm×14cm	12
17	26	Male	blood stream infection	No	9.5	Right	11cm×8cm	9
18	28	Male	blood stream infection	Yes	7	Left	19cm×13cm	10
19	35	Male	comminuted fractures	No	15	Left	14cm×14cm	12
20	40	Female	comminuted fractures	No	16	Right	15cm×9cm	10

The traditional treatment of blood vessels was that the proximal peroneal artery of the vascularized fibular flap was anastomosed with anterior tibial or peroneal artery of the proximal tibial defects area, while the distal peroneal artery of grafting fibular flap was ligated. 1 to 2 peroneal veins of the grafting fibular flap were anastomosed with the superficial vein near the defects area. The treatment of blood vessels did not only provide the blood supply for the grafting fibular flap, but facilitates the return of venous blood from the grafting fibular flap, increasing the success rate of fibular graft finally. However, this kind of treatment destroys the anatomical structure of the grafting artery; blood supply of distal limbs is also weakened because of the ligation of the distal peroneal artery. Flow-through arterial anastomosis was used in clinic by (Soutar et al., 1983) in the nineteen eighties and soon became widely applied to the reconstruction of soft tissues and bones defects. We used the method in combination with fibular grafts to reconstruct tibial defects and satisfactory results were achieved. Flow-through arterial anastomosis improves the patency rate and stabilizes the circulation of the graft, and it was demonstrated that flow-through arterial anastomosis has a higher patency rate than end-to-end and end-to-side anastomoses, increases the flow rate through the anastomotic sites (Miyamoto et al., 2008., and 2014) believed that flow-through arterial anastomosis helped maintain a high flow rate through the anastomotic site, and facilitated early mobilization for the grafting patients. The method is also adopted to establish main artery channel of the fibular flap and recovers anatomical structure and continuity of the main artery, providing more blood supply for the distal limbs and tissues connected with the tibial defects area, especially for the patients with only one main artery left (Garvey et al., 2012).

Vacuum Assisted Closures (VAC) was applied to the fibular graft and achieved good results. The transparent membrane covering the fibular grafting zone blocked the contacts between the grafting fibula and outside environment. Tube connected to the dressing could exclude the pollutants, and finally achieved the purpose of anti-infection. However, (Anagnostakos et al., 2012), indicated that both polyurethane and polyvinyl alcohol foam can be colonized by different bacterial organisms - no precise guidelines existed regarding the ideal period of VAC changes or whether a residual bacterial load in the wound might affect the future outcome (Berger et al., 2012). Significantly higher Interleukin 8 (IL-8) and vascular endothelial growth factor (VEGF) levels were detected during VAC therapy, which can stimulate the grafting wound vascularization, providing more survival chance for the grafting fibula (Labler et al., 2009). Studies also showed that VAC increased the capillary diameter and secretion of vasoactive substances, decreased the after-loading of the trunk blood vessels, achieving the purposes of increasing blood supply for the grafting fibula (Hunsicker et al., 2004; Narita et al., 2002). Negative pressure tension provided by VAC increased the diameter of vessels and blood flow to increase blood supply of the grafted fibula and more venous blood returning to the heart (Blume et al., 2008; Sepulveda et al., 2009). VAC can also attach (suggesting the use of the word *appose* instead) the skin flap to the grafting zone closely. However, the concern was that the vacuum suction with high pressure may damage the anastomosed blood vessels and lead to failure of the operation.

Anti-infection therapy before the operation was one of the key factors determining success of the operation and the course of anti-infection therapy was 2 or 3 weeks. It was forbidden to adopt the fibular graft for the patients suffering from serious infection, acute attack of the osteomyelitis and other serious diseases. Complete removal of the dead bone and inflammatory granulation tissue were also key factors determining success of the operation. Application of papaverine and dextran-40 can effectively promote the patency rate of anastomosed blood vessels. Stress fracture of a vascularized fibular graft is a complication that had been reported by many authors, even in early hypertrophied bone (Toh et al., 2001; Ceruso et al.

2008) Repetitive mechanical loading which exceeds the bone strength was the main cause of this complication. The application of external fixation was required in case of fractures of the grafting fibula after the operation, the commonly used external fixation device were external fixator or splint. However, some studies reported that a non-union rate of 11-32% was detected when auto-graft was used in combination with external fixation in the reconstruction of tibial defects area; it was mainly because the external fixation would destroy the blood supply and the mechanical environment would lead to displacement between fracture fragments (Steinlechner et al., 2005; Kocaoglu et al., 2006). Animal and clinical studies proved that part of weight loading in the early stage following surgery can promote the union, stimulate the thickening of grafting bone and reinforce the strength and stability in the grafting zone (Muramatsu and Bishop 2002). The periods of use of the VAC ranged from 7 to 14 days based on condition of the grafting zone and healing of the fibula grafted to the tibial defect area. The value of the negative pressure ranged from 50 - 200 mmHg while high negative pressure would lead to damage of the tissues and low negative pressure did not work for the grafted fibula survival rate.

Table 2: Results of Bones Healing

Pt.no	Flow-up Period(month)	Bone healing (month)	Score of EES	Sinus healing Within 4 weeks	complication
1	15	5.5	26	Yes	No
2	36	4.5	29	Yes	No
3	24	6.5	26	Yes	No
4	48	7.8	22	Yes	No
5	35	8	29	Yes	No
6	10	4.5	23	Yes	No
7	16	No healing	No healing	No	Bone non-union
8	12	7.5	15	Yes	No
9	14	8	25	Yes	No
10	18	5.2	30	Yes	Wound breakdown
11	32	4.8	28	Yes	No
12	26	6.5	17	Yes	No
13	23	7.6	28	Yes	No
14	18	7.5	30	Yes	No
15	36	6.4	26	Yes	Graft fracture
16	19	5.5	27	Yes	No
17	26	4.0	29	Yes	No
18	25	7.5	26	Yes	No
19	17	No healing	No healing	No	Bone non-union
20	16	5.2	28	Yes	No

Conclusion

The application of flow-through fibular graft is an effective and reliable method to treat the tibial defects caused by chronic osteomyelitis, especially in the patients with large defects more than 5 cm, it does not only reconstruct the tibia defects, but retains the continuity of grafting trunk vessels. The operative technique in combination with Vacuum Assisted Closure in the treatment of tibial defects controls the infection, shortens the treatment course, and restores the limb’s function effectively.

References

- Anagnostakos, K. and Mosser P. (2012). Bacteria identification on NPWT foams: clinical relevance or contamination? *J Wound Care* 21: 333-334, 336-339.
- Berger, P., de Bie, D., Moll, F.L., and de Borst, G.J. (2012). Negative pressure wound therapy on exposed prosthetic vascular grafts in the groin. *J Vasc Surg* 56: 714-720.
- Blume, P.A., Walters. J, Payne .W, Ayala. J and Lantis, J. (2008). Comparison of negative pressure wound therapy using vacuum-assisted closure with advanced moist wound therapy in the treatment of diabetic foot ulcers: a multicenter randomized controlled trial. *Diabetes Care* 31: 631-636.
- Brigman, B.E., Hornicek, F.J., Gebhardt, M.C. and Mankin, H.J. (2004). Allografts about the Knee in Young Patients with High-Grade Sarcoma. *Clin Orthop Relat Res*: 232-239.
- Ceruso, M., Taddei, F., Bigazzi, P. and Manfrini, M. (2008) .Vascularised fibula graft inlaid in a massive bone allograft: considerations on the bio-mechanical behaviour of the combined graft in segmental bone reconstructions after sarcoma resection. *Injury* 39 Suppl 3: S68-S74
- Chew, W.Y., Low, C.K., Tan, S.K. (1995). Long-term results of free vascularized fibular graft. A clinical and radiographic evaluation. *Clin Orthop Relat Res*: 258-261.
- Chen, H., Zhang, Y., Xia H, Wang, F. and Li, Z. (2014). Stability of tibial defect reconstruction with fibular graft and unilateral external fixation: a finite element study. *Int J Clin Exp Med* 7: 76-83.
- Critchlow, M.A., Bland, Y.S. and Ashhurst, D.E. (1994). The effects of age on the response of rabbit periosteal osteoprogenitor cells to exogenous transforming growth factor-beta 2. *J Cell Sci* 107 (Pt 2): 499-516.
- Enneking, W.F., Dunham, W., Gebhardt, M.C., Malawar, M .and Pritchard, D.J. (1993). A system for the functional evaluation of reconstructive procedures after surgical treatment of tumors of the musculoskeletal system. *Clin Orthop Relat Res*: 241-246.
- Garvey, P.B., Clemens, M.W., and Rhines, L.D (2012). Vertical rectus abdo. minis museuloeutaneous flow—through flap to a free fibula flap for total sacrectomy reconstruction. *Microsurgery*, [Epub ahead of print].

11. Germain, M.A., Mascard, E., Dubouset, J., and Nguefack, M. (2007). Free vascularized fibula and reconstruction of long bones in the child--our evolution. *Microsurgery* 27: 415-419.
12. Hunsicker, L.G. (2004). Emerging trends for prevention and treatment of diabetic nephropathy: blockade of the RAAS and BP control. *J Manag Care Pharm* 10: S12-S17.
13. Kinkel, S., Lehner, B., Kleinhans, J.A, Jakubowitz, E., and Ewerbeck, V. (2010). Medium to long-term results after reconstruction of bone defects at the knee with tumor endoprostheses. *J Surg Oncol* 101: 166-169.
14. Kocaoglu, M., Eralp, L., Rashid, H.U., Sen, C., and Bilsel, K. (2006). Reconstruction of segmental bone defects due to chronic osteomyelitis with use of an external fixator and an intramedullary nail. *J Bone Joint Surg Am* 88: 2137-2145.
15. Labler, L., Rancan, M., Mica, L., Harter, L., and Mihic-Probst, D. (2009). Vacuum-assisted closure therapy increases local interleukin-8 and vascular endothelial growth factor levels in traumatic wounds. *J Trauma* 66: 749-757.
16. Li, J., Wang, Z., Guo, Z., Chen, G.J. and Li, S.W. (2011). The use of massive allograft with intramedullary fibular graft for intercalary reconstruction after resection of tibial malignancy. *J Reconstr Microsurg* 27: 37-46.
17. Ma, L., Zhou, Y, Zhang Y. and Zhou, X., Yao, Z. (2014). Biomechanical evaluation with finite element analysis of the reconstruction of femoral tumor defects by using a double-barrel free vascularized fibular graft combined with a locking plate. *Int J Clin Exp Med* 7: 2425-2434.
18. Miyamoto, S., Okazaki, M., Ohura,N., Shiraishi, T., Takushima, A. (2008).Comparative study of different combinations of microvascular anastomoses in a rat model: end-to-end, end-to-side, and flow-through anastomosis. *Plast Reconstr Surg* 122: 449-455.
19. Miyamoto, S., Kayano, S., Fujiki, M., Chuman, H. and Kawai, A. (2014). Early Mobilization after Free-flap Transfer to the Lower Extremities: Preferential Use of Flow-through Anastomosis. *Plast Reconstr Surg Glob Open* 2: e127.
20. Muramatsu, K. and Bishop, A.T. (2002) Cell repopulation in vascularized bone grafts. *J Orthop Res* 20: 772-778.
21. Muhr, G. and Ostermann, P. (1997). [Treatment of open fractures exemplified by tibial shaft fracture]. *Z Arztl Fortbild Qualitatssich* 91: 415-419.
22. Narita, T., Kakei, M., and Ito, S. (2002). Aggressive antihypertensive treatment and serum lipid lowering therapy are necessary to prevent deterioration of the renal function even in elderly type 2 diabetic patients with persistent albuminuria [J]. *Gerontology*48: 302-308.
23. Rodl, R.W., Ozaki, T., Hoffmann, C., Bottner, F. and Lindner, N. (2000). Osteoarticular allograft in surgery for high-grade malignant tumours of bone. *J Bone Joint Surg Br* 82: 1006-1010.
24. Sepulveda, G., Espindola, M., Maureira, M., Sepulveda, E. and Ignacio, F.J. (2009). [Negative-pressure wound therapy versus standard wound dressing in the treatment of diabetic foot amputation. A randomised controlled trial]. *Cir Esp* 86: 171-177.
25. Soldado, F., Fontecha, C.G., Barber, I. and Velez, R., and Llusa, M. (2012). Vascularized fibular periosteal graft: a new technique to enhance bone union in children. *J Pediatr Orthop* 32: 308-313.
26. Soldado, F., Fontecha, C.G, Barber, I., Velez, R., and Llusa, M. (2012). Vascularized fibular periosteal graft: a new technique to enhance bone union in children. *J Pediatr Orthop* 32: 308-313.
27. Soutar, D.S., Scheker, L.R., Tanner, N.S. and McGregor, I.A. (1983). The radial forearm flap: a versatile method for intra-oral reconstruction. *Br J Plast Surg* 36: 1-8.
28. Steinlechner, C.W. and Mkandawire, N.C. (2005). Non-vascularised fibular transfer in the management of defects of long bones after sequestrectomy in children. *J Bone Joint Surg Br* 87: 1259-1263.
29. Tanaka, K., Maehara, H. and Kanaya, F. (2012) .Vascularized fibular graft for bone defects after wide resection of musculoskeletal tumors. *J Orthop Sci* 17: 156-162.
30. Templeman, D.C., Gulli, B., Tsukayama, D.T. and Gustilo, R.B. (1998) .Update on the management of open fractures of the tibial shaft. *Clin Orthop Relat Res*: 18-25.
31. Toh, S., Tsubo, K., Nishikawa, S., Narita, S.and Kanno, H. (2001). Ipsilateral pedicle vascularized fibula grafts for reconstruction of tibial defects and non-unions. *J Reconstr Microsurg* 17: 487-496.
32. Watson, J.T., Anders, M. and Moed, B.R. (1995). Management strategies for bone loss in tibial shaft fractures. *Clin Orthop Relat Res*: 138-152.
33. Zaretski, A., Amir, A., Meller, I., Leshem, D. and Kollender, Y. (2004). Free fibula long bone reconstruction in orthopedic oncology: a surgical algorithm for reconstructive options. *Plast Reconstr Surg* 113: 1989-2000.