

CASE REPORT

Intestinal Obstruction due to Bilateral Ovarian Cystic Teratoma in a Pregnant Woman: Report of a Case

Victor J Ekanem*¹, Duncan O Umukoro² and Gabriel Igberase

¹Department of Pathology, School of Medicine, College of Medical Sciences, University of Benin, Benin City, Edo State, Nigeria;

²Department of family Medicine, Eku Baptist Hospital, Eku, Delta State; ³Department of Obstetrics and Gynaecology, Delta State University, Abraka, Delta State.

*For correspondence: Email: vekanem2000@yahoo.com

Abstract

Teratoma is the most common ovarian tumour associated with pregnancy. The complications in pregnancy include torsion, rupture and malignant transformation mimicking ovarian carcinoma. Its association with intestinal obstruction is uncommon. Case: A 35 year old gravida 5 para 4 woman with 18 week gestation was referred to our hospital with a 2 week history of abdominal pain, abdominal distension and vomiting. Initial physical examination and ultrasound scan showed bilateral ovarian masses and intrauterine singleton viable pregnancy. At surgery the right mass was observed to be adherent to a part of the small intestine. The masses were excised and confirmed grossly and histologically as benign cystic teratoma. She was well and discharged nine days post operatively. The pregnancy was managed conservatively and she was delivered of a normal male baby at term by spontaneous vertex delivery. Although intestinal obstruction due to benign cystic teratoma in pregnancy is uncommon, abrupt surgical intervention and conservative management is important for favourable outcome (*Afr J Reprod Health 2011; 15[1]: 115-118*).

Résumé

Occlusion intestinale causée par le tératome kystique ovarien bilatéral chez une femme enceinte : Rapport d'un cas. Le tératome est la tumeur de l'ovaire la plus commune liée à la grossesse. Les complications dans la grossesse comprennent la torsion, la rupture et la transformation maligne qui cherche à imiter le cancer ovarien. Son association avec l'occlusion intestinale n'est pas commune : Le cas A : Une femme enceinte (gravide 5, 4^{ème} pare) avec 18 semaines de gestation a été orientée vers notre hôpital avec une histoire d'une douleur abdominale, une distension abdominale et le vomissement. L'examen physique initial et l'examen par l'échographie ont montré des masses ovariennes bilatérales et une grossesse viable d'intra-utérine simple. Pendant la chirurgie, on a constaté que la masse à droite était adhérente à une partie de l'intestin. Les masses ont été excisées et ont été confirmées comme étant largement et histologiquement un tératome kystique bénin. Elle s'est bien rétablie et a été renvoyé de l'hôpital neuf jours après l'opération chirurgicale. Nous avons pris en charge la grossesse de manière conservatrice et elle a accouché d'un garçon normal à terme à travers une présentation du sommet. Bien que l'occlusion intestinale causée par le tératome kystique bénigne pendant la grossesse n'est pas commune, il faut une intervention brusque et un traitement conservateur pour réaliser de bons résultats (*Afr J Reprod Health 2011; 15[1]: 115-118*).

Keywords: Intestinal obstruction, Teratoma, Pregnancy

Introduction

Bilateral teratoma associated with pregnancy is a relatively rare condition. Its involvement in intestinal obstruction has not been reported in the literature. For primary diagnosis ultrasound scan is the method of choice. Caspi et. al, reported that women in their reproductive years with an ovarian dermoid cyst less than 6cm in diameter diagnosed by ultrasound scan can be followed safely¹. Mature cystic teratoma is sometimes an incidental finding during physical examination, radiological examination or abdominal surgery. Though the complications of teratoma in pregnancy include torsion, rupture, obstruction to birth canal, there is no reported case of its association with intestinal obstruction.

This report presents a case of bilateral teratoma in a 35 year multiparous woman in association with intestinal obstruction. She was referred from a private hospital to Eku Baptist Specialist Hospital in Delta State of Nigeria for Specialist management.

Case Report

A 35 year old gravida 5 para 4 woman with 18 weeks gestation was referred to our hospital with a 2 weeks history of abdominal pain, persistent vomiting and abdominal distension. The pain was located around the umbilical region and was colicky in nature. There was associated constipation. Initial ultrasound scan done before referral showed a viable singleton cyesis with what appeared to be associated non viable ectopic

pregnancy. It also pointed out that there was associated paralytic ileus. Previous four pregnancies and delivery were uneventful. There was no previous history of twinning and no history of teratoma in her family. The initial physical examination in our hospital showed a well nourished woman with a distended abdomen greater than the gestational age (gait 136cm). There was generalised abdominal tenderness. A repeat ultra sound scan also reported a singleton intrauterine pregnancy with vague abdominal masses on both sides of the uterus and distended bowel loops. A diagnosis of intestinal obstruction in pregnancy was made and a laparotomy was performed. Findings at surgery were those of bilateral ovarian masses with the right causing kinking of the small intestine (ileum). The right mass adhered partially to the ileum and it separated from it without difficulty leaving a healthy looking serosal surface.

The ovarian masses were excised for histology, the intestinal kink was released and peritoneal lavage done. Her recovery was satisfactory and she was discharge 9 days post operatively. She was seen regularly for routine antenatal care. The pregnancy was carried to term and she was delivered of a male baby by spontaneous vertex delivery. APGAR score of the baby at birth was 7 at 1minute and 8 at 5 minutes.

Gross findings

Both lesions were cystic and approximately equal in size. They measured 16cm x 15cm x 14cm with a gray outer surface. The cut sections of the masses showed a cavity filled with hair, yellowish greasy sebaceous material admixed with clear yellowish fluid. Teeth and bony materials were recognised. Most of these features were recognized intra operatively as shown in figures 1-3.

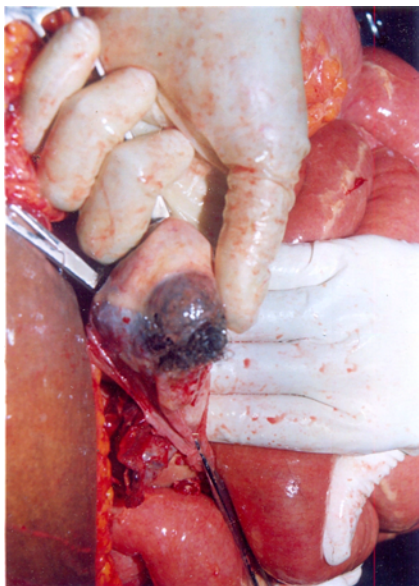


Figure 1: Intra abdominal teratoma being teased from distended bowel loops

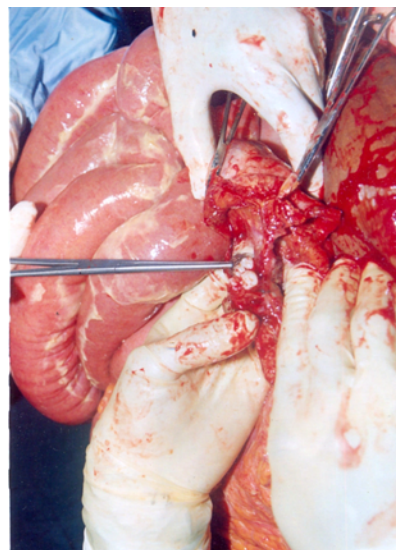


Figure 2: Teeth and other structures exposed at operation

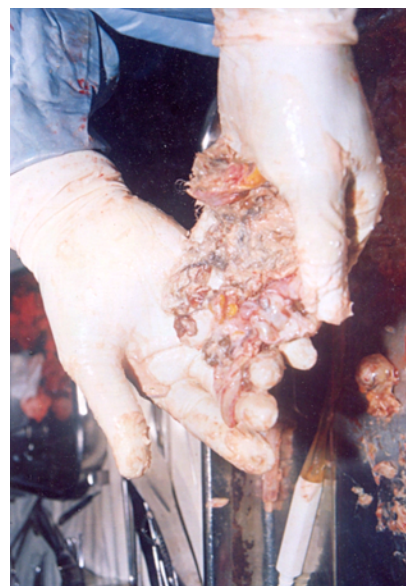

Figure 3: One of the teratomas after operation

Microscopic findings

Both ovaries showed features of benign cystic teratoma consisting of a cystic lesion lined by skin with attached adnexal components such as sweat glands, hair follicle and sebaceous glands. Mucin secreting glands, smooth muscles and cartilage were also seen. Figures 4 and 5.

Discussion

A teratoma is a germ cell tumor derived from pluripotential cells and made up of elements of different types of tissues derived from one or more of the three

germ cell layers. Matured cystic teratoma account for about 5 – 10 percent of all ovarian tumour and is the most common germ cell tumour^{2, 3, 4}. In spite of the fact that most of them are benign, they stimulate considerable interest because of the unusual histogenesis caused by the totipotency of these tumours that may give rise to any bodily structure or tissues.

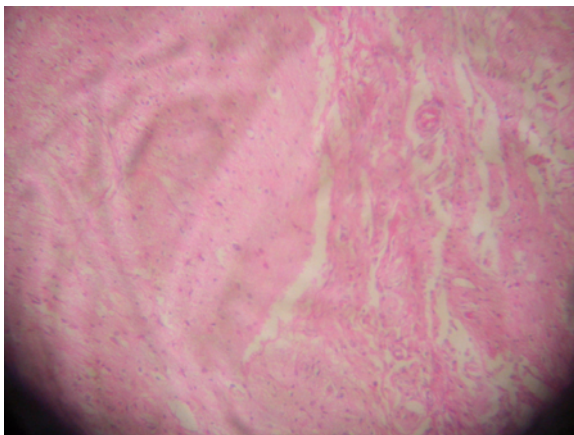


Figure 4: A section of microscopic picture of teratoma showing nerve bundle and muscle tissue

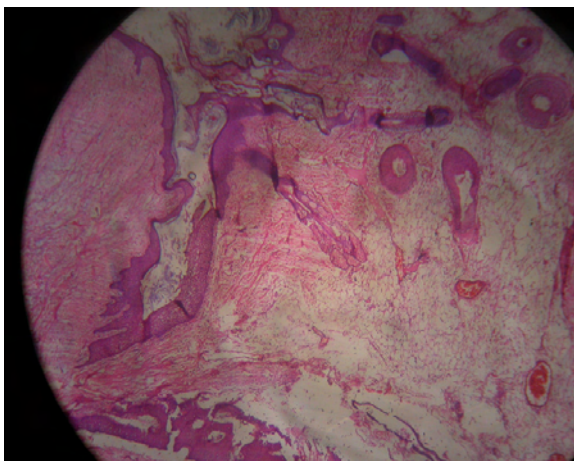


Figure 5: A low power view showing the wall of the teratoma lined by skin containing skin adnexal tissues

The occurrence of teratoma with pregnancy is uncommon, only about 10% of the cases of matured cystic teratoma are diagnosed during pregnancy⁵. With respect to diagnosis, ultrasound scan is the method of choice. It is able to determine the dimension of the tumour.

References

1. Caspi B, Appelman Z, Rabiner-on D, Zalel Y, Tulandi T, Shoham Z. The growth pattern of ovarian dermoid cysts: a prospective study in premenopausal and postmenopausal women. *Fertil Steril* 1997;68:501-5.

Our patient presented at the gestational age of 18 weeks. This tends to agree with the report of Moore and Smith in which they found that most of the cases presented in the second trimester⁶. Merha et al had earlier reported ruptured bilateral teratoma causing peritonitis in pregnancy but this occurred in the first trimester of pregnancy⁷.

Mature cystic teratomas usually occur in young women with a peak age incidence of between the ages of 20 – 40 years⁸. The age of our patient falls within this peak age incidence.

The most frequent symptom of teratoma is lower abdominal pain. Only few cases present for the first time with abdominal mass⁹. Our patient presented with features of intestinal obstruction during pregnancy. The obstruction was not severe enough as to cause gangrene of any segment of the bowel but was able to cause signs and symptoms. There was partial adhesion of the tumour to intestinal wall. The adhesion might have resulted from a response of the surrounding tissue, including intestine to the pressure effect of the tumour. On the other hand it might have also resulted from minor leak of tumour content into the surrounding tissue. However there was no evidence of invasion of the intestinal wall thus ruling out gross feature of malignancy. The association of complications like torsion of the ovary, haemorrhage and malignancy with cystic teratoma in pregnancy has been previously reported¹⁰. The size of the tumour in our patient might have contributed to the complication of intestinal obstruction. The size of the both tumours in our patient was approximately 15cm in diameter. This tumour possibly existed before the onset of pregnancy. Caspi reported that teratomas less than 6cm occurring before pregnancy do not grow during pregnancy¹⁰.

The pregnancy was carried to term. This tend to disagree with the report of Duncan et al which stated that there is an increase risk of spontaneous abortion among pregnant women who were subjected to general anaesthesia and surgery during the first and second trimester¹¹. Another study reported that pre-term labour and fetal growth restrictions, as well as neonatal death, also increase significantly in women who were subjected to surgery during pregnancy¹². However, favourable outcome of pregnancy has also been reported in association with ovarian teratoma¹⁰.

Although intestinal obstruction as a complication of benign cystic teratoma in pregnancy is very rare, the pregnancy can be managed conservatively after excision of a large size tumour. This report has shown early detection and excision of ovarian teratoma in pregnancy and the conservative management of the pregnancy to term.

2. Pepe F, Panella M, Pepe G, Panella P, Pennisi F, Arikian S. Dermoid cysts of the ovary. *Eur J Gynaecol Oncol* 1986; 7: 186– 191.
3. Lakkis WG, Martin MC, Gelfand MM. Benign cystic teratomas of the ovary: a 6-year review. *Can J Surg* 1985; 28: 444 – 446.

4. Bugarara FA. Incidence of the histologic types of ovarian tumours in Benghazi (Libya) and Poland. *Neoplasma* 1983; 30: 251–254.
5. Ayan A, Bukulmez O, Genc C, Kuramursel BS. Mature cystic teratomas of the ovary. A case series from one institution over 34 years. *Eur J Obst Gynecol*, 2000; 88: 153 – 160.
6. Moore RD, Smiht WG. Laparoscopic management of adnexal masses in pregnant women. *J Reprod Med* 1999; 44 (2): 97-100.
7. Mehra U, O’Conor T, Ostapowicz F, Cavanagh D. Pregnancy with bilateral ruptured benign cystic teratomas. *Am J Obstet Gynecol* 1976; 124(4): 361-6.
8. Comerci JT, Licciardi F, Bergh PA, Gregori C, Breen JL. Mature cystic teratomas: a clinicopathologic evaluation of 517 cases and review of the literature. *Obstet Gynecol* 1994; 84: 22–28.
9. Papdias K, Kairi-Vassilatou E, Kontagiani-Katsaros K, Argeitis J, Kondis- Pafitis A, Greatsas G. Teratomas of the ovary: a clinico-pathological evaluation of 87 patients from one institution during a 10-year period. *Eur J Gynaecol Oncol*. 2005; 26(4):446-8.
10. Benjamin Caspi, MD, a Roni Levi, MD, Zvi Appelman, MID, David Rabinerson, MD, Gil Gold,-an, MD, b and Zion Hagay, MD~Conservative management of ovarian cystic teratoma during pregnancy and labor *Am J Obstet Gynecol* 2000;182:503-5.
11. Duncan P, Pope WDB, Cohen MM, Greer N. Fetal risk of anesthesiaand surgery during pregnancy. *Anesthesiology* 1986;64:790-4.
12. Mazze RI, Kallen B. Reproductive outcome after anesthesia and operation during pregnancy: a registry study of 5405 cases. *Obstet Gynecol* 1989;161:1178-85.