

## CASE REPORT

# Acquired Salpingo-Enteric Fistula – A Case Report

Osesogie U Ogbeide<sup>1\*</sup>, Ikechukwu A Ukadike<sup>1</sup>, Festus O Ehigiamusoe<sup>1</sup> and Friday E Okonofua<sup>2</sup>

<sup>1</sup>Department of Radiology, and <sup>2</sup>Department of Obstetrics and Gynaecology, University of Benin Teaching Hospital, Benin City, PMB 1111, Edo State, Nigeria

\*For correspondence: Email: drosesogieogbeide@yahoo.com

## ABSTRACT

Hysterosalpingogram a common radiological examination is routinely used in the investigation of infertility and sub-fertility in women. The close proximity of the uterus to adjacent pelvic structures results in various types of pelvic fistulas after pelvic disease, pelvic radiation therapy, trauma or pelvic surgery. The case of a 34 years old Para 0<sup>+1</sup> woman with a diagnosis of secondary infertility and booked for hysterosalpingogram as part of the routine work-up is presented. There was a positive history of chronic pelvic inflammatory disease, myomectomy and appendectomy. The result showed evidence of opacification of the right fallopian tube with contrast outlining the adjacent large bowels. Asymptomatic pelvic fistulas maybe a silent cause of infertility, and association can only be stated as all other factors of infertility could not be convincingly ruled out (Afr J Reprod Health 2010; 14[1]:139-143).

## RÉSUMÉ

**Fistule de la salpingo-intestinale acquise – Un compte rendu.** L'on se sert systématiquement de l'hystérosalpinogramme, un examen radiologique commun, pour étudier la stérilité et la sous-stérilité chez la femme. Le fait que l'utérus est très proche des structures pelviennes avoisinantes mène à de divers types des fistules pelviennes suite à une maladie pelvienne, une radiothérapie, le traumatisme ou une chirurgie pelvienne. Le cas d'une nullipare âgée de 34 ans avec un diagnostic de la stérilité secondaire et pour qui une place a été réservée pour l'hystérosalpinogramme comme faisant partie du bilan de routine, est présenté dans cette étude. Il y avait une histoire positive de la salpingite aigüe, la myomectomie et l'appendicectomie. Le résultat a montré une évidence de l'opacification de la troupe utérine droite y compris le contraste qui trace les grande lignes de gros intestins adjacents. Des fistules pelviennes asymptomatiques peuvent être une cause silencieuse de la stérilité et l'on ne peut que citer l'association puisque les autres facteurs de la stérilité ne pouvaient pas être facilement exclus (Afr J Reprod Health 2010; 14[1]:139-143).

---

KEYWORDS: Hysterosalpingogram, Infertility, Utero-enteric fistula

---

## Introduction

Tubo-enteric (tubo-intestinal) or salpingo-enteric fistula is a very rare disease<sup>1-3</sup> and occurs whenever there is a connection between fallopian tubes of either side with intestinal loop, either

large or small bowel. This disease may result from obstetric complications from cesarean section, forceps-aided delivery, external cephalic version, curettage for manual removal of placenta or perforation of an intra-uterine device, inflammatory bowel disease like Crohn's

## Acquired Salpingo-Enteric Fistula

diseases, pelvic malignancy, pelvic radiation therapy, pelvic surgery from myomectomy or appendicectomy, iatrogenic causes or trauma.<sup>4-8</sup> Because of the close proximity of the female reproductive organs with other pelvic organs, fistulation can occur between the ureter, small or large bowels resulting in vesico-vaginal, vesico-uterine, vesico-enteric, uretero-vaginal, uretero-enteric and entero-vaginal fistulas.<sup>9-11</sup>

There is a wide variety of complaints in a woman being investigated for infertility suspected with fistulization. This ranges from the asymptomatic to the history of amenorrhea, menouria or cyclic hematuria, passage of urine, feces, perineal dermatitis, foul smelling air or discharge through unfamiliar orifices.<sup>12-14</sup> The actual demonstration of the fistulous tract and identification of its underlying cause is quite tedious and difficult. A variety of radiological modalities are available to identify fistulous communications and these include intravenous urography, cystography, barium enema, vaginography, colpography, ultrasonography, computerized axial tomography, magnetic resonance imaging and hysterosalpingography.<sup>15-19</sup> A search of literature by Hunt et al<sup>20</sup> revealed that till 1990, 14 out of 20 previously documented salpingo-enteric fistula cases were discovered incidentally by hysterosalpingography in infertile women.

The purpose of this case report is to present this rare hysterosalpingographic finding as a possible cause of or an associated factor in infertility.

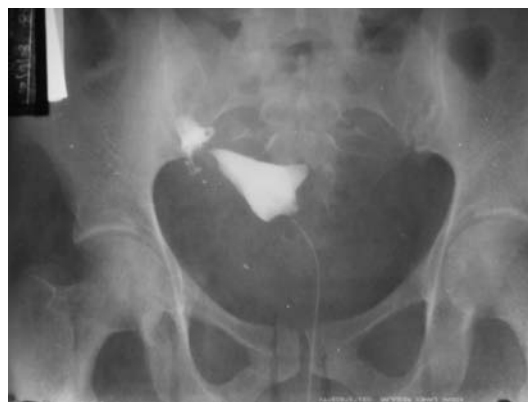## Case report

TA, a 34 years old Para 0<sup>+1</sup> woman, presented to our radiology department for hysterosalpingography as a routine work-up for secondary infertility. She was married for eight years and had not been able to achieve pregnancy. She admitted to a history of having lower abdominal pain and occasional discharge, which described to be on and off. Physical examination revealed that she had copious vaginal discharge. This was suggestive of active pelvic inflammatory disease. Significant information in her past medical history revealed that she had termination of a seven week pregnancy two years before marriage,

which was said to be uneventful. There was a history of myomectomy three years before her presentation and stated that a hysterosalpingography done prior to surgery revealed normal caliber and patent fallopian tubes bilaterally. There was no repeat hysterosalpingography after the myomectomy. She also had appendicectomy in a private hospital about 14 months before presenting for this hysterosalpingography.

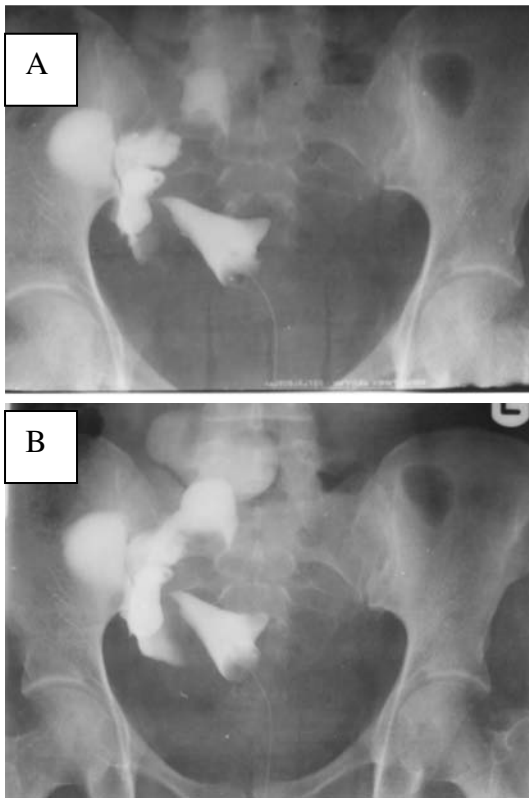
Patient presented for the examination on the 9<sup>th</sup> day of her cycle. She had completed an antibiotic therapy using oral ciprofloxacin and metronidazole.

HSG was done under normal sterile procedure using non-ionic contrast (iohexol 300mg). Following initial injection of about 8ml of contrast, a moderate capacity uterus with regular margins was opacified (figure 1). The left fallopian tube was not opacified at all. The right fallopian tube was visualized with a triangular loculation of contrast in its distal aspect. This lead



**Figure 1:** Initial HSG film showing contrast loculation in the right fallopian tube.

to a suspicion of possible right hydrosalpinx and as such further injections of contrast was done for confirmation. Subsequent films (figure 2), however, revealed contrast opacification of the large bowel as evidenced by the presence of haustrations within the opacified bowel. An oblique radiograph of the pelvis (figure 3A) and a true lateral radiograph of the abdomen (figure 3B), was done. Diagnosis of tubo-enteric fistula was therefore made.

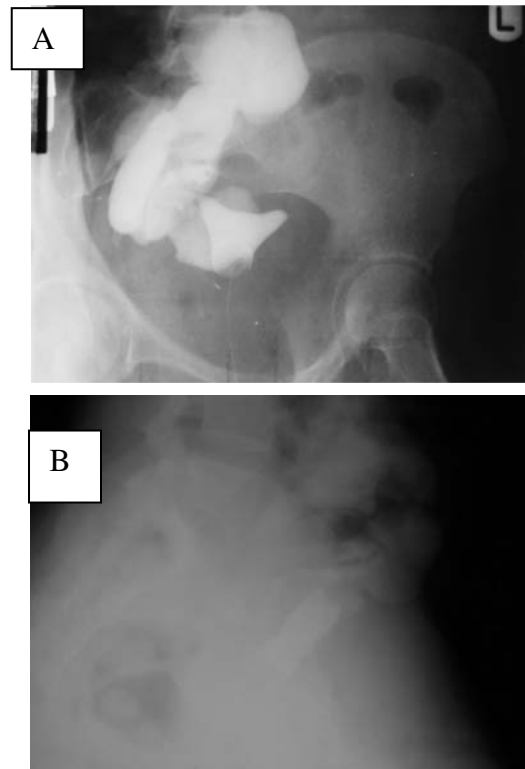


**Figure 2:** Subsequent HSG film showing contrast opacification of the colon through the right fallopian tube.

Pelvic ultrasound examination using 3.5MHz probe done for this woman, to search for any tubo-ovarian mass or abscess was unremarkable. Further investigation of this woman using a chest X-ray to rule-out tuberculosis was done and findings were essentially normal. There was also no family history of tuberculosis.

Patient and her husband became very anxious after these investigations and opted for fistula resection which was carried out successfully by combined team of surgeons and obstetricians. This patient did not come back for a repeat HSG after the surgery. She is presently visiting the IVF-unit in this hospital for possible assisted conception.

The husband was also investigated for male factors of infertility and semen analysis as well as other investigations was normal.



**Figure 3:** Oblique and lateral HSG film further showing the contrast in the large bowel due to fistulous connection between the right fallopian tube and the intestine

## Discussion

Salpingo-enteric or tubo-enteric fistula is a very rare incidental finding. Fistulas have been described between the fallopian tube and rectum, sigmoid, appendix, caecum and ileus.<sup>1-5</sup> Patient with salpingo-enteric fistula may be asymptomatic.<sup>1,21</sup> When symptoms are present they are usually related to the underlying disorder, such as pelvic inflammatory disease, appendicitis, endometriosis, tuberculosis.<sup>15</sup> This patient had features of pelvic inflammatory disease when she presented for this HSG, though the pelvic ultrasound done did not reveal any tubo-ovarian mass or abscess. It is important to emphasize that this patient had a history of termination of pregnancy which may also have contributed to chronic pelvic inflammatory disease. Peter et al<sup>2</sup> described tubo-ovarian

## *Acquired Salpingo-Enteric Fistula*

sigmoid fistula as a rare complication of pelvic inflammatory disease resulting from a severe post cesarean-section infection that formed a tubo-ovarian abscess and ruptured into the sigmoid colon.

Appendicitis has been implicated in the pathogenesis of salpingo-enteric fistula. Madson et al<sup>22</sup> described a case of fistula between the right fallopian tube and appendix, most probably caused by untreated appendicitis in a patient being investigated for infertility. The patient presented in this case report had appendectomy about 14 months prior to this HSG and also had myomectomy about 3 years ago. History of pelvic or obstetric surgery is associated factors in development of pelvic fistulas.<sup>10-12</sup> Other possible causes of this rare type of fistula include Crohn's disease and diverticular disease.<sup>3-5</sup>

While the rectum and bladder are some of the more common sites of fistula formation in Crohn's disease, the fallopian tube is extremely rare.<sup>3</sup> Michelassi et al<sup>3</sup> reviewed 18 years of fistulizing Crohn's disease at the university of Chicago and found two cases of entero-salpingeal fistulas out of 290 fistulas. There is no feature of Crohn's disease in this patient presented; however the lifetime risk for developing fistulas for patients with Crohn's disease has been reported to be 20-40%. Complicated Diverticular disease is also a well known cause of inflammatory fistulas, usually from sigmoid colon to bladder or vagina. William's et al<sup>4</sup> reported the first case of colo-salpingeal fistulation in radiological literature, occurring secondary to complicated diverticulitis. There is however no feature of diverticulitis both clinically and radiological in this patient. Also it is important to mention that both Crohn's disease and diverticulitis are commoner in the western countries.

The diagnosis of salpingo-enteric fistula in most cases is usually incidentally during HSG, for whatever reason, commonly infertility. This was the finding in the case presented. Occasionally salpingo-enteric fistulas may be diagnosed intra-operatively, especially those resulting from Crohn's disease and complicated diverticulosis.<sup>3-4,23</sup> It is important to note that the contribution of the salpingo-enteric fistula to the infertility in this patient cannot be defined. It may be stated that it

was an associated factor having contributed to the pelvic inflammatory disease seen in the patient.

Fistulas to the fallopian tubes are rare and their management is not very well described. Most studies advocate fistula resection and salpingectomy as the only feasible method of treating this rare disease to prevent the occurrence of ectopic pregnancy subsequently.<sup>24-27</sup> Those resulting from Crohn's disease and complicated diverticulitis, en-bloc fistula resection and salpingectomy are also recommended.<sup>3-5</sup> However the type of resection will be tailored to the peculiarity of the patient. The patient presented already had left tubal block as such opted for only fistula resection, sparing the tube. The probability of having an ectopic pregnancy is very high and patient was well advised to come for early pregnancy scan if pregnant.

Some authors have claimed that ultrasonography is a valuable non-invasive alternative study for diagnosis of pelvic fistula. The report stated that the modality is able to visualize vesico-uterine fistula, permitting correct diagnosis and obviating the need for further invasive procedure.<sup>28-29</sup> Computed axial tomography has proved superior in detecting a fistulous tract, also providing additional information regarding the etiology of the fistula and extent of extra-luminal disease. Such information is useful for patient management and planning for surgical repair. Magnetic resonance imaging may also be useful, but the limitations are those of cost, artifacts secondary to physiological motion which commonly lead to image degradation. It has been reported that rapid heavily T2-weighted images are utilized in the diagnosis of occult vesico-uterine fistula.<sup>15-18</sup>

## **Conclusion**

Salpingo-enteric fistulas from any cause are rare and may be a silent disease that can cause infertility or an associated factor. The presentation of classical features of pelvic inflammatory disease may mask other more sinister associations or risk factors of infertility as seen in this case report. The use of hysterosalpingography as complimentary

modality for investigation is once again strengthened.

## References

- Sanjeeb K.S, Murari L.A, Ashok B. The silent disease "Tubo-intestinal fistula". *European Journal of Radiology Extra* 67 (2008) e115-16.
- Peters WA. Tubo-ovarian sigmoid fistula after cesarean section: J Reprod Med. 1987 Dec; 32 (12) :937-8.
- Michelassi F, Stella M, Balestracci T. Incidence, diagnosis, and treatment of enteric and colo-rectal fistulae in patients with Crohn's disease. *Ann Surg* 1993; 218(5):660-6.
- Williams SM, Nolan DJ. Colo-salpingeal fistula: a rare complication of colonic diverticular disease. *Eur Radiol*. 1999; 9(7):1432-3.
- Palnaes-Hansen C, Bulow S, Karlsen J. Tubo-cutaneous fistula. *Acta Chir Scand* 1987;153(7-8):465-6.
- Tancer ML. Vesicouterine fistula: a review. *Obstet Gynecol Surv* 1986;41:743-53
- Iloabachie GC, Njoku O. Vesico-uterine fistula. *Br J Urol* 1985;57:438-9
- Alapont Perez FM, Gil Salom M, Esclapez Valero JP. Acquired entero-vesical fistulas. *Arch Esp Urol* 1994;47:973-9
- Bennett JK, Trulock TS, Finnerty DP. Urachal adenocarcinoma presenting as vesicoenteric fistula. *Urology* 1985;25:297-9
- H. E. Fadel. Ileo-uterine fistula as a complication of myomectomy case report. *BJOG* 1977; 84:312 – 3
- Kilinc F, Bagis T, Guvel S, Egilmez T, Ozkardes H. Unusual case of post-cesarean vesico-uterine fistula (Youssef's syndrome). *Int J Urol*. 2003;10:236-8.
- Okafor PI, Orakwe JC, Mbonu OO. Cyclical haematuria sequel to uterine myomectomy: a case report. *West Afr J Med*. 2002;21:341-2
- Catalano D, Conte R. Colo-uterine fistula. Report of a case. *Radiol Med (Torino)*. 1994;87:350-1.
- Mcfarlane MEC, Plummer JM, Remy T, Christie L, Laws D, Richards H, Cherrie T, Edwards R, Coward C. jejuno-uterine fistula- a case report. *Gynecological surgery* 2008; 5; 1613-6
- Sung Gyu Moon,Seung Hyup Kim,Hak Jong Lee,Min Hoan Moon,Jae Sung Myung. Pelvic Fistulas Complicating Pelvic Surgery or Diseases: Spectrum of Imaging Findings. *Korean J Radiol* 2001; 2: 97-104
- Kuhlman JE, Fishman EK. CT evaluation of entero-vaginal and vesico-vaginal fistulas. *J Comput Assist Tomogr* 1990;14:390-4
- Murphy JM, Lee G, Sharma SD, Doble A, Lomas DJ. Vesico-uterine fistula: MRI diagnosis. *Eur Radiol* 1999;9:1876-8
- Hwang JC, Ha HK, Weon YC. CT findings of enteric fistula. *J Korean Radiol Soc* 1997;37:1091-6
- Bello TO. Tubal abnormalities on hysterosalpingography in primary and secondary infertility. *West Afr J Med*. 2006 ;25:130-3
- Hunt RB, Siegler AM. Hysterosalpingography: techniques and interpretation, 2008.
- Petignat P, Billieux MH, Bianchi Demicheli F, Pelte MF. Silent colo-uterine fistula in an elderly woman. *J Am Geriatr Soc*. 2004;52:1965-6
- Madsen KM, Rasmussen LD. Salpingo-enteric fistula demonstrated by hysterosalpingography: Ugestr Laeger. 1989 Aug 28; 151(35) : 2210-1.
- Rozin S. The diagnosis of tubo-intestinal and tubovesical fistulas by hysterosalpingography. *Am J Obstet Gynecol* 1954;68:1525-30.
- Emmert C, Kohler U. Management of genital fistula in patients with cervical cancer. *Arch Gynecol Obstet* 1996;259:19-24
- Selzman AA, Patrick Spirnak J, Kursh ED. The changing management of uretero-vaginal fistulas. *J Urol* 1995;153:626-8
- Lee BH, Choe DH, Lee JH, et al. Device for occlusion of recto-vaginal fistula: clinical trials. *Radiology* 1997;203:65-9
- Nagy V, Valansky L, Milichovsky I. Urologic complications of gynecologic surgery and their treatment in our clinical data. *Ceska Gynekol* 1998;63:192-5
- Park BK, Kim SH, Cho JY, Sim JS, Seong CK. Vesico-uterine fistula after cesarean section: ultrasonographic findings in two cases. *J Ultrasound Med* 1999;18:441-3
- Adetiloye VA. Obstetric Fistula: evaluation with ultrasonography. *J Ultrasound Med* 2000;19:243-9

