

## CASE REPORT

# Spontaneous second trimester rupture of a previous caesarean section scar: A case report

DOI: 10.29063/ajrh2024/v28i2.12

Maradona E. Isikhuemen<sup>1</sup>, Celestine A. Imarengiaye<sup>2</sup>, Temitope A. Oyelade<sup>3</sup>, Friday E. Okonofua<sup>1</sup>

Department of Obstetrics and Gynaecology, University of Benin Teaching Hospital, Edo State, Nigeria<sup>1</sup>; Department of Anaesthesiology, University of Benin, Edo State, Nigeria<sup>2</sup>; God's Victory Hospital, Benin City, Edo State, Nigeria<sup>3</sup>

\*For Correspondence: Email: [maradona4real2002@yahoo.com](mailto:maradona4real2002@yahoo.com); Phone: +2348050638600

## Abstract

Spontaneous uterine rupture before the onset of labour is rare in pregnancy especially before the third trimester. It is life threatening with devastating consequences to the mother and fetus. We report a case of spontaneous second trimester uterine rupture in a multipara with a previous uterine scar with the aim of creating awareness and sharing the challenges in diagnosis and management of this unusual complication of pregnancy. A 34-year-old woman with two previous deliveries presented at 16 weeks gestation with abdominal pain and vaginal bleeding of one day duration. At presentation, she was pale and in shock. There was generalized abdominal tenderness with guarding and rebound tenderness. At laparotomy, there was uterine rupture involving the lower segment with right lateral upward extension which was repaired. She remained stable at the follow up visit. In conclusion, Spontaneous uterine rupture of a previous caesarean section scar in the second trimester is rare. The diagnosis should be considered in a woman with previous caesarean section who experience an acute abdomen in the second trimester of pregnancy. (*Afr J Reprod Health* 2024; 28 [2]: 125-128).

---

**Keywords:** Uterine rupture, second trimester, laparotomy

---

## Résumé

La rupture utérine spontanée avant le début du travail est rare pendant la grossesse, surtout avant le troisième trimestre. Elle met la vie en danger et entraîne des conséquences dévastatrices pour la mère et le fœtus. Nous rapportons un cas de rupture utérine spontanée au deuxième trimestre chez une multipare présentant une cicatrice utérine antérieure dans le but de sensibiliser et de partager les défis du diagnostic et de la prise en charge de cette complication inhabituelle de la grossesse. Une femme de 34 ans ayant déjà accouché deux fois s'est présentée à 16 semaines de gestation avec des douleurs abdominales et des saignements vaginaux d'une durée d'un jour. Lors de la présentation, elle était pâle et sous le choc. Il y avait une sensibilité abdominale généralisée avec une sensibilité de garde et de rebond. Lors de la laparotomie, il y a eu une rupture utérine impliquant le segment inférieur avec extension latérale droite vers le haut qui a été réparée. Elle est restée stable lors de la visite de suivi. En conclusion, la rupture utérine spontanée d'une cicatrice de césarienne antérieure au deuxième trimestre est rare. Le diagnostic doit être envisagé chez une femme ayant déjà subi une césarienne et présentant un abdomen aigu au cours du deuxième trimestre de la grossesse. (*Afr J Reprod Health* 2024; 28 [2]: 125-128).

---

**Mots-clés:** Rupture utérine, deuxième trimestre, laparotomie

---

## Introduction

Uterine rupture is the disruption of the whole uterine muscle and visceral peritoneum<sup>1</sup>. Spontaneous uterine rupture before the third trimester is rare. It is life threatening with devastating consequences to the mother and fetus. Few cases of second trimester uterine rupture have been reported in the literature<sup>1-3</sup>. The main risk factor for uterine rupture is previous uterine surgery while others include high parity, placental

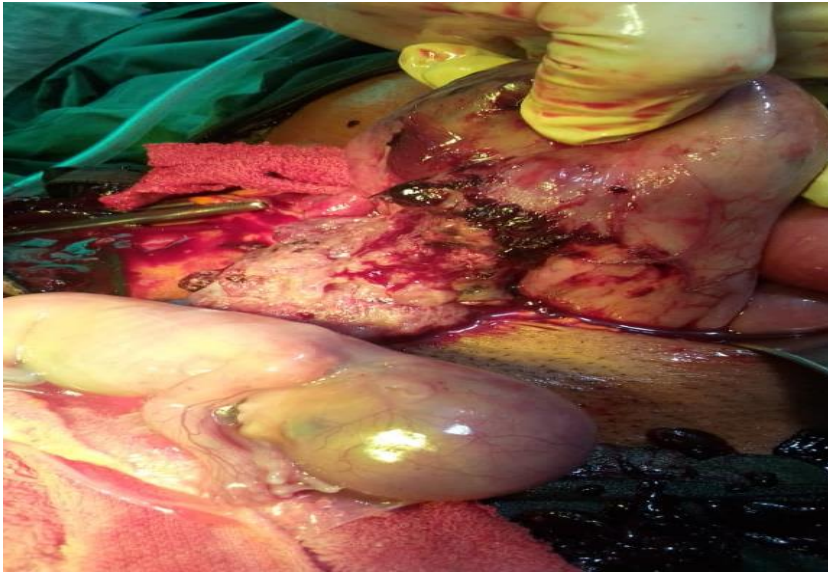
abnormalities, macrosomia, shoulder dystocia, medical termination of pregnancy and uterine anomaly<sup>1-3</sup>. In some cases, there may be no identifiable risk factor for uterine rupture<sup>1</sup>. There may be delay in the diagnosis due to its rare nature<sup>3,4</sup>. We report a case of spontaneous second trimester uterine rupture in a multipara with a previous uterine scar with the aim of creating awareness and sharing the challenges in the diagnosis of this unusual complication of early pregnancy.

## Case presentation

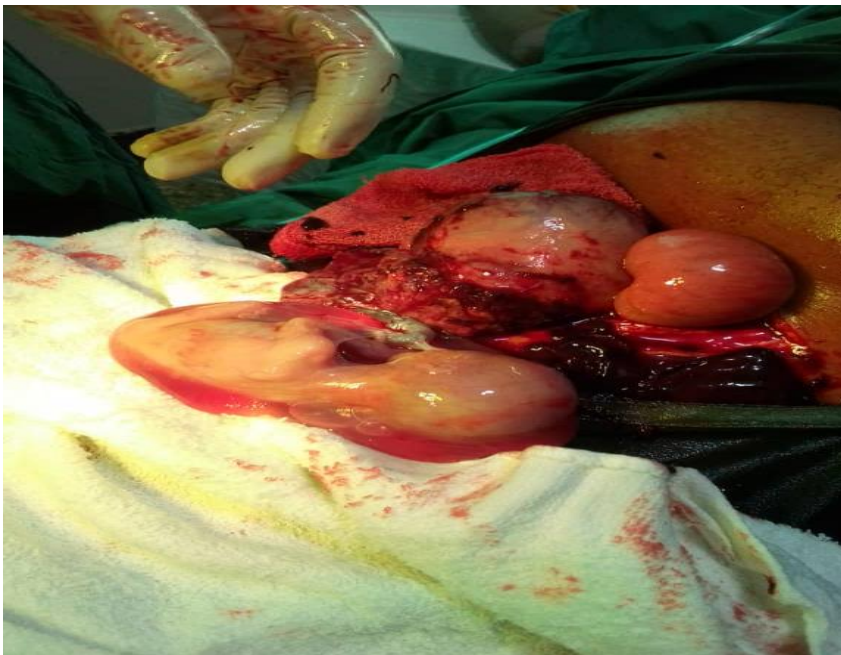A 34-year-old in her third pregnancy with no living child with two previous deliveries presented at 16 weeks gestation with complaint of abdominal pain and vaginal bleeding of one day duration. She noticed generalized body weakness a few hours before presentation in hospital. Her first pregnancy resulted in vaginal delivery at term following prolonged labour. The baby suffered an early

neonatal death from suspected severe birth asphyxia and hypoxic ischaemic encephalopathy. Her second pregnancy 2 years later ended up in an emergency caesarean section for obstructed labour. She had a stillbirth.

In her third pregnancy, she booked for antenatal care at 14 weeks. An abdominal scan carried out a week prior to presentation showed a viable intrauterine pregnancy at 15 weeks. She had no other known comorbid medical conditions.



**Figure 1:** Rupture involving the lower segment of the uterus with minimal upward right lateral extension (both fallopian tubes were healthy looking)



**Figure 2:** Extraction of the baby and removal of the placenta

At presentation, she was pale and in shock. Her pulse rate was 136 beats per minutes and her blood pressure was 119/72 mmHg. Her packed cell volume was 19%. There was generalized abdominal tenderness with guarding and rebound tenderness. Based on these findings, a possible diagnosis of ruptured ectopic pregnancy was made, although this was considered unusual for her gestational age. She was resuscitated with 0.9% saline. Following counseling, she gave consent for emergency laparotomy.

On arrival at the theatre, her heart rate was 124bpm and her SpO<sub>2</sub> was 97%. Preoxygenation was carried out for 3 minutes with 100% oxygen by face mask. Midazolam was given prior to induction and anaesthesia was achieved with ketamine. At surgery, there was hemoperitoneum of 2.5L and a linear rupture involving the lower segment of the uterus with extension to the right upper uterine wall (Figure 1). The baby and placenta were extracted (Figure 2). The uterus was repaired in 2 layers using size 2 Polyglactin 910 sutures and the anterior abdominal wall was repaired in layers. She was transfused with five units of whole blood. Her postoperative period was unremarkable and she was then counseled on the nature of the complication and care for subsequent pregnancies. Following recovery, she was discharged on the sixth postoperative day. She has remained stable at the follow up visit.

## Discussion

Spontaneous uterine rupture in the second trimester of pregnancy is rare. Only a few cases have been reported in the literature. Clinical diagnosis is difficult due to non-specific features. It is usually diagnosed intra-operatively. This case highlights a rare case of second trimester uterine rupture in a woman with a previous caesarean section.

Previous uterine surgery is a major risk factor for early pregnancy uterine rupture. The previous caesarean section in her second confinement was probably the risk factor for uterine rupture. The integrity of the previous repair may have a role to play in subsequent uterine rupture. The evidence of a lateral extension of the uterine rupture in this case suggests the possibility of this occurring in her first caesarean section. Failure to adequately repair this extended or incomplete rupture at that time may have provided a point of

weakness in the uterus that led to the spontaneous rupture that occurred in this pregnancy. Furthermore, obstructed labour in her previous deliveries may have led to endometritis which may have weakened the uterine scar. Despite the previously identified risk factors for early pregnancy uterine rupture, the cause of this rupture may yet be uncertain as second trimester uterine rupture have been known to occur in an unscarred uterus<sup>5</sup>. Previous uterine curettage and abnormal placentation may also predispose to uterine rupture<sup>4</sup>. Other authors have also noted uterine anomaly as a risk factor for this pregnancy complication<sup>6</sup>.

The diagnosis of second trimester uterine rupture is challenging. Ruptured ectopic pregnancy is a close differential diagnosis with similar presentation in early pregnancy. The signs and symptoms of uterine rupture in early pregnancy are not specific<sup>7</sup>. The finding of an intrauterine pregnancy on ultrasound scan may be misleading. A high index of suspicion is required for diagnosis of spontaneous uterine rupture in early pregnancy.<sup>6</sup> Diagnosis may even be more difficult in cases without clinical signs of haemoperitoneum. The most common reported site for uterine rupture in early pregnancy is in the fundus<sup>8,9</sup>. Previous history of uterine instrumentation during evacuation of retained products of conception may be a major risk factor for this. Other authors have also reported rupture at the site of previous caesarean section as seen in the index case.

The treatment of uterine rupture in the second trimester depends on the site of rupture, extent of rupture, parity and age of patient, expertise of the surgeon and condition of the patient<sup>2,10-13</sup>. Options of treatment are total hysterectomy, subtotal hysterectomy, uterine repair alone and uterine repair with bilateral tubal ligation. However, this case was peculiar as a preoperative diagnosis of uterine rupture was not made hence, consent for hysterectomy or permanent sterilization was not taken and she had no living child. Post-operative counseling is therefore important so that the woman fully understands the possibility of another uterine rupture with its devastating consequences. In cases where permanent sterilization was not done, counseling on other methods of assisted reproduction such as surrogacy or child adoption remains a valid option. Other complications may occur following uterine rupture.

The massive blood transfusion was a risk factor for coagulopathy and electrolyte imbalance hence, measures were taken to avoid these including the use of calcium gluconate<sup>14,15</sup>.

## Conclusion

Spontaneous uterine rupture in the second trimester is a rare outcome of pregnancy. Previous uterine incision is a major risk factor for uterine rupture in early pregnancy. In women with previous ultrasound scan finding of intrauterine pregnancy, uterine rupture should be suspected when they present with acute abdomen. Early diagnosis and management are key to preventing morbidity and mortality associated with uterine rupture.

## References

- Cecchini F, Tassi A, Londero AP, Baccharini G, Driul L and Xodo S. First trimester uterine rupture: a case report and literature review. *Int J Environ Res Public Health*, 2020; 17 (8): 2976
- Tola EN. First trimester spontaneous uterine rupture in a young woman with uterine anomaly. *Case Reports in Obstetrics and Gynecology*, 2014; article ID: 967386
- Abdulwahab D, Ismail H and Nusee Z. Second-trimester uterine rupture: lessons learnt. *Malays J Med Sci*, 2014; 21(4): 61 – 65
- Ibrahim S, Drymiotou S, Hegab K, Sideris M, Okba M. Second trimester ruptured uterus, unusual presentation. *Annals of Medicine and Surgery*, 2021; 61: 145 – 147
- Kashyap P, Prasad S and Singh B. A rare case of second trimester uterine rupture in unscarred uterus. *Int J Med Res Health Sci*, 2017; 6(11): 105 – 107
- Indriati FM, Riskianto CR and Kurniawati EM. A rare case of spontaneous uterine rupture in second trimester pregnancy with bicornuate uterus: a case report. *Journal of Health Science*, 2022; 15(1): 32 – 38
- Ho WY, Wang C, Hong SC and Han HC. Spontaneous uterine rupture in the second trimester: a case report. *Obstet Gynecol Int J*, 2017; 6(4): 00211
- Fahrni A, Salomon D, Zitiello A, Faki A and Ali NB. Recurrence of second-trimester uterine rupture in the fundus distant from old scars: a case report and review of the literature. *Case Reports in Women's Health*, 2020; 28: e00249
- Saghafi N, Maleki A, Ayati S and Shirinzadeh L. *Iran J Med Sci*, 2019; 44(5): 422 – 426
- Hawkins L, Robertson D, Frecker H, Berger H and Satkunaratnam A. spontaneous uterine rupture and surgical repair at 21 weeks gestation with progression to live birth: a case report. *BMC Pregnancy and Childbirth*, 2018; 18: 132
- MahaJan N, Moretti ML and Lakhi NA. Spontaneous early first and second trimester uterine rupture following robotic-assisted myomectomy. *Journal of Obstetrics and Gynaecology*, 2019; 39(2): 278 – 280
- Al-Obaidi AD, Hashim AS, Salih S and Hashim HT. Spontaneous mid-trimester uterine rupture associated with fetal death in a young patient during COVID – 19 pandemic: a case report. *Clinical Case reports*, 2022; 10(12): e6802
- Avidime AR and Haruna I. Spontaneous uterine rupture at twenty weeks of pregnancy. *Tropical journal of Obstetrics and Gynaecology*, 2014; 31: 1
- Maxwell MJ, Wilson MJA. Continuing Education in Anaesthesia. *Critical Care*, 2006; 6: 225 – 229
- Donaldson MJA, Seaman MJ and Park R. massive blood transfusion. *BJA*, 1992; 69: 621 – 630.