

## CASE REPORT

# Clinical Investigations and Management of Refractive Changes in Pregnancy: A Case Report

Bernadine N. Ekpenyong<sup>1,4\*</sup>, Nwakuso A. Aruotu<sup>2</sup>, Ebele B. Uzodike<sup>3</sup> and Chimela G. Njoku<sup>4</sup>

Department of Public Health, University of Calabar, Calabar Nigeria<sup>1</sup>; Department of ophthalmology, University of Port Harcourt, River State<sup>2</sup>; Department of Optometry, Abia State University, Uturu, Abia State Nigeria<sup>3</sup>; Benita eye Clinic, Calabar, Cross River State, Nigeria<sup>4</sup>;

\*For Correspondence: E-mail: benyita2001@yahoo.com; Phone: +2348033475138.

## Abstract

Pregnancy also presents with ocular changes, just as it affects other non - reproductive systems of the female. It has been reported to be associated with development of new health conditions or can exacerbate pre- existing health conditions. This paper reviews the management of Mrs AA, a 41 year old pregnant woman (primigravida) with refractive changes from myopia in the first trimester, to hyperopia in the second and third trimesters of her pregnancy. A comprehensive ocular examination was performed including fundus photograph and Optical Coherent Tomography. The results revealed signs of Central Serous Chorioretinopathy in both eyes which may have been due to various hormonal changes in pregnancy with resultant changes in refractive error. These ocular changes associated with pregnancy are, most often transient in nature, though occasionally permanent. This condition therefore requires clinical observation and monitoring until the resolution of the serous detachment is complete, and vision returned back to normal. Other ocular changes that are pregnancy related were reviewed. (*Afr J Reprod Health 2015; 19[4]: 107-117*).

---

**Keywords:** Primigravida, central serous chorioretinopathy, ocular changes, transient, optical coherent tomography.

---

## Résumé

La grossesse présente également avec des changements oculaires, tout comme elle affecte les autres systèmes qui n'ont rien à voir avec la reproduction chez la femme. Il a été signalé qu'elle est liée au développement de nouvelles conditions de santé ou peut exacerber les conditions préalables de santé existantes. Ce document passe en revue la gestion de Mme AA, une femme âgée de 41 ans, enceinte (primipare) qui souffre de modifications de la réfraction de la myopie dans le premier trimestre, à l'hypermétropie dans les deuxième et troisième trimestres de la grossesse. Un examen ophtalmologique complet a été effectué, y compris la photographie du fond d'œil et la tomographie optique cohérente. Les résultats ont révélé des signes de séreuse centrale Chorioretinopathie dans les deux yeux qui peuvent avoir été en raison de divers changements hormonaux pendant la grossesse avec les changements qui en résultent dans l'erreur de réfraction. Ces changements oculaires liés à la grossesse sont, le plus souvent de nature transitoire, bien que parfois permanente. Cette condition nécessite donc l'observation et la surveillance clinique jusqu'à la fin de la résolution du décollement séreux, et au retour de la vision normale. Nous avons examiné les autres modifications oculaires qui sont liées à la grossesse (*Afr J Reprod Health 2015; 19[4]: 107-117*).

---

**Mots-clés:** primigravide, chorioretinopathie séreuse centrale, changements oculaires, transitoires, tomographie optique cohérente

---

## Introduction

During pregnancy, various physiological and non-physiological changes can take place in most body organs including the eye<sup>1</sup>. The ocular changes associated with pregnancy may persist for a few weeks post-partum and during lactation<sup>2,3</sup>. The ocular effects of pregnancy can be divided into physiologic changes, pathologic conditions or modification of pre-existing conditions<sup>1,2,3</sup>. The effect of pregnancy on the eye fall into three categories, non-pathological changes in pressures,

corneal sensitivity and thickness, hypertensive and vascular disorders and uveal melanoma<sup>4</sup>.

Pregnancy is known to be responsible for refractive changes as a result of various hormonal disorders occurring during pregnancy<sup>1</sup>. The changes in refraction during pregnancy may result from changes in the anterior segment, posterior segment and or systemic disorders. Pizzarello<sup>5</sup> observed that all women who complained of visual changes were found to have experienced a myopic shift from pre-pregnancy levels and that by post-partum all subjects returned to near pre-pregnancy

levels of myopia. Pregnancy is a risk factor for central serous chorioretinopathy (CSCR), which usually causes a hyperopic shift.

Central serous chorioretinopathy (CSCR) is a relatively common retinal disease characterized by the accumulation of subretinal fluid at the posterior pole of the fundus, creating a circumscribed area of serous retinal detachment<sup>6</sup>. People between the ages of 20 and 50 years typically are affected and the literature consistently reports a higher prevalence in men than in women in clinic-based patient population, men accounting for 88%<sup>7</sup> of study population and 79%<sup>8</sup> of study population respectively in two different studies. A recent retrospective case – control study involving 624 patients (312 cases and 312 controls) showed that systemic steroid use and pregnancy are the most important risk factors for CSCR<sup>9</sup>. Although typically CSCR is a disease occurring in otherwise healthy young or middle – aged men, it has also been reported in pregnant women<sup>10,11</sup>. CSCR generally is unilateral, but most chronic cases are bilateral, Gackle et al.<sup>12</sup> reported bilateral involvement in 40% cases of CSCR. The prognosis of CSCR is generally excellent. Over 90% of patients regain 20/30 vision or better within 6 months<sup>13</sup>.

Pregnancy associated CSCR may recur in the context or outside of subsequent pregnancy<sup>14</sup>. CSCR reoccurred in two women, always in the same eye, in subsequent pregnancies. One patient had four successive pregnancies with CSCR<sup>15</sup> and one had two successive pregnancies complicated by CSCR<sup>16</sup>. However, Sunness et al.<sup>17</sup>, reported a case of a woman with CSCR in her third pregnancy, who did not experience a recurrence during a subsequent pregnancy. Therefore, due to the differences observed, it appears that the occurrence of CSCR during one pregnancy does not necessarily mean that it will recur in future pregnancies.

Central Serous Chorioretinopathy associated with pregnancy usually spontaneously resolves with minimal consequences without intervention after delivery of the baby<sup>18</sup>. Having knowledge of the ocular changes in pregnant women will help to differentiate the physiological changes from ocular manifestations of systemic diseases and diseases pertaining to the eye in a pregnant woman.

### Case report

Mrs. A.A, a 41 year old woman presented to our eye clinic on the 3<sup>rd</sup> of August 2010, complaining of blurred vision at distance. The patient had never worn glasses before, but there was a positive family history of refractive error. Her mother wears glasses for reading and there was no family history of blindness. The patient is a nurse by profession and was in the first trimester of her first pregnancy, there was no history of hypertension and diabetes before pregnancy. However, her blood pressure measured 160/90mmHg. She said that she did not smoke nor take alcohol. Patient denied episodes of swollen legs.

Her unaided visual acuity (VA) was 20/125 at distance and 20/32 at near both eyes (OU). Pinhole acuity at distance was 20/32 both eyes. Color vision test done with Ishihara test chart was normal.

Her objective refraction was

Right Eye (RE) – 1.00 – 0.25 X 180  
20/32

Left Eye (LE) – 1.00 – 0.25 X 165  
20/32

Subjective refraction

Right Eye (RE) – 1.00Ds  
20/32

Left Eye (LE) – 1.00Ds  
20/32 and 20/20 at near OU

Intraocular pressure was 9mmHg RE and 15mmHg LE by 4pm with non-contact air puff tonometry.

External eye examination revealed healthy eye lids, conjunctiva and cornea. Anterior segment evaluation by slit-lamp biomicroscopy revealed healthy lids, clear lashes and a quiet bulbar and palpebral conjunctiva, a clear intact cornea OU. Irises were brown and anterior chamber was deep. Funduscopy showed a dull macula area with poor fovea reflex. The cup-to-disk ratio of the RE was 0.5, while the LE was 0.6. A spectacle prescription of the above findings was given to the patient.

### Follow-up 1

Patient returned about 6 weeks after on 13<sup>th</sup> of September 2010 complaining of difficulty to see very well with present glasses. Her visual acuity at

distance was 20/125 and 20/40 at near both eyes. Visual acuity became worse with - 1.00Ds 20/160.

Blood pressure was 159/90mmHg.

Objective refraction changed from myopia to Hyperopia.

Objective refraction

RE + 1.50 20/32

LE + 1.50 20/32

Subjective refraction

RE +1.50 20/32

Add

1.50 20/20

LE +1.50 20/32

The patient was asked to do a fasting blood sugar test, see her physician and come back with result next visit. Patient was also counselled that these changes can occur with pregnancy and should comply with follow up appointment. Her spectacle prescription was changed to the new findings.

### Follow-up 2

The patient returned a week after on the 20<sup>th</sup> of September 2010. She presented her fasting blood sugar report which was normal 4.7mmol/L, (reference range 4.2mmol/L – 6.4mmol/L), blood pressure was 156/90mmHg, intraocular pressure was 9mmHg OD and 12mmHg but however reported blurred near vision with present glasses. Fundus findings remained the same. Unaided VA remained the same 20/125 both eyes. VA with present glasses of +1.50Ds Add 1.50Ds was now 20/50 at distance and 20/40 at near both eyes.

On refraction, the hyperopic correction increased from + 1.50Ds to + 3.00Ds 20/30 with an Add of still +1.50Ds 20/20 both eyes. Patient at this point was advised not to change her spectacle prescription till next visit so that we can monitor the progression.

But patient is undergoing an academic programme and needs to read. Prescription was changed to +3.00Ds for sight and +4.50Ds for near. Two separate glasses were prescribed. Patient was given a two week appointment.

### Follow-up 3

The patient missed her follow-up date and returned on the 28<sup>th</sup> of October 2010. Patient

reported that she can now read better with the glasses for sight +3.00 Ds, while she is now unable to read with the near prescription of +4.50Ds. Her vision improved remarkably on assessment. Unaided visual acuity at distance and at near was now 20/40 both eyes.

Refraction was done, visual acuity improved to 20/20 at distance and near with + 1.00 Ds Add 1.50 both eyes.

Intraocular pressure was 8mmHg OD and 14mmHg OS, by 4pm while her blood pressure was 150/90mmHg by 4.30pm. Funduscopy showed a binocularly dull macula area with poor fovea reflex. The cup-to-disk ratio of the RE was still 0.5, while that of the LE remained as 0.6. The prescription was dispensed. Patient was given another appointment to come to teaching Hospital to see an ophthalmologist and for further investigation.

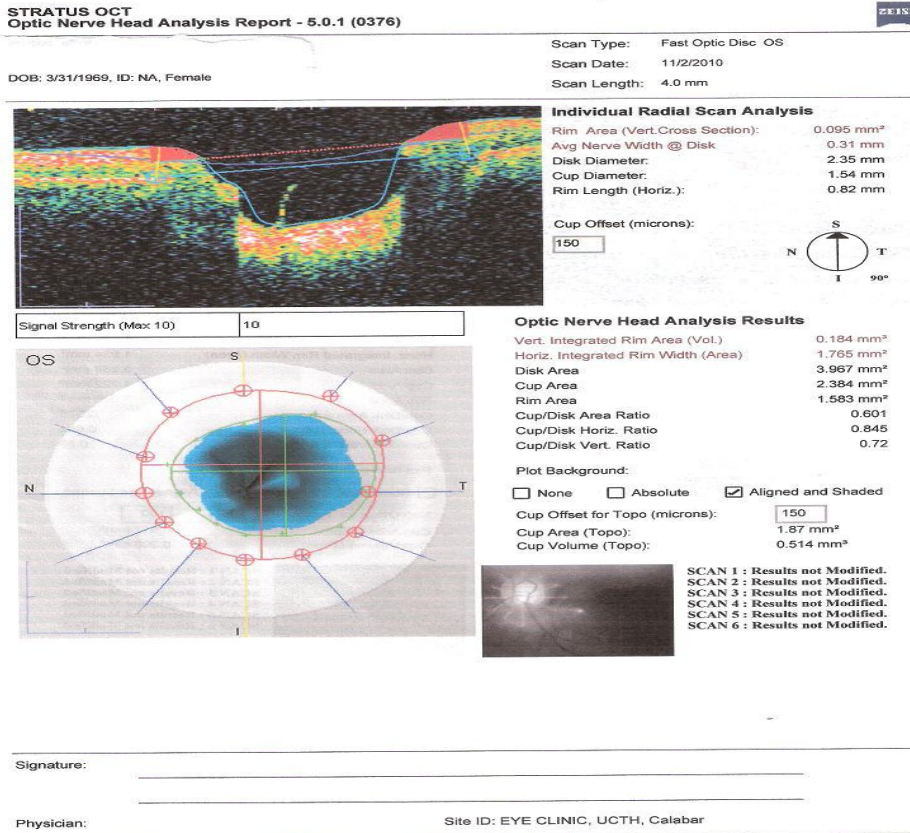
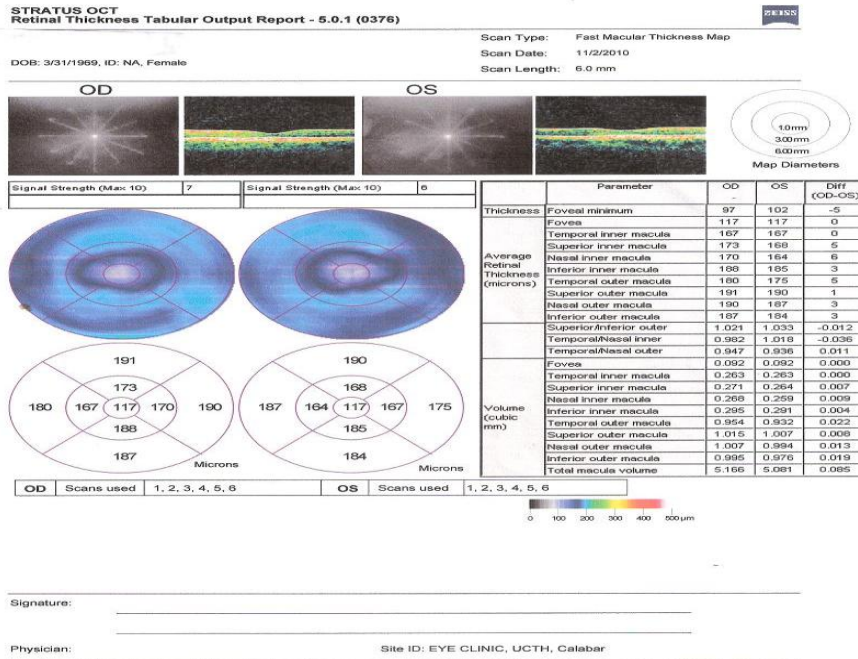
### Follow-up 4

Mrs. A.A reported to UCTH on 3<sup>rd</sup> November 2010. A more comprehensive examination was done. Her unaided visual acuity was now 20/40 at distance and 20/30 at near both eyes, her corrected visual acuity with her present spectacles +1.00 Add 1.50 was 20/20 at distance and near both eyes. On refraction, there was no change in refraction and she was comfortable with her spectacle prescription.

Ophthalmic diagnosis using OCT was done and the Retinal Thickness Tabular Outcome Report revealed a slightly raised area of the retina, and the retina thickness was a little up suggesting fluid accumulation that has probably resolved to a low level. The Optic Nerve Head Analysis Report showed cup/ disk area ratio of 0.3, a horizontal and vertical cup/ disk ratio of 0.6 and 0.5 respectively, for the right eye and cup/ disk area ratio of 0.6, a horizontal and vertical cup to disc ratio of 0.8 and 0.7 respectively for the left eye (Figure 1).

Visual field was done with Humphrey Matrix with Welch Allyn Frequency Doubling Technology. The fields of both eyes showed evidence of a scotoma which were not typical of glaucomatous cupping because it was done using normal threshold (Figure 2). A specific visual field

Figure 1: OCT Results of both Eyes



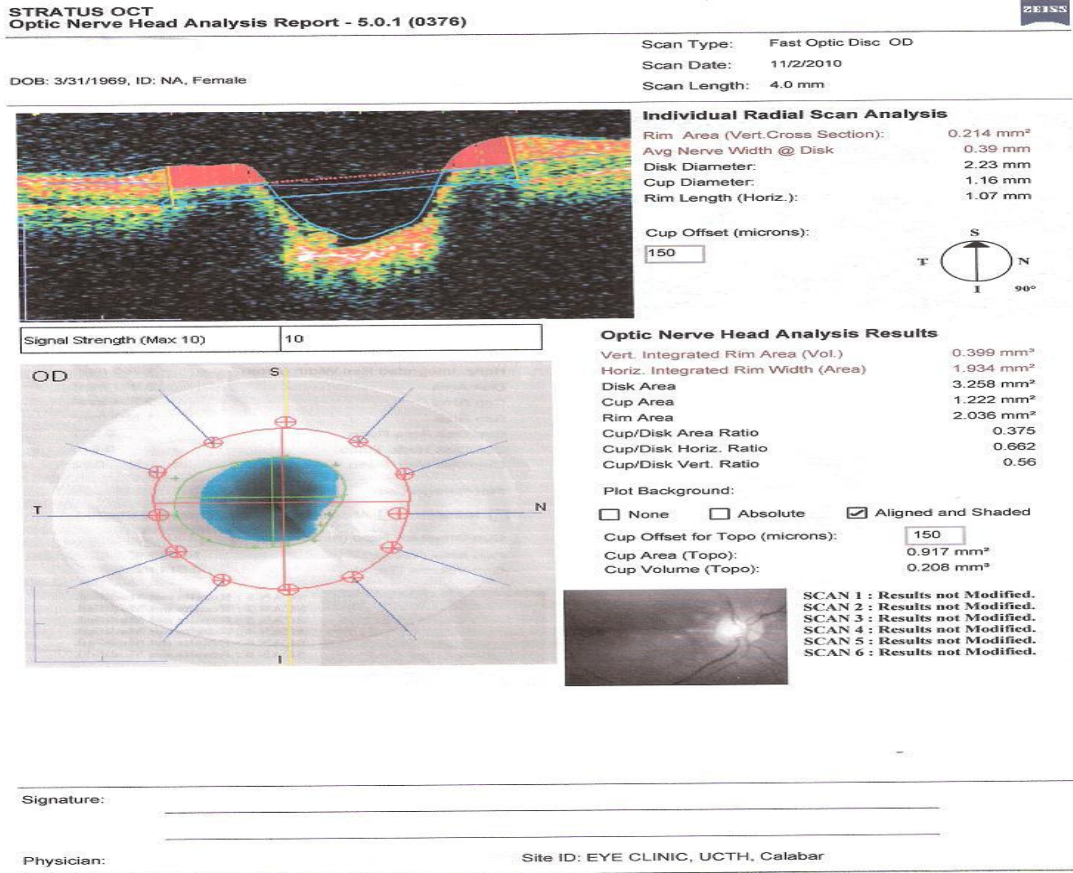
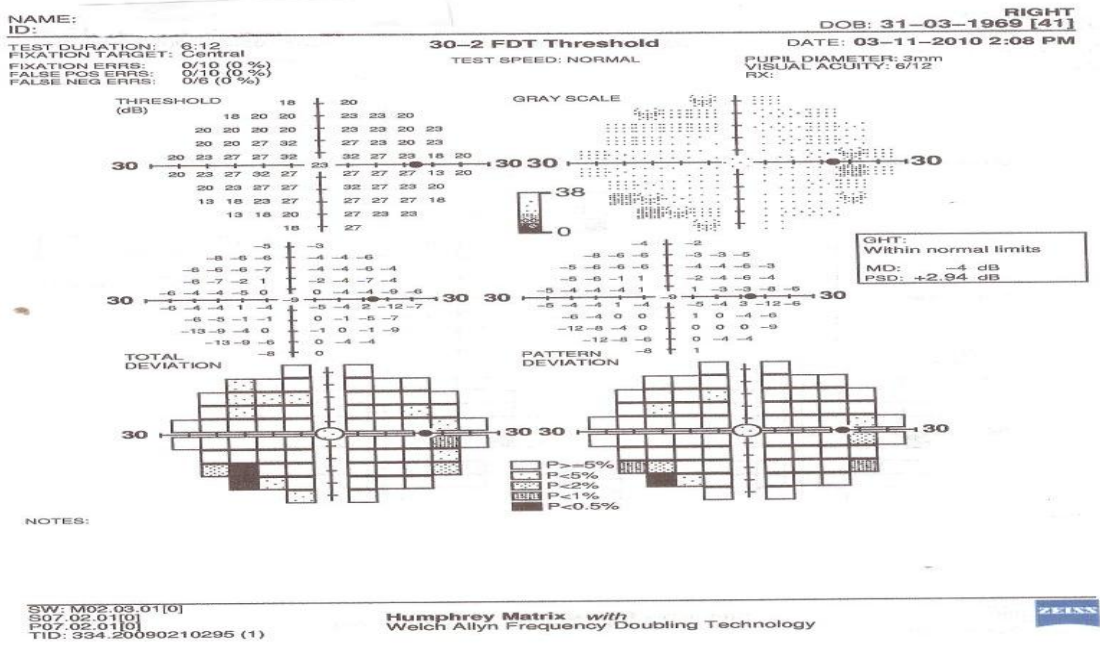
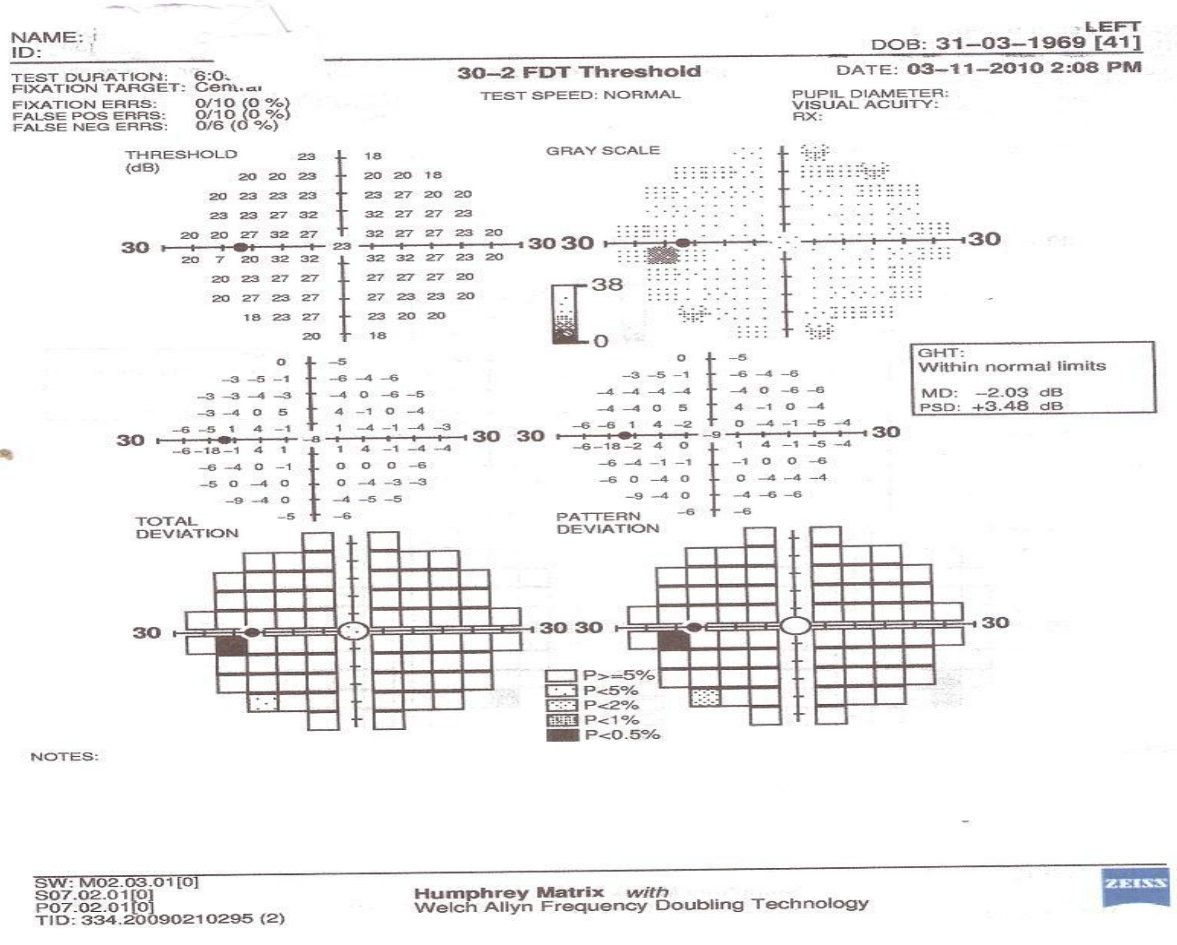


Figure 2: Visual field report





test for glaucoma investigation (central 10 degrees) may be necessary in future. The intraocular pressure was 8mmHg RE and 12mmHg LE by 11.00 am. These IOP results may also have been affected by the pregnancy. Blood pressure remained at 150/90mmhg, patient was advised to see her gynecologist for further investigation and management of her blood pressure.

Both eyes were dilated using one drop of 2.5% Mydrin (Phenylephrine Hydrochloride) and one drop of 1% Mydracyl (Tropicamide) ophthalmic solutions. Posterior segment evaluation with ophthalmoscope and slit lamp biomicroscope revealed that the media of both eyes appeared optically clear. Funduscopy revealed a clear disk with an estimated cup-to-disk ratio of about 0.5, arterial-venous ratio of 2:3, and

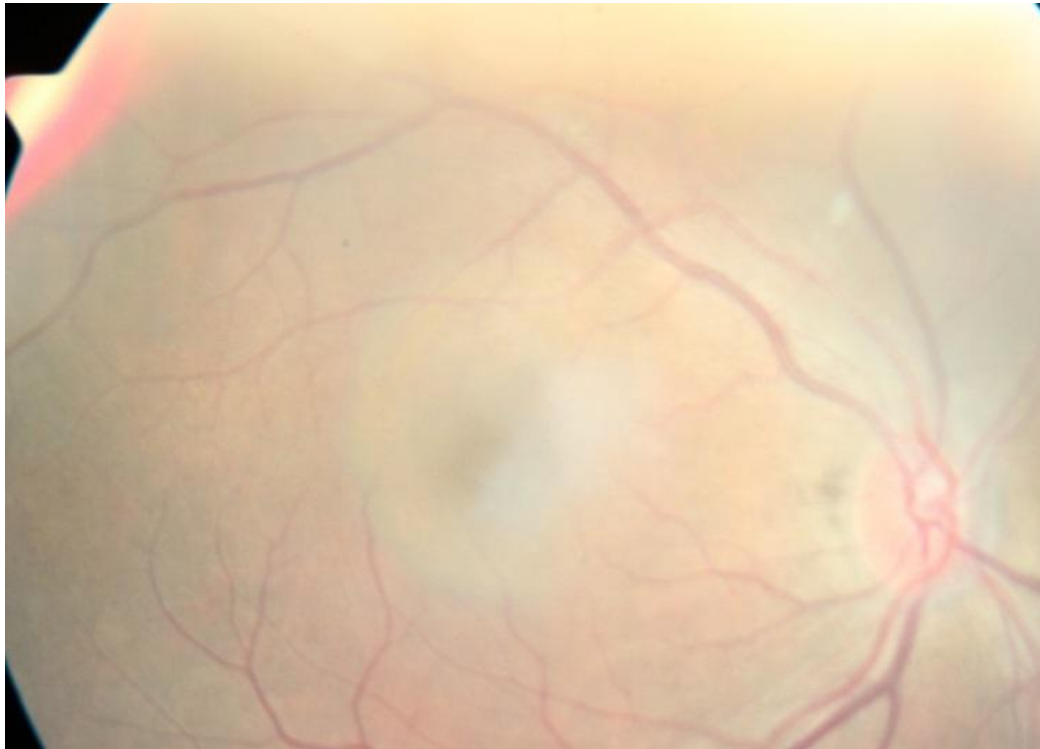
a focal area of retinal pigmented epithelium (RPE) mottling around the macula of both eyes. The fundus photograph revealed patches of yellow colouration around the macular area, more in LE than RE, with mottling of the macular area (Figure 3). Anterior segment evaluation by slit-lamp biomicroscopy revealed healthy lids, clear lashes and a quiet bulbar and palpebral conjunctiva OU, cornea was clear and intact OU. Irises were brown and anterior chamber was deep.

Patient was advised to continue with her spectacle prescription and to be reviewed post – partum in the absence of any further change in vision before delivery.

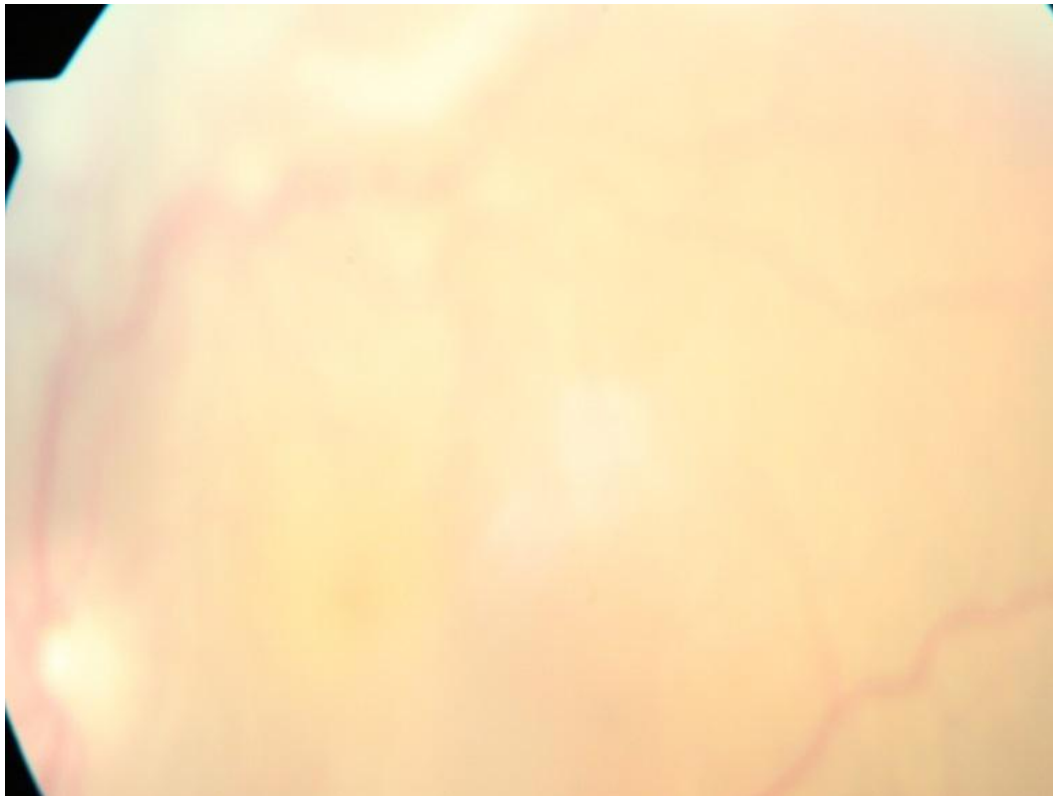**Differential Diagnosis/ Diagnosis**

The differential diagnosis includes, pregnancy-

**Figure 3.** Fundus image LE



RE



**Table 1:** Summary of Refractive Error Changes, IOP and Blood Pressure of the 41 Year Old Pregnant Woman

Variables		First Visit	Follow up 1	Follow up 2	Follow up 3	Follow up 4
Unaided VA Distance	RE	20/125	20/125	20/125	20/40	20/40
	LE	20/125	20/125	20/125	20/40	20/40
Unaided VA Near	OU	20/32	20/40	20/125	20/40	20/30

Habitual VA Distance	RE	Nil	20/160	20/50	20/125	20/20
	LE		20/160	20/50	20/125	20/20
Habitual VA Near Refraction	OU	Nil	20/40	20/40	20/125	20/20
	RE	- 1.00Ds	+1.50Ds	+3.00Ds	+ 1.00Ds	+ 1.00Ds
	LE	- 1.00 Ds	+1.50 Ds	+3.00Ds	+ 1.00 Ds	+ 1.00 Ds
			Add 1.50	Add1.50	Add 1.50	Add 1.50
Optimal VA Distance	RE	20/32	20/32	20/30	20/20	20/20
	LE	20/32	20/32	20/30	20/20	20/20
Optimal VA Near	OU	20/20	20/20	20/20	20/20	20/20
Blood Pressure		160/90mmHg	159/90mmHg	156/90mmHg	150/90mmHg	150/90mmHg
IOP	RE	9mmHg	8mmHg	9mmHg	8mmHg	8mmHg
	LE	15mmHg	13mmHg	12mmHg	14mmHg	12mmHg

induced hypertension or pre-eclampsia, gestational diabetes mellitus, pregnancy-induced corneal thickness and Central Serous Chorioretinopathy

**Pregnancy-induced hypertension or pre-eclampsia**

Pregnancy-induced hypertension or pre-eclampsia presents with pathological changes in the retina, blurred vision, retinal detachment, and patient complain of central scotoma, diplopia and photopsia on the affected eye<sup>19-20</sup>. The severity of the retinal changes depends on the degree of hypertenson<sup>20</sup>. Ophthalmoscopy may show macula edema, acute hypertensive retinopathy, retinal artery and venous occlusion, haemorrhages, optic neuritis and atrophy<sup>21-23</sup>. The majority of patients have complete resolution of vision with clinical management.

**Gestational diabetes mellitus (GDM)**

Gestational diabetes mellitus is a type of diabetes that arises during pregnancy. Rachel<sup>24</sup> reported a hyperopic shift associated with hyperglycemia. It present with abnormal fasting blood sugar level and blurred vision. In this case her fasting blood sugar was normal

**Pregnancy induced corneal thickness**

Corneal thickness has been reported to increase during pregnancy due to fluid retention that is often associated with pregnancy, with resolution a short time after delivery<sup>25-26</sup>. According to Omoti et al.<sup>27</sup>, due to variations in thickness, the refractive index of the cornea may be altered causing myopic shift.

**Central Serous Chorioretinopathy**

Central Serous Retinopathy (CSR) is a macular disorder characterized by a serous Retinal Pigment Epithelium (RPE). It most commonly affects young middle-aged adults from 20 to 45 years of age, and affects men 6 to 10 times more often than women<sup>11</sup>. The condition resolves spontaneously at the end of pregnancy or after delivery<sup>9,14,18</sup>. Typically visual acuity is reduced and may be correctable to 20/20 with a hyperopic shift in a patient’s prior habitual spectacle correction.

**Diagnosis**

Central serous chorioretinopathy in pregnancy due to various hormonal changes, which resulted in blurred vision and a hyperopic shift. The CSCR spontaneously resolved by second and third trimester with a remarkable improvement in vision.

**Discussion**

Women undergo a tremendous number of changes both systemic and ocular throughout pregnancy. The patient under review presented with normal eyelids no blotchy brown discoloration, edema or ptosis. Chloasma and spider angiomas are common during pregnancy and can occur on the eyelids perhaps related to high estrogen levels and increased fluid retention<sup>28,29</sup>. Studies have described changes in conjunctival blood vessels toward the end of normal pregnancies and they include granularity of the conjunctival vessels, mild spasm of conjunctival arterioles decreased visualization of conjunctival capillaries and increased vessel diameter<sup>30,31</sup>. The conjunctiva of



the patient under study appeared normal no spasm of conjunctival arterioles and hemorrhages.

Weinreb et al.<sup>25</sup> reported increase corneal thickness due to fluid retention during pregnancy with resolution a short time after delivery. The study found variations from 1 micron to 16 microns which appeared to be present throughout pregnancy. Due to resource restrictions, the corneal thickness could not be assessed, however no striae or folds in descemet's membrane were observed to indicate corneal edema.

This case study found slight and insignificant changes in IOP of the patient at the first and second trimesters. The curvature of the crystalline lens has been reported to be increased during pregnancy, resulting in a myopic shift in refraction<sup>27</sup>. In this case, there was a hyperopic shift from first trimester, which started resolving from second trimester and will likely continue till post-partum, in line with most studies<sup>10,32</sup>. This was accompanied with a dramatic improvement in visual acuity from 20/120 to 20/40 in both eyes.

The reason for this change can be best viewed using the OCT. Optical coherence tomography is one of the most exciting developments in ophthalmic imaging in recent years for retinal investigations. The OCT of the Retinal Thickness Tabular Output Report of both eyes appears as an elevation of the full thickness neurosensory retinal layer from the highly retinal pigmented epithelium layer (Figure 1). The image was typical of a resolved central serous chorioretinopathy; (CSCR) the height of the serous detachment appeared reduced due to resolved CSCR. The assumption therefore is that the retinal edema would have been very obvious if the OCT was done at the first visit when the visual acuity at distance was poor 20/125. By the second trimester, the fluid accumulation is expected to have resolved to a good extent, resulting in an improved visual acuity at distance 20/40 and a change in refraction.

People who need glasses may assume that the blurriness caused by CSCR is simply a change in their prescription. In most cases such condition, should be assessed by a retinal specialist otherwise a thorough assessment of the retina should be done with OCT or Angiographic imaging (fluorescein angiography).

Central serous chorioretinopathy is a complication that can occur in an otherwise normal pregnancy. CSCR in pregnancy is often associated with sub-retinal exudation which is possibly fibrinous in nature, caused by hemodynamic, biological and psychological alterations in pregnancy. The alteration resolves spontaneously towards the end of pregnancy or after delivery<sup>9,14,18</sup>. This explains the reason for improvement in visual acuity in this case from 20/125 to 20/40 without any treatment.

Typically in CSCR, Visual acuity is moderately reduced in the affected eye and may be correctable to 20/20 with a hyperopic shift in a patient's prior habitual spectacle correction. She had a refractive error of -1.00 at first visit during her first trimester, about one week later there was a hyperopic shift, and the refractive error changed to +1.50Ds OU, then to +3.00Ds five weeks after. Then by the second trimester about six weeks later the affection resolved, unaided visual acuity improved from 20/125 to 20/40 both eyes. The refractive error also changed to +1.00Ds Add 150, with VA of 20/20 at distance and near both eyes.

The change in refraction could not have been due to pregnancy-induced corneal thickness because corneal thickness which occurs in pregnancy due to fluid retention causes a myopic shift<sup>27</sup>. Gestation diabetes mellitus is a pregnancy induced diabetes mellitus which can cause a hyperopic shift in refraction. In this case the patient's blood sugar level was normal, ruling out GDM as a cause of the hyperopic shift. She had an elevated blood pressure, which according to her was normal before pregnancy. Her feet were not swollen, and she had no such episode. Result of investigation did not show macula edema and acute hypertensive retinopathy and as such could not have been a case of pre-eclampsia. The fundus photograph revealed mottling of the macular area and yellow spot on the retina typical of CSCR. The clinical investigations in this case have revealed a typical case of Central Serous Chorioretinopathy in pregnancy, which started resolving in the second and third trimester with a hyperopic shift.

The treatment of CSCR is based largely on uncontrolled observations, life style counseling and discontinuation of steroid medication as the case may be. However if detachment persists for

more than 3 months, photocoagulation or photodynamic therapy should be considered. It is therefore obvious in this case that monitoring of CSCR is the management strategy used. According to reports majority of cases of CSCR left untreated will resolved within few months of initial onset and vision will return to normal functional level in most patients<sup>10,32</sup>. Another interventional option in the management of CSCR is the use of direct laser photocoagulation at the site of RPE leakage. Argon laser photocoagulation hastens resolution of the serous detachment than those simply monitored<sup>33</sup>. Monitoring however remains the best management option in the treatment of CSCR associated with pregnancy because of the side effects of photocoagulation.

The usual advice is to wait at least several weeks post-partum if possible, before obtaining a new spectacle. This did not apply in this case because the change was fast, large and unbearable for the patient. Mrs. A.A was not in town for post-partum review; however a telephone conversation with her during the expected delivery period revealed that she was still comfortable with her glasses although regrettably, she had a stillbirth at the 8 month of the pregnancy.

## Conclusion

Central serous chorioretinopathy occurs most frequently in mid-life and more often in males than in females. Major risk factors are pregnancy and steroid use, while major symptoms are blurring or distortion of visual image and less frequently abnormal color vision and poor contrast. Normal vision often recurs spontaneously within few months. Pregnancy has effect on the normal physiology and pathophysiology of the woman's eye. Although the change in refractive error reversed by second and third trimester, it is expected that by post-partum, the CSCR will be fully resolved and vision will be further improved. This paper therefore emphasizes the need for proper case history, clinical observation and clinical assessment using OCT in the management of eye diseases. It is important for clinicians to have a firm understanding of the various ocular changes associated with pregnancy and the implications they may have for management and to resist the temptation to intervene with

photocoagulation before it is truly indicated. The complaint of blurred vision in a pregnant woman should not be dismissed, rather it should be considered an indication for evaluation for possible disease process, and therefore appropriate diagnostic testing should be performed to rule out other organic causes.

## Contribution of Authors

1. Bernadine N. Ekpenyong conceived and designed the study, evaluated and followed up on the patient, collected and analysed data.
2. Chimela G. Njoku assisted clinically in the evaluation of the patient and data collected.
3. Nwakuso A. Aruotu provided supervision and assisted in data analysis and discussion of results
4. Ebele B. Uzodike also provided supervision and assisted in data analysis and discussion of results.

## References

1. Barbazetto IA and Pizzarello LD. Ocular changes during pregnancy. *Compr ophthalmol update*. 2007; 8 (3): 155 – 67.
2. Sheth BP and Meller WF. Ocular complications of pregnancy. *Curr opin ophthalmol* 2001; 12 (6): 455 – 518.
3. Sharma S, Rekha W, Sharma T and Downey G. Refractive Issues in pregnancy. *The Australian and New Zealand Journal of obstetrics and gynaecology*. 2006; 46 (3): 186-188.
4. Sunness JS. The pregnant woman's eye. *Survey of ophthalmology* 1988; 32 (4): 219-255.
5. Pizzarello CD. Refractive changes in pregnancy. *Graefes archive for clinical and experimental ophthalmology*. 2003; 24 (6): 484-492.
6. Evryidiki AB, Panagiotis K and Constantin JP. Central serous chorioretinopathy and glucocorticoids. *Survey of Ophthalmol* 2002; 47 (5): 431 – 448.
7. Spitznas M and Huke J. Number, shape and topography of leakage points in acute type 1 central serous retinopathy. *Graefes Arch Clin Exp Ophthalmol* 1987; 225: 437 – 440.
8. Wang M, Sander B, LaCour M and Larsen M. Clinical characteristics of subretinal deposits in central serous chorioretinopathy. *Acta Ophthalmol Scand* 2005; 83: 691–696.
9. Haimovici R, Koh S, Gagnon DR. Risk factors for Central Serous Chorioretinopathy, a case control study. *Ophthalmology* 2004; 111: 244.
10. Rezai KA and Elliot D. Optical Coherent Tomography

- findings in pregnancy associated Central Serous Chorioretinopathy. *Graefe's Arch Clin Exp Ophthalmol* 2004; 242 : 1014 – 1016.
11. Chenug A and Scott IU. Ocular changes during pregnancy. *Ophthalmic pearls comprehensive AAO* 2012; 40 – 43.
  12. Gackle HC, Lang GE, Freissler KA and Lang GK. Central serous chorioretinopathy. Clinical, fluorescein angiography and demographic aspects. *Ophthalmologie* 1998; 95: 529–533.
  13. Wang M, Munch K, Hasler PW, Prante C and Larsen M. Central Serous Chorioretinopathy, *Acta Ophthalmol* 2008; 86: 126 – 145.
  14. Khairallah M, Nouria F, Gharsallah R and Chachis N. Central Serous Chorioretinopathy in a pregnant women. *J. Fr. Ophthalmol* 1996; 19:216-221.
  15. Chumbley LC and Frank RN. Central serous retinopathy and pregnancy. *Am J Ophthalmol* 1974; 77 - 158.
  16. Cruysberg JR and Deutman AF. Visual disturbances during pregnancy caused by central serous choroidopathy. *Br J Ophthalmol* 1982; 66 -240.
  17. Sunness, J.S. The pregnant woman's eye. *Survey of ophthalmology* 1988; 32 (4): 219-255.
  18. Kio W. Central serous choroidopathy associated with pregnancy. *J of Ophthalmic Nursing and Technology* 1992; 11(5):203 – 205.
  19. Prado RS, Figueiredo EL and Magalhaes TV. Retinal detachment in preeclampsia *Ara Bras Cardiol* 2002; 79: 183-189.
  20. Garg P and Aggarwal P. Ocular changes in pregnancy. *Nepal J. Ophthalmol* 2012; 4 (7); 150 – 161.
  21. Dinn RB, Harris A and Marcus PS. Ocular changes in pregnancy. *Obstet Gynecol Surv* 2003; 58:137 -144.
  22. Cunningham F G, Fernandez C O and Harnesdez C. Blindness associated with preeclampsia and eclampsia. *Obstet Gynecol* 1995; 172 (4): 1291 – 1298.
  23. Sunness J S, Haller J A and Fine S L. Central serous choroidopathy and pregnancy. *Arch Ophthalmol* 1993; 111 (3): 360 – 364.
  24. Rachel N.N. Early Ocular and Non Ocular indicatives of diabetes mellitus. *Ophthalmic and physiological optics: John Wiloy and Sons*, 1998; 18 (2): 167-173.
  25. Weinreb RN and Lu A, Beeson. Maternal corneal thickness during pregnancy. *American Journal of Ophthalmology*, 1988; 105:258.
  26. Riss B and Riss P. Corneal sensitivity in pregnancy. *Ophthalmologica* 1981; 183: 57.
  27. Omoti A E, Waziri-Erameh J M and Okeigbemen V W. A review of the changes in the ophthalmic and visual system in pregnancy. *African Journal of reproductive health* 2008; 12(3): 185-195.
  28. Sanke RF. Blepharoptosis as a complication of pregnancy. *Annals of Ophthalmology* 1984; 16:720.
  29. Esteve E, Sandeau L, and Pierre F. Physiological cutaneous signs in normal pregnancy: A study of 60 pregnant women. *Ann Dermatol Venerol* 1994; 121- 227.
  30. Gaikin AV. Condition of the microcirculatory bed of the bulbar conjunctiva in physiological and pathological pregnancies. *Arch Anat Gistol Embriol* 1985; 89:36.
  31. Vavilis D, Maloutas S, and Nasioutziki M. Conjunctiva is an estrogen sensitive epithelium. *Acta Obstet Gynecol Scand* 1995; 74:799.
  32. Wang M, Sander B, Lund-Andersen H & Larsen M. Detection of shallow detachments in central serous chorioretinopathy. *Acta Ophthalmol Scand* 1999; 77: 402–405.
  33. Leaver P and Williams S. Argon Laser Photocoagulation in the treatment of central serous chorioretinopathy. *Br J ophthalmol* 1997; 63: 674 – 677.