

CASE REPORT

Sonohysterography: Time to Step up its Use in Gynaecologic Imaging in West Africa

Augustina Badu-Peprah^{*1}, Alexander T. Odoi², Edward T. Dassah², Yaw Amo-Wiafe¹

¹Department of Radiology, Komfo Anokye Teaching Hospital, Kumasi, Ghana; ²Department of Obstetrics and Gynaecology, Komfo Anokye Teaching Hospital, Kumasi, Ghana

*For correspondence: Email: ghdocbp@hotmail.com Tel: +233-20-26300784; fax: +233-322-022308

Abstract

Sonohysterography is a simple, safe and convenient technique that is easily and rapidly performed in the ultrasound room; yet the technique seems to be underutilized in West Africa. We present two cases that were successfully carried out in our centre followed by detailed description, uses and challenges of the technique, with the hope of encouraging clinicians and sonographers in the sub-region to step up its use. Two women were referred for evaluation of their endometrial cavities on account of increasingly heavy menstrual bleeding. Sonohysterography revealed intracavity uterine masses with hyper-echoic focal thickening highly suggestive of endometrial polyps; histology confirmed the diagnosis of endometrial polyps. Sonohysterography is an affordable and feasible diagnostic modality for evaluating the endometrial cavity. Where equipment and skill permit, the technique should be used more often in the West African sub-region. Sonohysterography, Transvaginal sonography, Gynaecologic imaging, West Africa (*Afr J Reprod Health 2011; 15[3]:133-139*).

Résumé

Sonohystérogaphie: Temps d'augmenter son emploi dans la visualisation gynécologique en Afrique de l'Ouest : La sonohystérogaphie est une technique simple, non dangereuse et commode, qui est accomplie dans la salle d'ultrason ; pourtant, il semble que la technique est sous utilisée en Afrique de l'Ouest. Nous présentons deux cas qui ont été accomplis dans notre centre, suivi d'une description détaillée, l'emploi et les défis de la technique, avec l'espoir d'aider des cliniciens et des sonographes de la sous-région à augmenter son emploi. Deux femmes nous ont été envoyées pour l'évaluation de leurs cavités endométriales à cause d'une hémorragie menstruelle excessive. La sonohystérogaphie a révélé des masses utérines d'intra cavité, ayant un épaissement focaux hyper-résonnant qui indique la présence des polypes endométriales; l'histologie a confirmé le diagnostic de polypes endométriales. La sonohystérogaphie est une modalité diagnostique faisable et abordable pour évaluer la cavité endométriale. Là où l'on se dispose des équipements et le savoir-faire, il faut se servir de la technique plus souvent dans la sous-région ouest africaine (*Afr J Reprod Health 2011; 15[3]:133-139*).

Keywords: Family Planning, Unwanted pregnancies, Misuse of drugs, Emergency contraception

Introduction

Sonohysterography (SHG) consists of transvaginal sonography (TVS) with concomitant instillation of sterile anechogenic contrast medium (commonly normal saline) into the uterine cavity by means of a transcervical catheter¹. The saline distends the uterine cavity and also acts as a

contrast agent during TVS, giving exquisite detail of the endometrium and myometrium^{2,3}. The goal of SHG is to visualize the endometrial cavity in more detail than is possible with routine TVS⁴. The technique enhances the diagnostic potential of TVS and improves the detection of endometrial pathology such as polyps, submucous fibroids, hyperplasia, cancer and adhesions. It helps avoid invasive diagnostic procedures and optimizes the

preoperative triage for women requiring therapeutic interventions^{5,6}. SHG has been shown to be more sensitive and specific, with higher positive and negative predictive values than TVS, in diagnosing intrauterine lesions in women with abnormal uterine bleeding (AUB)^{7,8}. The results of SHG compared very well with those of hysteroscopy^{1,6}, which has become the gold standard for evaluating patients with AUB⁷. Unlike hysteroscopy however, SHG is relatively non-invasive, and can identify myometrial and adnexal pathology^{7,9}. Moreover, hysteroscopy is performed by a minority of gynaecologists⁷ and not readily available in most of our centers, while SHG can be made readily available in our setting since ultrasound machines are available in most district hospitals.

SHG is a simple, safe and convenient technique that is easily and rapidly performed at a reasonable cost in the ultrasound room. It is well tolerated by patients and virtually devoid of any complications^{5,9}. Consequently, SHG is performed in many centres as a first-line diagnostic procedure for evaluating AUB and mullerian abnormalities, investigating infertility in clients undergoing in vitro fertilization, and programming endoscopic surgery¹. The technique should be within the expected skill set of virtually any sonographer in a clinical setting¹⁰. Yet, SHG is rarely used in Ghana and seems to be underutilized in West Africa. To the best of our knowledge the procedure has not been reported in Ghana previously and only about one study¹¹ has been reported in the sub-region. We present two cases that were successfully carried out in our centre followed by a detailed description of the technique. An outline of the clinical indications and common imaging features are given as a guide to sonographers who are not yet familiar with the technique. The challenges, particularly in a developing world setting, are also discussed with the hope of encouraging clinicians and sonographers in the sub-region to step up its use.

Cases and Methods

Two clients, 32-year-old para 0+1 (case1) and 28-year-old para 0+0 (case 2) were referred to the Radiology Department for evaluation of their

endometrial cavities on account of AUB (increasingly heavy menstrual bleeding). Their medical histories were not significant. Physical and pelvic examinations were unremarkable apart from each having a slightly bulky uterus. Their laboratory investigations including high vaginal and endocervical swabs were normal.

The procedure of TVS was explained to the patients, and suggestion of performing SHG should the TVS be inconclusive, was made. After discussing the option of SHG, the clients were given an appointment to report to the Radiology Department on the 10th day of their menstrual cycle. The procedural steps of SHG were explained to them including the small risk of increased bleeding and even smaller risk of infection. On the appointment day the counseling was repeated and informed consent was obtained after the clients' questions had been answered.

Sonohysterography procedure

After emptying her bladder, the client was placed in the dorsal position and a TVS evaluation performed with a Siemens Sonoline G50 ultrasound machine (Siemens Medical Solutions, Milan, Italy) using a 7.5 MHz endovaginal probe covered with a condom and sterile gel. For both cases there was a hyper-echoic focal thickening in the endometrium, highly suggestive of endometrial polyp mostly probably resulting from endometrial hyperplasia, since both entities can show hyper-echoic appearance on TVS. The clients were then informed about the need for SHG.

A Cusco's bivalve speculum was inserted into the vagina, to visualize and cleanse the cervix with 10% savlon (chlorhexidine gluconate + cetrimide). A balloon-bearing size 8F Foley's catheter (Well Lead Medical Instruments Co. Ltd, Guangzhou, China) was flushed with sterile saline solution (0.9% NaCl) to minimize air bubbles and inserted into the cervical canal. The balloon was inflated with about 1.5mls of sterile saline solution to retain the catheter at the internal os. The speculum was gently removed to avoid the dislodging the catheter, and the endovaginal probe reinserted anterior to the catheter. Under direct sonographic visualization, the balloon was gently retracted to occlude the internal os. A 20ml syringe filled with normal saline was attached to the catheter and between 15-20 mls of sterile saline

solution was slowly instilled into the uterine cavity under continuous observation with TVS. Complete sonographic evaluation of the endometrial cavity was performed in both the coronal and sagittal planes until the lesion in the uterine cavity was clearly visualized. Inadvertently introduced air bubbles gave bright reflection that dispersed into tiny bubbles during saline introduction. Blood clots were found to be echogenic, mobile and became displaced with further saline introduction. The balloon was deflated just before the end of the procedure and additional saline instilled while the catheter was slowly withdrawn to enable a full evaluation of the lower uterine segment and endocervical canal.

Findings

Case 1

In case 1, a well defined smooth-margined homogenous hyper-echoic intracavity mass (3.2x2.4x2.5 cm) arising from the posterior wall of the uterus was clearly visualized (Figures 1a & b). Colour Doppler demonstrated flow within the stalk (Figure 1b), strengthening the diagnosis of endometrial polyp.

Case 2

In case 2, two well defined bilobulated homogeneous intracavity masses (Mass1=1.8 x 1.1cm; Mass 2=1.8x0.6cm) arising from the anterior wall of the uterus and highly suggestive of endometrial polyps were clearly visualized (Figure 2).

The procedure lasted about 20 minutes in each case. No antibiotics were administered to either client. The procedure was well tolerated, causing minimal pain in both clients that did not require any analgesics.

Subsequent gynaecological management

Following SHG, the clients were counseled on the diagnosis and the available management options discussed. Polypectomy was advised in each case and both clients consented to laparotomy, since hysteroscopy was not available in our centre. Laparotomy revealed endometrial polyps

consistent with the SHG findings in either case. Polypectomy was done in both cases and their post-operative recoveries were uneventful. Histological evaluation confirmed the polyps as simple hyperplasia of the endometrium in each case. Subsequently, the heavy menstrual bleeding resolved in both cases.

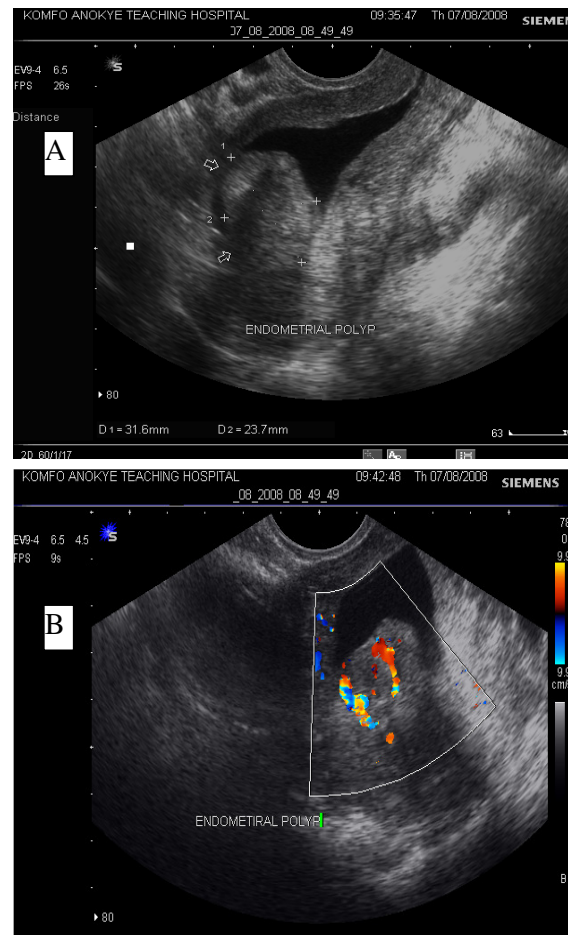


Figure 1: Sagittal view of intracavity mass showing dimensions (A) and coronal views of intracavity mass demonstrating intralesional feeding vessel under colour Doppler (B).

Discussion

Timing of SHG and client preparation

The optimal timing for SHG depends on the clinical presentation of the client. In a woman

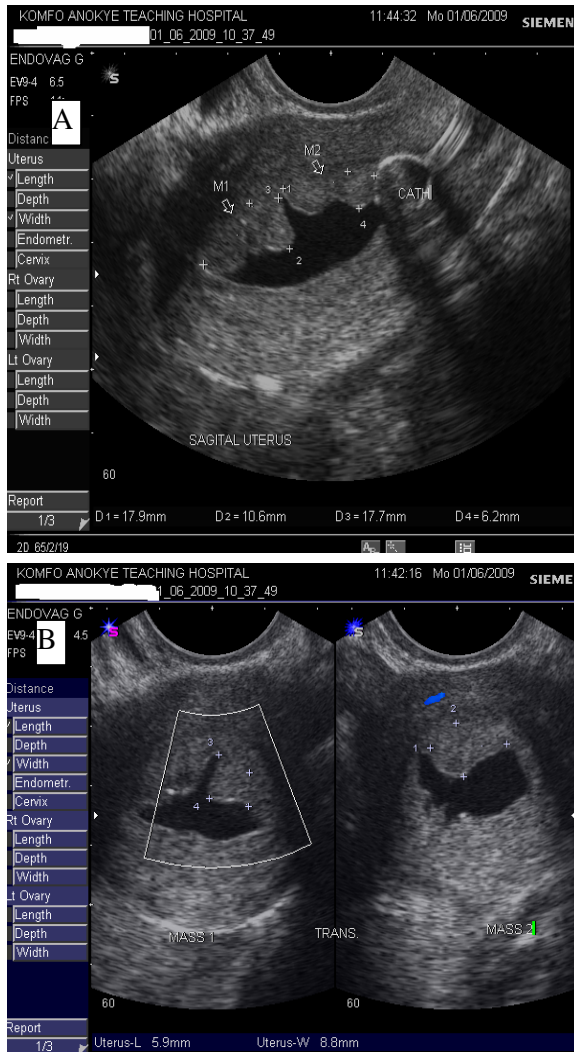


Figure 2: Sagittal view showing dimensions of the bilobulated masses (M1 & M2). CATH- Balloon of Foley's catheter (A) and coronal views of the bilobulated masses (Mass 1 and Mass2), under Doppler (B)

with regular menstrual cycles, SHG is typically scheduled early in the follicular phase of the cycle, after cessation of menstrual flow, but not later than day 10, as the endometrium is thin during this time of the cycle. This timing also minimizes the risk of interfering with an unsuspected early pregnancy^{2, 4, 5, 12, 13}. Focal lesions such as polyps are best seen when they are surrounded by a thin postmenstrual endometrium².

¹³. Generally, the secretory phase is avoided because folds and wrinkles in the endometrial lining can mimic small fibroids or polyps, or focal areas of endometrial hyperplasia, giving false positive results^{2, 5, 12-14}. In a woman with irregular bleeding, SHG should be performed soon after the bleeding has ceased¹³. In postmenopausal women with AUB, SHG can be performed at anytime. Where the woman is on hormone replacement therapy, the examination should be coordinated with withdrawal bleeding or the progesterone phase of the therapy². Active vaginal bleeding is not an absolute contraindication to SHG. However, the presence of blood clots within the uterine cavity may make the interpretation technically challenging^{2, 4}. Our clients were scheduled for the procedure in the follicular phases of their cycles.

Prophylactic antibiotics are not routinely given, but should be considered in clients with increased risk factors for infection such as chronic pelvic inflammatory disease or a cardiac condition^{2, 4, 12}. The procedure is often painless and well tolerated by the majority of clients, who require no analgesia or anaesthesia. However, administration of nonsteroidal anti-inflammatory drugs such as ibuprofen (400-600mg) 30-90 minutes before the procedure has been found to be useful in the minority of clients who remain fearful or experience some cramping during the examination^{5, 9, 13}. Ketorolac can be prescribed for clients who are allergic to ibuprofen⁵. In our cases, antibiotics were not required since they were medically fit and had no pelvic infections. Though analgesics were not used, both clients tolerated pain very well.

Indications

The commonest indication for SHG is as an adjunct to TVS in evaluating AUB in both premenopausal and postmenopausal women⁴. Other indications include; infertility and habitual abortion, congenital abnormalities of the uterine cavity, suspected submucous uterine fibroids, polyps, cysts and synechiae, further evaluation of the endometrial abnormalities detected on TVS and suboptimal imaging of the endometrium by TVS^{4, 5}. The indication for SHG in our clients was

AUB and endometrial polyps were diagnosed in both cases. For clients undergoing in vitro fertilization, SHG yields similar results as hysteroscopy but is less invasive, better tolerated, less expensive, and can evaluate the adnexa^{2, 7}. Moreover, SHG can be performed by any sonographer who is experienced in using the transvaginal probe and can readily be made available in a developing world setting.

The main contraindications to SHG are; pregnancy, pelvic infection or unexplained pelvic tenderness and excessive vaginal bleeding^{4, 5}. In the case of active pelvic infection, the examination should be deferred until after the client has been treated with the appropriate course of antibiotics⁴. Pelvic infection was excluded in our clients by physical examination and laboratory investigations.

Sonohysterographic features

It must be emphasized that the main purpose of SHG is to assist the attending physician plan further work-up. Where the endometrium appears “normal”, further interventions may become unnecessary. If any abnormality is found then SHG may help direct any further interventions that will be required.

Endometrial polyps are localized outgrowths of endometrial glands and stroma that project beyond the surface of the endometrium. They may have a broad base (sessile) or slender pedicle (pediculated). Polyps are a common cause of AUB in both premenopausal and postmenopausal women and are usually removed to exclude malignancy and for symptomatic relief of bleeding^{2, 10, 13}. During SHG, polyps typically appear as well defined, homogenous, rounded lesions isoechoic to the endometrium with preservation of the interface between the endometrium and myometrium⁵ (fig. 1b). Atypical features include; cystic components, multiple polyps, broad base, and hypoechogenicity or heterogenicity⁵. Though colour flow or power Doppler commonly identifies a central feeding vessel within the stalk (fig 1a), this is not specific to polyps and may be seen in atypical fibroids or endometrial carcinoma⁵.

Uterine fibroids are benign tumours of the uterine smooth muscle and are a common cause of AUB in our setting. Submucosal fibroids appear as well defined, broad based, hypoechoic and solid masses which distort the myometrial-endometrial interface, with an overlying echogenic endometrium and refractory shadowing arising from within the mass^{2, 5, 13, 14}. In addition, SHG clearly demonstrates the location, size and the degree of intramural or intracavity extension^{2, 3, 5, 13, 14}. Atypical features of fibroids seen on SHG include pedunculation, multilobulation and prolapse into the endocervical canal which usually precludes SHG⁵. Both uterine fibroids and polyps can coexist in the same client.

Endometrial hyperplasia results from unopposed oestrogen stimulation of the endometrium². Risk factors for developing endometrial hyperplasia are similar to those of carcinoma². Endometrial hyperplasia is usually visualized as diffuse irregular echogenic endometrial thickening without focal abnormality. Though endometrial carcinoma usually appears as a diffuse heterogenous lesion, a more focal form can be seen⁵. However, since these Sonohysterographic features are not pathognomonic, any focal endometrial abnormality seen on SHG must be biopsied to establish the diagnosis^{5, 13}.

Intrauterine adhesions usually result from traumatic injury to the endometrium. During SHG, they appear as mobile, thin, echogenic bridging bands across the endometrial cavity. Though they are not commonly encountered, thick, broad-based bridging bands usually impede distension of the endometrial cavity^{5, 13}.

Adenomyosis commonly present with AUB and dysmenorrhoea. Though not well diagnosed sonographically, diagnostic features during SHG include; small cystic areas in the subendometrial region of the myometrium and elongated tracks of fluid extending from the endometrial cavity into the myometrium^{5, 6}.

Challenges

Procedure-related challenges and complications are mild and rare. Most of these challenges can be overcome by using appropriate techniques⁹. The

failure rate of SHG varies from 2.8% to 7%^{8, 9}. Common causes of incomplete procedures are the presence of a stenotic cervix or severe cervical angulation preventing insertion of the transcervical catheter, cervical incompetence or a very patulous cervix causing backflow of the saline solution into the vagina, large intrauterine fibroids and adhesions impeding distension of the uterine cavity, pelvic pain and vagal symptoms^{9, 13, 15}. In the case of previous cervical surgery, a uterine sound may be used while for cervical stenosis, passage of Hegar dilators or a suitable catheter such as the Goldstein catheter will usually resolve the difficulty. Paracervical blockade is rarely required for dilatation^{9, 15}. In severe cervical angulation, angling the speculum appropriately and exerting traction on the cervix by the use of a tenaculum should reduce the angulation and allow introduction of the catheter. For cervical incompetence, the use of a balloon bearing catheter such as the Foley catheter will provide a good seal at the internal os^{8, 9, 15}. Other adverse effects of SHG include nausea (1%), vomiting (0.5%) and post procedure fever (0.8%)⁹. For clients who are allergic to latex condoms, we propose the use of non-latex condoms.

Various catheters have been proposed for use during SHG. In a prospective study to evaluate six of these catheters, their differences, in terms of how practically and easily the clinician could use them, were not statistically significant. The Foley's catheter was the cheapest and as a balloon bearing catheter, it can also prevent backflow of contrast medium into the vagina¹. The Foley's catheter is readily available in our setting. However inflation of the balloon stimulates the nerve fibres of the cervix, increasing client discomfort and the likelihood of vasovagal reactions^{1, 15}. In our opinion, since most clients can tolerate the Foley's catheter without analgesia and vasovagal reactions are very rare^{9, 11, 15}, it should be used as the first choice in this setting.

Conclusion

Sonohysterography is a simple, safe, relatively non-invasive and well tolerated technique for evaluating the endometrial cavity. It is an affordable and feasible option that should be used

more often in our setting. As we battle with AUB, side effects of tamoxifen therapy and infertility in the sub-region, it is about time to step up the use of SHG as the diagnostic modality of choice for evaluating the endometrial cavity, where facility and skill allow. Admittedly, adequately powered studies are needed to find out and address some of the challenges stated above in our setting.

Acknowledgements

We are grateful to our clients for giving consent for their case records to be published and to our colleagues who helped in the management of the cases.

References

1. Dessole S, Farina M, Capobianco G, Nardelli GB, Ambrosini G, Meloni GB. Determining the best catheter for sonohysterography. *Fertil Steril*. 2001 Sep;76(3):605-9.
2. Berridge DL, Winter TC. Saline infusion sonohysterography: technique, indications, and imaging findings. *J Ultrasound Med*. 2004 Jan;23(1):97-112; quiz 4-5.
3. Nanda S, Chadha N, Sen J, Sangwan K. Transvaginal sonography and saline infusion sonohysterography in the evaluation of abnormal uterine bleeding. *Aust N Z J Obstet Gynaecol*. 2002 Nov;42(5):530-4.
4. American College of Obstetricians and Gynecologists. ACOG Technology Assessment in Obstetrics and Gynecology No. 5: Sonohysterography. *Obstet Gynecol*. 2008 Dec;112(6):1467-9.
5. Elsayes KM, Pandya A, Platt JF, Bude RO. Technique and diagnostic utility of saline infusion sonohysterography. *Int J Gynaecol Obstet*. 2009 Apr;105(1):5-9.
6. Verma SK, Lev-Toaff AS, Baltarowich OH, Bergin D, Verma M, Mitchell DG. Adenomyosis: sonohysterography with MRI correlation. *AJR Am J Roentgenol*. 2009 Apr;192(4):1112-6.
7. Alborzi S, Parsanezhad ME, Mahmoodian N, Alborzi M. Sonohysterography versus transvaginal sonography for screening of patients with abnormal uterine bleeding. *Int J Gynaecol Obstet*. 2007 Jan;96(1):20-3.
8. Botsis D, Papagianni V, Makrakis E, Aravantinos L, Creatas G. Sonohysterography is superior to transvaginal sonography for the diagnostic approach of irregular uterine bleeding in women of reproductive age. *J Clin Ultrasound*. 2006 Nov-Dec;34(9):434-9.
9. Dessole S, Farina M, Rubattu G, Cosmi E, Ambrosini G, Battista Nardelli G. Side effects and complications

- of sonohysterosalpingography. *Fertil Steril*. 2003 Sep;80(3):620-4.
10. Goldstein SR, Monteagudo A, Popiolek D, Mayberry P, Timor-Tritsch I. Evaluation of endometrial polyps. *Am J Obstet Gynecol*. 2002 Apr;186(4):669-74.
 11. Aremu AA, Adetiloye VA, Famurewa OC, Ibitoye BO, Ayoola OO, Alao OB. Saline contrast sonohysterography findings in Nigerian patients with infertility. *Research Journal of Medical Sciences*. 2008;2(3):133-6.
 12. Lane BF, Wong-You-Cheong JJ. Imaging of endometrial pathology. *Clin Obstet Gynecol*. 2009 Mar;52(1):57-72.
 13. Sohaey R, Woodward P. Sonohysterography: technique, endometrial findings, and clinical applications. *Semin Ultrasound CT MR*. 1999 Aug;20(4):250-8.
 14. Nass Duce M, Oz U, Ozer C, Yildiz A, Apaydin FD, Cil F. Diagnostic value of sonohysterography in the evaluation of submucosal fibroids and endometrial polyps. *Aust N Z J Obstet Gynaecol*. 2003 Dec;43(6):448-52.
 15. de Crespigny L, Kuhn R, McGinnes D. Saline infusion sonohysterosalpingography, an underutilized technique. *Aust N Z J Obstet Gynaecol*. 1997 May;37(2):206-9.