

# Lilliputian hallucinations in Schizophrenia: a case report

Lilliputian hallucinations are a rare type of visual hallucination where imaginary objects, persons or animals of diminutive size are perceived. These small images are usually described as brightly coloured mobile creatures. The earliest description was given by Macarius in 400 AD who described these as 'little strangers'<sup>1</sup>, but the term 'Lilliputian' was first used by Leroy.<sup>2</sup> Lilliputian hallucinations have been described in a variety of clinical conditions such as delirium, dementia, alcohol withdrawal states, following intake of dihydrocodein phosphate and dl-methylephedrine hydrochloride (a cough syrup), and medical conditions like toxoplasmosis, basilar migraine, mesencephalic lesions, cerebral tumors, epilepsy, Charles Bonnet Syndrome, and trichloroethylene poisoning.<sup>1,3-7</sup> Lilliputian hallucinations were first described in schizophrenia by Lewis<sup>8</sup>, but have been reported as a rare phenomenon.

In this report we describe a patient with schizophrenia who presented predominantly with Lilliputian hallucinations and review the literature with respect to Lilliputian hallucinations in schizophrenia. Informed consent was obtained from the patient and her spouse to publish the case material, on the basis that it would be anonymous.

A 45 year old housewife, pre-morbidly well adjusted with no past or family history of mental illness, presented with a psychotic episode of acute onset three years prior. Her illness was characterized by auditory hallucinations of commenting and commanding type, somatic hallucinations, bizarre delusions, disturbed biofunctions and marked psychosocial dysfunction.

One year after the onset of the psychotic process, in addition to the above symptoms, she started experiencing visual hallucinations characterized by seeing miniatures (a few cubic centimeters) of certain animals. She would see the miniatures of snakes, pigs and dogs embedded in food and in the external objective space. The miniatures would resemble the real animals in their appearance and movement. These animals would also climb on her body, especially her forehead, from where she would often try to remove them. As the animals would be mostly inside her food, at times she would experience the sensation of chewing them and, consequently, would spit out the food. She would also feel that the miniature creatures were crawling through her body and, sometimes, exiting her body through her abdomen. As a result of these symptoms, she reduced her food intake significantly.

About 2 years after the onset of psychotic symptoms, she developed blurring of vision and ophthalmological examination revealed increased intraocular pressure suggestive of glaucoma which was successfully treated with pilocarpine eye drops.

On presentation, the patient had avoided eating for about 2 months and had significant weight loss. Poor insight into her illness was noted. There was no history of cognitive disturbances, substance abuse, seizures, recurrent headache, fever or head injury.

On investigation, electroencephalogram, non-contrast computerized tomography and magnetic resonance imaging of her brain did not reveal any abnormalities. Her haemogram, blood biochemistry, liver function test, renal function test and electrocardiogram were within normal limits.

Based on the history and examination findings, she was diagnosed with Schizophrenia, Paranoid type (PANSS total score 80). She was treated with olanzapine 20 mg/day, and improved over a period of 6 weeks (PANSS total score 37).

Lilliputian hallucinations are rare visual hallucinations in patients with functional psychosis. Patients complain of seeing miniature objects and persons, usually describing them as "persecutor dwarfs" or "life from another world".<sup>9</sup> There are three other case reports which have described Lilliputian hallucinations in patients with schizophrenia.<sup>6,8,9</sup> Another case report described the co-existence of Ekblom's syndrome (i.e. delusions of parasitosis) and Lilliputian hallucinations in a patient with dementia.<sup>5</sup> In the case described above, the patient not only reported seeing miniatures, but also described the sensation of miniatures moving over her body, analogous to a delusion of parasitosis. A comparable phenomenon has also been previously documented.<sup>5,10</sup> Lilliputian hallucinations involving food, resulting in reduced food intake, was similarly described in another case report.<sup>7</sup>

The pathogenesis of Lilliputian hallucinations is not clear; they could be described as micropsia for internally generated images or percepts. The neurobiological correlate of Lilliputian hallucinations is poorly understood but the phenomenon is more commonly reported after damage of the visual association cortex.<sup>10</sup>

Further research should focus on firstly, developing an understanding of the pathophysiology of Lilliputian hallucinations in both organic and functional disorders and, secondly, on the implications of this phenomenon on the prognosis and course of schizophrenia.

## Correspondence

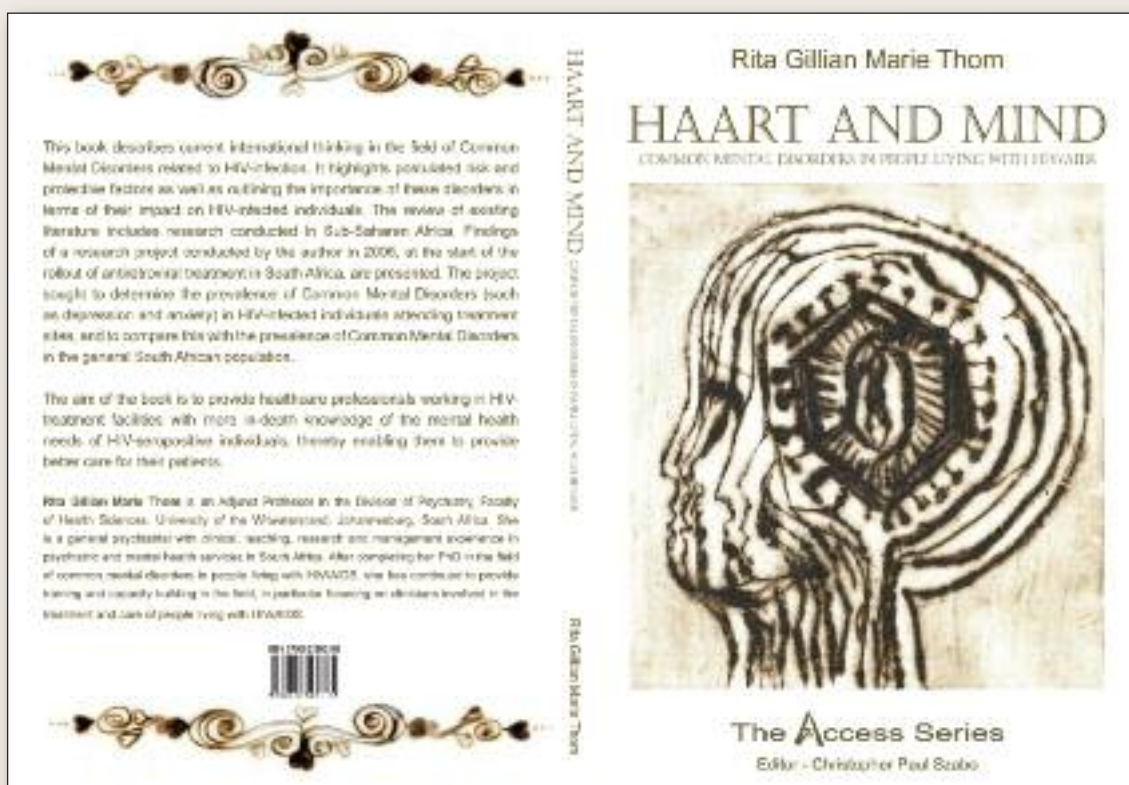
Dr Sandeep Grover  
email: [drsandeepg2002@yahoo.com](mailto:drsandeepg2002@yahoo.com)

**S Grover, V Kattharaghata Girigowda, V Kumar**  
Department of Psychiatry, Postgraduate Institute of Medical  
Education & Research, Chandigarh, India

## References

1. Cohen MA, Alfonso CA, Haque MM. Lilliputian hallucinations and medical illness. *Gen Hosp Psychiatry* 1994; 16:141-143.
2. Leroy R. Les hallucinations lilliputiennes. *Ann Med Psychol* 1909;10:278-289.
3. Todd J. Trichlorethylene poisoning with paranoid psychosis and Lilliputian hallucination. *Br Med J* 1954;1:439-440.
4. Goldin S. Lilliputian hallucinations; eight illustrative case histories. *J Ment Sci* 1955;101:569-576.
5. Kanazawa A, Hata T. Coexistence of the Ekblom syndrome and lilliputian hallucination. *Psychopathology* 1992;25:209-211.
6. Hendrickson J, Adityanjee. Lilliputian hallucinations in schizophrenia: case report and review of literature. *Psychopathology* 1996;29:35-38.
7. Chand PK, Murthy P. Understanding a strange phenomenon: Lilliputian hallucinations. *German J Psychiatry* 2007;10:21-24.
8. Lewis DJ. Lilliputian hallucinations in the functional psychoses. *Can Psychiat Ass J* 1961;6:177-201.
9. Estilae F, Nejad AG. The reflection of Lilliputian hallucinations in paintings of a schizophrenic patient. *European Psychiatry* 2011;26(Suppl 1):03-211.
10. Frassinetti F, Nichelli P, Pellegrin GD. Selective horizontal dysmetropsia following prestriate lesion. *Brain* 1999;122:339-350.

## Copies of “HAART AND MIND – common mental disorders in people living with HIV/AIDS” are now available



**Where:** Adler Museum, Faculty of Health Sciences, University of the Witwatersrand, 7 York Road, Parktown 2193, Johannesburg, South Africa

**Who:** Contact Cheryl-Anne Cromie Cheryl-Anne.Cromie@wits.ac.za / 011- 717 2067

**Cost:** R120 (plus postage, if required)