

Audit of head and neck fine needle aspiration cytology from a tertiary institution in south - west Nigeria.

¹Akinmoladun V. I., ²Okolo C. A., ¹Aladelusi T. O., ¹Gbolahan O. O.

¹Department of Oral and Maxillofacial Surgery, College of Medicine, University of Ibadan.

²Department of Pathology, College of Medicine, University of Ibadan.

ABSTRACT

Objective: FNAC is a well-established initial investigative tool for head and neck masses due to its being cost effective, quick to perform, low associated morbidity, high patient acceptability and high diagnostic accuracy. This study aimed to audit the utilization and deployment of FNAC in the management of head and neck masses in our hospital

Methods: This is a retrospective study of all patients presenting for fine needle aspiration cytology of lesions in the head and neck region at our hospital for fifteen years (from 2008 to 2017). All data were extracted from the FNA clinic records. The data was analyzed using the SPSS version 21 and results presented as figures and percentages.

Results: During the study period, 3194 patients were seen, 2789 had complete information for analysis. There were 875 males (31.4%) and 1914 females (68.6%). The ages ranged between 1 year and 103 years. Overall mean age was 39.7 + 17.9 years. The commonest site was the anterior neck, accounting for 1323 (47.4%) of the lesions. Cervical lymph nodal swellings accounted for 548 (19.6%). Benign lesions constituted 35%. A total of 160 (5.7%) specimens were reported as inconclusive. Malignant lesions had the highest prevalence in the 1-10year age group. There was no complication reported with any of the procedures.

Conclusion: FNAC is an established tool for investigating head and neck lesions in our hospital. The practice however needs to be further developed in line with the recommendations of National Institute for Clinical Excellence for improved outcomes.

Key words: Fine needle aspiration cytology, head neck masses.

INTRODUCTION: Fine-needle aspiration cytology (FNAC) is defined as a technique in which a narrow gauge needle is introduced into a mass, cells are aspirated and smeared onto a slide, stained appropriately, and a cytological diagnosis is rendered. Fine-needle aspiration biopsy is accepted as a first-line investigation for palpable masses of the head and neck¹⁻⁴. Given that the clinical and radiological examinations of head and neck masses are not always sufficient for diagnosis, and open biopsy could be hazardous especially in lateral neck masses, the cytological examination of the material obtained by fine-needle aspiration has become an efficient tool in the preoperative investigation of these lesions^{3,4}. It is indicated in any mass in this region, that is not an obvious abscess or aneurysm and persists despite

prescribed antibiotic therapies. Fine-needle aspiration cytology separates inflammatory and reactive processes that usually do not require any surgical intervention from neoplastic lesions that may be categorized as benign or malignant^{1,5}. This technique also aids to establish diagnoses in nonsurgical cases of head and neck disease and helps to allay patients' fears of potential head and neck malignancies which allows for informed observation of some lesions in this region. Its application further extends to helping to differentiate carcinoma from lymphoma¹. Although it cannot replace histologic examination, as the biological material obtained does not provide precise cellular architectural details, fine needle aspiration has the advantage of providing samples from multiple lesion sites, thus rendering incisional biopsy unnecessary in some cases.⁶ The aim of this study is to evaluate FNAC in the management of head and neck masses in our hospital.

METHODS

This was a retrospective study of all patients presenting for fine needle aspiration cytology for lesions in the head and neck region at our hospital for fifteen years (from 2008 to 2017). The patients' bio-

Correspondence: Aladelusi T.O.

Department of Oral and Maxillofacial Surgery
College of Medicine, University of Ibadan.

E mail: drtimmylee@gmail.com

Tel: +2348033662155

Received:31/05/2019

Accepted:19/08/2019

<https://dx.doi.org/10.4314/ajoh.v9i1.3>

recorded, as well as the anatomical site of the lesion amongst other data which were extracted from the FNA clinic records. The data was analyzed using the SPSS version 21. The procedure for FNAB was performed by a pathologist using a 2.5 cm long, 23–25 gauge needle attached to a 10 ml disposable syringe. Multiple smears were prepared from the aspirate. The smears were immediately fixed with ether-ethanol mixture & stained by May Grunwald Giemsa and PAP stains. The prepared smears were examined for adequacy and the procedure was immediately repeated for samples that were unsatisfactory. The diagnoses were subsequently recorded. Depending on the result of the cytological examination, appropriate

treatment plan was drawn up, including follow up, biopsy, medical treatment or surgical intervention.

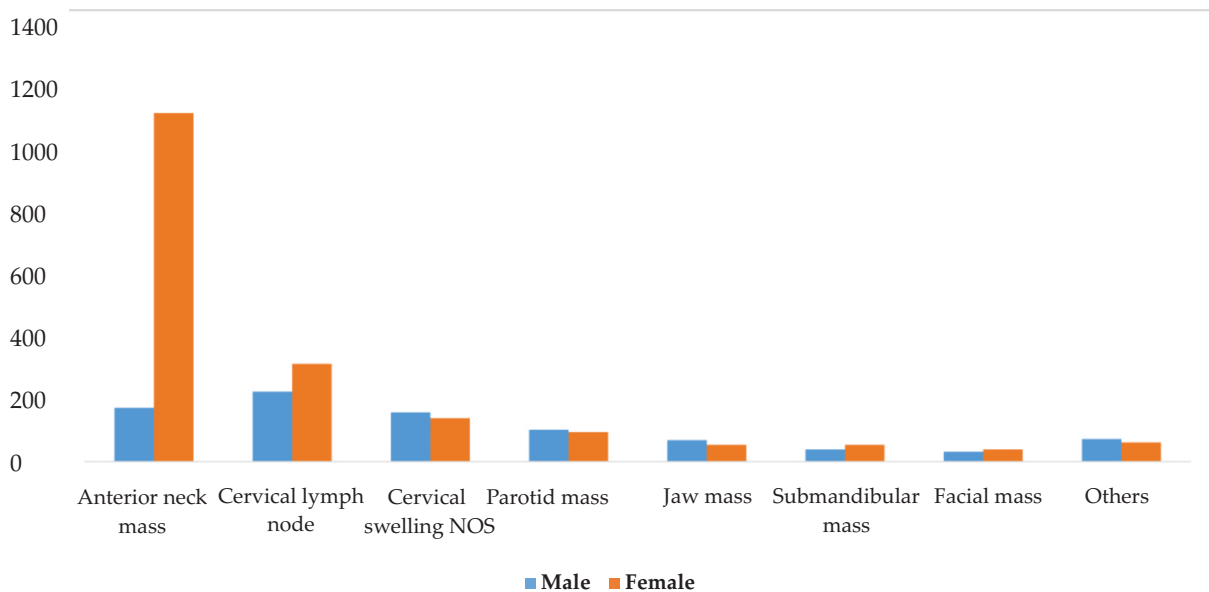
RESULTS

During the study period, 3194 head and neck cases were seen and 2789 had complete information for analysis. This consisted of 875 males (31.4%) and 1914 females (68.6%). The minimum age was 1 year 4 months and the oldest was 103 years old and overall mean age of 39.7 + 17.9 years with male having a mean of 37.5 + 20.4 and female at 40.7 + 16.6 years Table 1.

Table 1: Age and gender of participants

Age group	Gender		Total
	Male	Female	
1 - 10	107	95	202
11 - 20	94	110	204
21 - 30	131	285	416
31 - 40	162	499	661
41 - 50	132	398	530
51 - 60	114	318	432
61 - 70	92	155	247
71 - 80	34	42	76
81 - 105	9	12	21
Total	875	1914	2789

The commonest site of swelling in the head and neck region was the anterior neck accounting for 1323 (47.4%) of the lesions seen. This was followed by cervical lymph nodal swellings [548 (19.6%)]. Figure 1

Figure 1: Site subjected to cytological examination

Benign lesions were the most frequently diagnosed and are more common in the anterior neck region and in females while majority of the malignant lesions were seen in the cervical lymph nodes. (Table 2, Fig 2). Benign lesions were reported in 35% of specimen taken from male participants while 20.5% were malignant. However, in female participants 63.7 % of specimen were reported as benign while 10.3% were reported as being malignant. (Figure 2). 160 (5.7%) specimens were reported as inconclusive.

Table 2: Result of cytological examination of specimen

	Benign	Inflammatory/ reactive	Malignant	Inconclusive	Suspicious	Negative/ normal	Cyst	Total
Anterior neck mass	1159	53	39	47	20	2	3	1323
Cervical lymph nodes	37	292	161	32	24	2	0	548
Neck mass NOS	66	132	63	25	16	1	1	304
Parotid mass	100	42	24	14	14	3	2	199
Others	49	21	39	15	10	1	0	135
Jaw mass	35	18	30	14	10	1	0	108
Submandibular mass	44	37	3	4	2	1	0	91
Facial mass	31	8	15	8	3	2	1	68
Palatal mass	8	0	2	1	2	0	0	13
Total	1529	603	376	160	101	13	7	2789

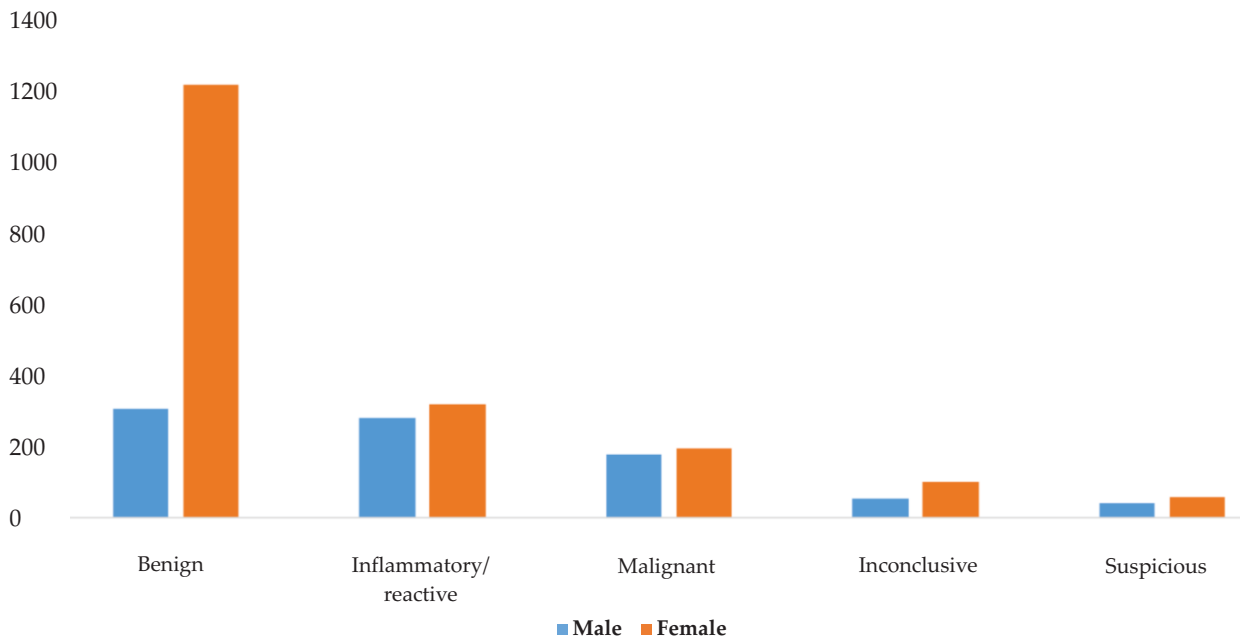


Figure 2: Report of cytological examination per gender

Table 3 shows the disease pattern as seen in each age group. Malignant lesions formed 13.5% of all the lesions seen, accounting for 31.6% and 28.6% of lesions in 71 – 80 and > 80 years age groups. However, a high incidence of malignant lesion was recorded in the 1-10 year age group where 23.3% of examined lesions were reported as being malignant. Meanwhile, prevalence of benign lesion was highest in the 41-50 group (65.1%).

Table 3: FNAC diagnosis and age group

Age	Benign	Inflammatory / reactive	Malignant	Inconclusive/ Unsatisfactory	Suspicious	Negative/ normal	Cyst	Total
1-10	32	104	47	12	6	1	0	202
11-20	59	88	25	19	12	0	1	204
21-30	211	130	39	23	11	1	1	416
31-40	424	119	48	43	24	1	2	661
41-50	345	75	67	18	22	2	1	530
51-60	281	43	66	22	12	7	1	432
61-70	131	35	54	16	10	0	1	247
71-80	37	7	24	4	3	1	0	76
81-105	9	2	6	3	1	0	0	21
Total	1529	603	376	160	101	13	7	2789

DISCUSSION

Although histology remains the gold standard for tissue diagnosis, FNAC remains an indispensable, inexpensive, minimally-invasive and efficient investigative tool in the initial evaluation of head and neck lesions. Fine-needle aspiration cytology is well established as an initial investigation for all head and neck soft tissue masses because it is cost effective, quick to perform, has low morbidity, high patient acceptability and high diagnostic accuracy^{4,7,8}. In this study with a total of 3194 patients seen during the study period, the utilization of FNAC for head and neck lesions is relatively significant in our hospital and uptake is spread across all age groups. More significant is the high paediatric utilisation with patient less than 20 years of age constituting 14.6% of all subjects. It was previously reported that FNAC was not well tolerated in the paediatric age group due to poor cooperation⁹. This study however showed that all age groups benefited from FNAC, although majority of our participants are in the 31-40 year age group, similar to previous report by Shekar et al¹⁰. It is also noteworthy that a high percentage of patients in the first decade of life had lesions which were reported as malignant. This is a pointer to the need for a raised index of suspicion when assessing head and neck masses in children, particularly when unresponsive to usual therapies. Our study showed a higher number of female participants in consonance with the findings of some previous authors^{11,12} but at variance with other findings that reported male preponderance^{10,13,14}. The high number of females in our study could be due to benign thyroid lesion which forms the majority of lesions in this series and is more commonly seen in females.

Aspirates from thyroid masses constituted the highest samples for FNAC from the head and neck region in the present study, followed by lymph nodes. This is in agreement with the study of Fernandes et al¹⁵, (56.45% thyroid) but at variance with most other earlier studies that reported lymph nodes as the commonest source of aspirates^{11,16,17}. Most of the studies reporting lymph node as most common site are from the Indian subcontinent with a high prevalence of oropharyngeal malignancy with high tendency for nodal involvement. Only 5.7% of the specimens were reported as inconclusive/unsatisfactory in the present study. This is similar to 6% reported in the study of Jain et al¹⁸, but lower than 13% observed in the study of Mohamed et al¹³. The recommended acceptable range

for unsatisfactory FNAC suggested in the guideline of the Papanicolaou Society of Cytopathology for fine needle aspiration procedure and reporting is below 15%¹⁹. The fact that FNAC is usually performed in our centre by a pathologist experienced in the procedure could explain the low reportage of inconclusive results in this study. The cost effectiveness and diagnostic accuracy of FNAC and the percentage of satisfactory specimens can be further increased by using ultrasound guidance^{1,3,15,20}. Ultrasound can also be a helpful distraction during the procedure, as the technology and display screen can be used to redirect the patient's attention. The patient will also find the initial ultrasound examination for target location a painless process, and this will build some initial trust for the rest of the FNA procedure. This is particularly so in the paediatric age group.

In the present study, benign lesions accounted for the majority (54.8%) of lesions, this was followed by reactive/granulomatous lesions (21.6%). Malignant lesions accounted for 13.4 % of the cases seen. This is similar to the findings in the study of El Hag et al²¹. (13%) and Mohamed et al¹³. (13%), but at variance with the studies of Cheng et al²² (50%) and Steel et al²³ (59%). As opined by Mohamed et al¹³, this observed difference could be due to epidemiological variation between developed and developing countries. We also observed a higher prevalence of malignant lesion in the 1-10-year age group (23.3%) while benign lesions had the highest prevalence in the 41-50 year age group (65.1%).

Cytological evaluation is vital in discriminating between reactive lymphadenopathy and malignant disease^{1,24}. Majority (42.8%) of malignancies reported in the present study were seen in the cervical lymph nodal aspirates, this is similar to the findings of Shekhar et al¹⁰ and Savitri et al²⁵. This is thought to be due metastasis to the node from primary sites. It is important to note that the finding of a malignant lesion in the neck node may be the first indicator of an occult malignancy. The clinical value of aspiration cytology is not limited to tumours; several authors have reported its use for the diagnosis of inflammatory and infectious lesions⁶. We also found 21.6% of specimens in the present study were reported as inflammatory or reactive. This is more so in the cervical lymph nodes where 48.4% were inflammatory lesions, this is higher than the 27.9% reported by Faro et al²⁶. The higher value noted in this

study could be due to the higher volume of specimen examined in the present study or perhaps a high prevalence of inflammatory head and neck lesions in our environment. Several authors^{13,18} have noted that FNAC is associated with little or no complication^{13,18}, there was no complication recorded with any of the procedures in this study.

CONCLUSIONS

FNAC is a useful first-line investigative tool with minimal risk of complication for head and neck lesions among all age groups. Benign lesions constitute the commonest condition for FNAC in patients presenting with head and neck swellings. Usage can be improved and outcome bettered by image guidance, on the spot assessment of test and immediate reporting. A standard method of describing a swelling is desirable; 'anterior neck masse' and 'lymph node' as recorded in our register and some other reports make separation of tumours into anatomic locations or entities impossible. The National Institute for Clinical Excellence (NICE) recognizes the importance of FNA in head and neck cancer, and in their document titled "Improving outcomes in head and neck cancers"²⁷ recommended for optimum management of all patients with neck lumps structured clinics with a cytopathologist present and preferably FNA with ultrasound guidance.

REFERENCE

1. Amedee RG, Dhurandhar NR. Fine-Needle Aspiration Biopsy. *Laryngoscope* 2001; 111: 15511557.
2. Jahshan F, Doweck I, Ronen O. Learning Curve of Fine-Needle Aspiration Cytology of Head and Neck Masses. *IMAJ* 2016; 18: 350353.
3. Jakowski JD, Dinardo LJ. Advances in head and neck fine-needle aspiration and ultrasound technique for the pathologist. *Semin Diagnostic Pathol* 2015; 32: 284295.
4. Layfield LJ. Fine-Needle Aspiration in the Diagnosis of Head and Neck Lesion : A Review and Discussion of Problems in Differential Diagnosis. *Diagnostic Cytopathol* 2007; 35: 798805.
5. Huyett P, Monaco SE, Choi SS, Simons JP Utility of Fine-Needle Aspiration Biopsy in the Evaluation of Pediatric Head and Neck Masses. *Otolaryngol Head Neck Surg* 2016; 154(5):928-35
6. Lacob A, Zazgyva A, Ormenisan A, Mezei T, Sin A, Tulinca M . Effectiveness of fine-needle aspiration cytology in the diagnosis of lateral cervical nonthyroid tumors. *Medicine (Baltimore)* 2016; 95: e4448.
7. Tandon S, Shahab R, Benton J, , , . Fine-needle aspiration cytology in a regional head and neck cancer center: comparison with a systematic review and meta-analysis. *Head Neck* 2008; 30: 1246 1252.
8. Nasuti J, Gupta P, Baloch Z. Diagnostic value and cost-effectiveness of on-site evaluation of fine needle aspiration specimens: review of 5,688 cases. *Diagn Cytopathol* 2002; 27: 14.
9. Purnima M, Rajni B, Pandey MK. Role of Fine Needle Aspiration Cytology in Head and Neck Lesions of Paediatric Age Group. *J Clin Diagnost Res* 2013; 7: 10551058.
10. Shekhar H, Kaur A, Agrawal P, Pancharia A, Jadeja P. Fine needle aspiration cytology in head and neck swelling : a diagnostic and therapeutic procedure. *Int J Res Med Sci* 2014; 2: 16671671.
11. Sreedevi P, Kishore, Kumar Ch Parankusa NC. Diagnostic Role of FNAC in Evaluation of Head and Neck Lesions. *IOSR-JDMS* 2016; 15: 1113.
12. Suryawanshi KH, Rajshri PD, Dravid N V, Nandkumar D V, Yogesh T. Spectrum of FNAC in palpable head and neck lesions in a tertiary care hospital in india- a 3 years study. *Ind J Pathol Oncol* 2015; 2: 713.
13. Mohamed MH, Hitam S, Brito-Mutunayagam S, Yunus MRM. Role of FNAC in Evaluation of Neck Masses. *J Curr Surg* 2013; 3: 1923.
14. Ahmad T, Naeem M, Ahmad S, , . Fine Needle Aspiration Cytology (FNAC) And Neck Swellings In The Surgical Outpatient. *J Ayub Med Coll Abbottabad* 2008; 20: 3032.
15. Fernandes VT, Santis RJ De, Enepekides DJ, Higgins KM. Surgeon-performed ultrasound guided fine-needle aspirate biopsy with report of learning curve; a consecutive case-series study. *J Otolaryngol - Head Neck Surg* 2015; 44: 4251.
16. Maniyar AU, Patel HL, Parmar BH. Study of Cyto-diagnosis of Head and Neck Neoplastic Lesions and Comparison with Histopathology. *Research and Reviews Histopathology. J Med Heal Sci*; 2.
17. Khetrupal S, Jetley S, Jairajpuri Z, Rana S, Kohli S. FNAC of head & neck lesions and its utility in

- Clinical diagnosis: a study of 290 cases. *NJMR* 2015;5:3338.
18. Jain M, Majumdar DD, Agarwal K, Bais AS, Choudhury M. . FNAC as a diagnostic tool in Pediatric head and neck lesions. *Indian J Paediatr* 1999;36:921923.
 19. The Papanicolaou Society of Cytopathology Task Force on Standards of Practice. Guidelines of the Papanicolaou Society of Cytopathology for fineneedle aspiration procedure and reporting. *Diagn Cytopathol* 1997;17:239247.
 20. Jeong EJ, Chung SR, Baek JH, Lim HK, Lee JH, Kim JK, et al. A Comparison of Ultrasound-Guided Fine Needle Aspiration versus Core Needle Biopsy for Thyroid Nodule : Pain , Tolerability , and Complications. *Endocrinol Metab* 2018;33:114120.
 21. El Hag AI, Chiedozi LC, Reyees AFA, Kollur, SM. Fine Needle Aspiration Cytology of Head and Neck Masses Seven Years ' Experience in a Secondary Care Hospital. *Acta Cytol* 2003; 47: 387–392.
 22. Cheng AT, Dorman B. Fine needle aspiration cytology: the Auckland experience. *Aust NZ J Surg* 1992;62:368–372.
 23. Steel BL, Schwartz MR, Ramzy I Fine needle aspiration biopsy in the diagnosis of lymphadenopathy in 1,103 patients. Role, limitations and analysis of diagnostic pitfalls. *Acta Cytol* 1995;39:76–81.
 24. Smith PA, Giles TE. Fine needle aspiration cytology of head and neck diseases : advantages and limitations. *Diagnostic Histopathol* 2010; 16: 287–294.
 25. Savitri C, Dimple D, Aditi D. Fine needle aspiration cytology of neck lesion - an experience at tertiary care hospital in central Gujarat. *Natl J Med Res* 2012;2: 255–259.
 26. Faro R, Mohammed A, Atanda A. Diagnostic utility of fine needle aspiration cytology in the evaluation of peripheral lymphadenopathy. *West Afr J Med* 2018;35: 162–167.
 27. National Institute for Clinical Excellence. Improving outcomes in Head and Neck cancer - The manual. London, 2004.