

CASE REPORT / CAS CLINIQUE

CASE REPORT: CALCIFIED CHRONIC SUBDURAL HAEMATOMA IN AN ELDERLY NIGERIAN**HEMATOME SOUS DURAL CHRONIQUE CALCIFIÉ CHEZ UN NIGÉRIAN ÂGÉ. A PROPOS D'UN CAS**

BANKOLE O. Babafemi ¹
 UKPONMWAN Efosa ¹
 KANU Okezie O. ¹
 ODUSANYA Benjamin ¹
 ARIGBABU S.O. ¹

1. Neurosurgery Unit, Department of Surgery, Lagos University Teaching Hospital, Idi-Araba, Lagos

E-Mail Contact - BANKOLE O. Babafemi : [f_baba\(at\)yahoo\(dot\)com](mailto:f_baba@yahoo.com)

Mots-clés: *Hématome sous dural, Hématome sous dural chronique, calcifié.*

Keywords: *armoured brain, calcified chronic subdural haematoma.*

ABSTRACT

Calcified chronic subdural haematoma [CCSDH] is a rare complication of the relatively more common condition of Chronic Subdural Haematoma (CSDH). We present the case of a 68yr old man referred with a 2 week history of sudden onset Right hemi paresis generalized tonic clonic seizures and aphasia. There was a history of mild head injury 7 years prior to presentation and computerized tomographic scan showed features suggestive of a Calcified Chronic Subdural Haematoma. He deteriorated rapidly prior to surgical intervention and had an emergency craniotomy with evacuation of the lesion performed. Unfortunately patient died 12 hours post operatively never having woken up after the operation. An acute subdural haematoma was discovered at post mortem.

RESUME

L'hématome sous-dural calcifié (HSDCC) est une complication rare Nous présentons le cas d'un patient de 68 ans ayan présenté en deux semaines une hémiparésie avec des crises toniques généralisées associée à une aphasie. Les antécédents étaient marqués par une blessure légère de tête 7 ans auparavant. Le scanner a montré des images suggestives d'hématome sous-dural calcifié. Il s'est détérioré rapidement avant l'intervention chirurgicale et a eu en urgence une craniotomie avec évacuation de la lésion. Malheureusement le patient est décédé 12 heures après l'opération sans s'être réveillé. L' HSDCC a été découvert en post mortem.

INTRODUCTION

Calcified chronic subdural haematoma [CCSH] is an infrequent complication of the more common condition of Chronic Subdural Haematoma(7,8,9). Since it was first described in 1884(7), many reports have been generated especially with the advent of modern neuroimaging. The diagnosis is usually made with the aid of a CT scan or an MRI although a plain skull X-ray will also show the calcific density. These calcifications are mostly found at the convexities(17,2,10,18,13,15,11). While there are many reports in literature highlighting this condition no previous report of this condition in our environment exists even though subdural haematoma is well recognized.

CASE SUMMARY

A 68yr-old man was referred for Neurosurgical review on account of Brain CT scan findings. He had a 2-week history of sudden onset of weakness of the right side of the body, loss of speech and generalized tonic clonic seizures. There was no associated loss of consciousness. He regained speech later but it remained

slurred. There was a history of mild head injury 7 years prior to presentation. He was not a known hypertensive or diabetic. He was being treated for a presumed Cerebrovascular Accident (CVA) when a Brain CT scan was done and he was sent for Neurosurgical review. Examination revealed a conscious, ill looking elderly man, with an upper motor neuron Right facial nerve palsy, he had tremors, hypertonia and hyper reflexia of the Right upper and lower limbs with MRC power grade 3. Brain CT scan showed a lentiform mass of mixed density with calcification in the Left fronto-parieto-temporal region with a central hypo dense area especially in the parietal region (figure 1). A diagnosis of calcified chronic subdural haematoma co-existing with an old infarct was made. At the time of presentation he appeared otherwise stable and was scheduled for a craniotomy on the next elective list. However, his Glasgow Coma Scale score dropped to 11 the next day therefore an emergency craniotomy and evacuation of organized clot was performed. Operative findings were a cheese like mass in the subdural space with a calcified wall and chocolate-like core extending from the Left frontal lobe to the parieto-occipital region (figure 2). Most of the mass was excised but it proved difficult separating the inner layer of the calcification from the underlying brain without provoking bleeding and therefore this was abandoned. Dura hitching stitches were placed in the extradural space as a precaution and the procedure terminated. Unfortunately, patient did not regain consciousness after the surgery and he died 12 hours later in the Intensive Care Unit. At autopsy a massive acute subdural haemorrhage was found in the cavity where the calcified mass had been excised and there was evidence of tonsillar herniation through the Foramen Magnum.

DISCUSSION

Calcified chronic subdural haematoma was first described in 1884(7,1) as a postmortem finding and is found in 0.3 - 2.7% of patients with chronic subdural haematoma(8,9,3). It occurs more frequently in children and young adults than in the elderly(3). It is sometimes referred to as 'armoured brain'. Several aetiological factors have been implicated in its pathogenesis. Head injury was a strong factor in the case presented above as corroborated by Wakamoto et al (16). It can also be a long term sequelae of ventriculo-peritoneal shunt insertion in children(7,13,14). It has also been associated with extra axial primary malignant lymphoma(4).

The pathogenesis of CCSH is unclear, the haemorrhage is thought to progress from hyalinization to calcification but it has been found that it takes at least six months for calcification to develop. However cases have been reported occurring many years after initial trauma as in our patient who became symptomatic seven years after the head trauma. (13,1,3,12).

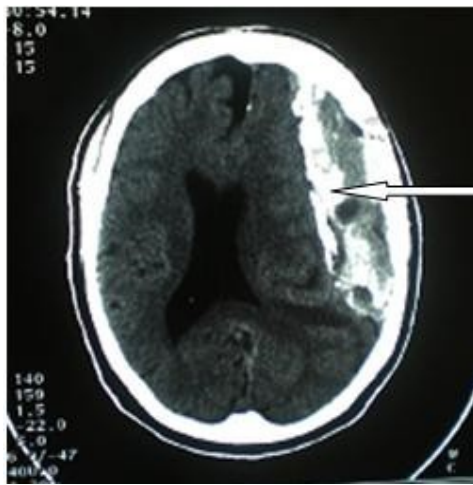
Patients can present with hemiparesis, aphasia, seizure, gait disturbances, mental and physical retardation and altered consciousness(17). However asymptomatic cases have also been reported(12,6). Other conditions that can be considered to mimic CCSH are calcified epidural haematoma(18), calcified chronic subdural empyema(5), meningioma(2), and calcified arachnoid cyst(15).

Treatment of CCSH depends on whether it is asymptomatic and also the age of the patient. Some workers have advocated observation for elderly patients with little or no symptoms. However, most surgeons agree that the onset of acute symptoms related to the lesion should be treated by craniotomy and excision of the organized clot. Sometimes the inner membrane is adherent to the underlying brain but this can usually be separated from the underlying arachnoid although this was not possible in our patient.

Generally good post operative neurological recovery is reported in most cases with gradual but definite improvement in pre operative clinical state. Acute subdural haematoma is a known complication following surgery and it could be fatal as seen in this case. Our patient showed a rapid decline in his clinical condition over a relatively short period of time. The poor outcome from surgery can be attributed to the significantly altered level of consciousness by the time of intervention.

CONCLUSION

Calcified chronic subdural haematoma is a rare but treatable condition. Modern imaging techniques have made its diagnosis easier and removal of the mass lesion when indicated is achievable. Acute subdural haematoma is a recognized post-operative complication and this can be fatal if not diagnosed early and treated promptly. Delay in intervention after onset of symptoms can result in a poor outcome.

**Figure 1**

Lentiform mass of mixed densities with calcification in the left fronto-parieto-temporal region with a central hypo dense area (white arrow).

**Figure 2**

Excised mass with a central core of chocolate coloured cheese-like material (black arrow) and the calcified wall encasing the organized haematoma (white arrow).

REFERENCES

1. AFRA D. Ossification of subdural hematoma. Report of two cases. *J Neurosurg* 1961; 18:393-397.
2. CUSICK JF, BAILEY OT. Association of ossified subdural hematoma and a meningioma. Case report. *J Neuro surg* 1972; 37:731-734.
3. DAMMERS R, TER LAAK-POORT M, MAAS IR. Armoured brain: case report of a symptomatic Calcified Chronic Subdural Haematoma. *J Neurol Neurosurg Psychiatry* 2007;78:542-543.
4. GOTOH M, TSUNO K, HANDA A, NISHIURA T, ISHIMITSU H, NISHIDA A. Extraaxial primary malignant lymphoma associated with calcified chronic subdural haematoma: a case report. *No Shinkei Geka* 2001;29(3):259-64.
5. HIKAWA T, UCHIDA S, FUJIKI M, KOBAYASHI H, Ooba H. Calcified chronic subdural empyema: a case report. *Neurosurgery Quarterly* 2006;16(3):152-154.
6. IDE M, JIMBO M, YAMAMOTO M, UMEBARA Y, HAGIWARA S. Asymptomatic calcified chronic subdural haematoma-report of three cases. *Neurol Med Chir (Tokyo)* 1993; 33:559-563.
7. IMAIZUMI S, ONUMA T, KAMEYAMA M, NAGANUMA H. Organized chronic subdural hematoma requiring craniotomy. Five case reports. *Neurol Med Chir (Tokyo)* 2001;41:19-24.
8. JONG-SOO P, EUN-LK S, DONG-WON K, SANG-PYO K. Calcified Chronic Subdural Haematoma associated with intra cerebral haematoma. *J Korean Neurosurg Soc* 2003; 34:177-178.
9. Mc LAUREN RL, MC LAUREN KS. Calcified subdural haematoma in childhood. *Journal of Neurosurgery* 1966; 24(3): 648-655.
10. MIYAGI Y, MORIOKA T, KIMURA Y, FUKUI M. Calcified convexity dura mater and acute epidural hematoma mimicking calcified chronic subdural Haematoma. *Neuroradiology* 1995; 37:551-552.
11. MOON KS, LEE JK, KIM TS et al. contralateral acute subdural haematoma occurring after removal of calcified chronic subdural haematoma. *J Clin Neuroscience* 2007;14:283-286.
12. NIWA J, NAKAMURA T, FUJISHIGE M, HASHI K. Removal of a large asymptomatic calcified chronic subdural haematoma. *Surg Neurol* 1988; 30:135-139.
13. PAPANIKOLEOU PG, PALEOLOGOS TS, TRIANTOFYLLOU TM, CHATZIDAKIS EM. Shunt revision after 33years in a patient with bilateral Calcified Chronic Subdural Haematoma: case illustration. *J Neurosurgery* 2008; 108(2): 401.
14. SHARMA RR, MAHAPATRA A, PAWAR SJ, SOUSA J, ATHALE SD. Symptomatic calcified subdural haematomas. *Paediatric Neurosurgery* 1999 Sept;31(3):150-154.
15. SHUANGSHOTI S. Calcified congenital arachnoid cyst with heterotopic neuroglia in wall. *J Neurol Neurosurg Psychiatry* 1978; 41:88-94.
16. WAKAMOTO H, MIWA T, ORII M, MIYAZAKI H, ISHIYAMA N. Calcified chronic subdural haematoma complicated with subcortical haemorrhage: case report. *No Shinkei Geka* Mar 2003; 31(3):269-73.
17. YAN HJ, LIN KE, LEE ST, TZAAN WC. Calcified chronic subdural haematoma: Case report. *Changeng Yi Xue Za Zhi* 1998; 21:521-525.
18. YUASA H, WATANABE H, UEMURA Y, TOKITO S. Intra osseous haematoma of the skull: case report. *Neurosurgery*: May 1992; 30(5):776-777