

Original Article

Effect of Vitamin A on Infertility Induced by Aluminum Chloride in Male Albino Mice

Zainab EL Mabrouk^{1*}, Habiba El Jaafari¹, Samira Elghul¹, Naema Shibani², Salma Abuser¹

¹Department of Zoology, Faculty of Science, University of Tripoli, Tripoli, Libya

²Department of Life Sciences, School of Basic Science, Libyan Academy of Postgraduate Studies, Janzur, Libya.

ARTICLE INFO

Corresponding Email. zainab_el@yahoo.com

Received: 02-05-2021 **Accepted:** 10-05-2021 **Published:** 11-05-2021

Keywords: Vitamin A, Histoarchitecture, Sperm Parameters, Mice.

This work is licensed under the Creative Commons Attribution International License (CC BY 4.0).

<http://creativecommons.org/licenses/by/4.0/>

ABSTRACT

Aims. The present study was designed to investigate the reproductive toxicity of Aluminum chloride ($AlCl_3$), and the potential protective role of vitamin A in adult male mice. **Methods:** Twenty-one adult male albino mice were divided into three equal groups, the first group injected with distilled water, the second group injected with $AlCl_3$ (120 mg/kg BW) daily for 10 days. The third group was also injected with $AlCl_3$ (120 mg/kg BW) for 10 days, then injected with vitamin A (40 mg/kg) for another 10 days. All doses were given once daily via intraperitoneal injection. **Results:** The results showed that $AlCl_3$ cause significant decrease in body weight, sperm motility, and sperm count, while it led to a significant increase in the number of abnormal sperm morphology. $AlCl_3$ caused apparent alterations in the histological structure of the testes. While treatment with vitamin A showed a protective effect on the damage caused by $AlCl_3$, on body weight, sperm parameters, and histoarchitecture of mice testes in comparison with $AlCl_3$ treated mice. **Conclusion:** This study affords evidence for the protective role of vitamin A in ameliorating testicular toxicity caused by $AlCl_3$.

Cite this article: EL Mabrouk Z, El Jaafari H, Elghul S, Shibani N, Abuser S. Effect of Vitamin A on Infertility Induced by Aluminium Chloride in Male Albino Mice. *Alq J Med App Sci.* 2021;4(2):40-50.

<https://doi.org/10.5281/zenodo.4749492>

INTRODUCTION

Environmental pollution is a major worldwide public health due to the use of toxic substances such as heavy metals, plastics, pesticides, and other toxic agents. Aluminum (Al) compounds are considered one of the dangerous pollutants that pose a threat to human and animal health [1]. A variety of Al compounds are used in cosmetics, fillers, aluminum cooking utensils, and containers [2] and in purification purposes of drinking water [3]. Moreover, Al is widely used in medicines as anti-diarrheal agents, antacid, vaccines, antiperspirants, and phosphate binders [4]. Additionally, Al compounds are extensively used in food manufacturing and are added to food constituents such as corn, yellow cheese, salt, spices, fermenting agents, and infant formula [5].

Humans and animals are exposed to Al compounds from drinking water [3], food [5], and medicines [4]. Humans are also exposed to Al by inhaling Al dust and through skin contact with cosmetics [6]. Several studies indicated that Al has toxic effects on various organs of the body such as bone, liver kidneys, brain [7], spleen [8], blood parameters [8, 9], and male reproductive system [10,11]. Numerous studies have shown that treated experimental

animals with AlCl_3 resulted in deterioration of sperm parameters, structural alteration in testicular tissues and decrease activity of antioxidant enzymes as well as decrease in testosterone production in rats [11-13], rabbits [14, 15] and mice [16].

The previous study has shown that oxidative stress plays an essential role in causing male infertility by inducing defects in sperm morphology and marked loss in its motility [17]. AlCl_3 can stimulate the oxidation of molecules inside the body thus resulting in oxidative stress. Antioxidants can protect cells either directly or indirectly against the harmful effects of toxic agents [9]. Many studies used vitamin C and E as an antioxidant against the effects of toxicants, but there is a paucity of information regarding the role of vitamin A as an antioxidant. Therefore, in the present study, a high dose of AlCl_3 was used to ascertain the possible protective role of vitamin A in ameliorating the reproductive toxicity induced by AlCl_3 in adult male albino mice.

METHODS

This experimental research on animals performed with the ethical rules recognized by the Libyan National Committee for Biosafety and Bioethics.

Chemical agents

Aluminum chloride ($\text{AlCl}_3 \cdot 6\text{H}_2\text{O}$) was purchased from Sigma, a chemical company. Vitamin A was purchased from Alfrnage pharmacy/ Tripoli/Libya. The solution of AlCl_3 and vitamin A was made fresh at the beginning of each experiment.

Animals

Male albino mice were bred in the animal house of the Zoology department, Faculty of Science, University of Tripoli, Libya. Mice were housed in plastic cages containing wooden flakes in an air-conditioned room. They were kept under standard laboratory conditions (12-h light, 12-h dark, and 25 °C) and fed standard commercial laboratory chow. Water and standard pellet diet were available ad libitum throughout the experimental period.

Experimental design

Twenty-one adult male Swiss albino mice aged between 12 – 14 weeks and their weights between 24 – 28 grams were used in this study. Mice were divided into three groups of seven mice each. The first group (control) injected with distilled water intraperitoneally (i.p.), the second group treated (i.p) with 120 mg/kg BW of AlCl_3 daily for 10 days, and the third group treated (i.p) with the same dose of AlCl_3 as in the second group (120 mg/kg BW) for 10 days, followed by vitamin A (40 mg/kg) (i.p) for additional 10 days. Mice weighed at the beginning of the experiment, before injection, and before sacrifice. At the end of the experiment, mice were sacrificed by cervical dislocation; mice were dissected, epididymis was carefully processed and evaluated for sperm motility, sperm count, sperm morphology, also testes were removed for histological examination.

Determination of sperm parameters

Sperm count

The sperm count of control and treated groups was determined using an improved Neubauer hemocytometer (American optical Co., Buffalo, N.Y.). Seminal fluid was collected in 1 ml of normal saline in a small dish and mixed well to distribute the semen. Sperm suspension was incubated at 37 °C for 10 minutes to separate the spermatozoa in the sperm suspension. Spermatozoa were counted by charging both chambers of the improved

Neubauer hemocytometer with sperm suspension and counted under a light microscope at a 40x magnification. Sperm count was expressed in millions per milliliter (10^6 / ml).

Sperm motility

The percentage of sperm motility was examined according to Ficsor and Ginsberg [18]. A drop of diluted sperm suspension was loaded onto the Neubauer hemocytometer and the number of motile and non-motile sperms of control and treated groups were calculated under the microscope at 40x magnification and expressed as a percentage.

Sperm morphology

To check the existence of any sperm morphological defects, two smears were taken for each mouse and allowed to air dry. The smears were stained with 1% Eosin Yin water for 10 minutes. From each mouse, 500 sperms were examined using a force of 400x magnification to find any morphological abnormalities in the sperm and expressed as a percentage. Abnormal head and tail were evaluated according to Mori et al., [19].

Histopathological examination

Testes from sacrificed mice were removed, washed with normal saline solution, then fixed in 10% neutral formalin for 24 hours. The fixed tissues were dehydrated in an ascending series of alcohol ranging from 70% to 100%. The dehydrated tissues were cleared in xylene (twice), then processed for paraffin embedding. Sections of 5µm thickness were cut using a rotary microtome. The sections were stained with Hematoxylin and Eosin.

Three microscopy slides for each sample were investigated for signs of histopathological changes; vacuolization of seminiferous tubules, detachment and sloughing of germinal epithelium of the seminiferous tubules. A comparative quantitative histopathological assessment of the testes was performed, the average percentage of normal and abnormal tubules was determined for each group. The average percentage of damaged seminiferous tubules was calculated by dividing the number of round tubules with a histopathological marker (detachment, vacuolization and sloughing) by the total number of round tubules in the same field multiplied by 100. The average of three microscopic fields for each slid was taken [20].

Statistical analysis

The data were expressed as mean \pm standard deviation (SD). Data were analyzed using one-way analysis of variance (ANOVA) followed by Duncan's test, to compare the significance of the difference between the control and treated groups for body weight and sperm parameters. Differences were considered statistically significant at $P < 0.05$.

RESULTS

The body weights

The results of the present study showed that administration of $AlCl_3$ caused an apparent effect on the body weight of adult male mice (Table 1). There was a significant decline in body weight of mice treated with $AlCl_3$ at a dose of 120 mg/kg, as their weight before administration was 24 ± 0.378 g, then decreased after the end of injection to 20.4 ± 0.477 g; while the body weight was increased from 23.2 ± 0.491 g to 25 ± 0.589 g in the control group. Also, there was a significant improvement in the body weight of the mice treated with a combination of $AlCl_3$ and vitamin A, as it was increased from 22 ± 0.799 g to 23.7 ± 0.54 g.

Sperm parameters

There was a significant reduction in sperm motility, normal sperm morphology, and sperm count of mice treated with AlCl_3 as compared to the control group and to the AlCl_3 + vitamin A treated group. Injection of mice (i.p.) with 120 mg/kg AlCl_3 for 10 days produced a significant decrease in the sperm count compared to the control group, as the mean value of sperm count of the control group was $26.4 \times 10^6 \pm 2.6152$ / ml and decreased to $22.8 \times 10^6 \pm 4.8682$. A significant increase in sperm count ($26.2 \times 10^6 \pm 4.1214$) was observed in the group administered AlCl_3 + vitamin A in comparison with the AlCl_3 group (Table 2). The percentage of motile sperm was significantly decreased in mice treated with AlCl_3 (39.73 ± 2.834) when compared to the control (73.38 ± 3.3866); additionally, the presence of vitamin A with AlCl_3 caused an increase in the percentage of motile sperms (68.75 ± 3.678) compared to AlCl_3 treated group. On the other hand, the percentage of abnormal sperm morphology was significantly increased in the AlCl_3 group (31.2 ± 5.3572 %) compared to the control and to AlCl_3 + vitamin A groups (16.50 ± 2.7019 % and 20.75 ± 7.0142 %) respectively (Table 2). The values of the control group in all sperm parameters were comparable to that of AlCl_3 + vitamin A were not significantly different. Vitamin A attenuated the effect of AlCl_3 toxicity on semen characteristics in this study. Different forms of the abnormal sperm head and tail were seen, as pin head, kink tail, coiled tail, bent tail, and two-tailed (Fig. 1).

Table 1. Mean value of mice body weight (g) of control and treated mice.

Experimental group	Weight before treatment (g)	Weight at the end of treatment (g)
Control	23.2 ± 0.491^a	25 ± 0.589^a
AlCl_3 (120 mg / kg)	24 ± 0.378^a	20.4 ± 0.477^b
AlCl_3 (120 mg/kg) + vitamin A (40mg/kg)	22 ± 0.799^a	23.7 ± 0.54^a

Values are presented as means \pm SD (n=7). The mean difference is significant at the $P \leq 0.05$ level. a, b, ($P \leq 0.05$).

Table 2. Mean value of sperm parameters of control and treated male mice.

Experimental groups	Sperm parameters			
	Sperm count 10^6 / ml	Normal sperm morphology %	Abnormal sperm morphology %	Motile sperm %
Control	$26.4^a \pm 2.6152$	$84.50^a \pm 2.7019$	$16.50^b \pm 2.7019$	$73.38^a \pm 3.3866$
AlCl_3 (120 mg / kg)	$22.8^b \pm 4.8682$	$69.25^c \pm 5.3572$	$31.2^a \pm 5.3572$	$39.73^b \pm 2.834$
AlCl_3 (120 mg/kg) + vitamin A (40mg/kg)	$26.2^a \pm 4.1214$	$76.75^b \pm 4.2661$	$20.75^b \pm 7.0142$	$68.75^a \pm 3.678$

Values are presented as means \pm SD (n=7). The mean difference is significant at the $P \leq 0.05$ level. a, b, c, ($P \leq 0.05$) compared with the control group.

Table 3. Testis's histopathology assessment for control and treated male mice.

Experimental group	Percentages of tubules			
	Detached	Oligospermia	Sloughed	vacuolized
Control	14.9 ± 3.9 ^b	15.6 ± 4.6 ^b	11.1 ± 5.4 ^b	10.0 ± 3.0 ^b
AlCl ₃ (120 mg / kg)	37.9 ± 8.1 ^a	54.5 ± 5.6 ^a	24.9 ± 13.7 ^a	39.0 ± 7.5 ^a
AlCl ₃ (120 mg/kg) + vitamin A (40mg/kg)	21.7 ± 7.2 ^b	19.3 ± 3.6 ^b	15.0 ± 5.7 ^b	10.9 ± 5.1 ^b

Values are presented as means ± SD. The mean difference is significant at the $P \leq 0.05$ level. a, b, ($P \leq 0.05$) compared with the control group.

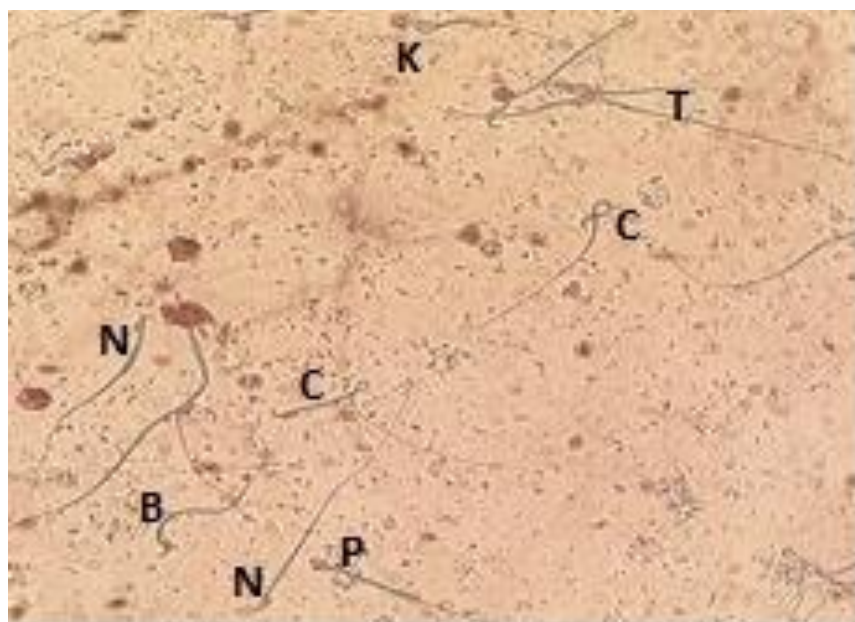


Fig 1. Sperm smear of AlCl₃ treated male mice showing head and tail abnormality: N (normal sperm), C (coiled tail), K (kink tail), T (two-tailed), B (bent tail). P (pinhead) (1% eosin stain, 40x).

Histological study

Histological examination of the control mice testes showed normal seminiferous tubules with various stages of spermatogenesis, well organized seminiferous tubules separated by narrow interstitial spaces. The interstitial spaces contain ledig cells and blood capillaries were normal. Also, testes of control mice revealed a low incidence of detached, sloughed, oligospermia, and vacuolized seminiferous tubules (Fig. 2 a and b).

Conversely, mice treated with 120 mg/kg AlCl₃ by i.p. injection showed many histological abnormalities in the structure of testes compared to the control. All testes' sections revealed the presence of edematous fluid in the tissues (interstitial edema), dilation and congestion of blood vessels (hyperemic blood vessels) and many seminiferous tubules exhibited active spermatogenesis. Moreover, the percentage of normal tubules was significantly decreased in mice treated with AlCl₃ comparing with the control group and to AlCl₃ + vitamin A treated group. Results showed a significant increase in the percentage of detached, vacuolized, oligospermia and sloughed seminiferous tubules (desquamate of the germinal cells into the tubular lumen) in AlCl₃ treated mice in comparison with the control group (Fig. 3 a, b, c, and d) and (Table 3). Additionally, varying degrees of

alterations of germ cell degenerative changes in the $AlCl_3$ treated group were seen; it was observed disorganization of germ cell layers, pyknosis of nuclei, multinucleated giant cells, and degeneration with clear coagulative necrotic debris in the tubular lumen (Fig. 3 c) compared to the control group and to $AlCl_3$ + vitamin A treated group. However, there was no significant difference between mice treated with $AlCl_3$ + vitamin A and the control group in detached, sloughed, vacuolized, and oligospermia seminiferous tubules (Fig. 2 and 4) and (Table 3). Also, treatment with vitamin A showed normal architecture of seminiferous tubules with few sloughing and oligospermia.

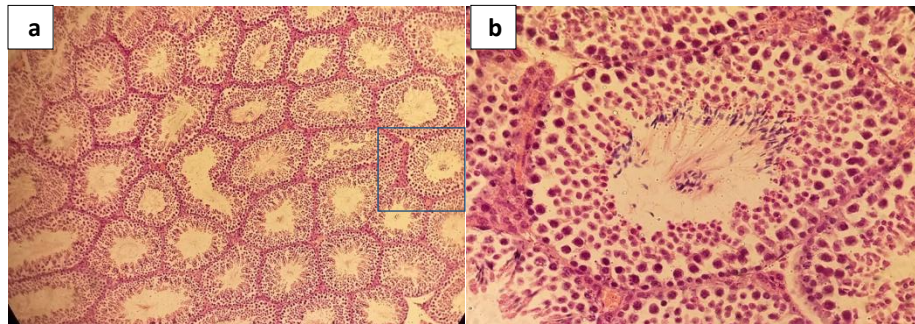


Fig. 2 Light microscopy of cross-sections of H&E-stained testis from control group showing normal architecture of seminiferous tubules (Magnifications 10X and 40X)

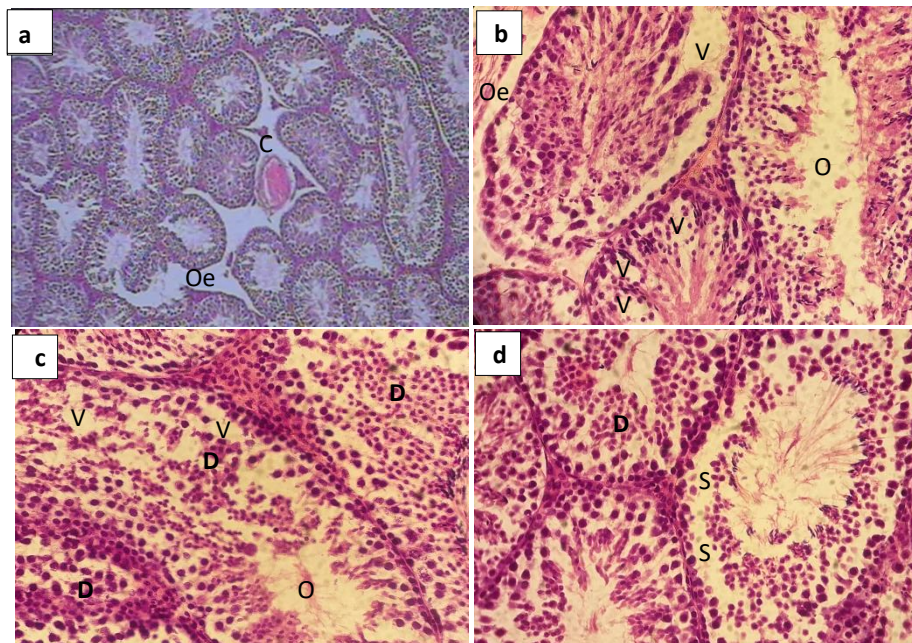


Fig. 3 Testes of $AlCl_3$ treated group (120mg/kg) stained with H&E, showing varying degrees of germ cell degenerative changes, a: moderate congestion of blood vessels and oedematous fluid interstitial space. b: vacuolization of seminiferous tubule and atrophy of the seminiferous epithelium. c: oligospermia and coagulative necrosis. d: sloughing of germinal epithelium. (Magnifications 10X and 40X). V: vacuole, S: sloughing, O: Oligospermia, Oe: oedema, D: detached, A: atrophy, C: congestion

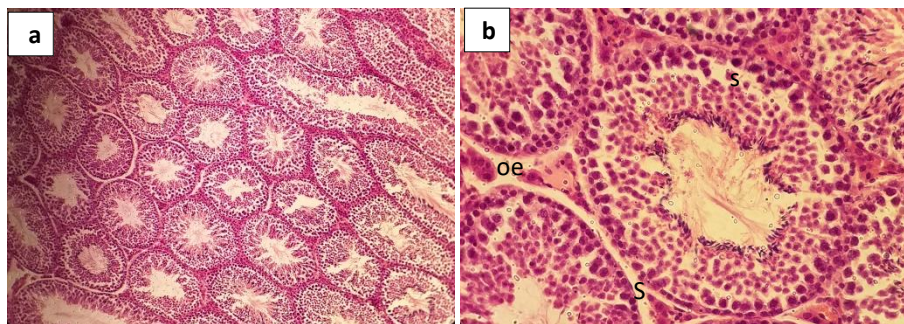


Fig. 4 Light microscopy of cross sections of (H&E staining) testes from AlCl_3 + vitamin A treated group showing normal architecture of seminiferous tubules with few sloughing and oligospermia (Magnifications 10X and 40X). V: vacuole, S: sloughing, O: Oligospermia

DISCUSSION

The fertility of males is sensitive to an assortment of toxic agents, such as lead, cadmium, Aluminium, mercury, and chemical materials arising from industrial processes. Accumulation of these materials inside the body can cause reproductive dysfunction [21]. Evaluation of sperm parameters is used as a marker for recognizing male reproductive toxicants [22]. Limited studies have used vitamin A as an antioxidant, therefore the purpose of the current study was to ascertain the possible protective role of vitamin A to ameliorate the reproductive toxicity of AlCl_3 in adult male albino mice.

The present study showed a significant decline in the bodyweight of the AlCl_3 treated group as compared to the control group. The significant reduction in body weight may due to a decrease in food intake, which leads to a decrease in the bodyweight of the AlCl_3 treated group. The results of the current study were compatible with other studies [12, 14, 16] who elucidated that Al compounds caused a considerable decline in the body weight of treated animals compared to the control.

Treated mice with AlCl_3 caused a significant decrease in sperm count and percentage of motility compared with the control group. However, a significant increase in abnormal sperm morphology was noticed in AlCl_3 treated group as compared with the control group. These results are consistent with previous studies [11, 12, 14, 15] who found similar effects following Al administration with different routes.

Attention has recently been focused on the role of oxidative stress in the pathophysiology of male infertility. Oxidative stress is linked with the overproduction of free radicals, such as reactive oxygen species (ROS) [17, 23]. Physiological levels of ROS are essential for natural sperm functioning and are involved in the development of sperm hyperactivation and capacitation [17, 24]. On the other hand, overproduction of ROS induced peroxidation of unsaturated fatty acids in the sperm membrane leading to loss of motility [17], damage to the acrosomal membranes, and DNA oxidation and thus loss of its fertilization capacity [25].

Yousef [26] stated that AlCl_3 was able to generate ROS in rabbit's testes causing oxidative damage. Excessive ROS production can be harmful to sperm and linked with a severe reduction in male fertility [27]. Another study showed that AlCl_3 administration results in the generation of oxidative stress and caused reproductive toxicity in male rats [28]. In addition, Khattab et al., [12] indicated that AlCl_3 decreases antioxidant enzymes and increases lipid peroxidation in testes, and caused fertility disorders.

ROS probably cause impairment of sperm function as a result of lipid peroxidation of the polyunsaturated fatty acids in the head and mid-piece, thus a change in morphology of sperm leads to a decrease in sperm viability and motility [23]. Also, the decrease in sperm motility may be attributed partially to the concurrent reduction in testosterone secretion after Al administration [14]. Moreover, oxidative stress in the testes diminishes normal

levels of ATP, induces damage of sperm DNA and interrupts microtubules structure in spermatozoa [29]. The decline of ATP may reduce sperm motility, DNA damage, and abnormal microtubule construction cause defects in sperm morphology in the head and tail [30].

Reduction in sperm count could be ascribed to the ability of $AlCl_3$ to induce oxidative stress and peroxidation of lipid, which cause damage to the macromolecules (protein, lipid, and nucleic acid) in the testes membrane leading to the interrupt of spermatogenesis [31]. Sperm plasma membrane and testicular tissue are extremely susceptible to lipid peroxidation by ROS, due to the abundance of highly unsaturated fatty acids [32] and modest antioxidant defenses. Furthermore, ROS and oxidative injure of macromolecules can contribute to male infertility [33].

Histopathologic examination of mice testes treated with $AlCl_3$ reveals structural alteration in the testes including, atrophy of the seminiferous epithelium, oligospermia, and coagulative necrosis and sloughing of germinal epithelium. These changes may be associated with the ability of $AlCl_3$ to induce lipid peroxidation [12] that harm membranes of the testes. The histological results of this study are consistent with other studies that previously reported similar histopathological alterations in testes treated with $AlCl_3$ [10, 11, 13]. Similar results were also obtained by Mayyas et al., [34] and Khattab et al., [12] who found that $AlCl_3$ treatment caused marked testicular damage of male mice as well as decreased sperm motility, viability, and testosterone level.

The administration of vitamin A following $AlCl_3$ demonstrated apparent improvement in sperm parameters and histology of testes. Treatment with vitamin A considerably increased sperm count and percentage of motility compared to the $AlCl_3$ treated group. Also, treatment with vitamin A decreased significantly the abnormal morphology as compared to the $AlCl_3$ treated group. Improvement in sperm motility that was observed in this study following treatment of mice with vitamin A may be attributed to the ability of vitamin A to reduce oxidative stress.

It has been reported that vitamin A is essential for normal mammalian spermatogenesis and fertility [35], as they found that vitamin A deficiency induces cessation of spermatogenesis and negatively affects the secretion of testosterone [35, 36]. Also, it was documented that supplying the rats with large doses of vitamin A resulted in an apparent reduction in lipid peroxidation of tissue homogenates [37]. The possible reason for the protective effects of vitamin A in ameliorating the reproductive toxicity of $AlCl_3$ might be due to its ability to react with oxygen-free radicals and combines and stabilizes peroxy radicals [38]. Co-treatment of vitamin A with $AlCl_3$ showed obvious alleviation in histopathological alterations, that caused by $AlCl_3$ in testes as compared with the $AlCl_3$ group.

Several studies have reported improvements in sperm quality with antioxidant treatment. Yousef et al. [39] has shown that administration of vitamin E to rabbits treated with $AlCl_3$ results in significant improvement in sperm quality. Similarly, Yousef et al. [14] showed that administration of vitamin C to rabbits treated with $AlCl_3$ resulted in considerable alleviation in sperm parameters. Likewise, Chinoy et al., [40] documented that concurrent administration of vitamin C with sodium fluoride and $AlCl_3$ resulted in amelioration of testicular damage due to the ability of vitamin C to induce cellular growth.

CONCLUSION

This study affords evidence for the protective role of vitamin A in ameliorating testicular toxicity caused by $AlCl_3$ as showed by a considerable increase in sperm parameters of $AlCl_3$ + vitamin A group and established histopathologically by the obvious improvement in testicular tissues.

Disclaimer

The article has not been previously presented or published, and is not part of a thesis project.

Conflict of Interest

There are no financial, personal, or professional conflicts of interest to declare.

REFERENCES

1. Tchounwou PB, Yedjou CG, Patlolla AK, and Sutton, DJ. Heavy Metals Toxicity and the Environment. NIH-PA. EXS. 2012; 101: 133-164. doi:10.1007/978-3-7643-8340-4_6.
2. Jorhem L, and Haegglund, G. Aluminium in food stuffs and diets in Sweden. Z. Lebensm. Unters. Forsch. 1992; 194: 38-42. doi: 10.1007/BF01191038
3. Miller RG, Kopfler FC, Kelty K C, Stober JA, and Ulmer NS. The occurrence of aluminum in drinking water. J. Am. Water Assoc. 1984; 76, 84–91. <https://doi.org/10.1002/j.1551-8833.1984.tb05267.x>
4. Lione A. Aluminium toxicity and the aluminium containing medication. J. Pharmacol. Therapy. 1985; 29: 255-285. doi: 10.1016/0163-7258(85)90032-4.
5. Müller M, Anke M, and Illing-Günther H. Aluminium in foodstuffs. Food Chem., 1998; 61, 419–428. [https://doi.org/10.1016/S0308-8146\(97\)00085-X](https://doi.org/10.1016/S0308-8146(97)00085-X)
6. Becaria A, Lahiri DK, mBondy SC, Hamadeh A, Taylor R, and Campbell A. Aluminium and copper in drinking water enhance inflammatory or oxidative events specifically in the brain. J. Neuroimmunol. 2006; 176(1): 16-23. doi: 10.1016/j.jneuroim.2006.03.025.
7. El Demerdash FM. Antioxidant effect of vitamin E and selenium on lipid peroxidation, enzyme activities and biochemical parameters in rats exposed to aluminum. J. Trace Elem. Med. Biol. 2004; 18: 113-121. doi:10.1016/j.jtemb.2004.04.001
8. Kadhum SA. Effects of Aluminum Chloride on the some Blood Parameters and Histological Spleen in White Male Rats. J. Univer. Babylon, Pure Appl. Sci. 2017; 25(5). 1886-1895.
9. Anacletus FC, and Onyegeme-Okerenta BM. Induction of haematological and lipid profile changes by aluminium induced toxicity and ameliorative effects of selected antioxidants on wistar rats. Health Sci. Res. 2016; 3(3): 30-34. <http://www.aascit.org/journal/hsr> ISSN: 2375-379X
10. Khattab IK. Histological and ultrastructural studies on the testis of rat after treatment with aluminium chloride. Aust. J. Basic Appl. Sci. 2007; 1: 63-72. ISSN 1991-8178
11. Ige SF, and Akhigbe RE. The role of Allium cepa on aluminium induced reproductive dysfunction in experimental male rat models. 2012; 5(2): 200-205 <http://www.jhrsonline.org> doi: 10.4103/0974-1208.101022.
12. Khattab HA, Abdallah A, and Kamel GM. Grape seed extract alleviate reproductive toxicity caused by aluminium chloride in male rats. J. Am. Sci. 2010; 6(12): 1200-1209. <http://www.americanscience.org>.
13. Nuhair RS. Effects of aluminium chloride on some hormones level and reproductive organs of male rats. J. Thi.-Qar Sci. 2015; 5(2) ISSN 1991-8690.
14. Yousef MI, El-Morsy AMA, and Hassan MS. Aluminium induced deterioration in reproductive performance and seminal plasma biochemistry of male rabbits: protective role of ascorbic acid. Toxicol. 2005; 215: 97-107. doi: 10.1016/j.tox.2005.06.025

15. Yousef MI, Kamel KL, El-Guendi MI, and El-Demerdash FM. An in vitro study on reproductive toxicity of aluminium chloride on rabbit sperm: The protective role of some antioxidants. *Toxicol.* 2007; 239: 213-223. doi:[10.1016/j.tox.2007.07.011](https://doi.org/10.1016/j.tox.2007.07.011)
16. Kumar P, and Singh P. Protective role of Tribulusterrestris on aluminium chloride induced reproductive toxicity in the male laboratory mouse. 2015; 6(6): 2395-2405. doi:[10.13040/IJPSR.0975-8232.6\(6\).2395-05](https://doi.org/10.13040/IJPSR.0975-8232.6(6).2395-05)
17. Agarwal A, Virk G, Ong C, and du Plessis SS. Effect of oxidative stress on male reproduction. *World J. Mens. Health.* 2014; 32(1): 1-17 <http://dx.doi.org/10.5534/wjmh.2014.32.1.1>
18. Ficsor G, and Ginsberg LC. The effect of hydroxyurea and mitomycin C on sperm motility in mice. *Mutation Research.* 1980; 70: 383-387. doi: [10.1016/0027-5107\(80\)90028-7](https://doi.org/10.1016/0027-5107(80)90028-7)
19. Mori K, Kaido M, Fujishiro K, Inoue N, Koide O, Hori H, and Tanaka H. Dose dependent effects of inhaled ethylene oxide on spermatogenesis in rats. *Br. J. Ind. Med.* 1991; 48: 270-274. doi: [10.1136/oem.48.4.270](https://doi.org/10.1136/oem.48.4.270)
20. Talebi AR, Khorsandi L, and Moridian M. The effect of zinc oxide nanoparticles on mouse spermatogenesis. *J. Assist. Reprod. Genet.* 2013; 30: 1203-1209. DOI [10.1007/s10815-013-0078-y](https://doi.org/10.1007/s10815-013-0078-y)
21. Wijesekara GU, Fernando DM, and Wijerathna S. Environmental and occupational exposures as a cause of maleinfertility. *Ceylon Med. J.* 2015; 60: 52-56. doi: [10.4038/cmj.v60i2.7090](https://doi.org/10.4038/cmj.v60i2.7090).
22. Working PK. Male Reproductive Toxicology: Comparison of the Human to Animal Models. *Environmental Health Perspectives.* 1988; 77:37-44. doi: [10.1289/ehp.887737](https://doi.org/10.1289/ehp.887737)
23. Nowicka-Bauer K, and Nixon B. Molecular changes induced by oxidative stress that impair human sperm motility. *Antioxidants.* 2020; 9: 134. Doi: [10.3390/antiox9020134](https://doi.org/10.3390/antiox9020134).
24. Aitken RJ. Free radicals, lipid peroxidation and sperm function. *Rep. Fer. Develop.* 1995; 7 (4):659-668. doi: [10.1071/rd9950659](https://doi.org/10.1071/rd9950659)
25. Gil-Guzman E, Ollero M, Lopez M, Sharma R, Alvarez J, Thomas A. Differential production of reactive oxygen species by subsets of human spermatozoa at different stages of maturation. *Human Reprod.* 2001; 16(9): 1922-1930. <https://doi.org/10.1093/humrep/16.9.1922>
26. Yousef MI. Aluminium induced changes in hemato-biochemical parameters, lipid peroxidation and enzyme activities of male rabbits: protective role of ascorbic acid. *Toxicol.* 2004; 199: 47-57. doi:[10.1016/j.tox.2004.02.014](https://doi.org/10.1016/j.tox.2004.02.014).
27. Turner TT, and Lysiak JL. Oxidative stress: A common factor in testicular dysfunctions. *J. Androl.* 2008; 29: 488-498. <https://doi.org/10.2164/jandrol.108.005132>.
28. Yousef MI, and Salama AF. Propolis protection from reproductive toxicity caused by aluminium chloride in male rats. *Food Chem. Toxicol.* 2009; 47: 1168-1175. doi:[10.1016/j.fct.2009.02.006](https://doi.org/10.1016/j.fct.2009.02.006)
29. Creasy DM. Pathogenesis of Male Reproductive Toxicity. *Toxicol. Pathol.* 2001; 29(1): 64 –76. doi: [10.1080/019262301301418865](https://doi.org/10.1080/019262301301418865).
30. Trivedi P, Kushwaha S, Tripathi D, and Jena G. Evaluation of male germ cell toxicity in rats: Correlation between sperm head morphology and sperm comet assay. *Mutat. Res-Gen. Toxicol. En.* 2010; 703: 115–121. doi: [10.1016/j.mrgentox.2010.08.005](https://doi.org/10.1016/j.mrgentox.2010.08.005).
31. Latchoumycandane C, Chitra KC, and Mathur PP. The effect of methoxychlor on the epididymal antioxidant system of adult rats. *Reprod.Toxicol.* 2002; 16: 161-172. doi: [10.1016/s0890-6238\(02\)00002-3](https://doi.org/10.1016/s0890-6238(02)00002-3)

32. Kalaiselvi A, Suganthy OM, Govindassamy P, Vasantharaja D, Gowri B, and Ramalingam V. Influence of aluminium chloride on antioxidant system in the testis and epididymis of rats. *Iranian J. Toxicol.* 2014; 8(24). URL: <http://ijt.arakmu.ac.ir/article-1-292-en.html>
33. Atessahin A, Yilmaz S, Karahan I, Pirincei I, and Tasdemir B. The effects of vitamin E and selenium on cypermethrin-induced oxidative stress in rats. *Turk. J. Vet. Anim. Sci.* 2005; 29: 385-391. ISSN: 1300-0128 / 1303-6181
34. Mayyas I, Elbetieha A, Khamas W, and Khamas A. Evaluation of reproductive and fertility toxic potentials of aluminium chloride on adult male mice. *J. Anim. and Vetr. Adv.* 2005; 4(2): 224-233. <https://www.researchgate.net/publication/26591008>
35. Hogarth CA, and Griswold MD. The key role of vitamin A in spermatogenesis. *J. Clin. Invest.* 2010; 120: 956-962. doi: 10.1172/JCI41303
36. Livera G, Rouiller-Fabre V, Pairault C, Levacher C, and Habert R. Regulation and perturbation of testicular functions by vitamin A. *Reprod.* 2002; 124: 173-180. DOI: [10.1530/rep.0.1240173](https://doi.org/10.1530/rep.0.1240173)
37. Kartha VN, and Krishnamurthy S. Antioxidant function of vitamin A. *Int. J. Vitam. Nutr. Res.* 1977; 47(4): 394-401.
38. Palace VP, Khaper N, Qin Q, and Singal PK. Antioxidant potentials of vitamin A and carotenoids and their relevance to heart disease. *Free Radic. Biol. Med.* 1999; 26 (5-6): 746-761. doi: 10.1016/s0891-5849(98)00266-4.
39. Yousef MI, Abdallah BK, and Kamel KI. Effect of ascorbic acid and vitamin E supplementation on semen quality and biochemical parameters of male rabbits. *Anim. Reprod. Sci.* 2003; 76(1-2): 99-111. DOI: [10.1016/S0378-4320\(02\)00226-9](https://doi.org/10.1016/S0378-4320(02)00226-9)
40. Chinoy NJ, Sorathia HP, and Jhala DD. Fluoride+Aluminium induced toxicity in mice testis with giant cells and its reversal by vitamin C. *Fluoride.* 2005; 38(2): 109-114.