



The Pattern of Occurrence, Risk Factor and Biomarkers Associated with Leiomyoma in Calabar, Nigeria

Mfoniso I. Udonkang^{1*}, Theophilus I. Ugben², Agala E. Egbe¹, Anietie M. Archibong³, Okiemute B. Oborairuvwe¹, Divine I. Ulom¹ and Osuogenduko A. Omoni¹

¹Department of Histopathology and Cytology, Faculty of Medical Laboratory Science, University of Calabar, Calabar, Nigeria; ²Department of Pathology, Faculty of Basic Clinical Sciences, University of Calabar, Calabar, Nigeria, and ³Histopathology Laboratory, University of Uyo Teaching Hospital, Uyo, Nigeria.

*Corresponding author: Dr Mfoniso I. Udonkang. Email address: mfonisotoday10@yahoo.com

Summary

BACKGROUND

Uterine fibroid is the commonest gynecologic tumour in women of reproductive age but there is a disparity in research to understand the aetiology and risk factors of the disease in Calabar. This study analyzed the clinical and histopathological characteristics of subjects and used an artificial neural network (ANN) to predict the risk factors/biomarkers of leiomyoma.

MATERIALS AND METHODS

This retrospective cross-sectional study involved women with complete data who were diagnosed with leiomyoma. Data from 104 subjects were retrieved and analyzed from January 2020 to May 2021. Ten uterine tissue blocks were retrieved and stained with haematoxylin and eosin (H&E), Weighert-van Gieson and immunohistochemical methods for progesterone receptor (PR), Ki-67 and p53. Descriptive statistics, ANOVA, and ANN model of Statistical Package for Social Sciences (SPSS) were used for analysis.

RESULTS

The 104 subjects with leiomyoma had 67(64.4%) leiomyoma uteri and 37(35.6%) degenerative changes. The nature of the sample was related to diagnosis ($p=0.036$). The age range was between 24-57 years. More cases occurred between 30-39 years with 58(55.8%) cases but were not statistically significant with age ($p=0.254$). The nature of the sample was significant with age ($p=0.008$). The ANN model predicted age (100%), p53 (78.2%), Ki-67(95.9%) and collagen(59.1%) as the important risk factors/biomarkers associated with leiomyoma.

CONCLUSION

Leiomyoma mostly affects women of reproductive age and is associated with loss of p53, increase Ki-67 and increase collagen deposition. The routine application of these biomarkers may be useful in understanding the predisposing factors of leiomyoma for effective diagnosis, management and prognosis.

Keywords: Leiomyoma, biomarkers, immunohistochemistry, artificial neural network

Afr. J. Health Sci. 2022 35(5): 628-638]

Introduction

Leiomyoma is the most common benign neoplasm affecting about 235 million women or 6.6% of the women population global [1, 2].

Although benign; leiomyoma has caused significant morbidity, infertility and pregnancy complications among females worldwide. Its presentation and complications may lead to life-



threatening outcomes such as giant tumours, excessive haemorrhage, and death [3]. In Nigeria, leiomyoma is a common gynaecological tumour in all parts of the country [4-9]. In Calabar, there has been an unprecedented increase in the occurrence of leiomyoma. A review of indications for hysterectomy cases from 1993-2002 at the University of Calabar Teaching Hospital reported 65 cases of leiomyoma, which affected mostly 50.8% of women between 41-50 years [8]. Another review from the same facility from 1996-2005 reported 246 leiomyoma cases with 104 (42.3%) of women within 31-40 years being mostly affected [9].

Though leiomyoma is very common, its aetiology, pathogenesis and pathophysiology remain unclear [10]. Some of the risk factors for the development of leiomyoma are environmental and genetics; which may include hormones, age, race and family history [11, 12]. Leiomyoma is most times characterized by increased collagen deposition around the smooth muscles [13]. According to available literary records, the growth of leiomyoma depends mostly on steroid hormones, particularly progesterone, which is believed to be the dominant factor [13, 14, 15]. Other markers such as Ki-67 and p53 proteins are also important. The Ki-67 antigen is a marker of proliferation and is useful in predicting tumour aggression, recurrence and prognosis. The p53 protein plays a crucial role as a tumour suppressor and has been widely applied in the diagnosis and prognosis of uterine smooth muscle tumours [16, 17]. The combination of Ki-67, PR and p53 for differential diagnosis of uterine tumours has been done in the previous study [18]. However, due to the current burden of leiomyoma in the study area; there is an urgent need to investigate the associated risk factors and biomarkers of the disease as there has been a paucity of data to date in this regard. Thus, this study was to analyze the current occurrence of leiomyoma; evaluate the collagen fibre

changes and immunohistochemical expressions of Ki-67, p53 and progesterone receptor (PR); and predict their associations with leiomyoma.

Materials and methods

Study design and population

This study was a retrospective cross-sectional study. The study population consisted of 104 women diagnosed with uterine tumours at the University of Calabar Teaching Hospital, Calabar, Cross River State, Nigeria from January 2020 to May 2021. The University of Calabar Teaching Hospital, Calabar is a hospital-based cancer registry and a tertiary health/referral facility where most of the uterine fibroid cases in Calabar and other parts of Cross River state are diagnosed.

Sample size determination was based on the sample size formula of difference in two proportions of [19] given as $Z^2 P_1(1-P_1) + P_2(1-P_2) / d^2$ where Proportions, $P_1=80\%$, $P_2=90\%$, Z is confidence interval at 95% =1.96, and d is relative precision =10%. This gave a minimum sample size of 96 but data from 104 eligible subjects who were diagnosed within the study period were used.

Sampling criteria involved the inclusion of all women who had complete clinical data and were diagnosed with leiomyoma within the period of study. Women having either incomplete/missing data or being diagnosed with other uterine diseases were excluded. Each subject's data was retrieved from the Histopathology Laboratory Register similar to data entered in the standard Histopathology laboratory request form.

Procedures

Clinical and histopathological data included age, nature of the tissue, and histopathological diagnosis. The diagnosis was done from H&E stained slides. There was no record of any histochemical and immunohistochemical staining techniques. Also,



10 archived formalin-fixed-paraffin wax-embedded leiomyoma tissue blocks were randomly retrieved, sectioned with a rotary microtome and stained with H&E and Weighert-van Gieson for smooth muscle and collagen fibre [20] and immunohistochemical methods for PR, Ki-67 and p53. The collagen staining intensity was graded as 1+(normal/low), 2+(moderate) and 3+(high). Ethical approval was obtained from the Institution Ethics Committee with protocol number UCTH/HREC/33/527.

Antibodies used for immunohistochemistry were PR(BSB-2, Bio-SB), Ki-67(EP5, Bio-SB), and p53(DO7, Bio-SB). Immunostaining was all based on the Bio-SB manufacturer's instruction and procedure [21]. Brown staining of nuclei showed positive expressions of PR, p53 and Ki-67 protein. Ki-67 expression was graded as positive if >10 smooth muscle cells were counted [18].

Statistical analysis

Descriptive statistics and ANOVA were used to analyze the data and establish relationships. SPSS version 20 software was used for all analyses. All results were statistically

significant at ($p \leq 0.05$). Multiple-level perceptron models (MLP) of artificial neural network (ANN) were used for predictions of risk/predisposing factors using 60, 20, and 20 models for training, testing, and holdout respectively.

Results

Preliminary data analysis

The distribution of histological types of tumours is shown in Table 1. Out of 104 leiomyomas recorded 67(64.4%) were leiomyoma uteri and 37 (35.6%) were leiomyoma uteri with degenerative changes. Among cases with degenerative changes were 26(25.0%) as degenerative changes (not specified), 4(3.8%) with cystic degeneration and 3(2.9%) with calcifications. The nature of the tissue sample recorded myomectomy as the highest with 92 (88.5%) and hysterectomy with 12(11.5%). The myomectomy and hysterectomy tissues diagnosed with leiomyoma uteri were the highest with 56(53.9) and 11(10.5) cases respectively. The nature of the tissue was related to the histological diagnosis of leiomyoma ($F=4.498$, $p=0.036$).

Table 1:
Summary of Clinicopathological Data of Diagnosis and Nature of Tissue and their Association

Diagnosis	n (%)		n (%)	Nature of tissue	n (%)
Leiomyoma uteri	67 (64.4)	-	-	Myomectomy	92(88.5)
L. uteri+deg.	37 (35.6)	Degeneration (unspecified)	26(25.0)	Hysterectomy	12(11.5)
		Cystic	4 (3.8)		
		Calcification	3 (2.9)		
		Hyaline	1 (1.0)		
		Red	1(1.0)		
		Cystic+hyaline	2 (1.9)		
Total	104 (100)	Total	37(35.6)	Total	104 (100)
	Total (%)	Myomectomy n(%)	Hysterectomy n(%)	Statistics	p-value
Leiomyoma uteri	67(64.4)	56(53.9)	11(10.5)	F=4.498	0.036
L. uteri+ Deg.	37(35.6)	36(34.6)	1 (1.0)		
Total	104 (100)	92(88.5)	12(11.5)		

Key: L. uteri+deg.= leiomyoma with degenerative changes



Table 2 showed that the age group of the subjects with the highest cases was 30-39 years with 58(55.8%) cases. Next was 40-49 years with 28(26.9%) cases. The least number was in 50-59 years with 4(3.8%) cases. The age range was between 24-57 years. The mean age at diagnosis was 36.3 ± 6.6 years. Association of age with a diagnosis of leiomyoma showed that 30-39 years had more leiomyoma uteri with 34(32.7%) and degenerative changes with 24(23.1%) cases but was not statistically significant ($F=1.378$, $p=0.254$). Myomectomy was performed more in 30-39 years with 54(57.9%) while hysterectomy was common in 40-49 years with 8(7.7%) cases.

There was statistical significance between age and the nature of the tissue sample ($F=4.157$, $p=0.008$).

Histological and immune-histochemical characteristics of tissue blocks

The histological and immune-histochemical characteristics of selected leiomyoma tissue blocks are shown in Table 3. Leiomyoma uteri were 5(50%), leiomyoma uteri with degenerative changes were 4(40%), and no pathology was 1(10%).

Table 2:
Association between Age with Diagnosis and Nature of Tissue

Age	L. uteri n(%)	L. uteri+Deg. n(%)	Total n(%)	Myomectomy n(%)	Hysterectomy n(%)
20-29	12 (11.5)	2(1.9)	14(13.5)	14(13.5)	0(0)
30-39	34(32.7)	24(23.1)	58(55.8)	54(57.9)	4(3.8)
40-49	19(18.3)	9(8.7)	28(26.9)	20(19.2)	8(7.7)
50-59	2(1.9)	2(1.9)	4(3.8)	4(3.8)	0(0)
Total	67(64.4)	37 (35.6)	104(100)	92(88.5)	12(11.5)
Statistics	$F=1.378$	$p=0.254$		$F=4.157$	$p=0.008$
Min: 24	Max:57				

Key: L. uteri=leiomyoma uteri, L. uteri+deg.= leiomyoma with degenerative changes, Min=minimum age, Max=maximum age

Table 3:
Mean Age at Diagnosis and Staining Characteristics of Tissue Blocks

Parameter	Positive n(%)	Negative n(%)
p53	3(30)	7(70)
Ki-67	7(70)	3(30)
PR	8(80)	2(20)
Diagnosis		
Lu	5(50)	-
Lu+D	4(40)	-
NO	-	1(10)
Collagen intensity	n(%)	
1+	3(30)	-
2+	3(30)	-
3+	4(40)	-
Mean Age (years)	34.5 ± 5.6	-

Key: Lu= leiomyoma uteri, Lu+D= leiomyoma with degenerative changes, NO=no pathology



The Mean age was 34.5±5.6 years. Collagen staining intensity was graded as 3+ in 5/10, 2+ in 2/10 and 1+ in 3/10 cases. Positive expression of immunohistochemical markers was 3/10(30%) for p53, 7/10(70%) for Ki-67, and 8/10(80%) for PR.

Multilayer perceptron network prediction

The results of the multilayer perceptron network are presented in Table 4. The 60-20-20 model had an input layer (10 units), hidden layer (6 units) and output layer (3 units) with hyperbolic tangent and softmax as activation functions for the hidden and output layers respectively. The cross entropy error for training was 0.120 and testing was 0.040 which signified a good prediction of the model. The % incorrect prediction was good at 0% each for the training and testing layers. The ROC curve analysis gave perfect accuracy of prediction as 1.000 for the leiomyoma diagnosis. Normalized importance of the predictors or risk factor/biomarkers of

leiomyoma in order of importance were age (100%), p53(78.2%), Ki-67(95.9%), collagen(59.1%) and least was PR(36.3%). Figure 1 is the multilayer perceptron network diagram showing the interconnections between age and biomarkers with leiomyoma.

Photomicrographs

Figure 2 shows the photomicrographs. Plate 1 is the photomicrograph of leiomyoma uteri with a longitudinal bundle of smooth muscles stained with haematoxylin and eosin. Plate 2 is Weighert-van Gieson-stained collagen fibres in leiomyoma with cystic degeneration. Plate 3 is nodular leiomyoma stained with Ki-67. Plate 4 showed leiomyoma uteri smooth muscle cells with positive expression of the progesterone receptor. Plate 5 is leiomyoma with positive expression of p53 protein.

Discussion

The occurrence of leiomyoma among females in Calabar is increasing.

Table 4:
Multiple-level perceptron results

MLP	SUMMARY		Partition	
Layer	Description	Values	Layer	No of units
Training	CE Error	0.120	Input	10
	% Incorrect prediction		Hidden	6
	Training time	0%	Output	3
Testing	CE Error	0.040		
	% Incorrect prediction			
		0%		

Parameter	Independent variable importance		ROC CURVE	
	Relative importance	Normalized importance (%)	Diagnosis	Area
Age	0.295	100	Lu	1.000
P53	0.231	78.2	Lu+D	1.000
Ki-67	0.195	65.9	NO	1.000
PR	0.104	36.3		
Collagen	0.174	59.1		

Key: CE Error- Cross entropy error; ROC- Receiver's Operator Characteristics, Lu= leiomyoma uteri, Lu+D= leiomyoma with degenerative changes, NO=no pathology

The black race has been implicated as a major risk factor but there are concerns that genetic changes, lifestyle changes and environmental influences may be other predisposing factors. However, the aetiology of the disease is still a major problem to unravel. Thus, the multilayer perceptron network was employed to give a close prediction of the

possible risk factors associated with leiomyoma. This study recorded increased cases of leiomyoma within a short period compared to previous studies of ten years duration [8]. Accessibility to modern diagnostic facilities may contribute to increasing the number of cases recorded.

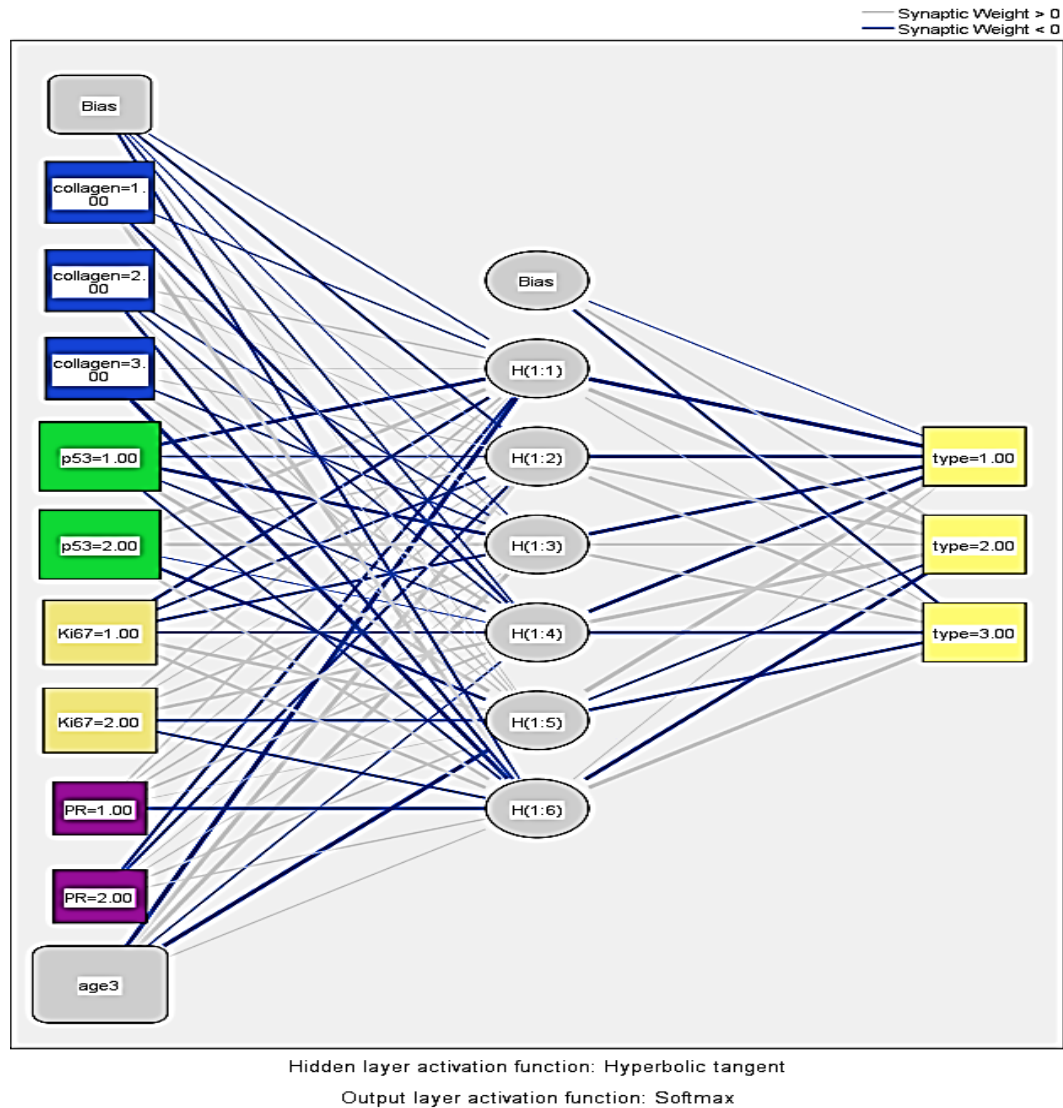


Figure 1:
Multilayer Perceptron Network Diagram of Interconnections between Age and Biomarkers with Leiomyoma

Key: Collagen 1.00=1+, 2.00=2+, 3.00=3+ staining intensities; p53 1.00=p53 negative, p53 2.00=p53 positive, Ki67 1.00=Ki67 negative, Ki67 2.00= Ki67 positive, PR 1.00=PR negative, PR 2.00=PR positive; type 1.00=leiomyoma uteri, type 2.00=leiomyoma uteri, with degeneration, type 3.00= no leiomyoma uteri.

The majority of the cases were leiomyoma uteri which have the potential to proliferate and increase in size compared to a small proportion that had already undergone degeneration. A study by another researcher has shown that degeneration is a sign of inactivity and is an indicator of a good prognosis [22].

A high number of myomectomy was sent for histological diagnosis in this study. This is comparable to a similarly high number of myomectomies in previous work [23]. This finding raises fertility issues regarding leiomyoma as most women would prefer to undergo myomectomy to preserve their uterus [10, 23]. The few cases of hysterectomy in the study showed that it is only at unbearable states that hysterectomy is preferred. The nature of the tissue sent for diagnosis was associated with the disease status as the majority of the myomectomy and hysterectomy were from leiomyoma uteri.

This shows that most of the leiomyoma uteri may have been problematic causing significant morbidity to the affected patients. This also confirms that the affected persons may have undergone significant trauma, increase risk of mortality and reduction in quality of life after the surgical interventions [24, 25].

Another major finding in the study was that leiomyoma affected mostly women in their reproductive age. Women between 24-57 years were affected, peaking at 30-39 years. Interestingly, the multilayer perceptron model used in this study further put age as the major risk factor for leiomyoma. This emphasizes the influence of hormones on the physiology of the uterus. Reproductive hormones are known to cause DNA changes that cause increased replication of cells of the uterus. Other studies have also confirmed the predominance of leiomyoma in a similar age range [6, 9, 23, 24].

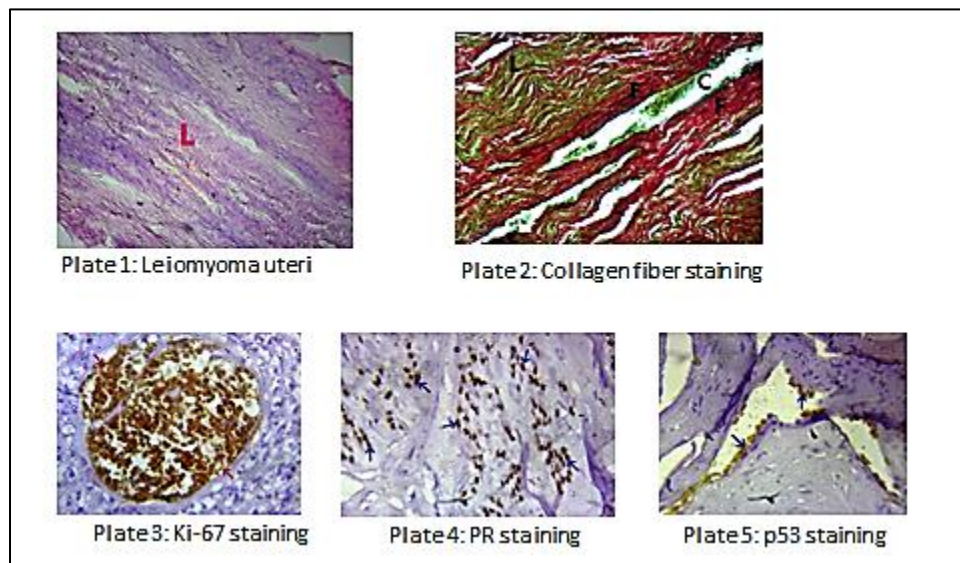


Figure 2:
Photomicrographs of Histological and Immunohistochemical Staining of Leiomyoma

Key: Plate 1: Leiomyoma uteri. There is a prominent longitudinal band (L) of smooth muscle fibres (H&E x400 magnification). Plate 2: Collagen fibre staining. Thick red collagen fibres (F) surround the cystic cavity (C) and longitudinal (L) smooth muscle fibres (Weigert-van Gieson x400 magnification). Plate 3-5: Ki-67, Progesterone receptor, and p53 stained slides respectively. The smooth muscle cells show brown-stained immunopositivity (IHC x400 magnification).



Age was also associated with the nature of tissue sent for histological diagnosis. Younger women preferred myomectomy while most of the hysterectomy samples were from older women. This shows that the women agreed to these surgical interventions taking into account the attendant effects on their reproductive health being that childbearing in Africa is a priority for most women [9, 23].

The multilayer perceptron model also showed that there was an important relationship between p53 protein expression and leiomyoma. p53 is a tumour suppressor and normal cells express this protein, which is important to induce apoptosis and prevent the initiation of tumour formation [16, 17]. In this study, only the normal tissue and degeneration changes expressed p53. All the leiomyoma uteri tissues showed loss of p53. Thus, expression of p53 may show a good prognosis as its presence indicates that the cells are in an active state of tumour suppression [16, 17].

Another prognostic marker associated with leiomyoma was the Ki-67 protein. This protein indicates the level of proliferation of leiomyoma and may be beneficial in discriminating cases that may have the potential to reoccur after surgical intervention, form multiple tumour sites, or may have the potential to progress to malignant leiomyosarcoma. Similar work has shown that an increased Ki-67 index is a marker of poor prognosis and aggressiveness in smooth muscle tumours [18]. Collagen changes were as well associated with leiomyoma in the study. Collagen fibres have been shown to increase in concentration due to increased synthesis in previous studies on breast tumours [26, 27]. It is believed that increased collagen deposition is an initial protective mechanism that may later become deleterious to the tissue. This also correlates with the findings of similar studies where collagen concentration was reportedly higher in leiomyoma compared to

normal myometrium [28, 29]. Similarly, another research concluded that leiomyoma has increased deposition of collagen and may play a role in the proliferation of uterine leiomyoma [30].

There was high PR expression among the tissues stained in this study. This correlates with the findings from a previous study that reported progesterone receptor expression in all cases of leiomyoma [25]. However; progesterone was the least important biomarker that was associated with leiomyoma in the multilayer perceptron model. This discovery has shown that although progesterone was vital to uterine proliferation and growth during reproductive age as stated in works [13, 14, 15]; it may not be the sole driver of tumour formation. This calls for further research on the role of female reproductive hormones on uterine tumour formation in African women. This may be able to unravel why every woman has a surge in progesterone but only some develop leiomyoma. This study suggests that other predisposing factors may be more influential in the development of leiomyoma other than progesterone. There are also serious concerns about environmental influences including diets as possible predisposing factors that need to be studied.

Study strengths and limitations

The strength of this study is drawn based on being the first to stain for biomarkers as well as the first to use the ANN model to give a strong prediction of the possible risk/predisposing factors of leiomyoma greatly affecting women in the study area. The limitation of this study was the small number of tissues stained for collagen and immunohistochemical staining as this was intended to be a pilot study.

Conclusion

This study has shown that leiomyoma is increasing and affects mostly women of reproductive age with a substantial number undergoing various forms of degeneration. Age is

a high-risk factor for its development. But proteins expressions like p53, Ki-67 and collagen are other possible predisposing factors to leiomyoma. Expression of PR was not related to leiomyoma development. The detection of these proteins may be valuable and can be used as adjunct biomarkers for differential diagnosis and treatment of this problematic tumour for better prognosis and management of the affected women. However, further studies on the role of diet and possible genetic and epigenetic changes may proffer additional explanations for the increase in the occurrence of leiomyoma in Calabar.

Acknowledgement

The authors are grateful to Dr Naomi Ernest for her coordination and technical assistance during the study.

Author contributions

Conception and design: Mfoniso I. Udonkang, Okiemute B. Oborairuvwe, Experimental protocol: Okiemute B. Oborairuvwe, Divine I. Ulom, Osuogenduko A. Omoni, Theophilus I. Ugbem, Anietie M. Archibong. Data collection, analysis and interpretation: Okiemute B. Oborairuvwe, Mfoniso I. Udonkang, Agala E. Egbe, Manuscript writing: All authors, Final approval of manuscript: All authors.

Source of funding

This research did not receive any external funding/support

Conflict of interest

The authors declare that there is no conflict of interest whatsoever.

References

1. **WHO** classification of tumours of female reproductive organs. In: Kurman R. Ed., World Health Organization Classification of Tumours. 6th ed. *WHO Press*; Geneva, Switzerland, 2014.

2. **Stewart EA, Cookson CL, Gandolfo RA, et al.** Epidemiology of uterine fibroids: A systematic review. *Biological Journal of Obstetrics and Gynecology*. 2017; 124: 1501-1512.
3. **World Health Organisation (WHO).** International Classification of Diseases, 11th Revision (ICD-11) Geneva. 2018.
4. **Ezeama C, Ikechebelu J, Obiechina N, et al.** Clinical Presentation of Uterine Fibroids in Nnewi, Nigeria: A 5-year Review. *Annual Medicine Health Science Research*. 2012; 2(2):114-118.
5. **Obuna JA, Umeora OU, Ejikeme B, et al.** Uterine Fibroids in a tertiary Health Centre South East Nigeria. *Nigeria Journal of Medicine*. 2008; 17(4): 447-451.
6. **Okogbo FO, Ezechi OC, Loto MO, et al:** Uterine Leiomyomata in South Western Nigeria: A clinical study of presentations and management outcome. *African Health Science*. 2011; (2):271-278.
7. **Bukar M, Audu BM, Melah GS.** Myomectomy at the Federal Medical, Gombe. *Nigeria Journal of Medicine*. 2009; 18(1):94-97.
8. **Udoma EJ, Ekanem EA, Udo AE, et al.** Hysterectomy among nulliparous women in Calabar-indications, complications, social implications and management outcome: *Global Journal of Medical Science*. 2003; 2(2):135-139.
9. **Ayodele J, Patience O, Martins, A, et al.** A review of Leiomyoma in Calabar, Nigeria. *Scholars Journal of Applied Medical Sciences*. 2016; 4(4A):1106-1108.
10. **Al Hendy A, Myers ER, Stewart E.** Uterine fibroids: Burden and unmet medical need. *Seminars Reproduction Medicine*. 2017; 35:473-480.
11. **Radin R, Julie R, Lynn R, et al.** Dietary glycemic index and load in relation to risk of uterine leiomyomata in the Black Women's Health Study. *American Journal of Clinical Nutrition*. 2010; 91(5):1281-1288.



12. **Davis BJ, Risinger JI, Chandramouli GV, et al.** Gene expression in uterine leiomyoma from tumors likely to be growing (from black women over 35) and tumors likely to be non-growing (from white women over 35). *PLoS One*. 2013; 8:63909.
13. **Islam MS, Ciavattini A, Petraglia F, et al.** Extracellular matrix in uterine leiomyoma pathogenesis: a potential target for future therapeutics, *Human Reproduction Update*. 2018; 24(1):59–85.
14. **Ishikawa H, Ishi K, Serna V, et al:** Progesterone is essential for maintenance and growth of uterine leiomyoma. *Endocrinology*. 2010; 151:2433-2442.
15. **Chill HH, Safrai M, Reuveni SA, et al.** The rising phoenix-progesterone as the main target of medical therapy for leiomyoma. *Biomedical Research Institute*. 2017; 470:51-64.
16. **Liang Y, Zhang X, Chen X, et al.** Diagnostic value of progesterone receptor, p16, p53 and PHH3 expression in uterine atypical leiomyoma. *International Journal of Clinical and Experimental Pathology*. 2015; 8:7196-7202.
17. **Mitta K, Demopoulos RI.** MIB1 (Ki 67), p53, estrogen receptor and progesterone receptor expression in uterine smooth muscle tumours. *Human Pathology*. 2016; 32:984-987.
18. **Petrovic D, Babic D, Forko JI, et al.** Expression of Ki-67, P53 and Progesterone Receptors in Uterine Smooth Muscle Tumors. *Diagnostic Value, Cell Anthropology*. 2008; 34:93-97.
19. **Goyal, M.** *Research methodology for health professionals including proposal, thesis and article writing*, 1st ed.: New Delhi: Jaypee Brothers Medical Publishers: 2013; 45-86.
20. **Bancroft JD, Gamble M.** *Theory and Practice of Histological Techniques*. 6th ed. London: Churchill Livingstone. 2008; 121-173.
21. **Ghirardi G, Delfino I, Kaplan E, et al.** Importance of p16 and Ki67. Immunohistochemical Expression and in a Typical Immature Metaplasia (AIM). *Journal of Clinical Review and Case Report*. 2018; 3(3): 1-4.
22. **Glaxon JA, Saldanha P.** Morphological variants and secondary changes in uterine leiomyomas – Is it important to recognize them? *International Journal of Biomedical Research*. 2013; 4: 640-645.
23. **Ekanem I, Ekanem O, Ekanem C.** Clinicopathologic Features of Uterine Fibroids in a Private Gynecologic Setting in Calabar, Nigeria. *American Journal of Clinical Pathology*. 152(Sup 1): S138, 2019
24. **Elugwaraonu O, Okojie AI, Okhia O, et al.** The Incidence of Uterine Fibroid among Reproductive Age Women: A Five Year Review of Cases at ISTH, Irrua, Edo, Nigeria. *International Journal of Basic, Applied and Innovative Research*. 2013; 2(3):55-60.
25. **Adegbesan-Omilabu MA, Okunade KS, Gbadegehin A.** Knowledge of perception of, and attitude towards uterine fibroids among women with fibroids in Lagos, Nigeria. *Scientifica*. 2014; 1-5.
26. **Udonkang M, Ugbem T, Eze I, et al.** Pattern of immunohistochemical expression of inherited breast cancer genes and collagen changes among African women with early breast cancer in Calabar, Nigeria. *Global Journal of Pure and Applied Science*. 2021; 27(3): 327-34.
27. **Udonkang M, Ene C, Archibong A, et al.** Aqueous beetroot dye as an alternative to haematoxylin and eosin in the diagnosis of breast tumours. *Global Journal of Pure and Applied Science*. 2021; 27(4): 417-423.
28. **Wolanska M, Sobelewski K, Drozdzewicz M, et al.** Extracellular matrix components in uterine leiomyoma and their alteration during the tumour growth. *Journal of Molecular and Cell Biology*. 1998; 1:145-152.



29. **Malik M, Norian J, McCarthy-Keith D, et al.** Why leiomyomas are called fibroids: The central role of extracellular matrix in symptomatic women. *Seminars in Reproduction Medicine*. 2010; 28:169-179.
30. **Koohestani A, Braundmeier AG, Mahdian A.** Extracellular matrix collagen alters proliferation and cell cycle progression of uterine leiomyoma smooth muscle cells. *PLoS One*. 2013; 8(9): 758-764.