

Case Report.

A giant swelling over the upper limb.

Singal R¹, Gupta S², Singh B³

¹Department Of Surgery- Maharishi Markandeshwer Institute of Medical Sciences and Research, Mullana,(Distt-Ambala), Haryana, India

²Department of Radiodiagnosis and Imaging- Maharishi Markandeshwer Institute of Medical Sciences and Research, Mullana, (Distt-Ambala), Haryana ,India

³MS Department of SURGERY- Maharishi Markandeshwer Institute of Medical Sciences and Research, Mullana, (Distt-Ambala),Haryana , India.

Corresponding Author and Address

Rikki Singal, Assist Prof, C/O DR. KUNDAN LAL HOSPITAL, AHMEDGARH, DISTT-SANGRUR, PIN CODE-148021, PUNJAB, INDIA.E mail – singalsurgery@yahoo.com, Mobile no -09996184795 , Fax No - 01731304550

SUMMARY

Although lipomas are common entity in the literature but giant lipoma is rare disease. We are reporting a case in an adult patient who presented with a huge swelling in the right arm. It was present over the lateral aspect of the upper limb. Surgical excision of the tumour was done. In follow – up of 9 months, patient is doing well with all normal movements without any neurological deficient. Although, it is not the only case reported, giant lipoma of the upper limb is very uncommon.

Keywords – Subcutaneous; Tumour; Lipoma; Ultrasonography; Surgery

[Afr J Health Sci. 2012; 20:3-4]

Introduction

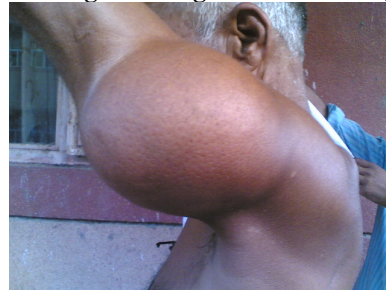Lipoma is one of the commonest benign mesenchymal tumours in the body composed of mature adipose cells. It is found in almost all the organs of the body where normally fat exists that is why it is also known as ubiquitous tumour or universal tumour. Lipomas are slow-growing soft tissue tumours that rarely reach a size larger than 2 cm. Lesions larger than 5 cm, so-called giant lipomas, can occur anywhere in the body [1]. Lipomas are among the most commonly encountered benign soft tissue tumors [2]. Majority of lipomas are located in the head and neck region as well as over the shoulder and back [3]. They can occur anywhere on the body but are rarely found as giant tumour over the arm.

Case report 1

A 67-year-old male patient reported with a 3-year history of an enlarging, painless swelling on the right arm (Figure- 1). He did not have any history of trauma on the area. There was no history of weight loss and had no other symptoms other than rapid enlarging of the tumor for the last 8 months. Movements of the upper limb were within normal

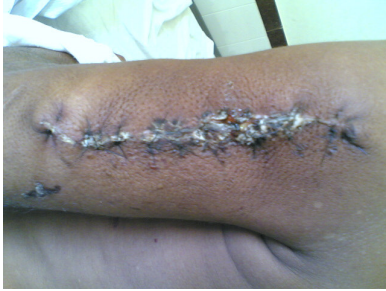limits except for some discomfortness due of is large size.

Figure 1: A huge swelling seen over the right arm



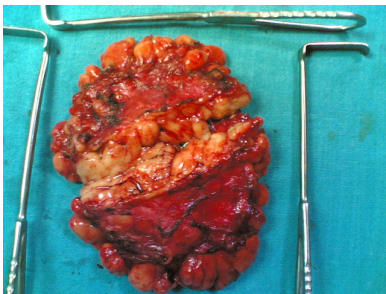
On local examination, a solitary mobile swelling of size 18 x 7 x 10 cm seen lateral aspect of the arm (Figure- 1). Overlying skin was normal. It was firm in consistency, non-tender and edges were well defined. No cervical or axillary lymphadenopathy was noted. Ultrasonography revealed a large soft tissue mass in subcutaneous area of the right arm. An elliptical incision was given longitudinally. Lump was adherent to the underlying muscles and other tissue. Surgical excision done under local anaesthesia and skin was closed primarily (Figure-2).

Figure 2: Skin closed primarily



Grossly, it was a soft yellowish-red, glistening on touch and well defined mass (figure-3). Histopathology confirmed the diagnosis as lipoma. Microscopic examination revealed almost mature fat cells and scattered atypical lipoblast-like cells.

Figure 3: Operative picture showing yellowish in colour of the tissue



Discussion

Lipomas are common, benign tumours originating from adipose tissues. They are not very common in the hand and very rarely seen involving the fingers [4]. Grouped under the label of intermediate malignancy, well-differentiated liposarcoma (WDLs) was originally termed atypical lipoma and atypical lipomatous tumor to emphasize their almost invariably locally aggressive behaviour (almost never metastasize) [5]. The concept of atypical lipoma or atypical lipomatous tumors was first introduced by Evans and associates in 1979 [6].

Lipoma is a slowly growing common solid tumour and occurs mostly in the fifth and sixth decade. These lightly encapsulated tumors are composed of mature fatty tissue where the central lipid droplet and peripherally located nucleus forms the characteristic signet ring cell [2]. They arise from mesenchymal primordial fatty tissue cells. These tumors may be superficial, arising from the subcutaneous tissues and or less commonly may be subfascial, arising deep in the palm within the Guyon canal, the carpal tunnel or the deep palmar space and generally being of bigger size [2].

Neoplastic lesions (liposarcoma, lipoblastoma, Giant cell tumour, spindle cell lipoma, angioliipoma, and

neural fibrolipoma) and non neoplastic lesions (implantation cyst, pyogenic granuloma, and nodular fasciitis) with clinical characteristics similar to those of a lipoma of the finger should be considered in the differential diagnoses of a mass on the finger [3]. Ultrasonography, computerized tomography, or magnetic resonance imagings are useful investigations and differential diagnosis [7]. As in both of our cases, diagnosis was made on ultrasonography as soft tissue tumour and provisional diagnosis kept as lipoma which was confirmed on histopathology.

Conclusion

Although lipomas of the fingers are rare entities, their awareness is imperative, as it is difficult to diagnose. It is necessary to make the differential diagnosis from other soft tissue tumors and from the special lipomatous subtype.

References

1. Allen B, Rader C, Babigian A. Giant lipomas of the upper extremity. *Can J Plast Surg* 2007; **15**:141-4.
2. Efstathios C, Nikolaos P, Christos K, Alkis K, Spyros P, Ioannis N, et al. Patient presenting with lipoma of the index finger: a case report. *Cases J* 2010; **3**: 20.
3. de Giorgi V, Salvini C, Sestini S, Alfaioli B, Carli P. Lipoma of the finger: A case report and differential diagnosis. *Clin Exp Dermatol* 2005; **30**:439-40.
4. Anupama Gupta, Rikki Singal, Amit Mittal and Mohit Goyal. Report of two cases of subcutaneous lipoma over the finger and review of literature: case series Benign tumour. *Musculoskeletal Surgery* DOI: 10.1007/s12306-011-0134-7Online
5. Kindblom LG. Lipomatous tumors-how we have reached our present views, what controversies remain and why we still face diagnostic problems: a tribute to Dr Franz Enzinger. *Adv Anat Pathol* 2006; **13**: 279-85.
6. Dei Tos AP, Mentzel T, Fletcher CD. Primary liposarcoma of the skin: a rare neoplasm with unusual high grade features. *Am J Dermatopathol* 1998; **20**: 332-8.
7. Horcajadas AB, Lafuente JL, de la Cruz Burgos R, Muniz SH, Roca SA, Ortega SG, et al. Ultrasound and MR findings in tumor and tumor-like lesions of the fingers. *Eur Radiol* 2003; **13**:672-85.