



## Case Report

## Open Access

# Cerebrospinal fluid xanthochromia in acute bacterial meningitis as a red herring for subarachnoid haemorrhage: A case report

\*<sup>1</sup>Adesokan, M. A., and <sup>2</sup>Akbari, A. R.

<sup>1</sup>Emergency Department, University Hospital Ayr, Ayrshire, Scotland, United Kingdom

<sup>2</sup>King's Mill Hospital, Sherwood Forest Hospitals NHS Foundation Trust, Nottinghamshire, United Kingdom

\*Correspondence to: [Adedapo.muideen@nhs.net](mailto:Adedapo.muideen@nhs.net); [dapoadesokan@gmail.com](mailto:dapoadesokan@gmail.com)

ORCID: 0000-0003-3132-945X

## Abstract:

This article presents a case that highlights the importance of excluding underlying intracranial pathology in a patient presenting with severe headache and positive xanthochromia. This case report demonstrated that false-positive xanthochromia without subarachnoid haemorrhage (SAH) is possible in acute bacterial meningitis when there is a combination of traumatic lumbar puncture and either hyperbilirubinaemia or raised cerebrospinal fluids (CSF) protein.

**Keywords:** cerebrospinal fluid; acute bacterial meningitis; subarachnoid haemorrhage; xanthochromia

Received Sept 20, 2022; Revised Sept 23, 2022; Accepted Sept 30, 2022

Copyright 2022 AJCEM Open Access. This article is licensed and distributed under the terms of the Creative Commons Attribution 4.0 International License <http://creativecommons.org/licenses/by/4.0/>, which permits unrestricted use, distribution and reproduction in any medium, provided credit is given to the original author(s) and the source. Editor-in-Chief: Prof. S. S. Taiwo

## Xanthochromie du liquide céphalo-rachidien dans la méningite bactérienne aiguë comme hareng rouge pour une hémorragie sous-arachnoïdienne: à propos d'un cas

\*<sup>1</sup>Adesokan, M. A., et <sup>2</sup>Akbari, A. R.

<sup>1</sup>Service des urgences, Hôpital Universitaire Ayr, Ayrshire, Écosse, Royaume-Uni

<sup>2</sup>Hôpital King's Mill, Fondation NHS des Hôpitaux de la Forêt de Sherwood, Fiducie, Nottinghamshire, Royaume-Uni

\*Correspondance à: [Adedapo.muideen@nhs.net](mailto:Adedapo.muideen@nhs.net); [dapoadesokan@gmail.com](mailto:dapoadesokan@gmail.com)

ORCID: 0000-0003-3132-945X

## Résumé:

Cet article présente un cas qui met en évidence l'importance d'exclure une pathologie intracrânienne sous-jacente chez un patient présentant une céphalée sévère et une xanthochromie positive. Ce rapport de cas a démontré qu'une xanthochromie faussement positive sans hémorragie sous-arachnoïdienne (HSA) est possible dans la méningite bactérienne aiguë lorsqu'il existe une combinaison de ponction lombaire traumatique et d'hyperbilirubinémie ou d'augmentation de la protéine du liquide céphalo-rachidien (LCR).

**Mots clés:** liquide céphalo-rachidien; méningite bactérienne aiguë; hémorragie sous-arachnoïdienne; xanthochromie

## Introduction:

Otitis media, and less commonly otitis externa, is a well-known cause of bacterial meningitis (1). Common clinical presentations of acute bacterial meningitis following otitis infection are fever, otalgia, neck stiffness, headache, and confusion (1). One important differential is subarachnoid haemorrhage (SAH), which typically occurs between ages 40 and 60, with the peak frequency between 55 and

60 years (2). The Cooperative study found that intracranial aneurysms were the causative factors in 54% of the initial SAH, while arteriovenous malformations (AVMs) accounted for 6%, and other aetiologies for the remaining 40% (3). After negative computed tomography (CT) of brain for SAH, CT angiography (CTA) is the next line of investigation to identify and characterise berry aneurysms or AVMs (Fig 1). Therefore, there is a clinical justification for patients to have an outpatient magnetic

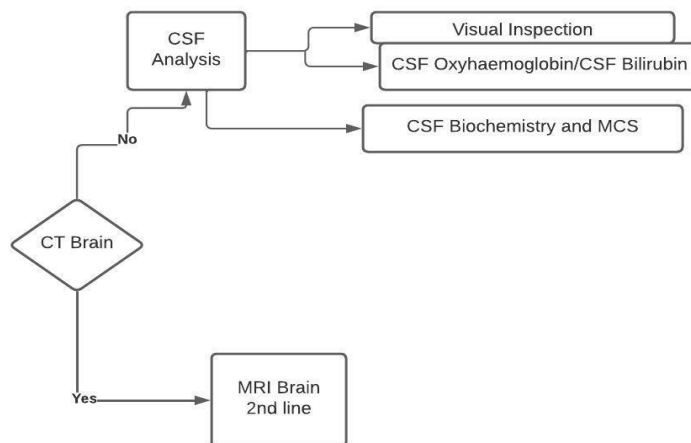


Fig 1: Diagnostic flowchart for suspected subarachnoid haemorrhage and central nervous system infections

Table 1: Causes of false-positive and false-negative cerebrospinal fluid xanthochromia for subarachnoid haemorrhage

False positive result	False negative result
<b>1. Increased oxyhaemoglobin and bilirubin typical of SAH</b> i. Repeat LP ii. Traumatic LP and increased CSF protein iii. Traumatic LP and hyperbilirubinaemia <b>2. Increased bilirubin (late presenting SAH)</b> i. Raised CSF protein ii. Hyperbilirubinaemia	i. LP performed < 12 hours after onset of symptoms ii. CSF sample exposed to light iii. Prolonged delay in CSF sample analysis  i. CSF sample exposed to light ii. Prolonged delay in CSF analysis

LP=Lumbar puncture; CSF=cerebrospinal fluid; SAH=subarachnoid haemorrhage

resonance imaging (MRI) of head with contrast carried out to exclude any underlying cause.

It is possible that a combination of traumatic lumbar puncture (LP) and either hyperbilirubinemia or raised CSF protein may lead to false-positive tests for xanthochromia (4,5). Notable causes of false-positive and negative CSF results for SAH are shown in Table 1. In this report, we discuss a case which highlights the importance of excluding underlying intracranial pathology in a patient presenting with severe headache and positive xanthochromia.

**Case presentation:**

A 61-year-old man with a past medical history of systemic hypertension and bilateral hip replacements presented to the Emergency department (ED) after a few weeks of experiencing tinnitus, ear ache and giddiness. He was managed as otitis externa a week before his admission. A day before admission, he had an MRI brain in a private hospital to rule out acoustic neuroma. He presented to the ED following a collapse episode, which according to his wife, had prior complaints of severe headache and acute confusion but no previous fever. At ED triage, he was noted to have slurred speech, slight facial droop on the right with temperature of 39.4°C. On examination, he had a left-sided hemiparesis with power of 4/5, Glasgow Coma Score of 13/15, and was

deaf in the right ear. The report of the standard MR brain and both internal auditory meatus (IAM) were normal for age, except for a minor paranasal sinus mucopolypsis.

On admission to the ED, the CT head (axial view) revealed no acute abnormality. The patient’s blood sample analysis showed raised inflammatory markers (Table 2). The CSF collected in aliquots of 4 bottles following

Table 2: Blood sample analysis results of the patient

Test (Normal values)	Day 1	Day 12
Hydrogen ions (35-45 nmol/l)	29.3	
Glucose (3.2-6.1 mmol/l)	10.7	
Lactate (0.7-2 mmol/l)	2.4	
White cell count (3.7-9.5 x10 <sup>9</sup> /l)	17.2	9.6
Neutrophils (1.5-6.5 x10 <sup>9</sup> /l)	15.2	6.5
Lymphocytes (1.1-5 x10 <sup>9</sup> g/l)	0.5	0.8
C-reactive protein (2-10 mg/l)	59	39
Urea (2.5-7.5 mmol/l)	6.1	4.4
Creatinine (50-125 mmol/l)	96	79
Ferritin (20-100 U/l)	1305	1102
Platelet (150-400 ng/ml)	124	347

lumbar puncture, was cloudy macroscopically (but not blood-stained) with subsequent analysis revealing white cell count of 1530 cells/ml; 95% polymorphs and 5% lymphocytes. The detailed results of the CSF analysis are shown in Table 3. The CSF and blood cultures

grew *Streptococcus pneumoniae* and the CSF pneumococcal antigen was also positive. The 4<sup>th</sup> sample bottle which was used for CSF xanthochromia spectrophotometry analysis revealed the presence of oxyhaemoglobin and bilirubin, indicative of xanthochromia. Blood borne viruses (BBV) screening was negative for HIV and hepatitis, and ECG shows only sinus tachycardia.

Table 3: Cerebrospinal fluid sample analysis results of the patient

Parameter	Test sample	Bottle 2	Bottle 3	Bottle 4
CSF RBC count	-	423	403	209
CSF protein	5.4			
CSF glucose	1.4			
Blood glucose	10.3			

Based on the history and examination findings at the ED, the patient was treated for possible CSF infection and started on treatment to cover for both bacterial meningitis and encephalitis, after the initial CT head excluded SAH, intracranial bleed or space-occupying lesion (SOL). The patient received intravenous (IV) crystalloids infusion, empirical IV ceftriaxone 2g and acyclovir 800mg as well as antipyretics, until his fever subsided, and was thereafter admitted into the medical ward. The positive finding of CSF xanthochromia necessitated request for an outpatient MRI brain (or the 'gold standard' CTA or MRA brain) to exclude AVM or berry's aneurysm underlying probable SAH, judging by the fact that CT head diagnosis of SAH diminishes with time (5).

On day 3 of admission, he was commenced on IV dexamethasone to mitigate the possibility of cerebral edema developing. On day 10 of admission, the patient became positive for coronavirus disease-19 (COVID-19), which was likely from cross-infection, and was transferred to the COVID ward where he remained asymptomatic. The patient was discharged home on day 12 with a request for outpatient MRA brain to exclude AVM/berry's aneurysm.

The MRI reported a subtle subcentimetre focus of T2 hyperintensity within the subcortical white matter of the right frontal lobe on the FLAIR sequence only. This was considered non-specific and of doubtful significance with no apparent underlying mass lesion. There were no evidences of haemorrhage, infarct, expansible mass lesion, gross atrophy or small vessel ischaemia, diffusion restriction, arterial or venous sinus lesion, and no AVM or berry aneurysm was identified. Only mucosal retention cysts were noted in the right maxillary sinus.

## Discussion:

The 'gold standard' investigation for the diagnosis of SAH in 98% of patients presenting within 12 hours is CT of the brain, but the sensitivity drops to 50% if patients present one week after onset of SAH (6). CSF xanthochromia may remain positive up to 2 weeks post-SAH event (6). The diagnostic test for both meningitis and SAH is LP for CSF analysis. LP should be performed less than 12 hours after the SAH event ideally and this typically reveals xanthochromia to confirm the diagnosis, which is usually detected by CSF spectrophotometry (7).

Researchers in Aberdeen have previously reported a review of 316 CSF samples analysed by spectrophotometry between 1 February 2011 and 31 January 2012, with 26 patients positive for CSF xanthochromia, 6 of whom had aneurysms on CTA (all 6 aneurysms were subsequently clipped or coiled), one patient had encephalitis and another one had malignant meningitis (8). Therefore, it is ideal to determine in CT brain-negative patients in whom clinical suspicion of SAH remains high, the need for further imaging in form of angiography.

The guideline for diagnosis of SAH is CSF with increased oxyhaemoglobin and bilirubin spectrophotometry (6). Isolated elevation of CSF bilirubin spectrophotometry finding however occur when either CSF proteins or serum bilirubin are raised (6). Traumatic LP which occurs commonly can cause raised CSF oxyhaemoglobin, however, this does not cause CSF bilirubin rise, as CSF bilirubin needs to be synthesized *in vivo* (9). The basis of CSF analysis using UV-Vis spectrophotometer is to determine oxyhaemoglobin at the maximum absorbance between 410 and 418 nm while CSF bilirubin is determined at broad absorption maximum in the range of 450 to 460 nm or as a shoulder adjacent to the oxyhaemoglobin peak (Fig 2).

As second line to CT brain, MRI brain is the preferred option. In the case presented, subsequent outpatient MRI brain turned out normal, excluding the possibility of underlying AVM or berry's aneurysm causing an intracranial bleed. This case report described the basis of CSF analysis in form of spectrophotometry and highlighted the need to use MRI/MRA brain to exclude relevant intracranial pathology. It also emphasized the need to confirm the CSF xanthochromia seen in this patient as a red herring, not indicative of SAH, and is in fact due to raised CSF protein from bacterial meningitis, in spite of clinical features suggestive of intracranial bleed.

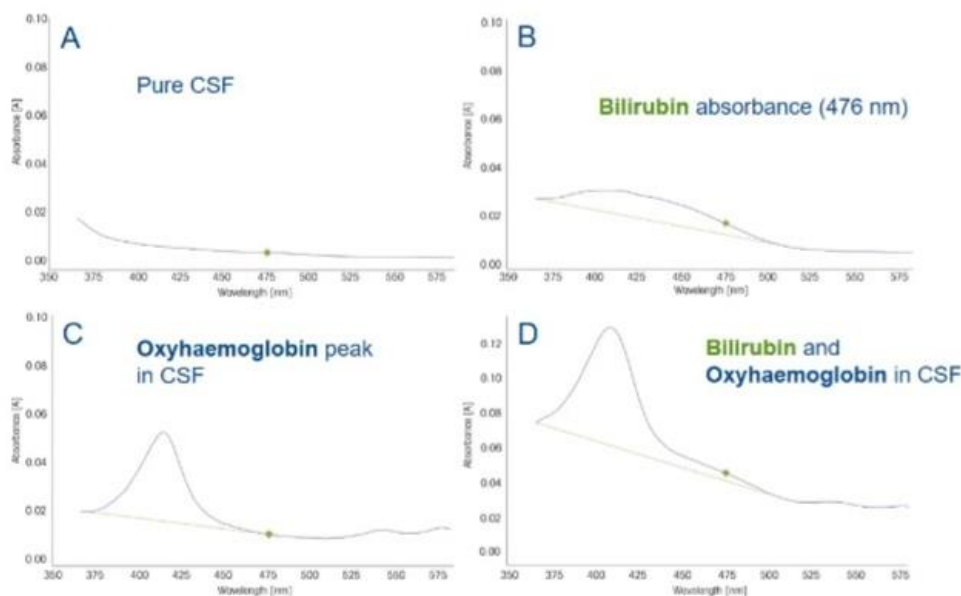


Fig 2: Specifics of CSF analysis in SAH/CNS infections using UV-Vis spectrophotometer

### Acknowledgements:

The authors appreciate Dr. Amrit Ashok, the supervising consultant, Dr. Olalekan Abudu, the radiology consultant who reported the scans and Dr Sathyaprakash Ranganath the consultant ED physician who vetted and contributed to the first manuscript draft.

### Contributions of authors:

AMA is responsible for study design, conceptualization, interpretation and writing of the manuscript. ARA is responsible for critical review and writing of the manuscript. The authors actively contributed to the writing and reviewing of the manuscript and approve the final submitted version.

### Source of fund:

Authors received no external funding

### Ethical approval:

The patient gave explicit consent to publish the clinical case

### Conflicts of interest:

No conflict of interest is declared

### References:

1. Kaplan, D. M., Gluck, K., Kraus, M., et al. Acute

bacterial meningitis caused by acute otitis media in adults: A series of 12 patients. *Ear Nose Throat J.* 2017; 96: 20-28.

2. Kopitnik, T. A., and Samson, D. S. Management of subarachnoid haemorrhage. *J Neurol Neurosurg Psychiatry.* 1993; 56: 947-959
3. Locksley, H. B., Sahs, A. L., and Sandler, R. Report on the cooperative study of intracranial aneurysms and subarachnoid hemorrhage. 3. Subarachnoid hemorrhage unrelated to intracranial aneurysm and A-V malformation. A study of associated diseases and prognosis. *J Neurosurg.* 1966; 25: 219-239.
4. Griffiths, M. J., Ford, C., and Gama, R. Revised national guidelines for the analysis of cerebrospinal fluid for bilirubin in suspected subarachnoid haemorrhage: interpret with caution. *J Clin Pathol.* 2009; 62: 1052
5. Sulaiman, R. A., and Gama, R. Pitfalls in CSF spectroscopy results for the diagnosis of subarachnoid haemorrhage. *Brit J Neurosurg.* 2010; 24: 726
6. Cruickshank, A., Auld, P., Beetham, R., et al. Revised national guidelines for analysis of cerebrospinal fluid for bilirubin in subarachnoid haemorrhage. *Ann Clin Biochem.* 2008; 45: 238-244
7. Kjellin, K. G., and Soderstrom, C. E. Diagnostic significance of CSF spectrophotometry in cerebrovascular diseases. *J Neurol Sci.* 1974; 23: 359-369
8. Rana, A. K., Turner, H. E., and Deans, K. A. Likelihood of aneurysmal subarachnoid haemorrhage in patients with normal unenhanced CT CSF xanthochromia on spectrophotometry and negative CT angiography. *R Coll Phys Edinb.* 2013; 43: 200-206
9. Chow, E., Griffiths, M., and Gama, R. Audit of CSF spectroscopy for suspected subarachnoid haemorrhage in a large DGH by retrospective case note review. *Ann Clin Biochem.* 2008; 45 (Suppl 1): 120