

CASE REPORT

AFRICAN JOURNAL OF CLINICAL AND EXPERIMENTAL MICROBIOLOGY ISBN 1595-689X JANUARY 2019 VOL20 No. .1
AJCEM/1910 <http://www.ajol.info/journals/ajcem>
COPYRIGHT 2018 <https://dx.doi.org/10.4314/ajcem.v20i1.10>

<http://dx.doi.org/10.4314/ajcem.v17i4.1>
AFR. J. CLN. EXPER. MICROBIOL. 20 (0): 67-71

A TWO YEAR OLD INFECTED WITH *DICROCOELIUM DENDRITICUM*: A CASE REPORT

Okwuzu J.O[§], Gbaja-Biamila T.A, Wapmuk A. E, Austin-Akaigwe P.C, Odubela O.O, David A.N, Ezechi O.C.

Clinical Sciences Department, Nigerian Institute of Medical Research, Yaba, Lagos

[§] Correspondence: E-mail ogoamakajane@yahoo.com

ABSTRACT

Dicrocoelium dendriticum infection is rare in human and generally non-fatal unless infection of liver is severe. The disease could lead to biliary colic, digestive disturbances that include bloating and diarrhea. In heavy infections, bile ducts and the biliary epithelium may become enlarged with the generation of fibrous tissues around the ducts leading to hepatomegaly or inflammation of the liver (cirrhosis). This is a case presentation of a two-year old male child who is infected with Human Immune deficiency virus (HIV). BMI was 10.3kg/m², which is below the fifth percentile. Child lost 1.5kg on retrospective review of case file and another 0.5kg after presentation with loss of appetite, cough and fever. Patient was reportedly fed with liver on several occasion. Stool examination revealed many *Dicrocoelium dendriticum* and *Ascaris lumbricoides* ova. Albendazole treatment was instituted and after three months, body weight improved to 10.5kg. It becomes important to screen underweight children for helminthiasis, particularly HIV/AIDS patients whose HIV treatment plan might be of priority to the physician.

Keywords: *Dicrocoelium dendriticum*, Child, *Ascaris lumbricoides*, HIV/AIDS, Albendazole.

RAPPORT DE CAS D'INFECTION À *DICROCOELIUM DENDRITICUM*, AVEC UN BEBE DE DEUX ANS

Okwuzu J.O[§], Gbaja-Biamila T.A, Wapmuk A. E, Austin-Akaigwe P.C, Odubela O.O, David A.N, Ezechi O.C.

Département des sciences cliniques, Institut nigérian de recherche médicale, Yaba, Lagos. § correspondance: E-mail ogoamakajane@yahoo.com

ABSTRAIT

L'infection à *Dicrocoelium dendriticum* est rare chez l'homme et n'est généralement pas mortelle, sauf si l'infection du foie est grave. La maladie pourrait entraîner des coliques biliaires et des troubles digestifs tels que ballonnements et diarrhée. Dans les infections graves, les voies biliaires et l'épithélium biliaire peuvent s'agrandir avec la formation de tissus fibreux autour des voies conduisant à une hépatomégalie ou à une inflammation du foie (cirrhose). Présentation d'un cas d'un enfant de sexe masculin de deux ans infecté par le virus de l'immunodéficience humaine (VIH). L'IMC était de 10,3 kg / m², ce qui est inférieur au cinquième centile. L'enfant a perdu 1,5 kg lors de l'examen rétrospectif du dossier et 0,5 kg après présentation avec perte d'appétit, toux et fièvre. Le patient aurait été nourri de foie à plusieurs reprises. L'examen des selles a révélé de nombreux ovules de *Dicrocoelium dendriticum* et d'*Ascaris lumbricoides*. Un traitement à base d'albendazole a été instauré et au bout de trois mois, le poids corporel s'est amélioré pour atteindre 10,5 kg. Il devient important de dépister l'helminthiase chez les enfants de poids insuffisant, en particulier les patients atteints du VIH / SIDA dont le plan de traitement du VIH pourrait être une priorité pour le médecin. Mots-clés: *Dicrocoelium dendriticum*, Enfant, *Ascaris lumbricoides*, VIH / SIDA, Albendazole

INTRODUCTION

Dicrocoelium dendriticum (liver fluke) is a trematode that causes the disease dicrocoeliasis which is a disease of the liver. The disease is rare in humans and fairly common in grazing animals throughout the

world. This disease can be a serious problem in animals as they can accumulate in large numbers in the bile duct eventually leading to cirrhosis. In humans, it is generally non- fatal unless infection of liver is severe.

Copyright ©2017 AJCEM. This work is licensed under the Creative Commons Attribution 4.0 International License CC-BY

However, due to the unique morphology of the trematode- long and narrow, infections are confined to the more distal parts of the bile ducts and produces mild symptoms as a result. These symptoms could be biliary colic, general digestive disturbances which include bloating and diarrhea. However, in heavy infections, bile ducts and the biliary epithelium may become enlarged with the generation of fibrous tissues around the ducts leading to hepatomegaly or inflammation of the liver (cirrhosis) (1).

Ruminants such as cows and sheep including deer and rabbits (2) are usually the definitive host, but humans and other herbivores can also serve as definitive hosts through the ingestion of infected ants which is found in grass, herbs, raw fruit, vegetables or even drinking water (3). The main reservoirs for *D. dendriticum* are sheep, cows, land snails and ants and have also been found in goats, pigs.

The diagnosis of *D. dendriticum* involves the identification of the parasite eggs in faeces of human or animals. In humans, the eggs in stool may be as result of ingestion of infected animal liver and may not indicate dicrocoeliasis. Therefore, examining bile or duodenal fluid for eggs is a more accurate diagnostic technique.

Ascaris lumbricoides is the largest nematode (roundworm) parasitizing the human intestine. Adult female is 20 to 35 cm long, 3-6 mm wide; adult male: 15 to 30 cm long, 2-4 mm wide. Uteri of females may contain up to 27 million eggs at a time, with 200,000 being laid per day. Fertilized eggs are oval to round in shape and are 45-75 µm long and 35-50 µm (0.0014-0.0020 in) wide with a thick outer shell. Unfertilized eggs measure 88-94 µm (0.0035-0.0037 in) long and 44 µm (0.0017 in) wide.

It is the most common parasitic worm in humans. This organism is responsible for the disease ascariasis (loffer's syndrome), a type of helminthiasis and one of the groups of neglected tropical diseases. An estimated 1 billion people are infected with *A. lumbricoides* worldwide (4). While infection occurs throughout most of the world, *A. lumbricoides* infection is most common in sub-Saharan Africa, the Americas, China, and East Asia (5).

While the vast majority of these cases are asymptomatic, infected persons may present with pulmonary or potentially severe gastrointestinal complaints. Symptoms may include bloody sputum, cough, fever, abdominal discomfort, intestinal ulcer, and passing worms.— Accompanying symptoms include pulmonary infiltration, eosinophilia, and

radiographic opacities (6). Significant increases in fertility are observed in infected women (7). The rate of complications secondary to ascariasis ranges from 11-67%, with intestinal and biliary tract obstruction representing the most common serious sequelae, estimated 730,000 cases of bowel obstruction annually, 11,000 of which are fatal (8). In one series of pregnant patients in Bangladesh, biliary ascariasis was responsible for a plurality (28%) of non-obstetric etiologies of acute abdomen (9).

Ascariasis predominates in areas of poor sanitation and where raw human faeces are used as fertilizer. It is associated with malnutrition, iron-deficiency anemia, and impairments of growth and cognition. Children, because of their habits (eg, directly or indirectly consuming soil), are more commonly and more heavily infected than adults. Male children are thought to be infected more frequently, owing to a greater propensity to eat soil. Neonates may be infected by transplacental infection. Frequently, families may be infected and re-infected in group fashion due to shared food and water sources as well as hygiene practices.

Preventing ascariasis or any faecal-borne disease requires educated hygienic habits/culture and effective faecal treatment systems. The eggs are one of the most difficult pathogens to kill and the eggs commonly survive 1-3 years. *A. lumbricoides* lives in the intestine where it lays eggs. Infection occurs when the eggs are eaten. The eggs may get onto vegetables when improperly processed human feces of infected people are used as fertilizer for food crops. Infection may occur when food is handled without removing or killing the eggs on the hands, clothes, hair, raw vegetables/fruit, or cooked food that is (re)infected by handlers, containers, etc.

Case Presentation

A two year old male child who is infected with human immune deficiency virus (HIV). Patient was delivered through vaginal delivery at term at a TBA centre. He was breast fed at birth and breastfeeding was stopped at 2 months of age. There was no PMTCT intervention either to mother or child. Father is a 33 year old technical school graduate of unknown HIV status. Mother is a 29 year old technical school graduate, recently diagnosed of HIV positive. The patient is the only child of the parents and was placed on HAART, daily vitamin B complex, cotrimoxazole and immune booster. The child is in school.

He weighed 9.5kg at presentation (at 25th month of age) with a loss of 1.5 kg body weight at earlier visit at 18th month of age and a further drop of 0.5kg

weight at the next clinic visit three months from date of presentation. Body temperature was normal at 36.5°C, pulse was 128 beats per minute, while respiration was 30 breaths/min. Height was 96 centimeters which increased steadily from time of registration at two months of birth (57cm). Body mass index was 10.3kg/m² which falls below the fifth percentile indicating that the child is underweight. Head circumference also increased from 41cm at presentation to 48cm at 2 years. His CD4 count gradually improved from 961 to 1795 at 20th month of life then declined a little at presentation at 1542. The haemoglobin level, creatinine, Alanine aminotransferase, urea, glucose were at normal ranges. Viral load was undetectable throughout.

The 1.5kg loss in body weight was with poor appetite, cough and fever at 18th month of life. However, there was no parasitic investigation nor any parasitic treatment plan for the patient. The patient was reportedly not been given antiparasitic medicine by the parents and had been fed with cooked liver on several occasions.

The patient's stool was soft formed. Microscopic examination for ova and parasites revealed many *Dicrocoelium dendriticum* and *Ascaris lumbricoides* eggs. The patient was placed on albendazole. After three months, the body weight of the patient improved drastically to 10.5 kg.

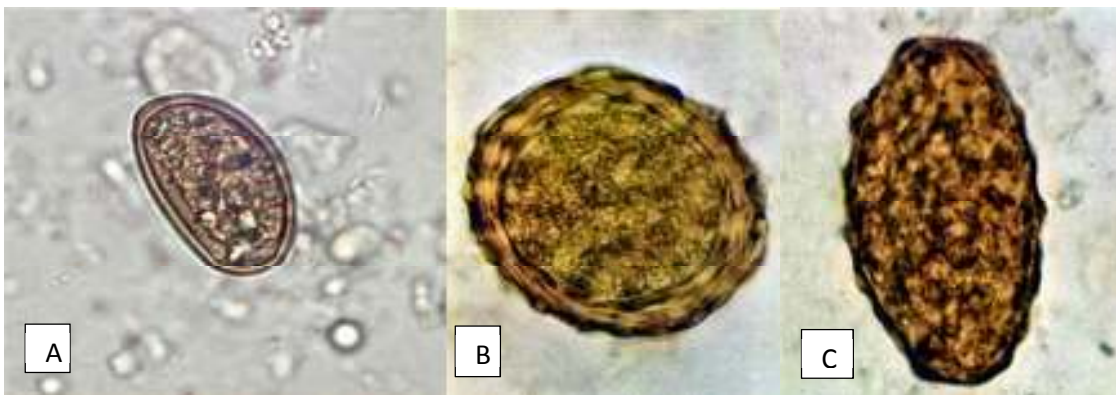


Figure1: A: a wet mount slide of *Dicrocoelium dendriticum* egg in an unstained stool. B: fertile *Ascaris* egg in faeces; C: infertile *Ascaris* egg.

DISCUSSION

The clinical features of *A. lumbricoides* infection are variable between asymptomatic and symptomatic disease depending upon the parasitic burden. The symptomatic disease is largely restricted to individuals with a high worm load (5). The symptoms are related either to larval migration or to the adult worm intestinal stage. Pulmonary manifestations of ascariasis are due to the larval migration through the lungs. Heavy infection with *A. lumbricoides* is frequently manifested by abdominal discomfort, anorexia, nausea and diarrhoea. Heavily infected children suffer from protein malnutrition and vitamin A deficiency (10,11).

Infection of *Ascaris* begins with the ingestion of embryonated (infective) eggs in faeces-contaminated soil or foodstuffs. Once ingested, eggs hatch, usually in the small intestine, releasing small larvae that penetrate the intestinal wall. Larvae migrate to the pulmonary vascular beds and then to the alveoli via the portal veins usually 1-2 weeks after infection, during which time they may cause pulmonary symptoms (e.g. cough, wheezing). The management

of the majority of cases of uncomplicated ascariasis can be done successfully with antiparasitic drugs (12). Meanwhile, complicated cases of ascariasis can be managed by surgical intervention. In our case, albendazole treatment was instituted with a positive response.

Although previously identified in North America, Asia and Africa, most reports of human infection by *D dendriticum* originate in Europe and the Middle East, where the lancet fluke is a common parasite in sheep and cattle. In Nigeria, *D. dendriticum* infections have been reported in slaughtered- cattles in Bauchi (13). Most human cases represent spurious infections, reflecting the gastrointestinal passage of parasite eggs by consumption of infected animal liver.

The caregiver of the child confirms recent ingestion of animal liver, several times that year. We suspect that he passed *Dicrocoelium* eggs in his stool after possibly inadvertent consumption of infected liver, in keeping with a pseudoparasitic infection. True human infection is acquired by ingesting the field ant, which can occur after drinking contaminated water, or eating salads or raw vegetables containing infected

ants. The present patient reported no history of recent ant ingestion.

Symptoms of true human infection may include constipation, chronic diarrhea, vomiting and abdominal pain (14,15) as well as hepatomegaly and peripheral eosinophilia (15,16); and these were not demonstrated by our patient.

Patients infected with HIV and *D. dendriticum* have been reported in the literature (17,18); there is no indication that our patient's immunosuppressive condition had any influence on his clinical presentation as shown by his undetectable HIV viral load and high CD4 T lymphocyte count. His condition improved after successful treatment with albendazole, indicating that his condition was largely related to parasitic infection. Generally, there is no

need to initiate antiparasitic treatment in patients who pass *Dicrocoelium* eggs after ingesting contaminated liver, but we decided to treat the present patient with albendazole and confirm the absence of eggs in the stool, because of co-infection with *A. lumbricoides* as well as his immunosuppressive condition and the concern about his age and interference with physiologic development.

Conclusion

The present report underlines the importance of screening the stool of patients especially children with low body weight for age for underlying, often unsuspected parasitic infections, particularly HIV/AIDS patients whose HIV treatment plan might be of priority to the physician.

REFERENCES

1. Cengiz ZT, Yilmaz H, Dulger AC, Cicek M (2010). [Human infection with Dicrocoelium dendriticum in Turkey](#). *Annals of Saudi Medicine*. 30 (2): 159–61.
2. Burger NC, Nesvadba J, Nesvadba Z, Busato A, Gottstein B (2006). The incidence of *Dicrocoelium dendriticum* in Emmental. *Berl Munch Tierarztl Wochenschr*; 119:324–9.
3. Haridy FM, Morsy TA, Ibrahim BB, Abdel-Aziz A (2003). A preliminary study on dicrocoeliasis in Egypt, with a general review. *J Egypt Soc Parasitol*; 33:85–96.
4. [Parasites - Ascariasis](#)". U.S. Centers for Disease Control and Prevention. Retrieved 3 March 2016.
5. Dold C, Holland CV (2011). Ascaris and ascariasis. *Microbes and Infection*, 13:632–637.
6. Löffler, W (1956). Transient Lung Infiltrations with Blood Eosinophilia. *International Archives of Allergy and Applied Immunology*. 8(1–2): 54–9. doi:10.1159/000228268. PMID 13331628.
7. Blackwell, A. D.; Tamayo, M. A.; Beheim, B.; Trumble, B. C.; Stieglitz, J.; Hooper, P. L.; Martin, M.; Kaplan, H.; Gurven, M. (2015). Helminth infection, fecundity, and age of first pregnancy in women. *Science*. 350 (6263): 970. doi:10.1126/science.aac7902
8. Mishra PK, Agrawai A, Joshi M, Sanghvi B, Shah H, Pareikar SV(2008). Intestinal Obstruction in children due to Ascariasis: a tertiary health centre experience. *Afr Paediatr Surg* ; 5(2): 65-70.
9. Haque M, Kamal F, Chowdhury S, Uzzaman A, Aziz I (2014). Non obstetric causes and presentation of acute Abdomen among the pregnant women. *J Family Reprod Health*; 8(3):117-22.
10. Stephenson LS, Latham MC, Ottesen EA (2000). Malnutrition and parasitic helminth infections. *Parasitology*, 121(Suppl.):S23–S38.
11. Crompton DW, Nesheim MC (2002). Nutritional impact of intestinal helminthiasis during the human life cycle. *Annual Review of Nutrition*, 22:35–59.
12. Keiser J, Utzinger J (2008). Efficacy of current drugs against soil-transmitted helminth infections: systematic review and meta-analysis. *Journal of the American Medical Association*; 299:1937–1948.
13. Karshima NS, Bata SI, Bobbo AA, Habila A (2016). Prevalence and risk factors of *Dicrocoelium dendriticum* and *Eurytrema pancreaticum* infections in slaughtered-cattles in Bauchi, Nigeria. *Nigerian Journal of parasitology*; 37 (2): 260-264.

14. Jelinek T, Rack J, Adusu E (2004). Human infection with *Dicrocoelium dendriticum*. *Deut Med Wochenschr*;129:2538-40.
15. Ondriska F, Sobota K, Janosek J, Joklova E (1989). A rare case of human autochthonous dicrocoeliasis in Czechoslovakia. *Bratisl Lek Listy*; 90:467-9.
16. el-Shiekh Mohamed AR, Mummery V (1990). Human dicrocoeliasis. Report on 208 cases from Saudi Arabia. *Trop Geogr Med*; 42:1-7.
17. Drabick JJ, Egan JE, Brown SL, Vick RG, Sandman BM, Neafie RC (1988). Dicrocoeliasis (lancet fluke disease) in an HIV seropositive man. *JAMA* ;259:567-8.
18. Zali MR, Mehr AJ, Rezaian M, Meamar AR, Vaziri S, Mohraz M (2004). Prevalence of intestinal parasitic pathogens among HIV-positive individuals in Iran. *Jpn J Infect Dis*; 57:268-70.
<https://www.cdc.gov/dpdx/dicrocoeliasis/tx.html>