

Afr. J. Biomed. Res. 13 (May 2010); 157 - 160

Short Communication

Autogenous Corticocancellous Iliac Bone Graft in Reconstruction of Mandibular Defect: Point of Technique

¹Ogunlade S. O., ²Arotiba J. T. and ²Fasola A. O.

¹*Orthopaedic and Trauma Department University College Hospital and Department of Surgery
College of Medicine, University of Ibadan, Ibadan. Nigeria.*

²*Department of Oral and Maxillofacial Surgery, Faculty of Dentistry,
College of Medicine, University of Ibadan, Ibadan. Nigeria.*

ABSTRACT: Mandible resection and subsequent defect created lead to aesthetic and functional abnormalities. The surgical reconstruction of the defect is a major challenge in maxillofacial surgery. Lack of appropriate facilities and the high cost of newer modalities made the use of non-vascularized iliac bone graft in reconstruction of mandibular defect an attractive option in our environment. The technique of harvesting iliac crest graft is highlighted in this prospective study involving 37 iliac crest grafts for mandibular defect reconstruction between 1999 and 2006. Ameloblastoma was the most common indication for mandibular resection in 27 patients (73 percent), while 24 patients (64.9 percent) had hemimandibulectomy which is the most common type of mandibulectomy. A graft take rate of 91.1 percent was achieved in this study. Graft site infection was the most complication with overall incidence of 27.0 percent. Most of the infections were superficial and responded to antibiotic use and local wound care. Donor site complications were few in the study. We recommend the use of autogenous iliac bone graft for reconstruction of mandibular bone defect in our environment

Key Word: Mandible resection, iliac bone graft,

INTRODUCTION

Mandibular resection and the subsequent defect created are relatively common in the practice of a busy maxillofacial surgeon. The reconstruction of the defect is a major challenge in maxillofacial surgery due to attendant aesthetic and functional defects. (Mehta, 2004).

Tumours of the oral cavity and oropharynx constitute the commonest indication for mandibular resections; others include gunshot injuries, osteomyelitis, osteoradionecrosis, congenital abnormalities and defects from trauma. (Head, 2003, August 2000, Obiechina 2003). There are various options available for the reconstruction of the mandible. They include vascularised bone graft, non vascularised graft, alloplastic implants and xenografts (Obiechina 2003, pogrel *et al* 1997, Baky *et al* 1997). Others are distraction osteogenesis and genetically engineered bone growth, which are recent methods introduced in dealing with mandibular defects. (Abukawa *et al* 2004, Tidstrom *et al* 1990).

The lack of appropriate facility and the high cost of newer modalities has been a major limitation to the reconstruction of mandibular defect in our environment. The use of non-vascularized iliac bone graft in reconstruction of mandibular defect is well recognized. The drawback with the use of this method

Manuscript received: December 2010;

Revised version accepted: April 2010

**Correspondence:*

Mr. S. O. Ogunlade, Department of Orthopedic and Trauma
University College Hospital, Ibadan. Ibadan, Nigeria

includes donor site complications, failure of the bone graft and inability of the nonvascular graft to tolerate post-operation radiation. The graft success rate in nonvascularized iliac bone graft varies from 76 percent to 100 percent (August et al, 2000, Pogrel et al 1997, Tidstrom et al 1990). Nonvascularized iliac bone grafts have been found to create a better contour and bone volume for facial esthetics and subsequent implant insertion, and may be the treatment of choice for secondary reconstruction of defects less than 9cm in diameter (Pogrel et al 1997). However the availability of the graft at no additional cost to the patient using common and basic orthopaedic instruments make the method attractive in our environment (Obiechina et al 2003).

MATERIALS AND METHODS

The Technique of Harvesting Nonvascularized Iliac Crest.

The patient lie supine with a small sand bag under the gluteal region to lift the iliac wing away from the operation table.

The operation field is prepared using povidone iodine and patient is draped to expose the whole extent of the iliac wing. A gentle upward pull is made using the edge of ulnar aspect of the hand placed on the iliac fossa to lift upward the skin over the iliac crest. A marker is used to mark the skin that lie over the iliac crest from the anterior superior iliac spine to the posterior superior iliac spine while maintaining the pull. A note is then made of the mark which should now lie just below the prominence of the iliac crest when the gentle skin pull is released. This will make the subsequent scar to lie below the prominence of the iliac crest and below the level of the belt for trousers and skirts in male and female patients respectively preventing future irritation of the scar by the belt.

Incision is made over the mark and deepened to the deep fascia, which is incised. The broad musculofascial attachment of the abdominal wall muscles to the iliac crest is defined and any fatty covering should be cleared off to expose the attachment of these fascia.

A small blade osteotome (1cm wide blade) is used to elevate the musculofascial attachment of the abdominal wall muscles to the iliac crest with about 2mm of bone thickness. The length of the graft will determine the extent of the incision. The use of small blade osteotome will allow for osteotomy line to follow the curve of the iliac crest, if powered instrument is available a thin narrow blade saw should be employed.

In patients with open iliac bone apophysis the osteotomy should be well below the apophysis to avoid damage to the structure.

The elevated muscle with attached bone is then lifted medially to expose the cut surface of the iliac bone, periosteal elevator is then used to clear soft tissue attached to the ilium about 2cm from the cut surface on both medial and lateral surfaces. An abdominal swab is laid along the exposed medial surface of the iliac wing while 1cm thick iliac bone from the cut surface is taken using the osteotome with a counter pressure applied to the iliac bone by the assistant from the medial aspect of the ilium. Care should be taken to ensure that the osteotome does not pass through the entire thickness of the ilium in a single blow, it is advisable that the entire length of the graft be marked out by the osteotome going half way through the depth of the ilium, returning to complete the osteotomy.

The abdominal swab will prevent the osteotome getting into the content of iliac fossa. Also the depth of the osteotome can be estimated from the cut surface of the ilium. An oscillating saw can also be used if available, the precaution to be taken is the same as that for an osteotome. The anterior extent of the osteotomy should be about 1cm from the anterior superior iliac spine to avoid damage to the attachment of the Sartorius muscle.

The osteotomy must be complete before lifting up the graft to avoid breaking the graft. Usually soft tissue attachment to the graft will be encountered posteriorly this should be incised with a scapel. Hemostasis should be achieved and drain inserted. The muscular attachment on the thin layer of bone is approximated to the iliac bone by suturing the fibrous muscular attachment to the deep fascia which will bring the muscular attachment in close proximity to the iliac bone. Skin is closed, 10mls of 0.5% marcain diluted with 10mls of water for injection is infiltrated around the incision wound to reduce post operative pain. Dressing is applied to the wound.

RESULTS

There were 37 iliac crest grafts for mandibular defect reconstruction between 1999 and 2006.

Age group and Sex

There were 22 male and 15 female with a male female ratio of 1.3:1 The ages range from 12 years to 65years with a mean of 27.86⁺-10.18

Diagnosis

Ameloblastoma accounted for the indication for mandibular resection in 27 patients (73 percents), Dentigerous cyst, odontogenic Keratocyst occurred in 2

patients respectively. Other indication for mandibular resection included primordial cyst, central giant cell tumor/granuloma, odontogenic myxoma each

occurring in one patient. Gunshot injury to mandible was responsible for mandibular defect in one patient

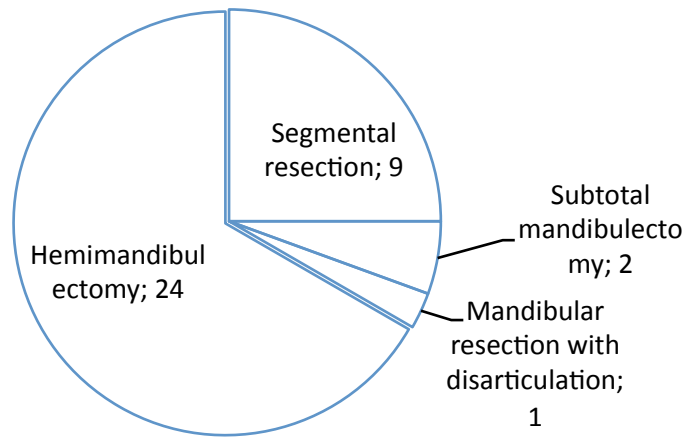


Fig. 1: Types of mandibulectomy

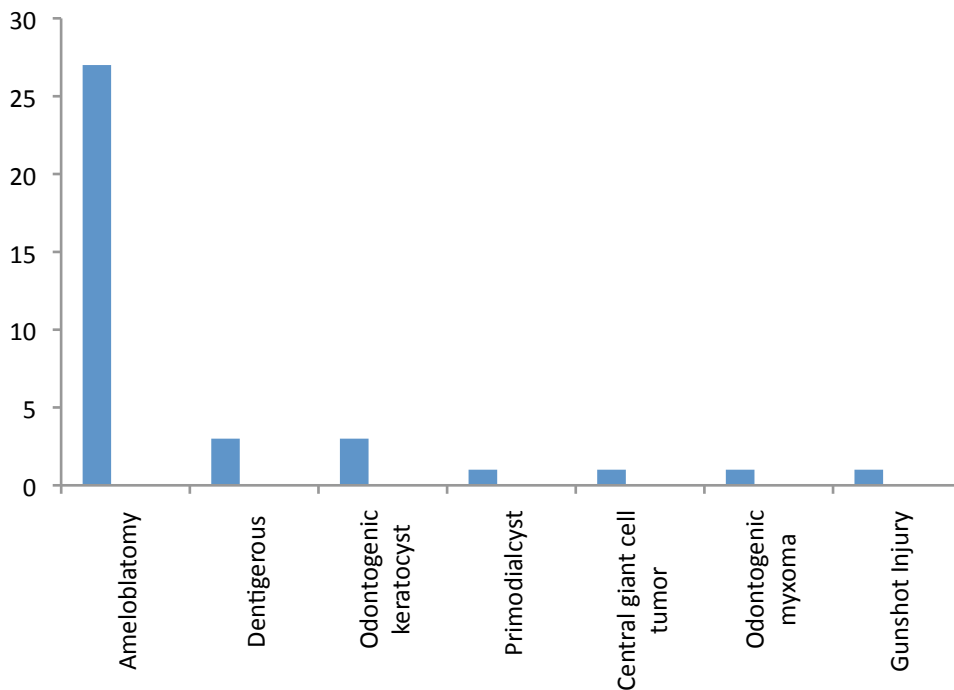


Fig. 2; Indications for surgery

Type of Mandibulectomy

24 patients had hemimandibulectomy accounting for 64.9 percent of the cases, 9 patients (24.3 percent) had segmental resection. Subtotal mandibulectomy in two patients and mandibular resection with disarticulation in one patient. Mandibular

defects in one patient was not from mandibular resection but was a result of gunshot injury.

DISCUSSION

Oro mandibular reconstruction represents an exciting and growing area within head and neck reconstructive

surgery. The advent and use of free tissue transfer had revolutionized the field (Bukey et al 1997).

The most common indication for mandibular reconstruction in our environment is excision of neoplastic lesions in the orofacial regions. This phenomenon appears global as reported by other authors (Mehta et al 2004, Egyedi 1986, Kudo et al 2006).

A graft takes rate of 91.9 percent was achieved in our study. We consider this to be a good outcome. Some authors have reported lower success rate for free autogenous iliac crest like (Pogrel et al, 1997) reported 76 percent success rate while (Kudo et al 2006) reported bony union been achieved in six of eight patients using an antogenous iliac bone graft, a success rate of 75 percent. However authors like Tidstrom and keller (Tidstrometal 1990) reported 100 percent graft incorporation rate along with low overall morbidity. The high percentage of graft incorporation in our study may be due to a low incidence of infection and short span of graft length (mostly 9cm or shorter) with no post operative irradiation, as most of the indications for mandibular resection were benign lesions .

Graft site infection was found to be the most common complication in our study with overall incidence of 27.0 percent. Most of the infections were superficial and responded to antibiotic use and local wound care. Deep infections occurred in 3 patients, who eventually had the graft removed.

In our study, we found no correlation of graft site infection with type of fixation, extent of soft tissue resection, however all our reconstruction were primary. The graft site infection rate of 27 percent i.e 10 patients out of 37 patients agreed with the finding of Egyedi who reported infection in 10 patients out of 38 patients with autogenous bone graft representing infection rate of 26.3 percent (Egyedi, 1986). We also found that none of our patient with no recipient site complication go on to develop graft failure. This finding had also been observed by (August et al 2000).

In this study, donor site complication were few, one patient developed seroma, which resolved with aspiration. One patient had paraesthesia on the lateral aspect of the thigh. This may be due to injury to the lateral cutaneous nerve of the thigh as it passes close to the anterior superior iliac spine.

In two patients, there were reason to expose the previous donor site for harvesting bone graft. It was noticed that there were bony union at the donor site.

We also noticed that none of our patient developed incisional hernia, scar problem from clothing irritation as we have placed the incision to lie below the belt line.

Conclusion

Mandibular defect commonly from tumour excision and trauma is quite common in our environment. The use of autogenous iliac bone graft has been shown to give a good result in our environment, where facilities for free vascular bone and soft tissue flap or metallic implants are not readily available.

REFERENCES

- Abukawa H, Shin M, Williams WB, Vacanti JP, Kaban LB, Troulis MJ.** (2004); Reconstruction of mandibular defects with Autogenous tissue engineered bone. *J Oral Maxillofac Surg.* 2004; 62: 601-606.
- August M, Tom pach P, Chang Y, Kaban L.** (2000); Factors influencing the long-term outcome of mandibular reconstruction. *J. Oral Maxillofacial Surg.* 731-736.
- Bukey BB, Coleman JR.** (1997); Current Concepts in Oromandibular reconstruction. *Otolaryngol Clin N Am* 30: 607-630.
- Egyedi P.** (1986) Wound infection after mandibular reconstruction with autogenous graft. *Ann Acad Med Singapore.* 15: 340-345.
- Head C, Alam D, Sercart JA, Lee JT Rawnsley JD, Berk GS, Black well KE.** (2003); Microvascular Flap reconstruction of the Mandible: A comparison of bone graft and bridging plates for restoration of mandibular continuity. *Otolarygol Head Neck surg* 129 (1): 48-53.
- Kudo K, Shoji M, Yokota M, Fujiok Y.** (2006); Evaluation of mandibular reconstruction technique following resection of malignant tumors in the oral cavity *J Oral Maxillofac Surg* 50: 14-21.
- Mehta PM, Deschler DG.** (2004); Mandibular reconstruction in an analysis of different techniques. *Otolaryngol Head Neck Surg* 12:288-293.
- Obiechina AE, Ogunlade SO, Fasola AO, Arotiba JT.** (2003); Mandibular segmental reconstruction with iliac crest. *West Afr J Med.*22; (1): 46-49.
- Pogrel MA, Podlesh S, Anthony J, Alexander J.** (1997); A comparison of vascularized and non vascularized bone grafts for reconstruction of mandibular continuity defects. *J Oral Maxillofac Surg.* 55; 1200-1205.
- Tidstrom KD, Keller EE.** (1990); Reconstruction of Mandibular Discontinuity with Autogenous iliac bone grafting: Report of 34 consecutive patients. *J oral Maxillofac Surg.* 48: 336.