



www.ajbrui.org

Afr. J. Biomed. Res. Vol. 21 (January, 2018); 51- 55

Research article

Sperm Morphology and Characteristics in Male Rats Treated with Leaf Extract *Combretum sordidum*

Oridupa O.A¹, *Samuel B.B² Amolegbe A.A²

¹*Department of Veterinary Pharmacology and Toxicology, Fac. of Veterinary Medicine, University of Ibadan,*

²*Pharmaceutical Chemistry Department, Faculty of Pharmacy, University of Ibadan, Nigeria.*

ABSTRACT

This study assessed the reproductive toxicity potential of *Combretum sordidum*, a medicinal plant used in West Africa as an antioxidant and antimicrobial recipee. Male Wistar rats (25) were orally administered with the acetone extract of *C. sordidum* a dose of 100, 200, 400 or 800mg/kg for 14 days. On day 15, the rats were humanely sacrificed and semen samples were collected to determine the sperm morphology and characteristics. Histology of the testes was also carried out to assess for the effect of the extract. The extract caused morphological changes of the sperm cells, predominantly secondary abnormality. Primary abnormality observed was rudimentary tail and secondary abnormalities included bent mid-piece, curved mid-piece, bent tail, curved tail, tail-less head, head-less tail and looped tail. The reduction in primary abnormality as opposed to the increase in secondary abnormalities shows that administration over a period of time does not adversely affect spermatogenesis but causes morphological changes of the spermatozoa during maturation and storage at the epididymis. The reduction in sperm count and motility at high doses are indicative of a decline in sperm quality. Although, these semen parameters fall within the recommended range, chronic administration of the extract of *C. sordidum* may lead to infertility and further progress to sterility. It is therefore recommended that *C. sordidum* should not be administered at doses exceeding 200mg/kg and chronic exposure should be avoided in males with reproductive potentials.

Keywords: *Toxicology, Male reproduction, Combretum sordidum, Wistar rat*

*Author for correspondence: E-mail: tundebisamuel@gmail.com; Tel: +234-813-195-1725

Received: January, 2017; Accepted: August, 2017

Abstracted by:

Bioline International, African Journals online (AJOL), Index Copernicus, African Index Medicus (WHO), Excerpta medica (EMBASE), CAB Abstracts, SCOPUS, Global Health Abstracts, Asian Science Index, Index Veterinarius

INTRODUCTION

The use of medicinal plants for curative and prophylactic purposes has increased in the past four decades due to occurrence of adverse drug effects with many orthodox drugs and their limited availability (Nair *et al.*, 2005; Adebayo and Krettli, 2010). Medicinal plants on the other have been employed for ages in different cultures and civilizations of the world with remarkable result and minimal adverse effects reported (Okigbo *et al.*, 2009). Most of the traditional medicine systems do not assess for safety of the various plant parts usually prescribed in combination or singly. Also, there is neither scientific basis for their use(s), nor verification of claims and empirical standardization of drug preparation for precision and repeatability (Joshi *et al.*, 2011).

Lack of proper documentation of patients' responses to these herbal remedies and follow-up records of treatment has blind-sided users of herbal remedies to potential deleterious

effect(s) of some toxic principles produced by some plants as part of their defense mechanisms (Nair *et al.*, 2005). To ensure that medicinal plants with good pharmacological effects become more beneficial to humans and animals, toxicity assessment of these plants is imperative.

An arm of toxicology assesses for toxicities to the reproductive system which may affect fecundity, fertility and overall reproductive potentials of living organisms (Hood and Parker, 2010). This study was therefore designed to assess the reproductive toxicity potentials of *Combretum sordidum* Exell, a medical plant of the family Combretaceae, locally called Apoka pupa in Yoruba (Aworinde and Erinoso, 2015). In West Africa, the family Combretaceae is represented by 9 genera with 72 species and the genus *Combretum* Loefl. is the largest genus with 49 species (Gill, 1988). The genus is widely distributed in the tropics with about 100 species (Ekeke and Agbagwa, 2014). Some of these plants have been used as sources of raw materials for manufacturing of pharmaceuticals

and cosmetics (Irvine, 1961). The plants are reported to possess anti-inflammatory, analgesic anthelmintic, anti-bilharzia (anti-schistosomal) effects, and are used for treatment of malaria, dermatitis, diarrhea, pneumonia, gonorrhea, syphilis, hypertension and some cancers (Ekeke *et al.*, 2014). A recent study showed that *C. sordidum* exhibits both antimicrobial and antioxidant activities, a mechanism underlying many diseases (Olaoluwa and Ogunbor, 2015).

This study assessed the acute and sub-chronic toxic potential of acetone extract of *C. sordidum* on male Wistar rats administered with the extract for 14 days. Sperm cell morphology and semen characteristics such as sperm volume, motility, count and liveability were carried out as indicators of male reproductive toxicity. Histopathology scoring of the cauda epididymis and testes were also carried out to determine changes that may have occurred.

MATERIALS AND METHODS

The Plant

The leaves of *Combretum sordidum* Exell were collected from Ibadan. The confirmation of the plant identity was carried out at the Herbarium of Forestry Research Institute of Nigeria (FRIN), Ibadan, and the Voucher No: 109923 issued. The leaves of the plant collected were air dried and pulverized.

Extraction of the fruit

Soxhlet extraction of 1kg of the pulverized leaves of *C. sordidum* using a soxhlet apparatus was carried out with acetone (distilled) as the solvent of choice. The acetone extract obtained was concentrated on a water bath at low temperature. The result was a paste-like extract, weighing 72.2g (percentage yield of 7.22%). The extract was stored at 40C and freshly reconstituted in corn oil for each experiment.

Experimental animals

The study was carried out at the Experimental Animal Unit of the Department of Veterinary Physiology, Biochemistry and Pharmacology, University of Ibadan, Nigeria. Twenty-five adult male Wistar rats were used for the study and randomly but equally divided into groups of 5 rats each. The rats were acclimatization to the study cages for 3 weeks prior to commencement of the experiment. The animals were fed with pelletized commercial rat feed (Vitafeed®) and clean water ad libitum. All experiments have been examined and approved by the appropriate ethics committee of the University of Ibadan, Nigeria and have therefore been performed in accordance with the ethical standards laid down in the 1964 Declaration of Helsinki.

Sub-chronic toxicity test

Group A was designated the control and administered with distilled water, while the test groups (B-E) were administered with the extract at doses of 100mg/kg, 200mg/kg, 400mg/kg and 800mg/kg. The extract was administered orally once daily at regular intervals for 14 days. The study was carried out according the Animal Care and Use Ethics Committee recommendation of the University of Ibadan, Nigeria, and the animals were treated humanely in the study.

Sample Collection

On day 15, the Wistar rats were first anaesthetized by the use of ether before they were humanely sacrificed by cervical dislocation. The tunica vaginalis was excised and the testes were milked to the surface. The spermatic cord was then exposed, ligated and incised. Semen samples were thereafter collected from the cauda epididymis. This method of collection was as described by Saba *et al.*, 2009. The semen samples were analyzed immediately after collection.

Sperm Volume Assessment

The measurement of sperm volume was carried out by the use of a calibrated measuring cylinder.

Sperm Morphology Assessment

Following the method described by Cipak *et al.*, 2009, the liquefaction of semen was first carried out, then 10 μ L of semen was spread onto a glass slide and allowed to air-dry at room temperature. The smears were then stained with Giemsa stain and sperm morphology was assessed according to WHO criteria. Two different examiners counted 200 cells per smear using brightfield illumination at final magnification of 1000x and oil immersion.

Sperm Motility, Sperm Count and Liveability Assessment

Standard indicators of semen quality (Karpuz *et al.*, 2007) were carried out in this study. After liquefaction, 10 μ L of semen was pipetted onto a glass slide and covered with a cover slip (size 22 x 22 mm). The analysis was performed at room temperature at final magnification of 500x. The immobile sperm were considered dead. The motility was expressed as the percentage of motile spermatozoa, as described by Cipak *et al.* (2009).

Statistical Analysis: All data were presented as mean \pm standard error of mean (SEM) with sample size 5 (n=5) and analyzed using GraphPad Prism (Version 6) with statistical significance determined by One-way ANOVA (Analysis of Variance) and Tukey was used as the post-hoc test. The differences in mean were considered significant at $p < 0.05$

RESULTS

Sperm morphology

Rudimentary Tail: The number of spermatozoa with rudimentary tails in the Wistar rats administered with the extract was non-significantly ($p > 0.05$) lower than those of the rats in the control group (Table 3).

Tail-less Head: There was a non-significant ($p > 0.05$) increase in the number of spermatozoa with the tail-less head abnormality in all Wistar rats groups compared to the Wistar rats in the control group (Table 3).

Head-less Tail: There was a non-significant ($p > 0.05$) decrease in the number of spermatozoa with the headless tail abnormality in Group D (4.40 ± 0.51) and Group E (4.40 ± 0.68), compared to that of the rats in the control group (5.00 ± 0.32). There was no difference in the number of spermatozoa with the headless tail abnormality in Group B

(5.00±0.45) and Group C (5.00±0.55) compared to the control rats (5.00±0.32) (Table 3).

Bent Tail: The Wistar rats in Group B (10.80±0.37), Group D (11.40 ± 0.24) and Group E (10.08±0.37) had a significant (p<0.05) increase in the population of spermatozoa with bent tail, compared to the control rats (8.40±0.40). The number of spermatozoa with bent tail in Group C (9.80±0.58), however, was non-significantly higher than that of the control rats (8.40±0.40) (Table 3).

Bent Mid-piece: There was a significant (p<0.05) increase in the number of spermatozoa with bent mid-piece in Group C (10.20±0.20) and Group D (11.40±0.51) when compared to the control rats (09.00±0.32). Spermatozoa with bent mid-piece in Group B (10.00±0.32) and Group E (10.20±0.37) however were non-significantly higher than that of the control rats (09.00±0.32) (Table 3).

Curved Tail: The number of sperm cells with curved tail in Group C (11.20±0.37) was significantly (p< 0.05) higher than that of the control rats (09.00±0.32). Group B (10.80±0.66),

Group D (11.60 ± 0.81), and Group E (10.80±0.37) on the other hand had a non-significant (p>0.05) increase in population of spermatozoa with the curved tail abnormality compared to the control rats (09.00±0.32) (Table 3).

Curved Mid-piece: Group B (10.00±0.32), Group D (13.00±0.95), and Group E (11.20±0.20) had a significant (p<0.05) increase in population of spermatozoa with the curved mid-piece abnormality compared to the control rats (08.60±0.24). There was however a non-significant (p>0.05) increase in population of spermatozoa with the curved mid-piece abnormality compared to the control rats (08.60±0.24) (Table 3).

Looped Tail: Group C (02.00±0.32), Group D (02.00±0.32), and Group E (02.00±0.45) had the same number of spermatozoa with the looped tail abnormality compared to the control rats (02.00±0.32). Group B (1.80±0.37) on other hand had a non-significant (p>0.05) decrease in number of spermatozoa with the looped tail abnormality compared to the control rats (02.00±0.32) (Table 3).

Table 1:

Occurrence of different sperm abnormalities in Wistar rats administered with acetone extract of acetone *Combretum sordidum* for 14 days.

Mean Sperm Abnorm	Group A (Control)	Group B (100mg/kg)	Group C (200mg/kg)	Group D (400mg/kg)	Group E (800mg/kg)
Tailless Head	04.00 ± 0.32	04.80 ± 0.49	04.60 ± 0.51	04.80 ± 0.49	04.20 ± 0.58
Headless Tail	05.00 ± 0.32	05.00 ± 0.45	05.00 ± 0.55	04.40 ± 0.51	04.40 ± 0.68
Bent Tail	08.40 ± 0.40	10.80 ± 0.37	09.80 ± 0.58	11.40± 0.24*	10.08 ± 0.37
Curved Tail	09.00 ± 0.32	10.80± 0.66*	11.20± 0.37*	11.60± 0.81*	10.80± 0.37*
Bent Mid-piece	09.00 ± 0.32	10.00 ± 0.32	10.20± 0.20*	11.40± 0.51*	10.20± 0.37*
Looped Tail	02.00 ± 0.32	1.80 ± 0.37	02.00 ± 0.32	02.00 ± 0.32	02.00 ± 0.45
Curved Mid-piece	08.60 ± 0.24	10.00± 0.32*	10.20± 0.37*	13.00± 0.95*	11.20± 0.20*
Rudimentary Tail	02.40 ± 0.40	02.20 ± 0.37	01.80 ± 0.37	02.00 ± 0.32	02.00 ± 0.45
Total Mean Abn Sperm	48.40 ± 2.64	55.40± 3.35*	54.80± 3.27*	60.40± 4.13*	55.60± 3.47*

Abn – Abnormal; Values with * are statistically significant compared to the control value

Table 2:

Semen characteristics of male Wistar rats administered with acetone extract of *Combretum sordidum* for 14 days

Semen Character	Group A (Control)	Group B (100mg/kg)	Group C (200mg/kg)	Group D (400mg/kg)	Group E (800mg/kg)
Motility (%)	91.60 ± 0.93	72.00 ± 2.00	68.00±2.00 ^d	56.00 ± 4.00 ^c	54.00 ± 6.00
Live/ Dead ratio (%)	96.20 ± 0.73	93.60 ± 2.23	94.20±2.40	90.60 ± 3.44	92.20 ± 2.99
Volume (cm³)	5.18 ± 0.02	5.18 ± 0.02	5.20±0.00	5.18 ± 0.02	5.18 ± 0.02
Count (% count)	146.80± 4.00 (100%)	105.40±2.50 (71.8%)	98.80±4.25 (67.3%)	95.80 ± 6.25 (65.3%)	95.00 ± 5.36 (64.7%)

Superscript letters indicate group(s) on the same row that were statistically significant (p<0.05)

Table 3:

Histopathological Dimensions of Seminiferous tubules of Wistar rats administered with *Combretum sordidum* Exell for 14 days

Groups	Seminiferous Tubular Diameter	Germinal Height	Luminal Diameter
Control	191.3±10.64	74.66±4.60	57.20±5.95
100mg/kg	361.9±11.03*	107±7.22*	45.40±3.16
200mg/kg	253.9±14.87*	69.02±2.50	82.34±3.98*
400mg/kg	315.3±12.36*	98.99±8.43*	47.16±4.64
800mg/kg	182.4±39.61	74.6±4.16	72.42±6.65

*Indicates significant ($p < 0.05$) difference compared to control value

Semen Characteristics

Sperm Motility: The rate of sperm motility in the test groups was significantly ($p < 0.05$) lower than that of the control rats (Table 4).

Percentage Liveability/Live: Dead Ratio: The ratio of live to dead spermatozoa in Group B (93.60±2.23), Group C (94.20±2.40), Group D (90.60±3.44) and Group E (92.20±2.99) was non-significantly lower than that of the control rats (96.20±0.73) (Table 4).

Volume of Sperm: The volume of sperm was the same for Group B (05.18±0.02), Group D (05.20±0.00) and Group E (05.18±0.02) as for the control rats (05.18±0.02). Group C (05.20±0.00), however, had a non-significantly ($p > 0.05$) higher than that of the control rats (05.18±0.02) (Table 4).

Sperm Count: There was a significant ($p < 0.05$) decrease in the sperm count of the Wistar rats in the test groups compared to that of the control rats (Table 4).

DISCUSSION

In this study, acetone extract of *C. sordidum* caused significant changes in the sperm morphology which could be categorized into the primary, secondary or tertiary sperm abnormalities based on the classification by Adeniji *et al.* (2010). Primary sperm abnormalities occur as a result of the disturbance of spermatogenesis which may be due to congenital or hereditary factors, high ambient temperature or scrotal insulation and diseases, while secondary sperm abnormalities occur during maturation process, while tertiary occur during epididymal transit of spermatozoa (Saba *et al.*, 2009). Rudimentary tail abnormality was the only primary sperm abnormality observed, while the secondary abnormalities were the bent mid-piece, curved mid-piece, bent tail, curved tail, tail-less head, head-less tail and looped tail.

The extract caused a significant increase in the overall abnormal sperm cells observed in treated rats compared to the control rats, with majority of the abnormalities occurring during maturation (Tulsiani *et al.*, 1998). These observations showed that in the overall view, *C. sordidum* a period of time did not adversely affect spermatogenesis but caused morphological changes of the spermatozoa during maturation and storage in the epididymis. Histology of the seminiferous tubules also showed enlargement of the seminiferous tubules with increased luminal diameters and degenerated germinal heights. This may explain the earlier mentioned significantly ($p < 0.05$) increased secondary abnormality, as many cells were misshaped in the process of maturation (Ikawe *et al.*, 2010). According to Bala *et al.* (2015), about 60% of the sperm cell population should be normal in size and shape for fertilization to occur. Sperm cell motility observed in this study attests to the increased sperm cell abnormalities with the dose-dependent reduction in motility. Rats administered with the highest dose showed the least motility of 54%. Clinically, reductions in the sperm cell motility translate to the fact that fertility will reduce in these tested rats and continuous administration of the extract may lead to sterility.

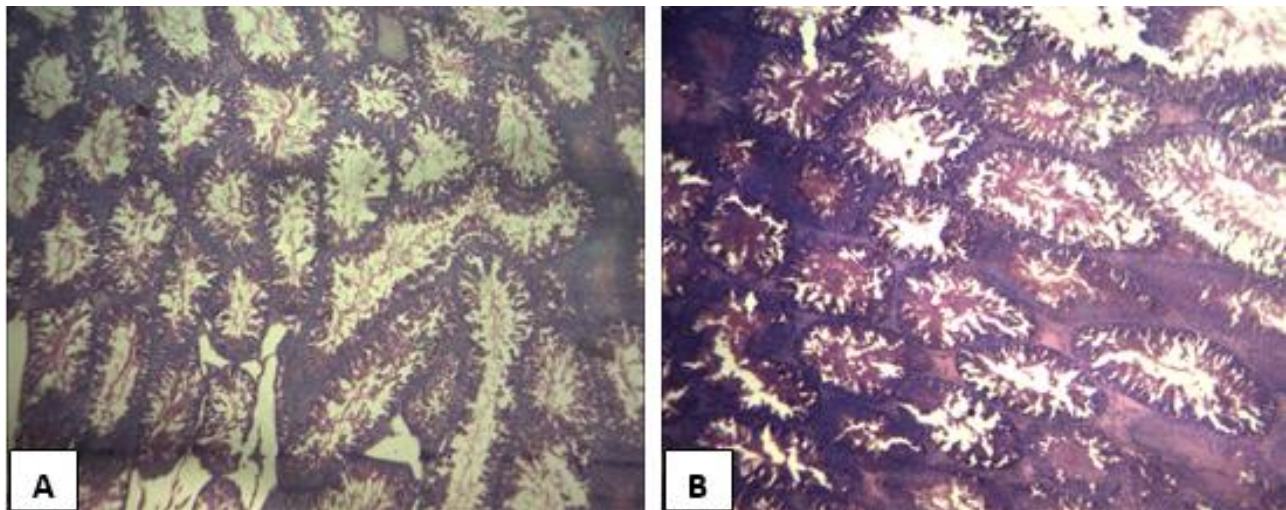


Plate 1

Slide A: Seminiferous tubules of normal rats in control group

Slide B: Seminiferous tubules of rats administered the extract of *Combretum sordidum* 800mg/kg Haematoxylin and Eosin stain. Magnification X40

The ratio of live/ dead spermatozoa decreased in treated rats compared to the control rats, but semen volume of all the rats were statistically unchanged. Sperm count showed a significant ($p < 0.05$) dose-dependent decline, with clinically significant ($p < 0.01$) decreases in rats administered with the higher doses (400mg/kg and 800mg/kg). Low sperm count, however, is not an absolute predictor of infertility. Going by the report by Horvath *et al.* (1989) and Ombelet *et al.* (1997), pregnancies have been achieved with very low sperm counts in studies carried out on different population human males. As long as sperm cells were present, there is no threshold below which pregnancy can occur (Anderson *et al.*, 2002).

Assessment of sperm morphology, count, motility and percentage of normal sperm cells are conventional criteria for determination of semen quality (Karpuz *et al.*, 2007). However, none of these parameters, alone or in combination can be considered diagnostic of infertility (Guzick *et al.*, 2001). This means that despite the decline in sperm quantity and quality, fertilization and conception may still occur, but an exception is made for cases of azoospermia (Skakkebaek, 2010). Azoospermia may eventually occur following chronic administration of this extract. This can be inferred from the rate of progress of development of abnormality following sub-chronic administration of this extract.

Another condition which may occur is teratozoospermia which is a condition diagnosed when semen samples contain $< 30\%$ of morphologically normal spermatozoa according to the WHO criteria or $< 15\%$ according to the strict criteria (Cipak *et al.*, 2009). Although the reduction in normal sperm morphology and characteristics observed in this study may not be severe enough to cause teratozoospermia, it is severe enough to cause significant male infertility and reduced rate of conception in partner females.

The World Health Organization (WHO) guidelines suggest that the cut off value for a normal semen sample should be 20 million spermatozoa per ejaculate, with 50% motility and 60% normal morphology. Although, these semen parameters fall within the recommended range, chronic administration of the extract of *C. sordidum* may lead to infertility and further progress to sterility. It is therefore recommended that *C. sordidum* should not be administered at doses exceeding 200mg/kg and chronic exposure should be avoided in males with reproductive potentials.

REFERENCES

Abarikwu, S.O. (2013): Causes and Risk Factors for Male-Factor Infertility in Nigeria: The Review. African Journal of Reproductive Health. 17(4): 150-166.

Adebayo JO, Krettli AU, (2011): Potential antimalarials from Nigerian plants: A review. Journal of Ethnopharmacology 133: 289-302.

Adeniji, D.A., Oyeyemi, O.A., Olugbemi, J.B. (2010): Sperm Morphological Characteristic and Mating Behaviour of Proviron® Treated West African Dwarf Bucks with Testicular Degeneration. Int. J. Morphol. 28(2): 623-626.

Bala, R., Gupta, V.C., Kumar, V. (2015): A Study to Evaluate Effect of Yashad Bhasm in Oligospermia. World Journal of Pharmacy and Pharmaceutical Sciences. 4(1): 516-520.

Cipak, A., Stanic, P., Duric, K. et al. (2009): Sperm morphology assessment according to WHO and strict criteria: method comparison and intra-laboratory variability. Biochemia Medica. 19(1): 87-94.

Guzick, D.S., Overstreet, J.W., Factor-Litvak, P. et al. (2001): Sperm Morphology, Motility, and Concentration in Fertile and Infertile Men. The New England Journal of Medicine. 345(19): 1388-93.

Hood, R. D. and Parker, R. M. (2010): Reproductive and Developmental Toxicology. Pharmaceutical Sciences Encyclopedia. 12:1-60

Horvath, P.M., Bohrer, M., Shelden, R. et al. (1989): The relationship of sperm parameters to cycle fecundity in superovulated women undergoing intrauterine insemination. Fertil. Steril. 52(2): 288-294.

Ikawe M, Inoue N, Benham AM, Okabe M, (2010): Fertilization: a sperm's journey to and interaction with the oocyte. J Clin Invest 120: 984

Joshi B, Sah GP, Basnet BB, Bhatt MR, Sharma D, Subedi K, Pandey J, Malla R, (2011): Phytochemical extraction and antimicrobial properties of different medicinal plants: *Ocimum sanctum* (Tulsi), *Eugenia caryophyllata* (Clove), *Achyranthes bidentata* (Datiwan) and *Azadirachta indica* (Neem). Journal of Microbiology and Antimicrobials 3(1): 1-7

Karpuz, V., Göktürk, A., Koyutürk, M. (2007): The Effects of Sperm Morphology and Motility on the Outcomes of Intracytoplasmic Sperm Injection. Marmara Medical Journal 20(2): 92-97.

Laing, J. A. (1979): Fertility and Infertility in domestic animals. 3rd Edn. Baillière Tindall, London. pp 59-68.

Nair R, Kalariya T, Chanda S (2005): Antibacterial activity of some selected Indian medicinal flora. Turk. J. Biol., 29: 41-47

Okigbo RN, Anuagasi CL, Amadi JE, (2009): Advances in selected medicinal and aromatic plants indigenous to Africa. Journal of Medicinal Plant Research 3(2): 86-95

Olaoluwa OO, Ogunbor F, (2015): Phytochemical screening, antimicrobial properties and essential oil constituents of *Combretum sordidum* exell. Int Journal of Pharmaceutical Sciences and Research 6(3): 1176-1180

Ombelet, W., Vandeput, H., Van de Putte, G. et al. (1997): Intrauterine insemination after ovarian stimulation with clomiphene citrate: predictive potential of inseminating motile count and sperm morphology. Hum. Reprod. 12(7): 1458-1463.

Saba, A.B., Oridupa, O.A., Oyeyemi, M.O., Osanyigbe, O.D. (2009): Spermatozoa morphology and characteristics of male wistar rats administered with ethanolic extract of *Lagenaria breviflora* Robert. African Journal of Biotechnology. 8(7): 1170-1175.

Skakkebaek, N.E. (2010): Normal reference ranges for semen quality and their relations to fecundity. Asian Journal of Andrology. 12(1): 95-98

