



www.ajbrui.org

Afr. J. Biomed. Res. Vol. 20 (September, 2017); 287- 292

Full Length Research Paper

Whey Protein Concentrate and Dexamethasone Protected Rat Cerebellum from Gamma-radiation Injury

Onatola O.A¹, Owoeye O¹, Elumelu T.N², Shokunbi M.T^{1,3} and Malomo O.A^{1,3}

¹*Department of Anatomy, College of Medicine, University of Ibadan, Ibadan, Nigeria*

²*Department of Radiotherapy, College of Medicine/University College Hospital, Ibadan, Nigeria*

³*Department of Surgery, University of Ibadan/University College Hospital, Ibadan, Nigeria*

ABSTRACT

The possible radioprotective effect of Immunocal® (whey protein) supplement and dexamethasone on gamma-irradiated cerebellar tissue of Wistar rat was investigated in this study. Forty male albino rats were acclimatized and randomized into four groups of 10 animals each. Group I rats served as control; Group II: received 2.5 Gy of gamma-radiation; Group III: received Immunocal® (286mg/kg) for 14 days, then 2.5 Gy gamma rays on day15 of experiment; Group IV: received dexamethasone (1mg/kg) i.p daily for 3 days, then 2.5 Gy gamma rays. All rats were euthanized 14 days post-irradiation. Rat brains were fixed in 10% formalin, processed with routine paraffin wax techniques and stained with Haematoxylin and Eosin. Histomorphometric studies showed that radiation significantly ($p < 0.05$) reduced the thickness of both the molecular and granular layers of the cerebellum when compared with the control group. This reduction was significantly ($p < 0.05$) increased in animals pretreated with Immunocal® and dexamethasone before irradiation. The densities of the Purkinje and outer stellate cells were significantly ($p < 0.05$) reduced in the irradiated animals compared with the control. The Purkinje cells and outer stellate cells were significantly increased ($p < 0.05$) in animals of Radiation + Immunocal® and Radiation + Dexamethasone groups relative to the radiation group. In conclusion, data from the present study showed that pre-treatment with Immunocal® and dexamethasone before exposure to a single dose of 2 Gy of gamma radiation on the 15th day of the experiment, protected rat's cerebellum from gross and histological alterations from radiation injury.

Keywords: Radioprotection, Immunocal®, Dexamethasone, Cerebellum, Purkinje cells

*Author for correspondence: E-mail: owoeye2001@gmail.com; Tel: +2348033239973

Received: December, 2016; Accepted: April, 2017

Abstracted by:

Bioline International, African Journals online (AJOL), Index Copernicus, African Index Medicus (WHO), Excerpta medica (EMBASE), CAB Abstracts, SCOPUS, Global Health Abstracts, Asian Science Index, Index Veterinarius

INTRODUCTION

Radiotherapy is used either alone or as an adjunct to chemotherapy and surgical management in the treatment of various malignancies (Aunapuu *et al.*, 2003). As a modality for cancer management, radiotherapy has been reported to be of great benefit to patients receiving it (Jagetia *et al.*, 2004), however, normal adjacent tissue may be impaired by the radiation of the cancerous lesion close to them (Belka *et al.*, 2001; Yang *et al.*, 2015). For example, radiotherapy of tumours of the nasopharynx, oropharynx or cervical lymph nodes could affect nearby neural structures leading to radiation myelopathy (Malomo *et al.*, 2005). Therefore, strategies capable of protecting the normal tissue adjacent to the tissue being irradiated from the lethal actions of radiation

will therefore be of benefit to affected recipients (Adaramoye *et al.*, 2008).

When using radiation to treat cancer, radiation concomitantly generates free radicals, apart from those generated during normal body metabolism especially in the electron transport respiratory chain (Singh, 2002; Liu *et al.*, 2007), and those produced by activated microglia and immune cells (Greene-Schloesser *et al.*, 2012). Although the body has naturally occurring antioxidant substances that neutralize excess free radicals namely: glutathione, superoxide dismutase, catalase, glutathione peroxidase, vitamin E and ascorbic acid among others, the inadequacy of the body's endogenous antioxidants to mop up the free radicals may lead to oxidative damage of the body (Farombi *et al.*, 2008).

L-gamma-glutamyl-L-cysteinyl-glycine (GSH) antioxidant system is an important protective mechanism of the cell among the naturally occurring endogenous antioxidants

(Bounous & Molson, 2003). A concomitant reduction of the GSH level with elevation of lipid peroxidation in the body is a signal of oxidative stress (Adedara *et al.*, 2014), hence any factor that will encourage generation of GSH will be of importance in ameliorating the effects of oxidative stress. However, the systemic availability of oral GSH is negligible in man and GSH has to be synthesized intracellularly with cysteine being the rate limiting factor in the synthesis of glutathione in the cell (Moulson & Molson, 2003). Augmentation of GSH will therefore be a good strategy to address states of GSH deficiency and high oxidative stress conditions like radiation exposure in cancer therapy. In neural tissues, this will be of immense help since GSH is transported across the blood brain barrier (Kannan *et al.*, 1990).

Immunocal® serves as a cysteine delivery system (Bounous & Moulson, 1999) for the synthesis of reduced glutathione. Immunocal® also called “Whey protein concentrate” was developed in 2000 by Bounous. It contains about 90% protein and is a United States patented natural food protein concentrate in the FDA category of GRAS (generally recognized as safe) which assists the body in maintaining optimal concentrations of GSH by supplying the precursors for intracellular GSH synthesis. Clinical evidence that Immunocal® raises GSH have been provided by Lands *et al.* (1999).

Experimental evidences have been provided that dexamethasone, a glucocorticoid which proven anti-inflammatory property, has some ameliorating effect on radiation damage (Weissman *et al.*, 1991; Lee *et al.*, 2002; Malomo *et al.*, 2006).

The human cerebellum located in the posterior cranial fossa has a most unique histoarchitecture in consisting of 3 layers viz. molecular, Purkinje and granular (Young & Heath, 2000). Grossly it has a median vermis and two cerebellar hemispheres (Conn, 1995) and serves majorly as the coordinating centre for willed muscular movement and posture (Handelman, 2000). Injury to the cerebellum may lead to uncoordinated movement and posture manifested as gross truncal ataxia with marked unsteadiness of gait. The speech may be dysarthric and horizontal nystagmus may be present (Hendelman, 2000) while there may be instability of limb on attempting to maintain a posture against gravity, and past-pointing on reaching intended target (Badoe *et al.*, 2000; Potts *et al.*, 2009).

Considering the important functions of the cerebellum in various activities that involve movements and posture, the present study was designed, using a rat model, to investigate the possible protective effect of Immunocal® and dexamethasone against radiation induced oxidative damage of the brain tissues by applying histological analysis of structural modifications of cerebellar tissue. The outcome will enable us answer the research question: “Can Immunocal® and dexamethasone protect rat’s cerebellum from radiation injury?”.

MATERIALS AND METHODS

Experimental animals: Forty male Wistar rats, weight ranging between 180-220 g were obtained from the Animal House of the College of Medicine, University of Ibadan,

Nigeria and used in this study. After one week acclimatization in the Anatomy Department animal room, they were randomized into four groups. All the animals were kept four in a cage with dimensions 39 cm x 29 cm x 27 cm, and fed with standard rat diet obtained from Bendel Feeds, Benin, Nigeria, with water *ad libitum*. All animals were weighed before and on day of radiation as well as on the sacrifice day, using a Swiss Microwa balance type 7720 weighing machine. The experimental protocols were carried out to conform to the acceptable guidelines on the ethical use of animals in research (Public Health Service, 1996).

Research design: The forty male rats divided into 4 groups of 10 each received treatment as follows:

Group A (Control): animals that served as control.

Group B (Rad): treated with 2 Gy gamma-rays on day 15 of the experiment.

Group C (Rad + Imm): received Immunocal® at 286 mg/kg body weight daily for 14 days per oram and 2 Gy gamma irradiation on day 15 of the experiment.

Group D (Rad + Dex): treated with intraperitoneal injection of dexamethasone at 1 mg/kg body weight /day for 3 days before irradiation with 2 Gy gamma-rays on day 15 of the experiment.

Dexamethasone preparation and administration.:

Standard preparation of 1 mL ampoules containing 4 mg of dexamethasone (Dexagen, Huangshan Tianmu Pharma, India) was administered via a sterile hypodermic syringe with 28 gauge needle at a dose of 1 mg/kg body weight intraperitoneal once daily for 3 days, the last dose was given 1 hour before irradiation was delivered. The dose of dexamethasone was based on the method of (Malomo *et al.*, 2005).

Preparation of working Immunocal® solution.:

The Immunocal® supplement (ImmmoGSH, Canada) used in this study is a dehydrated powdered protein isolate which needs to be appropriately rehydrated before use. The stock solution of Immunocal® supplement was prepared by dissolving 2.5 g of whey protein in 100 mL of distilled water to produce the stock Immunocal® solution and so had a concentration of 25 mg/mL of water. In human trials, an average of 20 g of protein per day per person was used (Bounous *et al.*, 1992) working out at 286 mg/kg body weight forming the basis for administering an average of 60 mg/2.4 mL of Immunocal® solution daily for 14 days to each experimental animal. It was administered orally using a sterile cannula.

Irradiation procedure:

Each experimental rat was administered with 2.5mg/kg of Diazepam injection (Roche, Switzerland) i.p. to sedate and immobilize the rats thus ensuring even body distribution of radiation. Each experimental animal was irradiated with a single dose of 2.5 Gy of gamma-rays obtained from Cobalt-60 source according to the method of (Owoeye *et al.*, 2008). Irradiation was delivered by an AECL Theratron 780-C Teletherapy machine with energy of 1.25 MeV, in a container of field size (Fs) of 18cm x 18cm, with an equivalent square area (ESA) of 18cm² at a surface to surface distance of 80 cm over 2.16 minutes.

The procedure was carried out at the Department of Radiotherapy, University College Hospital, Ibadan, Nigeria.

Tissue extraction, processing and histology: Immediately after irradiation, rats were freed, placed in their cages, and transferred back to the laboratory where they were allowed to recover from sedation. The animals were monitored till the 14th day post-irradiation, weighed and then euthanized by overdose of ketamine anaesthesia. The brains were carefully dissected out, rinsed, blotted dry, weighed and then fixed in 10% formalin. The fixed brains were then processed with routine paraffin wax techniques. Serial sections of 5µm thickness were cut using a rotary microtome (Leitzer Wetzler, Germany) and sections were then stained using Haematoxylin and Eosin (H&E).

Parameters studied: Gross parameters measured included the weight of the animals using a Swiss Microwa balance type 7720, weight of the brain and cerebellum using a Metler Analytical balance and width of cerebellar using a manual sliding caliper. Microscopic parameters were measured using a light microscope (Olympus) with an eyepiece objective ruler (Leitz, Germany) which was calibrated with a 2mm stage micrometer (Leitz, Germany). With x10 and x40 objective magnifications, we measured the thickness of the layers of the cerebellar cortex, the density of the Purkinje cells and outer stellate cells. Photomicrographs were taken with Leitz Photomicroscope (Ernst Leitz Wetzlar GmbH).

Data analysis: Data were expressed as mean ± SD. The statistical significance of the mean differences between groups was assessed by Student's test; a p-value of < 0.05 was regarded as significant.

RESULTS

General observations: Of the four groups of rats studied, only the control group remained active, agile and aggressive throughout the experimental period while all the irradiated animals became weak following irradiation returning gradually to normal activities after 7 days. In addition, all irradiated rats passed watery faeces and had diarrhoea for 2 days after irradiation.

Gross morphometry: As shown in Table 1, radiation reduced the brain weight of rats significantly (p < 0.05) when compared with the control, while treatment with Rad + Dex significantly (p < 0.05) increased the values when compared with Rad group. Radiation similarly reduced the body weight of the rats when compared with the control, while the body weights were even lower in the Rad + Dex and Rad +Imm groups when compared with Rad group though not significant. The significant (p < 0.05) reduction of the maximum width of the rat cerebellum by radiation when compared with control is depicted in Table 2. Neither Rad nor Imm pre-treatment with Rad was able to ameliorate the effect of Rad on the width of cerebellum as shown in Table 2.

Histological examination of cerebellar tissue: As shown in Plate 1, all the groups presented the normal three cortical

layers associated with cerebellum: outer molecular, middle Purkinje and innermost granular with white matter deep to the granular layer. All groups appear to show normal histoarchitecture and preservation of cerebellar cortical layers.

Table 1:
Effect of treatments on weight of rats on day 16 of experiment

Group	Body weight (g)	Brain weight (g)	Relative brain weight
Control	187±10.0	2.22±0.11	1.19
Rad only	176±24.4	1.89±0.11*	1.07
Rad + Imm	157±12.9	1.85±0.08	1.18
Rad + Dex	170±19.2	2.07±0.08**	1.22

Values are expressed as Mean ± S.D of 5 animals per treatment group. Rad = gamma radiation; Imm = Immunocal®; Dex = Dexamethasone. *P<0.05 compared to control group, **P<0.05 compared to HgCl₂ group.

Table 2:
Effect of treatments on gross and microscopic dimensions of rat cerebellum on day 16 of experiment

Group	Maximum width of cerebellum (mm)	Thickness of Molecular layer of cerebellum (µm)	Thickness of Granular layer of cerebellum (µm)
Control	118±4.5	141.0±21.0	242.0±52.0
Rad only	108±4.0*	108.4±17.7*	105.0±22.0
Rad + Imm	108±2.4	142.2±32.2**	214.4±45.0
Rad + Dex	110±8.9	125.2±7.1**	256.0±20.0

Values are expressed Mean ± S.D of 5 animals per treatment. Rad = gamma radiation; Imm = Immunocal®; Dex = Dexamethasone. *P<0.05 compared to control group, **P<0.05 compared to HgCl₂ group.

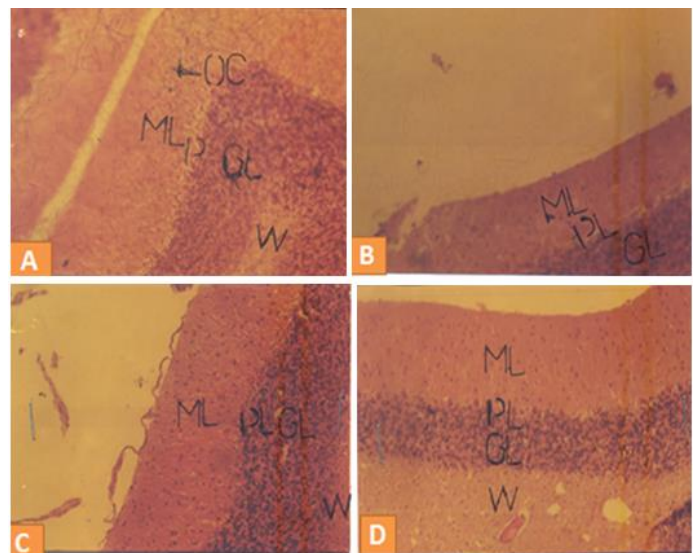


Plate 1:
Representative photomicrograph of cerebellar sections: (A) Control group (B) Irrad group showing apparently normal cortical layers (C) Rad + Imm group (D) Rad + Dex group. All groups appear to show normal histoarchitecture and preservation of cerebellar cortical layers. Irrad=irradiation; Imm=Immunocal. H&E. x 100.

Table 3:

Effect of treatments on the densities of Purkinje and outer stellate cells of rat cerebellum on day 16 of experiment

Group	Density of Purkinje cells (/0.11mm ²)	Density of outer stellate cells (/0.11mm ²)
Control	9.5±1.6	33.6±1.82
Rad only	6.6±1.2*	31.9±4.77
Rad + Imm	8.8±1.2**	37.0±3.39**
Rad + Dex	8.0±0.8**	45.0±5.1**

Values are expressed Mean ± S.D of 5 animals per treatment. Rad = gamma radiation; Imm = Immunocal®; Dex = Dexamethasone. *P<0.05 compared to control group, **P<0.05 compared to HgCl₂ group.

Histomorphometric evaluation of cerebellar tissue

Table 2 shows that radiation significantly (p<0.05) reduced the thickness of the molecular layer of the cerebellum compared with the control. However, treatment with Rad + Dex and Rad +Imm significantly elevated the thickness when compared with Rad group. Similarly, the thickness of the granular layer of cerebellum which Rad reduced significantly p<0.05 when compared with the control was increased in the Rad + Dex and Rad +Imm treatment groups in a significant manner (p<0.05) as shown in Table 2.

There was a significant (p<0.05) reduction in the density of the Purkinje cells relative to control values whereas, there was a reversal of this parameter by the significant (p<0.05) elevation of the density by treatment with Rad + Dex and Rad + Imm when compared with the Rad treatment as shown in Table 3. However, the density of the outer stellate cells of the cerebellum was reduced in the Rad group in comparison with the control, however, the density was increased significantly (p<0.05) in the Rad + Dex and Rad + Imm groups relative to Rad group (Table 3).

DISCUSSION

The overall outcome of our results demonstrated that radiation toxicity caused gross morphometric, histological and histomorphometric alterations in irradiated rats under investigation. The observation of weakness and lethargy in all animals that received radiation treatment might be due not only to the impact of radiation but also to fluid loss from the copious diarrhoea with attendant possible electrolytes loss from the body. Copious diarrhoea by all animals that were irradiated might also be due to radiation injury to colonic mucosa, inflammatory responses, and decreased absorption of water and nutrients of the continuously cycling cells of the gastrointestinal epithelium. Lining epithelial cells being actively mitotic are highly sensitive to radiation, and may lose fluid due to impairment of the absorptive capacity of the injured simple columnar epithelial cells (Young and Heath, 2000) and would appear that pretreatment with Imm and Dex was unable to ameliorate these effects.

Changes in organ weight induced by toxicants have been reported to be a reliable marker of toxicity (Elias and Nelson, 2012). In this experiment, radiation has proven to be toxic to the brain as shown by the reduction of brain weight and

cerebellar width in agreement with published reports (Owoeye *et al.*, 2011; Owoeye and Elumelu, 2015). The inability of pretreatment with Imm and Dex to ameliorate the reduction in the body weight by radiation of rats in both the Rad + Imm and Rad + Dex groups might be due to the overwhelming free radicals generated by the gamma rays leading to a state of oxidative stress.

The reduction in the morphologic parameters of the cerebellum by gamma radiation as shown in Tables 2 and 3 namely, the molecular layer (ML), granular layer (GL), densities of Purkinje cells and outer stellate neurons are consistent with previous reports (Malomo *et al.*, 2006; Owoeye *et al.*, 2011; Owoeye and Elumelu, 2015). The cause of this cerebellar damage might be due to the known toxicity of radiation to neural tissue (Belka *et al.*, 2001; Malomo *et al.*, 2005). The consequences of the above reduction is the effect it would have on these layers and cells namely: reduction in efficiency of granular cells which play important roles in the formation and functioning of cerebellar glomeruli and the eventual synaptic connections that determine the final neuronal output from the cerebellum; reduction in effectiveness of Purkinje cells which is responsible for the most important efferent route from the cerebellum via the very important dentato-rubro-olivary pathway (Potts *et al.*, 2009); effect on the major function of the cerebellum i.e. coordinating the willed muscular activity; effect on granular layer since 90% of all the cerebellar cells are granule cells (DeMeyer, 1988) and from which parallel fibres arise (Potts *et al.*, 2009).

It has been established that cell damage by radiation is mediated by free radicals produced by radiation and pre-treatment with substances that have antioxidant activity or enhancement can mitigate the effect of radiation toxicity in living tissues (Jagetia *et al.*, 2004; Lee *et al.*, 2006; Malomo *et al.*, 2006). Therefore, the amelioration of radiation toxicity by pretreatment with Imm and Dex as demonstrated for all these parameters in the Rad + Imm and Rad + Dex groups (Tables 2 and 3) suggest the ability of as Imm and Dex to neutralise the effect of the damaging free radicals released by the gamma rays. In the case of Immunocal®, this might be due to its ability to augment the antioxidant system with glutathione (GSH) during oxidative stress (Bounus and Molson, 2003). Experimental pre-treatment of rats and mice with cysteine before exposure to radiation protected them from radiation-induced sickness and mortality (Jagetia *et al.*, 2002). Augmentation of glutathione (GSH) source will boost the antioxidant defence system of the body when subjected to oxidative stress as in this experiment and Immunocal® is a ready source of cysteine needed for the synthesis of GSH thus improving the antioxidant defence of the body. Dexamethasone might have stabilized the neuronal cellular membranes from breaking down due to its membrane-stabilising and anti-inflammatory properties, thus enhancing cellular integrity (Schultheiss *et al.*, 1992; Lee *et al.*, 2002; Malomo *et al.*, 2006).

The implication of the amelioration by Immunocal® and Dexamethasone of the altered cerebellar parameters is the neuroprotection offered which would allow the cerebellum to continue to perform its function of coordination of the ipsilateral limbs on performing volition movements and prevention of possible lesions like dys-synergia, intention and

terminal tremors, hypotonia of the ipsilateral limbs, instability of limb on attempting to maintain a posture against gravity, and past-pointing on reaching intended target (Badoe *et al.*, 2000; Potts *et al.*, 2009).

In conclusion, data from the present study showed that pre-treatment with Immunocal® (286 mg/kg) and dexamethasone (1mg/kg) before exposure to a single dose of 2 Gy of gamma radiation on the 15th day of the experiment, protected rat's cerebellum from gross and histological alterations from radiation injury. Also, since the need to protect normal tissue during cancer treatment is as important as the destruction of the cancer cells, focus on application of simple radioprotection substances is recommended for further study. In addition, further research is needed to better understand the mechanisms underlying the protective response of Immunocal® and dexamethasone to cerebellar radiation trauma using histochemical techniques to study the roles of astrocytes and microglia response to the radiation injury.

Acknowledgements

The authors appreciate Prof O.B. Campbell and the Department of Radiotherapy, University College Hospital, Ibadan, Nigeria for providing dosimetry and radiotherapy facilities. We also thank specially Mrs A. O. Ekiola, Mrs B. O. Akinlade, and Mr. A.M. Akinwande of the same department for their helpful roles in the irradiation procedures.

Declaration of interest: The authors declare that there is no conflict of interest in this study. The authors alone are responsible for funding of this research and the content and writing of this paper

REFERENCES

Adaramoye O., Ogunbayo B., Anyaegbu O., Fafunso M. (2008): Protective effects of extracts of *Vernonia amygdalina*, *Hibiscus sabdariffa* and vitamin C against radiation-induced liver damage in rats. *J. Radiat. Res.*, 49, 123-131.

Adedara, I.A., Owoeye, O., Aiyegbusi, M.A., Dagunduro, J.O., Daramola, Y.M. and Farombi, E.O. (2015): Kolaviron protects against benzo[a]pyrene-induced functional alterations along the brain-pituitary-gonadal axis in male rats. *Environ Toxicol and Pharmacol.* 40, 459-470.

Aunapuu M., Pekhter I., Roosaar P., Gershkevich E., Mar'iamiagi M.M., Arend A., Kol'ts I., Ots M. (2003): Morphological changes in the kidney after 5/6 nephrectomy and low-dose radiation. *Tsitologia*, 45, 555-63.

Badoe E.A., Archampong E.Q., da Rocha-Afodu J.T. (2000): Principles and practice of Surgery including pathology in the tropics 3rd ed, 961-967.

Belka C., Budach W., Kortmann R.D., Bamberg M. (2001): Radiotherapy of tumours proximal to normal CNS structures is limited by the sensitivity of the normal tissue. *Br J Cancer* 85, 1233-1239.

Bounous G., Baruchel S., Falutz J., Gold P. (1992): Whey proteins as a food supplement in HIV-seropositive individuals. *Clin Invest Med*, 16:3, 204-209.

Bounous G., Moulson S. (1999): Competition for Glutathione precursor between the immune system and the skeletal muscles: pathogenesis of chronic fatigue syndrome. *Medical Hypothesis*, 53(4). 347-349.

Bounous G., Molson J.H. (2003): The Antioxidant System. *Anticancer Research*, 23, 1411-1416.

Conn P.M. (1995): *Neuroscience in Medicine*. J.B. Lippincott Company. Philadelphia, 451-452, 593-602.

DeMeyer W. (1988): *Neuroanatomy. The National Medical Series for Independent Study*. Harwal Publishing, Philadelphia, 187-206.

Elias A., Nelson B. (2012): Toxicological effect of ciprofloxacin on testicular function of male guinea pigs. *Asian Journal Experimental Biological Science*, 3, 384-390.

Farombi E.O., Ugwuezunmba M.C., Ezenwadu T.T., Oyeyemi M.O., Ekor M. (2008): Tetracycline induced reproductive toxicity in male rats: Effects of vitamin C and *N*-acetylcysteine. *Experimental and Toxicologic Pathology*. 60, 77-85.

Greene-Schloesser D., Robbins M.E., Peiffer A.M., Shaw E.G., Wheeler T.T., Chan M.D. (2012): Radiation-induced brain injury: a review. *Frontiers in Oncology*, 2, (Article 73), 1-18. www.frontiersin.org. doi: 10.3389/fonc.2012.00073

Handelman W.J. (2000): *Atlas of Functional Neuroanatomy*. CRS Press Ltd. 126-136.

Lands L.C., Grey V.L., Smountas A.A. (1999): The effect of supplementation with a cysteine donor on muscular performance. *J App Physio*, 1(87), 1381-1385.

Liu Q., Xie F., Rolston R., Moreire P.I., Nunomura A., Zhu X., Smith M.A., Perry G. (2007): Prevention and treatment of Alzheimer Disease and aging: Antioxidants. *Mini-Reviews in Medicinal Chemistry*, 7, 171-180.

Jagetia G.C., Venkatch P., Balinga M.S. (2004): Fruit extract of *Aegle marmelops* protects mice against radiation-induced lethality. *Integr. Cancer Ther.* 3, 323-332.

Jagetia G.C., Balinga M.S., Malagi K.J. Kamath M.S. (2002): The evaluation of the radioprotective effect of Triphala (an ayurvedic rejuvenating drug) in the mice exposed to γ - radiation. *Phytomedicine*, 9, 99-108.

Kannan R., Juhlenkamp J.F., Jeandidier E., Trinh H., Ookhtens M., Kaplowitz N. (1990): Evidence for carrier-mediated transport of glutathione across the blood-brain barrier in the rat. *J. Clin. Invest.* 85 (6), 2009-2013.

Lee A.W., Kwong D.L., Leung S.F., Tung S.Y., Sze W.M., Sham J.S., Teo P.M., Leung T.W., Wu P.M., Chappell R., Peters L.J., Fowler J.F. (2002): Factors affecting risk of symptomatic temporal lobe necrosis: significance of fractional dose and treatment time. *Int J Radiol Biol Phys*, 53, 75-85.

Lee H.J., Kim S.R., Kim J.C., Kang C.M., Lee Y.S., Jo S.K., Kim T.H., Jang J.S., Nah S.Y., Kim S.H.. (2006): In vivo radioprotective effect of Panax ginseng C.A. Meyer and identification of active ginsenosides, *Phytother Res*, 20(5), 392-395.

Malomo A.O., Owoeye O., Elumelu T.N., Akang E.E.U., Adenipekun A., Campbell O.B., Shokunbi M.T. (2005): The effect of dexamethasone, metronidazole and ascorbic acid on the morphological changes induced by gamma rays on the spinal cord of Wistar rat. *Afr. J. Med. Med. Sci.* 34, 161-165.

Malomo A.O., Ekpo O.E., Imosemi I.O., Owoeye O., Osuagwu F.C., Avwioro O.G., Shokunbi M.T. (2006):

Neuroprotective effect of dexamethasone on the morphology of the irradiated post natal developing cerebellum of Wistar rat. *Int.J Morphol.*, 24(2), 221-229.

Owoeye O., Malomo A.O., Elumelu T.N., Salami A.A., Osuagwu F.C., Akinlolu A.A., Adenipekun A., Shokunbi M.T. (2008): Radiation Nephritis: anti-inflammatory effect of dexamethasone in adult Wistar rats (*Rattus novvegicus*). *Int J Morphol.*, 26(1), 69-74.

Owoeye O., Farombi E.O., Onwuka S.K. (2011): Gross morphometric reduction of rats' cerebellum by gamma irradiation was mitigated by pretreatment with *Vernonia amygdalina* leaf extract. *Rom J Morphol Embryology*, 52(1), 81-88.

Owoeye O., Elumelu T.N. (2015): Tomato consumption protected against gamma radiation-induced behavioural and histological alterations in the hippocampus and cerebellum of rats. *Nigerian Veterinary Journal*, 36(3), 1240-1250.

Singh S.P. (2002): A textbook of Biochemistry, 3rd Ed. CBS Publishers, New Delhi, 545-553.

Potts M.B., Adwanikar H., Noble-Haeusslein L.J. (2009): Models of Traumatic Cerebellar Injury. *Cerebellum*, 8, 211–221. DOI 10.1007/s12311-009-0114-8.

Public Health Service (PHS). (1996): Public health service policy on humane care and use of laboratory animals. US Department of Health and Human Services, Washington, DC, PL, 99-158.

Schultheiss T.E., Stevens L.C. (1992): Radiation Myelopathy. *Am J Neuroradiol*, 13, 1056-1058.

Weissman D.E., Janjan N.A., Erickson B., Wilson F.J., Greenberg M., Ritch P.S., Anderson T., Hansen R.M., Chitambar C.R., Lawton CA., et al (1991): Twice-daily tapering Dexamethasone treatment during cranial radiation for newly diagnosed brain metastases. *Journal of Neuro-oncology*, 235-39.

Yang Z., Bai S., Gu B., Peng S., Liao W., Liu J.(2015): Radiation-Induced Brain Injury After Radiotherapy for Brain Tumor. Licensee InTech. Downloaded from <http://dx.doi.org/10.5772/59045> on 13/08/2016.

Young B., Heath JW. (2000): Wheater's Functional Histology- a text and colour atlas. 4th ed. Churchill Livingstone, Edinburgh, 118, 155, 164, 373.