

Original article

EFFECT OF CHRONIC CONSUMPTION OF COW'S URINE CONCOCTION ON GASTRIC MUCOSA OF ALBINO RAT

Jimoh S.A¹, Soladoye A. O², Enaibe B.U¹. and Owoyele B.V²

Department of ¹Anatomy and ²Physiology, University of Ilorin, Ilorin

The effect of chronic consumption of cow's urine concoction (CUC) and the role of tobacco leaves was studied on the gastric mucosa of Albino rats. The rats were in four groups. Three formulations were used; A full formulation of CUC (CUC-F) was prepared as directed by a herbalist; a modified formulation without tobacco leaves (CUC-NT) and a third formulation (CUC-T) has only tobacco leaves soaked in cow's urine. These formulations were given to three separate groups of rats for a period of four weeks. The fourth group of rats were given ordinary water and normal diet as the control. The weight of the rats were monitored over the four week period. The histology of the mucosa were analysed after staining with haematoxylin and eosin dyes. Compared with the control the pyloric pits in animals administered with CUC-F showed moderate disruption with sloughing of the epithelial lining. In CUC-NT fed group, the pyloric pits showed mild disruption while in group fed with CUC-T, The pits were severely disrupted. In addition, the pyloric glands in group fed with CUC-F showed 50% reduction in glandular tissue while CUC-T fed group showed 80% reduction but the pyloric glands in group fed with CUC-NT were not reduced. Furthermore, the lamina propria showed 90% tissue loss in group fed with CUC-F, 100% in CUC-T fed group and 10% in CUC-NT group. The tissue loss were also associated with significant pseudopit formation. The results also showed changes in the staining characteristics and growth retardation in all the three groups exposed to the formulations.

Key words: cow's urine, gastric mucosa, histological changes, growth retardation

Cow's urine concoction (CUC) has been use for many years among the Yoruba's in the Southwest of Nigeria as a remedy for convulsion in children. Different studies have shown that the composition of the concoction varies (Oyebola and Adetuyibi 1979). Most of the studies available on CUC in literature are associated with physiological changes, some of these include its hypoglycaemic (Oyebola & Olusi 1976; Grage 1981; Iranloye et al, 1999) and cardio-respiratory effects (Elegbe and Oyebola, 1975). Several reports have also shown that administration of this preparation may result in poisoning and even death. From available literature, there is a dearth of information on how this local preparation affects the gastro-intestinal tract. In the present study, the effect of CUC on the morphology of the stomach is investigated. The role played by tobacco leaves – a major component of CUC is also investigated .

MATERIALS AND METHOD:

The study was undertaken in 32 albino rats, divided into four groups of eight animals. Rats in all the groups were given normal rat diet ad-libitum. Water was given to the groups A,B and C three times a day while the control group (D) was given water ad-libitum.

Preparation:

The cow's urine concoction was prepared based on the composition provided by other authors (Oyebola and Adeuyibi 1977,1979) and as directed by a herbalist as follows:

1. The full formulation (CUC-F) Four medium size tobacco leaves (*Nicotiana tabacum*) and medium size basil leaves (*occimum viridae*) from four stalks of the plant soaked in half a litre of cow's urine and 15ml of lemon juice from the lemon fruit (*citrus medicana*), a medium size bulb of onion (*Allium cepa*), ten medium cloves of garlic (*Allium Sativum*) and 5.0g of rock salt (Trona).
 - ii. The tobacco- free formulation (CUC -NT) has all other constituents as the full formulation (CUC-F) but no tobacco leaves.
 - iii. The tobacco-rich formulation (CUC-T) has only tobacco leaves soaked in the cow's urine.
- All the three formulations were left for five days to mature before administration.

Administration of the concoction:

The concoction was administered through a special cannula, employing the modified technique. The concoction was given orally through a plastic tube as reported by other authors (Soladoye and Oyeleke 1990). In this method a special plastic disposable hypodermic syringe (5ml) and between 1.5 – 2.0ml was administered to each rat 8 hourly such that each rat was given the

concoction three times a day. The rats were maintained on the concoction and their normal diet for between one to four weeks and are weighed every other day for the period of the research.

Extraction of tissue specimen:

Animals from each group were sacrificed after four weeks of exposure to determine the effect of the concoction on the gastric mucosa. Prior to sacrificing the animal, it was ensured that the animal were off feeds and water for 8 hours after the last administration of the concoction. The animals were rendered unconscious (stunning) before the laparotomy to expose the abdominal viscera. The gut (including the stomach and the esophagus) were removed and transferred into 10% buffered formalin.

A section of the pylorus was then removed and processed for staining with haematoxylin and eosin dyes. The histological slides that were prepared were analysed to determine the effect of the concoction.

RESULTS

Body weight changes

Loss of appetite was noticed as early as third day which was very evident in the group exposed to the tobacco-rich formulation (CUC-T). This had a resultant effect on their weight loss, which is also more pronounced in the group exposed to the tobacco- rich formulation (CUC-T) (Figure1). Furthermore, the slides from the experimental groups were reviewed and compared with that of the control with respect to the morphology of the pyloric pits, pyloric glands. The lamina propria and the staining characteristics.

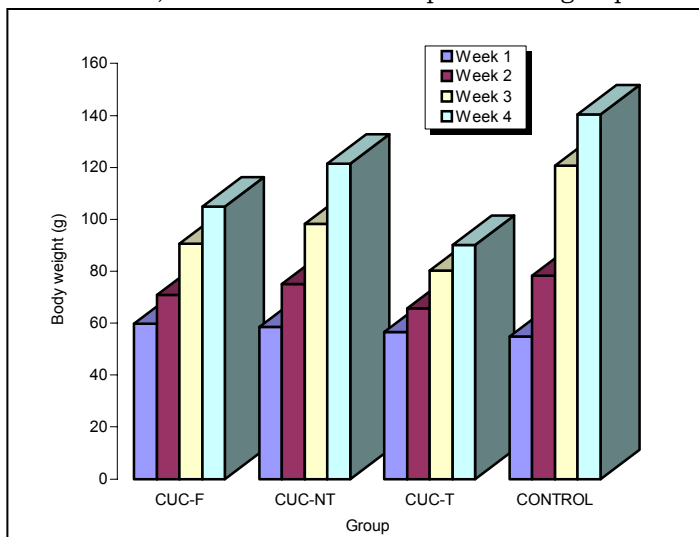


Fig. 1 Weekly Body weight changes in rats fed with full (CUC F), tobacco-free (CUC-NT), tobacco-rich (CUC-T) forms of cow's urine concoctions. Control animals were given 0.0% NaCl

Effect of the full formulation (CUC-F)

After four weeks, the pyloric pits showed moderate disruption and sloughing of the epithelial lining. The pyloric glands showed 50% reductions in glandular tissue. Tissue loss in the Lamina propria was 90% and affinity for haematoxylin was moderate while there was little or none for eosin (plate A). The results are summarized in table 1.

Effect of Tobacco-free formulation (CUC-NT)

The pyloric pits showed mild disruption but no significant loss of epithelia lining. The pyloric gland showed a 50% reduction in glandular tissue. The lamina propria showed 10% tissue loss with significant pseudopit formation. Affinity for haematoxylin was moderate and little or none of eosin. (Plate B).

Effect Tobacco-rich formulation (CUC-T)

After the fourth week, the pyloric pits in this group showed severe disruption. The pyloric gland showed 50%

TABLE 1
SUMMARY OF HISTOLOGICAL CHANGES

| Histological changes | Group | | | |
|--|-------|-----|------|--------|
| | A | B | C | D |
| Pylorus pits | | | | |
| Distruption and sloughing of epithelial lining | ++ | + | +++ | - |
| Glands: (Loss of glandular tissue) | 50% | - | 80% | - |
| Laminar propria (tissue loss) | 90% | 10% | 100% | - |
| Pseudopit formation | ++ | - | +++ | - |
| Staining reaction: | | | | |
| Haematoxylin | ++ | ++ | + | Normal |

reduction in glandular tissue and there was 100% tissue loss in the lamina propria with numerous pseudopits. The staining characteristics showed mild affinity for haematoxylin and moderate affinity for eosin dyes (Plate C).

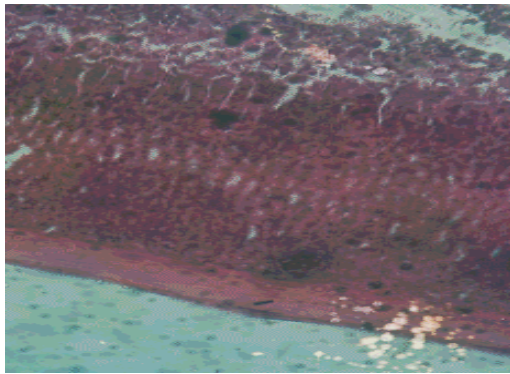


PLATE D
Control

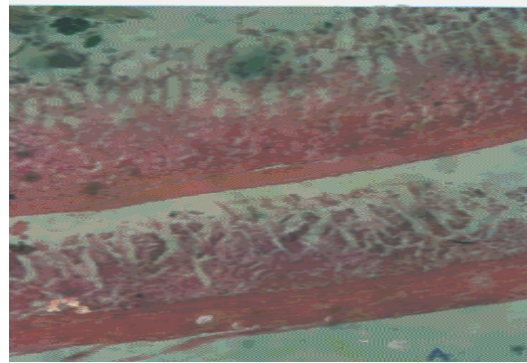


PLATE A
CUC-F



PLATE B
CUC-NT

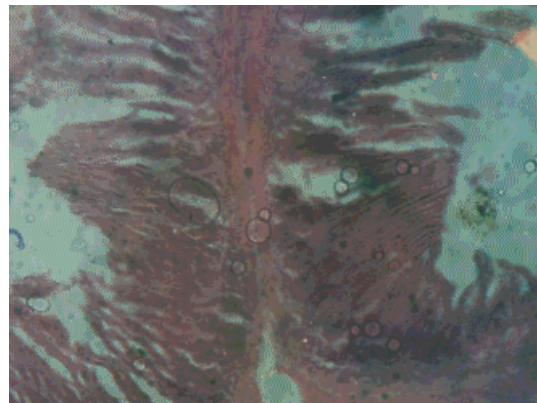

PLATE C
CUC-T

DISCUSSION

In the present study, the effects of CUC formulations with or without tobacco leaves on the morphology of gastric mucosa was investigated. The concoctions were carefully prepared to conform with the traditional preparation and formulation used in past studies (Oyebola and Adetuyibi 1979). The control group was exposed to the normal rat diet and water while the experimental groups had in addition to their diet, cow's urine concoction. Thus, the changes in gastric mucosa are likely due to the effect of the different cow's urine concoction.

The control group showed normal gastric mucosa after four weeks of exposure to the normal food and water.

Among the groups that received cow's urine concoction, damages to the gastric mucosa was most severe in the group that was fed the tobacco rich formulation. On the contrary, damage to gastric mucosa was minimal or the least in the group that had the tobacco free formulation. The damage to the gastric mucosa was characterised by the destruction of the glands, loss of tissue in the lamina propria and formation of pseudopits. In addition, the mucosa also showed disruption of the pyloric pits (Plate 4). These findings have not been documented in the literature before and this has made comparison with previous studies difficult. This is because most of the previous studies on CUC reported functional or physiological changes only (Ojewole and Olusi 1976).

The toxic effect of CUC as observed in those group exposed to the tobacco rich formulation (CUC-T) might not be unconnected with the nicotine contained in the tobacco leaves. Tobacco

usage has been associated with growth retardation and an increased incidence of intrauterine and neonatal death (Russel et al 1966) and nicotine in low concentration is a cholinergic stimulator of autonomic ganglia and in high concentration, a ganglion blocker. It also causes cutaneous and splanchnic vasoconstriction, and produce paralysis of voluntary muscles. It also affect the central nervous system to produce anorexia, nausea and vomiting. Large amount of tobacco taken by mouth delayed gastric emptying (Rogers, 1981).

After the four week period the growth curves also showed depressed growth rate among the animal fed on cow's urine concoction. This probably was associated with the chronic consumption of cow's urine concoction while the histologic changes could be due to the acute effect. It is also possible that the effect on the gastric mucosa interfered with the normal function of the gastric mucosa especially in the digestive processes. Such an effect could lead to undernutrition with a consequent deleterious effect on growth rate. However, the inclusion of trona in the concoction could also retard growth rate as shown in other studies (Soladoye and Oyeleke 1990)

In conclusion, cow's urine concoction as shown by this study altered the morphology and function of the gastric mucosa, at use in the traditional management of conullion in children should be discourage.

ACKNOWLEDGEMENTS

The authors were grateful to Messers Itiola and Abiola for their technical assistance and chief Oyetayo and Mrs. Oyonloye for the secretarial assistance.

REFERENCES

-
- Elegbe, R. A. And Oyebola, D. D. O. (1977)** CUC Poisoning in Nigeria Cardiorespiratory effects of cow's urine concoction in dogs. *Trans R. Soc. Trop. Med.*
- Elegbe, R. A. ; Bamgbose S. O.A ; Oyebola, D.D.O. (1976)** Cow's urine poisoning in Nigeria. The cardiotoxic effects of (CUC) on anaesthetized cats. *J. Trop. Paed and Environ. Child Hlth.* 22: 232-235.
- Iranloye B. O., Olaleye S.B, Oshatimi A and Ojo M.O. (1999).** Effects of Cow's urine concoction with or without garlic on blood glucose in rats. *Afr. J. Biomed. Res.* 2(2): 99-102.
- Grage A (1987). Experimental studies on the cow's urine mixture. *Ann. Trop. Paediatr.* 1: 175-9
- Ojewole, J.A. and Olusi, S. O. (1976) Effects of (CUC) on plasma glucose concentration in fasted rats *J. Trop. Med. Hyg.* 79,241-243.
- Oyebola, D. D. O.; Adetuyibi, A (1977) Toxicity of modified of modified preparation of cows urine concoction in mice. *Trans. R. Trop.med. hyg.*71, 349-350
- Oyebola,d.d.o. and adetuyibi,a.(1979) effect of variation inthe quantities of the constituents of cows urine concoction and its acute toxicity in mice. *West African J. Pharam. And drug Res.* 5, 63-69
- Rogars H.J., Spector R.G. *Textbook of Clinical Pharmacology* (Hodder AND stoughton.) Publ. 1981 pg.796
- Russel, C.S. Taylor R and maddisson R.N. Some effects of smoking in pregnancy. *J. Obstet. Gynecol. Br. Commonwealth* 73,742
- Soladoye, A.O. and Oyeleke, O.A (1990) Effect of moderate intake of trona (Kaun) on growth rate of blood indices in rats. *Nig. J. Physiol.* 6, (2) 1-8

Received: February 1999

Revised version accepted: August 2000