

www.ajbrui.net

Afr. J. Biomed. Res. Vol.17 (May, 2014); 125- 128

Full Length Research Paper

Morphometric Investigation of the Occipital Area of the Adult Nigerian Local Dogs

***Igado O. O and Ekeolu O. K**

*Comparative Anatomy, Neuroscience and Environmental Toxicology Unit,
Department of Veterinary Anatomy, Faculty of Veterinary Medicine, University of Ibadan, Nigeria.*

ABSTRACT

The foramen magnum is of great clinical importance especially in neurologic investigations. This study was carried out to investigate the morphometrics of the foramen magnum of the Nigerian local dog using 13 adults (7 males, 6 females). The shape of the foramen magnum in all specimens examined presented an almost oval shape, with no dorsal notch or extension, and closure of the dorsal bone, resembling that previously reported in Alsatian breeds. Average values were obtained for the foramen magnum height, width, index, occipital height, occipital height without foramen magnum and inter-jugular process width and expressed as mean \pm standard deviation. The males recorded higher mean values for the foramen magnum height and index relative to the females, while the females recorded higher mean values for the width, occipital height and the occipital height without the foramen magnum relative to the males. None of the parameters measured showed statistically significant differences between the genders ($P>0.05$). Values obtained for the inter-jugular process width were similar in both genders. Data obtained from this study will find application in pathological neuroanatomy, comparative anatomy and archaeological studies.

Key words: Nigerian local dog, foramen magnum, morphometrics, dorsal notch, occipital area

INTRODUCTION

The foramen magnum in all animals serves as the point of exit of the brainstem as the spinal cord (Dyce *et al.*, 2002). The shape and size of the foramen magnum has been reported to have undergone many changes, revealing important race and individual variation (Onar *et al.*, 1999). The foramen magnum and occipital bone are of great interest in scientific investigations due to their morphological variability and clinical importance (Janeczek *et al.*, 2011). In humans and animals, anomalies or deviations from the normal in the form and structure of the foramen magnum and the occipital area have been shown to lead to neurological signs (Cagle, 2010).

Of all the domesticated species, the dog has been identified to have shown the closest relationship with humans, worldwide. Dog breeds exhibit a wide range of phenotypic variations and dolichocephalics are characterised by their slim builds and long legs (Onar *et al.*, 2013). The Nigerian local dogs (NLD) are commonly bred in Nigeria, and have been reported to be more resistant to some endemic diseases relative to the 'exotic' or imported breeds (Olayemi *et al.*, 2009). Data from this research is expected to compare with previous findings in other dolichocephalics and other dog skull types, and therefore document any variation or similarities observed

*Corresponding author:

E-mail: mayowaigado@yahoo.com

Tel: +2348035790102

Date Received: September, 2013

Date Accepted: February, 2014

Abstracted by:

Bioline International, African Journals online (AJOL), Index Copernicus, African Index Medicus (WHO), Excerpta medica (EMBASE), CAB Abstracts, SCOPUS, Global Health Abstracts, Asian Science Index, Index Veterinarius

MATERIALS AND METHODS

All procedures followed during this experiment complied with the Guide for care and use of experimental animals, Faculty of Veterinary Medicine, University of Ibadan, Nigeria. Ethical approval was obtained from the same, with ethical code number 'ethic/05/11/01'. Care was taken not to cause unnecessary pain to the animals.

Thirteen adults (7 males, 6 females) were used for this study. All animals were aged 2 years and above. Age was confirmed using the dentition, according to Dyce *et al.*, (2002). The dogs were euthanized with sodium pentobarbital intravenous injection. Heads were decapitated at the atlanto-occipital junction. Skin, muscle, eyeball and tongue were removed from the heads. The skulls were macerated in boiling water to which polycarboxylate, sodium carbonate and anionic surfactant had been added, for one hour, to remove remaining muscles, ligaments and other structures, leaving only the whitened skull, according to the method previously described by Igado (2011). A total of 10 parameters were determined, most of them around the occipital region of the skull and adapted from Onar (1997) and Janeczek *et al.*, (2008). Parameters measured are as follows.

- Whole skull height (WSH): distance measured from the highest level of the frontal bone to the lowest level of the mandible.
- Skull height without the mandible (SHWM): from the level of the highest point of the frontal bone to the base/lowest level of the jugular process.
- Skull height to sphenoid bone (SHWM 1): height of the skull from the most ventral limit of the sphenoid bone, just below the foramen magnum, to the highest limit of the nuchal crest.
- Height of the foramen magnum (FMH): maximum height of the foramen magnum.

- Width of the foramen magnum (FMW): maximum width of the foramen magnum, or also the maximum distance between the two lateral aspects of the foramen magnum.
- Foramen magnum index (FMI): calculated as FMH/FMW X 100. Expressed in percentage.
- Occipital height (OCH): distance from the nuchal crest to the lower rim of the foramen magnum.
- Occipital height without foramen magnum (OCHW): distance from the nuchal crest to the upper rim of the foramen magnum.
- Inter-jugular process width (IPCW): the greatest distance between the medial aspects of the two jugular processes.
- Maximum width of the occipital condyles (OCW): maximum width or distance, measured from the lateral aspect of one occipital condyle to the lateral aspect of the other occipital condyle.

Statistical analysis: All parameters were measured in centimetres (cm) and recorded as Mean \pm standard deviation. Statistical analysis was determined using Student's t-test and correlation analysis with the Graphpad prism V4 software. Statistical significance was reported at $p < 0.05$.

RESULTS

The females recorded higher values in eight out of the ten parameters measured (skull height, skull height without mandible, skull height to sphenoid bone, width of the foramen magnum, occipital height, occipital height without foramen magnum, inter-jugular process width and width of the occipital condyles), although no statistically significant differences were observed. The heights of the skull with and without mandible were 8.1 ± 0.8794 cm and 4.707 ± 0.646 cm respectively (Table 1).

Table 1: Occipital area measurements in the Nigerian Local Dog (NLD).

Parameters	Results in all dogs (n = 13)	Males (n = 7)	Females (n = 6)
Whole skull height (cm)	8.1 ± 0.879	7.883 ± 0.618	$8.286 \pm 1.068^*$
Skull height without mandible (cm)	4.707 ± 0.646	4.483 ± 0.574	$4.875 \pm 0.682^*$
Skull height to sphenoid bone (cm)	4.508 ± 0.616	4.125 ± 0.591	$4.7 \pm 0.566^*$
Height of foramen magnum (cm)	1.245 ± 0.052	1.26 ± 0.055	1.233 ± 0.052
Width of foramen magnum (cm)	1.573 ± 0.079	1.56 ± 0.089	$1.583 \pm 0.075^*$
Foramen magnum index (cm)	79.37 ± 4.893	80.9 ± 3.701	78.1 ± 5.715
Occipital height (cm)	4.408 ± 0.559	4.16 ± 0.321	$4.563 \pm 0.637^*$
Occipital height without foramen magnum (cm)	2.917 ± 0.493	2.725 ± 0.222	$3.013 \pm 0.574^*$
Inter-jugular process width (cm)	3.68 ± 0.660	3.675 ± 0.369	$3.683 \pm 0.838^*$
Width of occipital condyles (cm)	3.075 ± 0.362	3.018 ± 0.225	$3.103 \pm 0.427^*$

* Indicates values which were higher in females, although no statistically significant differences were observed ($P > 0.05$).

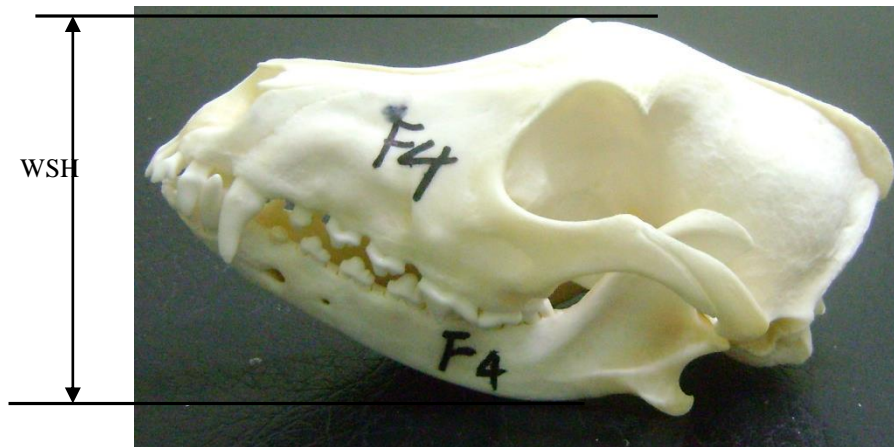

Plate 1:
Lateral view of the skull of the NLD, showing the Whole Skull Height (WSH).

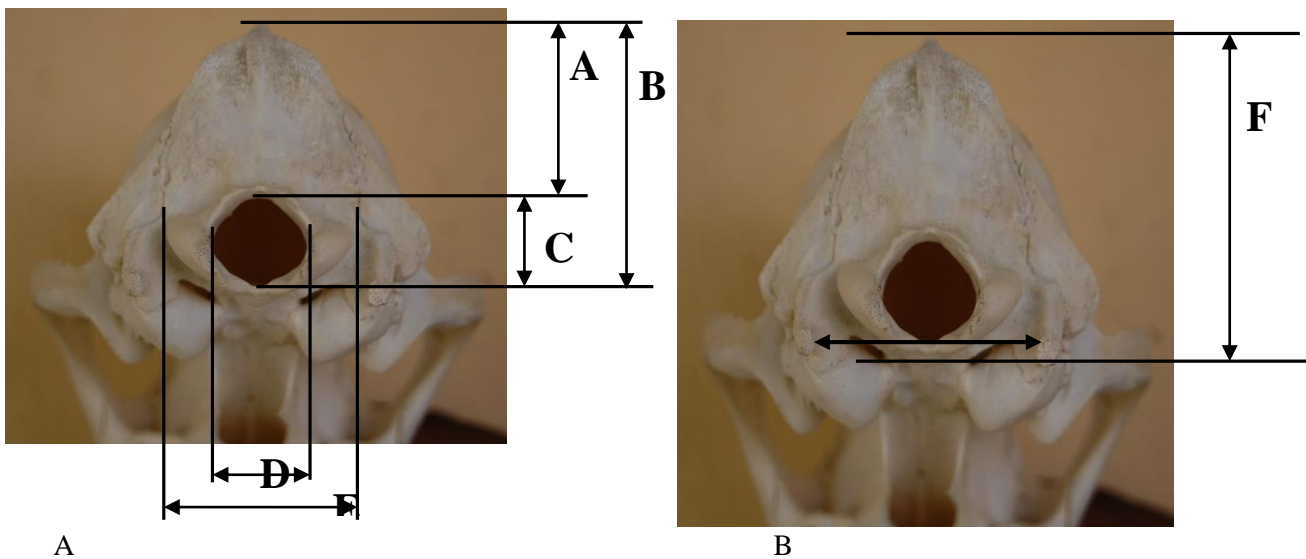


Plate 2:
A. Occipital view of the skull of the NLD, showing OCHW (A), OCH (B), FMH (C), FMW (D) and OCW (E).
B. Occipital view of the skull of the NLD, showing IPCW (arrow) and SHWM 1 (F).

Table 2:
Pearson's correlation coefficient values (r) in occipital area parameters of the NLD

	WSH	SHWM	SHWM 1	FMH	FMW	FMI	OCH	OCHW	IPCW	OCW
WSH	-	-0.196	-0.137	-0.15	-0.043	-0.069	-0.142	-0.240	0.426	-0.435
SHWM	-0.196	-	0.545	-0.702	0.079	-0.531	0.563	0.724	-0.166	0.220
SHWM 1	-0.137	0.545	-	-0.757	0.234	-0.705	0.841	0.682	-0.062	0.468
FMH	-0.150	-0.702	-0.757	-	0.089	0.612	-0.653	-0.681	0.091	-0.078
FMW	-0.043	0.079	0.234	0.089	-	-0.732	0.170	0.067	0.356	0.259
FMI	-0.069	-0.531	-0.705	0.612	-0.733	-	-0.580	-0.504	-0.212	-0.242
OCH	-0.142	0.563	0.841	-0.653	0.170	-0.580	-	0.887	-0.099	0.180
OCHW	-0.240	0.724	0.682	-0.681	0.067	-0.504	0.887	-	-0.025	0.114
IPCW	0.426	-0.166	-0.062	0.091	0.356	-0.212	-0.099	-0.025	-	-0.047
OCW	-0.435	0.22	0.468	-0.078	0.259	-0.242	0.180	0.114	-0.47	-

In all the dog skulls examined, the shape of the foramen magnum showed a consistently oval shape with no dorsal notch observed (Plates. 1 and 2).

Pearson's correlation showed highest positive values for 'r' between OCHW and OCH (0.887), SHWM 1 and OCH (0.841) and OCHW and SHWM (0.724); while highest negative values were observed

between SHWM 1 and FMH (-0.757), SHWM and FMH (-0.702) and OCHW and FMH (-0.681) (Table 2).

DISCUSSION

The foramen magnum is of great importance as it relates to the upper cervical vertebrae, the medulla and the upper cervical cord for a number of reasons. First, skeletal movement relative to the central nervous system is maximal at this point and secondly, many bony abnormalities also occur in this region (Davies, 1962).

The skulls used in this experiment recorded parameters that were mostly higher in females relative to the males, although no statistically significant differences were observed ($p > 0.05$). The foramen magnum index expresses the ratio between the maximal width and total height of the foramen. The foramen magnum height and width showed no statistically significant difference between the sexes, similar to that observed in the Pekingese; but unlike the present study in NLD, the Pekingese showed statistically significant difference between gender values for the foramen magnum index, with the males having higher values (Simoens, 1994). The lack of the dorsal notch in the dog skulls examined is consistent with the report of Onar *et al.*, (1997) in the Alsatian, but inconsistent with previous reports in the Pekingese, toy poodle and the Yorkshire terrier (Simoens, 1994; Baroni *et al.*, 2011). Simoens *et al.*, (1994) mentioned a direct relationship between the occipital triangle (OCH) and the foramen magnum index. This was not the case in this study, where a negative correlation was observed ($r = -0.580$). The skull height maintained a negative correlation, although negligible, to most of the other parameters measured, except to OCW, which was low (-0.435), and IPCW, which was positive (0.426). The FMI maintained a negative correlation to most of the other parameters measured, similar to the report of Onar *et al.*, (1997), except to the foramen magnum height which gave a value of $r = 0.612$.

The foramen magnum index observed in this study (79.37 ± 4.893) was quite different from that observed in the Alsatian (92.67 and 93.51) by Onar *et al.*, (1997), although this current study used adult animals, two years and above, while Onar *et al.*, used 43-60 day, and 61-107 day old puppies respectively.

As was observed with the report of Onar *et al.*, (1997) in the German shepherd, all specimens of NLD examined showed no occurrence of a dorsal notch, and full ossification had occurred in all specimens. This observation of the absence of the dorsal notch could possibly be peculiar to the dolichocephalic, as no neurological symptoms were observed in the subjects

used, and previous reports of presence of the dorsal notch were not in dolichocephalics. In addition, no variability was observed in the shape of the foramen in all the specimens examined.

There is currently an increased awareness of the advantages of breeding the NLD in a tropical environment. Current research shows a strong potential correlation between occipital dysplasia and advanced dog breeding (Janeczek *et al.*, 2011). This current research hopes to highlight the benefits of breeding the NLD, and also provide baseline data on information on its occipital area for anatomical and clinical interventions.

Acknowledgements

The authors gratefully acknowledge the technical assistance of Messrs. A.W. Ramoni and P.O. Akintoye, of the Department of Veterinary Anatomy, University of Ibadan, Nigeria

REFERENCES

- Baroni C.O., Pinto A.C.B., Matera J.M., Chamone C.M.K., Hayashi A.M. (2011):** Morphology and morphometry of the foramen magnum in Toy Poodle and Yorkshire terrier dogs. *Ciência Rural*, Santa Maria, 41(7), 1239-1244.
- Cagle L. (2010):** Concurrent occipital hypoplasia, occipital dysplasia syringohydromyelia and hydrocephalus in a Yorkshire terrier. *Can. Vet. J*, 51, 908-904.
- Davies H.W. (1962):** Abnormalities of the foramen magnum area. *Proceedings of the Royal Society of Medicine*, May 18, 1962, pp 276.
- Dyce K.M., Sack W.O., Wensing C.J.G. (2002):** Textbook of Veterinary Anatomy. 3rd edn. W.B. Saunders Company, Philadelphia.
- Igado O.O. (2011):** Neurometrics and neurocraniometry of the Nigerian local dog (*Canis lupus familiaris*). *J. Vet. Anat*, 4(2), 99-109.
- Janeczek M., Chrószcz A., Onar V., Pazvant G., Pospieszny N. (2008):** Morphological Analysis of the Foramen Magnum of Dogs from the Iron Age. *Anat. Histol. Embryol*, 37, 359-361.
- Janeczek M., Chrószcz A., Czernski . (2011):** Morphological Investigations of the Occipital Area in Adult American Staffordshire Terriers. *Anat. Histol. Embryol*, 40, 278-282
- Olayemi F.O., Azeez I.O., Ogunyemi A., Ighagbon F.O. (2009):** Study on erythrocyte values on the Nigerian indigenous dog. *Folia Vet.*, 53(2), 65-67.
- Onar V., Mutuş R., Kahvecioğlu K.O. (1997):** Morphometric analysis of the foramen magnum in German Shepherd dogs (Alsatis). *Ann. Anat*, 179, 563-568.
- Onar V., Pazvant G., Gezer Ince N., Alpak H., Janeczek M., Kiziltan Z. (2013):** Morphometric analysis of the foramen magnum of byzantine dogs excavated in Istanbul Yenikapi at the site of Theodosius Harbour. *Medit. Arch. Archaeom*, 13(1), 135-14