

Full Length Research Paper

Analysis of epidermal growth factor receptor in histopathologically tumor-free surgical margins in patients with oral squamous cell carcinoma

Sepideh Vosoughhosseini¹, Mehrdad Lotfi^{2*}, Ashraf Fakhrjou³, Amirala Aghbali¹, Monir Moradzadeh¹, Mahmood Sina¹ and Parya Emamverdizadeh¹

¹Department of Oral and Maxillofacial Pathology, Dental Faculty, Tabriz University (Medical Sciences), Tabriz, Iran.

²Research Center for Pharmaceutical Nanotechnology, Tabriz University (Medical Sciences), Tabriz, Iran.

³Department of Pathology, Medical School, Tabriz University (Medical Sciences), Tabriz, Iran.

Accepted 9 November, 2011

Oral squamous cell carcinoma (OSCC) is the most common oral malignancy. The prevalence of OSCC has been reported in more than 90% of all oral cancers. The main treatment of OSCC is complete removal of the tumor. Nevertheless, treatment is not always successful. Approximately 40% of treatment failure rate is seen in patients with OSCC, the most common cause of which is local or regional lymph node recurrence. Even in tumor-free surgical margins, a 30% recurrence rate has been reported. Molecular changes that might indicate early tumor development are seen in normal surgical margins of tumors in the oropharynx and larynx regions. Epidermal growth factor receptor (EGFR), a receptor of tyrosine kinase of ErbB family that is found in tumor lesions, is associated with tumor invasion, increased metastasis to cervical lymph nodes and lower histological differentiation of tumor in OSCC. The existence of EGFR in histopathologically free tumor margins has not been investigated. The purpose of this study was to assess EGFR expression in histopathologically tumor-free margins. A total of 40 paraffin-embedded tissue blocks related to OSCC were obtained from the Pathology Department of Dental School, Tabriz, Iran. All the samples included histologically tumor-free margins and were analyzed by immunohistochemistry for EGFR. Fisher exact test with 95% confidential level was used to analyze data. Strong EGFR staining in the membrane of tumor cells was seen in 30 of 40 (75%) tumor tissues and 4 of 40 (10%) histopathologically tumor-free margins. This study confirmed that the assessment of tumor-free surgical margins by conventional histopathologic examination is not sufficient and detection of EGFR may identify patients who are at a high risk for tumor recurrence and can benefit from anti-EGFR treatment.

Key words: Epidermal growth factor receptor (EGFR), immunohistochemistry, oral squamous cell carcinoma, surgical margin.

INTRODUCTION

Squamous cell carcinoma (SCC) accounts for 94% of all oral malignancies with an annual incidence rate of 5 per 100,000 in the United States (Neville et al., 2008). The

main objective of the surgical treatment of oral squamous cell carcinoma (OSCC) is complete removal of the tumor (Sutton et al., 2003). Despite advances in OSCC treatment, survival rates of patients have not been improved significantly due to local or regional lymph node recurrence (van Houten et al., 2004; Bilde et al., 2009). Even when the surgical margins are histopathologically diagnosed as tumor-free, approximately 30% of OSCC patients develop local recurrences (Bilde et al., 2009, 2009). It is likely that genetically altered cells may be left

*Corresponding author. E mail: mehrlotfi@yahoo.com. Tel: +09411 3355965. Fax: +094113346977.

Abbreviations: OSCC, Oral squamous cell carcinoma; EGFR, epidermal growth factor receptor.

Table 1. Clinical data of the patients.

Variable	Parameter	Value
Age	Male	(45-85) 69.45
	Female	(18-87) 62.18
Sex	Male	(60%) 24
	Female	(40%) 16
Region	Tongue	(42.5%) 17
	Lower lip	(37.5%) 15
	Palate	(10%) 4
	Mandible	(5%) 2
	Floor of the mouth	(2.5%) 1
	Buccal mucosa	(2.5%) 1

in the histopathologically normal surgical margins and cause local recurrence. Therefore, it is important to evaluate not only histology but also the molecular nature of the surgical margin, targeting important genes in carcinogenesis (Bilde et al., 2009; Jelovac et al., 2009).

Epidermal growth factor receptor (EGFR) is an oncogene and its over expression is identified in many malignancies, including breast, prostate, lung, bladder, and head and neck cancers (Oliveira et al., 2006). In OSCC, EGFR over expression is related to decreased overall survival, metastases to lymph nodes and diffuse tumor invasion (Oliveira et al., 2006; Laimer et al., 2007). The aim of the present study was to investigate the presence of EGFR gene in histopathologically tumor-free margins.

MATERIALS AND METHODS

Patients and inclusion criteria

A total of 40 paraffin-embedded tissue blocks from OSCC cases were obtained from the Pathology Department of Dental School, Tabriz, Iran. All the samples included histologically tumor-free margins and were reviewed by two pathologists. Surgical margin was considered negative when the distance from the tumor to resection surface was 5 mm or more (Bilde et al., 2009). Inclusion criteria were patients with complete records, negative surgical margins and no history of radiotherapy, chemotherapy and recurring tumors. Tumor tissue and adjacent normal surgical margins were analyzed for EGFR expression.

Immunohistochemistry

One 4- μ m-thick section from each paraffin-embedded block was cut and deparaffinized at 37°C for 24 h. The slides were rehydrated through graded concentrations of alcohol to retrieve surface antigens. Then, they were put in a microwave oven in boiling citrate buffer (pH = 6) for 5 min and floated in phosphate-buffered saline (PBS) (pH = 6). Then, immunohistochemical staining steps were followed sequentially: Blocking the endogenous peroxides activity by 11.11% hydrogen peroxide for 5 min; immersion in PBS; use of

the monoclonal antibody of EGFR (Dako, Denmark A/S; Lot no: 00049086) for 30 min; immersion in PBS; and use of the envision solution for 15 min. Finally, the samples were stained with hematoxylin and eosin and studied at high magnification (40x) under a light microscope. The proportion score described the estimated fraction of positively stained tumor cells (1 <10%; 2 = 10 to 50%; 3 = 50 to 80%; 4 \geq 80%). The intensity score represented the estimated staining intensity (1, no staining; 2, weak; 3, moderate; 4, strong) (Kusukawa et al., 1996).

Statistical analysis

Statistical analysis was carried out in an attempt to determine EGFR expression in the tumor tissue and adjacent normal surgical margins, using Fisher exact test. Statistical significance was defined at $p < 0.05$.

RESULTS

Clinical data

Complete records and tissue specimens from 40 cases of OSCC (16 females and 24 males) were available. The median age of the patients was 26 (a range of 33 to 98 years). The most common site was the tongue which accounted for 42.5% of the cases. The remaining tumors were found in the lower lip (37.5%), palate (10%), mandible (5%), floor of the mouth (2.5%) and buccal mucosa (2.5%) (Table 1). A total of 95% of the tumors were well differentiated, with 5% moderately differentiated.

EGFR expression

Strong EGFR staining was seen in the membrane of tumor cells in 30 of 40 (75%) tumor tissues (Figure 1) and 4 of 40 (10%) histopathologic tumor-free margins (Figure 2). On the other hand, 10% of histopathologic tumor-free margins were stained with EGFR. However, significant

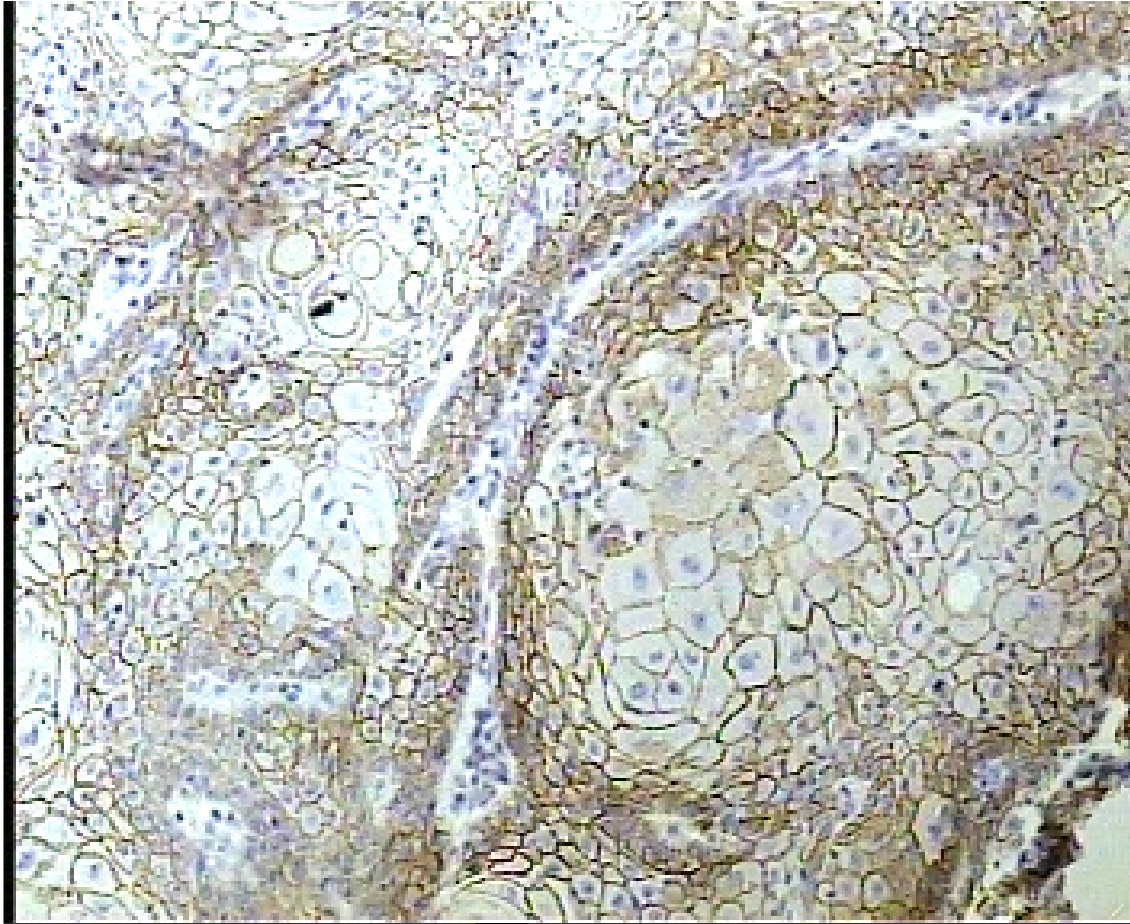


Figure 1. Strong EGFR staining in the membrane of the carcinoma cells.

difference was found in the EGFR staining between the tumor tissue and histopathologic tumor-free margins ($p = 0.01$). No significant differences were found between genders.

DISCUSSION

SCC is the most common oral cancer which originates from the dysplastic surface epithelium and is composed of islands of malignant squamous epithelial cells that have invaded the underlying connective tissue (Neville et al., 2008). Approximately, 40% treatment failure rate is seen in patients with OSCC, the most common cause of which is recurrence in the local or regional lymph nodes (Bilde et al., 2009; Hansen et al., 1998). Various research studies have reported recurrence in spite of having tumor-free surgical margins. In two studies conducted by Bilde et al. (2009), even when the surgical margin was diagnosed as tumor-free, a 30% recurrence rate was reported. In another similar study, Jelovac et al. (2009) reported a 10 to 30% recurrence rate. Molecular changes that might indicate early tumor development are seen in

normal surgical margins of tumors in oropharynx and larynx areas (California et al., 1996; Tabor et al., 2001).

EGFR, a receptor tyrosine kinase of ErbB family, can be hyperactive in a normal cell and provides signals for cellular proliferation, anti-apoptosis, angiogenesis and metastasis, which are the main characteristics of cancer (Sebastian et al., 2006). This receptor is abnormally activated in many epithelial tumors (Mendelson et al., 2006). In OSCC, this oncogene is associated with tumor invasion, increased metastasis to cervical lymph nodes and lower histological differentiation of the tumor (Oliveira et al., 2006). EGFR overexpression and lower disease-free survival were described by Grandis et al. (1998). In our study, EGFR overexpression was observed in 75% of tumor tissues. Other studies, such as Laimer et al. (2007) (73.42%) and Ryott et al. (2009) (72%), confirm EGFR overexpression in our study. In addition to tumor tissues, EGFR overexpression was observed in 10% of the histopathologically normal margins. In several studies, different markers have been investigated in histologically tumor-free margins and similar results have been reported. Jelovac et al. (2009) found p53 mutations and ErbB2 and c-Myc amplifications in tumor-free surgical

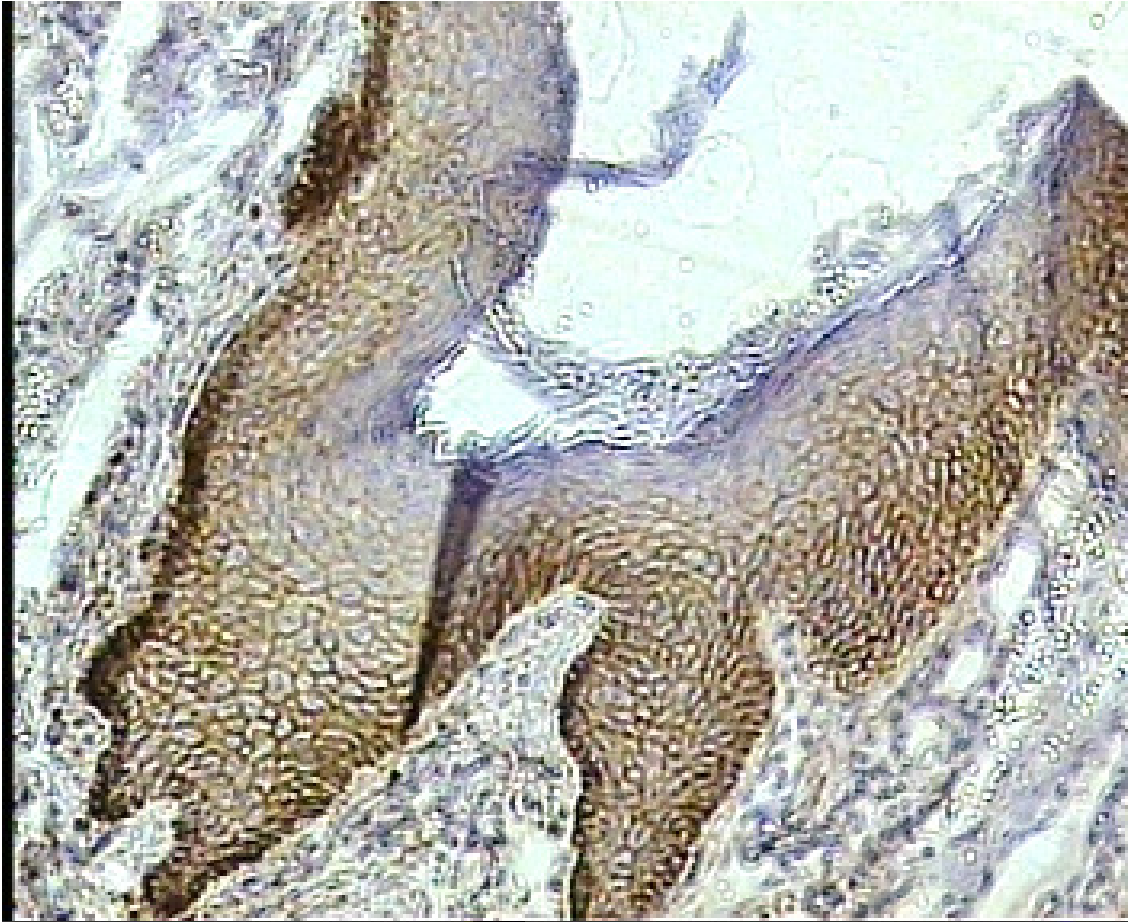


Figure 2. Strong EGFR membrane staining in the free margin cells.

margins in patients with OSCC. In similar studies, Van Houten et al. (2004) described p53 mutations and Bilde et al. (2009) found p53 and p16 expression in tumor-free surgical margins. One study showed that EGFR/SGLT1 coexpression may contribute to the growth and survival of OSCC (Hanabata, 2011). EGFR has been reported as an important target for cancer therapy and different types of EGFR inhibitors have been used in the treatment of various cancers, including gastric cancer, colorectal and lung cancers with EGFR overexpression (Hiraishi et al., 2008; Becker et al., 2006; Moroni et al., 2005). Hiraishi et al. (2008) have reported that EGFR inhibitor in combination with Cisplatin, a chemotherapy drug, is a useful strategy for treatment of patients with OSCC. Although, the expression of EGFR in tumor cells and marginal cells had significant difference, however the expression of EGFR in some marginal cells that seem normal in H&E staining depicted the presence of tumor cells in these margins. Therefore, our result supports the importance of using EGFR staining technique. A new technique such as dual 1.5 mm core tissue microarray is a valid, rapid, economical and tissue-saving way to study OSCC biopsies (Monteiro et al., 2010). However,

prognostic relevance is debatable and requires further standardization (Oliveira and Ribeiro-Silva, 2011).

In conclusion, assessment of tumor-free surgical margins by conventional histopathologic examination is not sufficient and detection of some oncogenes like EGFR may identify patients who are at a high risk of tumor recurrence and can benefit from anti-EGFR treatments.

ACKNOWLEDGEMENT

The authors are grateful to the Research Deputy of Tabriz Dental School for fully supporting this work.

REFERENCES

- Becker JC, Muller-Tidow C, Stole M, Fujimori T, Tidow N, Ilea A M, Brandits C, Tickenbrock L, Serve H (2006). Acetylsalicylic acid enhances antiproliferative effects of the EGFR inhibitor gefitinib in the absence of activating mutations in gastric cancer. *Int. J. Oncol.* 29: 615-623.
- Bilde A, Buchwald CH, Dabelsteen E, Therkildsen MH, Dabelsteen S (2009). Molecular markers in the surgical margin of oral carcinoma. *J.*

- Oral. Pathol. Med. 38: 72-78.
- Bilde A, Thode C, Therkildsen MH, Guldborg P, von Buchwald C, Dabelsteen E (2009). No mutation of p53 in the surgical margin of oral carcinomas. *Oral. Oncol.* 3(1): 98-99.
- Califano J, van der Riet P, Westra W, Nawrocz H, Clayman G, Piantadosi S, Corio R, Lee D, Greenberg B, Koch W, Sidransky D (1996). Genetic progression model for head and neck cancer: implications for field cancerization. *Cancer Res.* 56: 2488-2492.
- Grandis JR, Melhem MF, Gooding WE, Day R, Holst VA, Wagener MM, Drenning SD, Tweardy DJ (1998). Levels of TGF- α and EGFR protein in head and neck squamous cell carcinoma and patient survival. *J. Natl. Cancer. Inst.* 90: 824-832.
- Hansen HHS, Overgaard J, Jorgensen KE (1998). DAHANCA (Danish head and cancer)-20 years of cooperation. *Ugeskr. Laeger*, 160: 821-826.
- Hiraishi Y, Wada T, Nakatani K, Tojyo I, Matsumoto T, Kiga N, Negoro K, Fujita SH (2008). EGFR Inhibitor Enhances Cisplatin Sensitivity of Oral Squamous Cell Carcinoma Cell Lines. *Pathol. Oncol. Res.* 14: 39-43.
- Jelovac D, Konstantinovic V, Ilic B, Nesic B, Manasijevic M, Popovic B, Milasin J (2009). Analysis of p53, c-Myc and c-Erb B2 gene in histopathologically tumour-free surgical margins in patients with oral squamous cell carcinoma. *Int. J. Oral. Maxillofac. Surg.* 38: 428-429.
- Hanabata Y (2011).. Expression analysis of EGFR and SGLT1 in oral squamous cell carcinoma Kokubyo. *Gakkai. Zasshi.* 78: 12-8.
- Kusukawa J, Harada H, Shima I, Sasaquri Y, Kameyama T, Morimatsu M (1996). The significance of epidermal growth factor receptor and matrix metalloproteinase-3 in squamous cell carcinoma of the oral cavity. *Eur. J. Cancer. B. Oral. Oncol.* 32B: 217-221.
- Laimer K, Spizzo G, Gastl G, Obrist P, Brunhuber T, Fong D, et al (2007). High EGFR expression predicts poor prognosis in patients with squamous cell carcinoma of the oral cavity and oropharynx. *Oral. Oncol.* 43: 193-198.
- Mendelsohn J, Baselga J (2006). Epidermal growth factor receptor targeting. *Cancer.* 33: 369-385.
- Monteiro LS, Diniz-Freitas M, Garcia-Caballero T, Forteza J, Fraga M (2010). EGFR and Ki-67 expression in oral squamous cell carcinoma using tissue microarray technology. *J. Oral. Pathol. Med.* 39: 571-8.
- Moroni M, Veronese S, Benvenuti S, Marrapese G, Sartore-Bianchi A, Di Nicolantonio F, Gambacorta M, Siena S, Bardelli A (2005). Gene copy number for epidermal growth factor receptor (EGFR) and clinical response to antiEGFR treatment in colorectal cancer: a cohort study. *Lancet Oncol.* 6: 279-286.
- Neville BW, Damm DD, Allen CM, Bouquout JE (2008). *Oral and maxillofacial pathology*, 3rd ed, Saunders, Philadelphia. 409: 419-420.
- Oliveira LR, Ribeiro-Silva A (2011). Prognostic significance of immunohistochemical biomarkers in oral squamous cell carcinoma. *Int. J. Oral. Maxillofac. Surg.* 40:298-307.
- Oliveira S, Van Bergen en Henegouwen PM, Storm G, Schiffelers RM (2006). Molecular biology of epidermal growth factor receptor inhibition for cancer therapy. *Expert. Opin. Biol. Ther.* 6: 605-617.
- Ryott M, Wangsa D, Heselmeyer-Haddad K, Lindholm J, Elmberger G, Auer G, Lundquist A, Ried T, Munk-Wikland E (2009). EGFR protein overexpression and gene copy number increases in oral tongue squamous cell carcinoma. *E. J. C.* 45: 1700-1708.
- Sebastian S, Settleman J, Reshkin SJ, Azzariti A, Bellizzi A, Paradiso A (2006). The complexity of targeting EGFR signalling in cancer: from expression to turnover. *Biochem. Biophys. Acta.* 1766: 120-139.
- Sutton DN, Brown JS, Rogers SN, Vaughan ED, Woolgar JA (2003). The prognostic implications of the surgical margin in oral squamous cell carcinoma. *Int. J. Oral. Maxillofac. Surg.* 32: 30-34.
- Tabor MP, Brakenhoff RH, van Houten VM, Kummer JA, Snel MH, Snijders PJ, Snow GB, Leemans CR, Braakhuis BJ (2001). Persistence of genetically altered fields in head and neck cancer patients: biological and clinical implications. *Clin. Cancer Res.* 7: 1523-1532.
- Van Houten VMM, Leemans CR, Kummer JA, Dijkstra J, Kuik DJ, van den Breke MWM, Snow GB and Brakenhoff RH (2004). Molecular Diagnosis of Surgical Margins and Local Recurrence in Head and Neck Cancer Patients: A Prospective Study. *Clin. Cancer Res.* 10: 3614-3620.