

*Full Length Research Paper*

# Animal experiment of periodontal tissue remodeling in application of mini-implant anchorage for incisor intrusion

Yi Hu<sup>1</sup>, Shengchao Wang<sup>1\*</sup>, Yin Ding<sup>2\*</sup>, Liping Su<sup>3</sup> and Yan Wang<sup>1</sup>

<sup>1</sup>Department of Preventive Dentistry, School of Stomatology, The Fourth Military Medical University, Xi'an, Shaanxi, China.

<sup>2</sup>Department of Orthodontics, School of Stomatology, The Fourth Military Medical University, Xi'an, Shaanxi, China.

<sup>3</sup>Clinic of sanatorium for army retired cadres, The Fourth Military Medical University, Xi'an, Shaanxi, China.

Accepted 14 January, 2011

The aim of the present study is to observe the remodeling of periodontal tissue in application of mini-implant anchorage for incisor intrusion in dogs. Six adult male beagle dogs were used for the experiment. On the buccal site, a mini-implant was placed at the interalveolar septum between the maxillary second incisor and the third incisor on each side. The six maxillary incisors were connected together through the segmental wires and the individual bands were welded by brackets. An intrusive force (120 g) was applied by Ni-Ti coil spring on each side. An animal was sacrificed at the end of 0, 1, 3, 7, 14 and 30 days, respectively, after the activation. X-ray examination, HE staining and receptor activator of nuclear factor-kappa B ligand (RANKL) immunohistochemistry staining were performed afterwards. Then, we found that the periodontal tissue in apical area and crest of ridge remodeled most actively. In addition, the periodontal tissue on the buccal and the lingual sides also remodeled. In conclusion, the incisor teeth were not only intruded vertically but also showed rotation of the crown towards the labial side and the root towards the palatal side, by using mini-implants as anchorage. Besides, if the force applied was excessively large, it would cause apical root resorption.

**Key words:** Anchorage, mini-implant, incisor intrusion, and receptor activator of nuclear factor-kappa B ligand (RANKL).

## INTRODUCTION

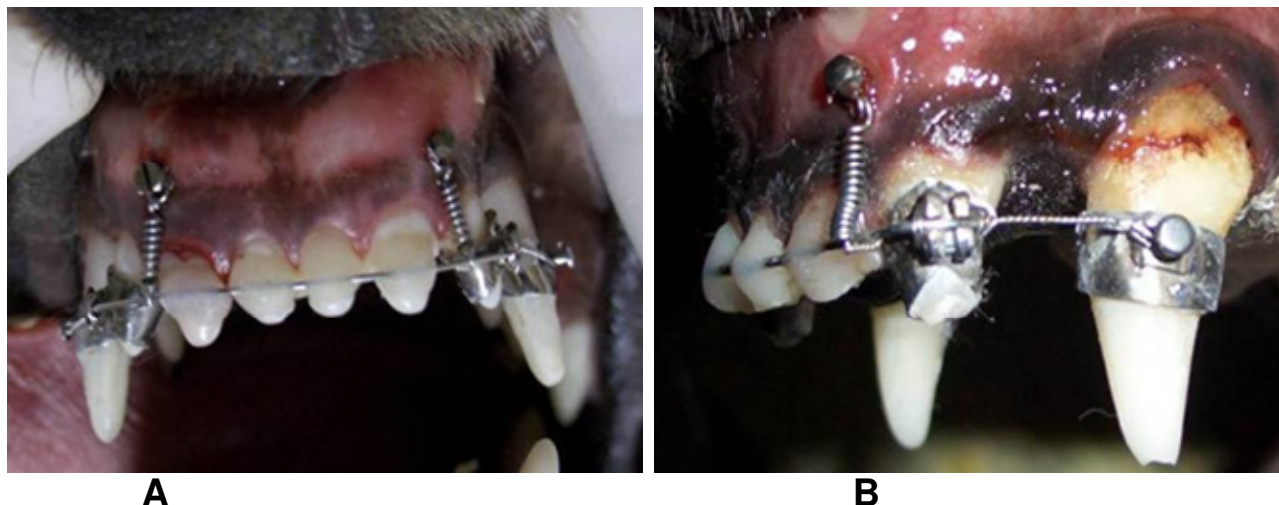
For long, many learners have been actively seeking a stable, reliable, comfortable and aesthetical way to control anchorage. As implantodontics progress, implants have proven to be new devices to be used during clinical application in the 1990s. The implementation of implant anchorage in clinical practice has shown favorable results of having complete control of anchorage. So far, a variety of implants have been used in clinical application. Out of these, the use of mini-implant anchorage system is the

most widespread. This is due to its ability to stabilize, ability to be used easily and it has little harm inflicted by it (Kanomi, 1997; Park, 2001).

In orthodontical clinical application, mini-implants can be used as an absolute anchorage to retract the anterior teeth as much as possible on patients who have severe crowding of teeth or bimaxillary protrusion (Kyung et al., 2003). On the other hand, mini-implants can be used to intrude the anterior teeth to treat patients with severe imbalance of alveolar heights showing symptoms such as gummy smile or deep overbite. Recently, several reports have described the clinical use of mini-implants to intrude the maxillary incisors (Kanomi, 1997; Ohnishi et al., 2005). These reports indicated that effective maxillary incisor intrusion was achieved with minimal side effects without patient cooperation by using miniscrews as anchorage.

\*Corresponding author. E-mail: wangshengchao@fmmu.edu.cn.  
Tel: +86 29 84776159. Fax: +86 29 84776159.

**Abbreviations:** HE, Hematoxylin and eosin; RANKL, nuclear factor-kappa B ligand; OD, optical density.



**Figure 1.** Placement of appliances. A: Using a local archwire to combine the six upper incisors to one; B, in order to control the torque, the third upper incisor and the upper canine were ligated on each side.

However, the process of periodontal tissue remodeling and the ways of teeth movement using mini-implant anchorage for incisor intrusion are still not completely clear. For this purpose, beagle dogs were used to observe the periodontal tissue remodeling using mini-implant anchorage for incisor intrusion, to further analyze the ways of teeth movement, so as to provide a reliable theory and guide for clinical application.

## MATERIALS AND METHODS

The protocols of this study were reviewed and approved by the Animal Ethics Committee of School of Stomatology, The Fourth Military Medical University. Two mini-implant (Zhongbang Titanium Biological Materials Co., Ltd, Xi'an, China) were inserted into each of six adult male beagle dogs (1.5 years old; 12 to 15 kg). The screws had a diameter of 1.5 mm and a length of 10 mm, and the way of activation mimicked the most probable situation in clinical orthodontics.

General anesthesia was applied to the beagle dogs using Su Mian Xin injecta (Changchun Military Medical Veterinary University, China). Six upper incisors were prepared and moulds were obtained for use. Individual bands were made on the moulds and brackets were welded on the bands. Then, the anterior section of the archwire was bended using stainless steel round wire with diameter of 0.5 mm.

After selective disinfection, a pathway was prepared using the guiding drill and a low-speed engine at 2500 rpm (rounds per minute) in a direction which was perpendicular to the bone surface (Sharawy et al., 2002), at the juncture of the attached gingiva and the mucosa, between the second upper incisor and the third upper incisor on both sides. Subsequently, the mini-implant was inserted with a hand manual driver (Chung et al., 2007).

General anesthesia was applied again after 24 h and individual bands were bonded on the third upper incisor and the upper canine on each side using glass ionomer cement (ShoFu Inc, Japan). The two ends of the local archwire were fixed onto the brackets of the upper third incisor on both sides. After which, the archwire was inserted into the prepared slots of the first upper incisors and the second upper incisors on both sides and was bonded using light-

cured resin, combining the six into one. In addition, in order to control the torque, the third upper incisor and the upper canine were ligated on each side to prevent the dental crowns from labial tilting. A force of 120 g was applied to each side by using the Ni-Ti coil spring (3M Corp, USA) which had one end fixed onto the mini-implant and another end onto the archwire between the second upper incisor and the third upper incisor to intrude the six upper incisors (Burstone, 1997; Figure 1).

Each animal was sacrificed at the end of the 0th, 1st, 3rd, 7th, 14th and 30th days after the activation; general anesthesia was applied to the beagle dogs. The bilateral arteria carotis communis were exposed and the tubes were inserted. After which, 40 g/l of neutral buffering paraform was perfused, the incisors and the surrounding alveolar bones were removed. X-ray examination was performed followed by external fixation. Kristensen's decalcifying fluid was used to decalcify the specimens. Dehydration in sequence was carried out. Finally, the specimens were imbedded in paraffin. The specimens were sliced along the anteroposterior axes and coronal direction of the teeth. Then, hematoxylin and eosin (HE) staining and receptor activator of nuclear factor-kappa B ligand (RANKL) immunohistochemistry staining were performed. At each set time, three slices were selected from the immunohistochemistry stain. Three visual fields were randomly chosen in each slice at the periodontal tissue found in the apical zone and the crest of ridge. Image-Pro Plus 6.0 software was used to measure the optical density (OD) value of the stained male sex cell intensity. After which, the mean of the measured values was used as the actual value of each set time.

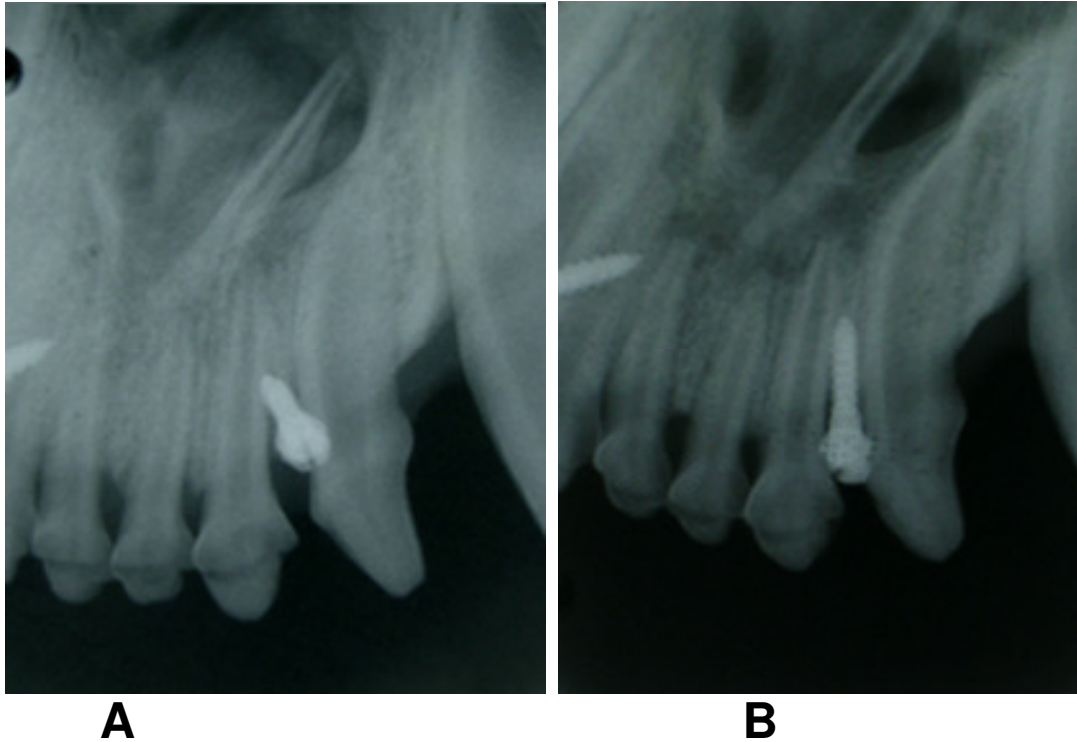
## Statistical analysis

The SPSS13.0 software was used to compare the OD values of each area and each set time (adopt one-way analysis of valance).

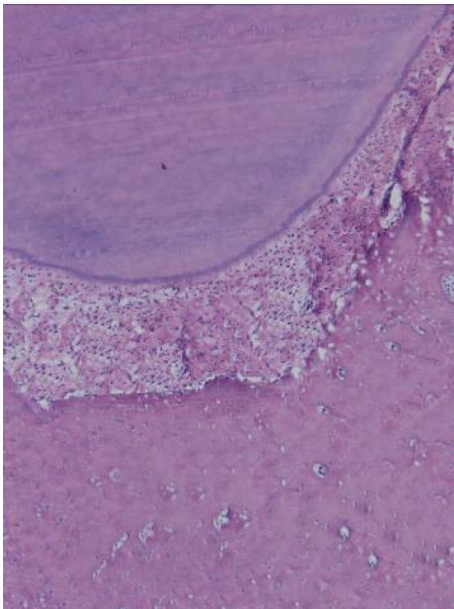
## RESULT

### General state of health of the animals

All six beagle dogs survived, with slight disorder of the masticatory function. There were no infections surround-



**Figure 2.** X-ray examination. A: At the end of the 0th day after the activation. B: At the end of the 7th day after the activation, an obvious shadow was observed at the alveolar bone at the apical zone.



**Figure 3.** The apical zone at the end of the 0th day, using HE staining  $\times 50$ . The bone margin at the apical zone was smooth.

ding the mini-implants and no case of loosening and abscission of the mini-implants and the appliances. According to the clinical standard of mobility, the mobility

of each experimented tooth was less than  $1^\circ$ .

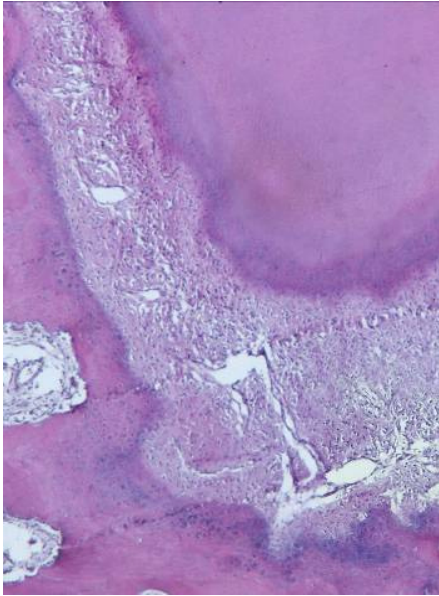
### X-ray examination

The most obvious change of the periodontal tissue was seen at the end of the 7th day after the activation. The cavity of parodontal membrane at the apical zone became widened and the lamina dura was not clearly seen. An obvious shadow was observed at the alveolar bone at the apical zone. The apex of the root of teeth was rounded and the bone margin of the crest of ridge was not clearly seen (Figure 2).

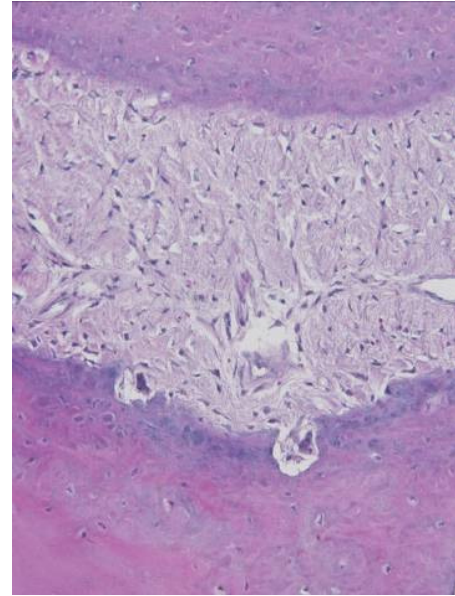
### Observation of the histomorphology of the periodontal tissue

The periodontal tissue at the apical zone and the crest of ridge remodeled most actively. At the end of the 0th day, the bone margin at the apical zone and the crest of ridge were smooth. No osteoclasts were seen (Figure 3). At the end of the 1st day after the activation, the periodontal ligament at the apical zone underwent hyalinization, partially. However, bone absorption was little. At the end of the 3rd day after the activation, the cavity of parodontal membrane at the apical zone became widened slightly. The number of blood vessels increased. The surface of the alveolar bone was uneven. The supracrestal fiber at





**Figure 4.** The apical zone at the end of the 7th day, using HE staining  $\times 50$ . The alveolar bone surface at the apical zone had formed a large amount of bone lacuna. The apex of the root of teeth also showed cementum lacunae.



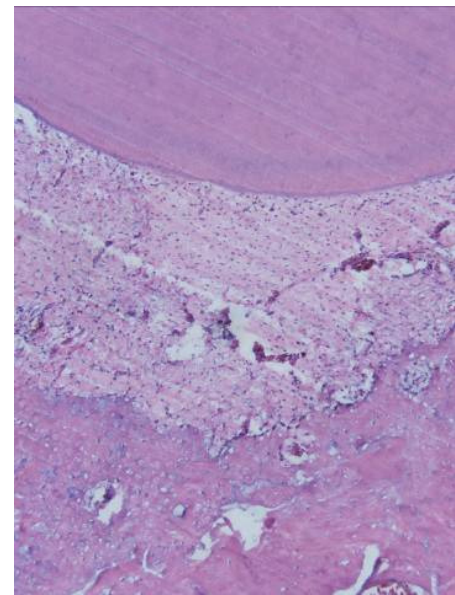
**Figure 5.** The apical zone at the end of the 7th day, using HE staining  $\times 200$ . Osteoclasts could be seen and bone absorption was active.

the dental cervix became thicker and tenser. Slight bone absorption was seen at the crest of ridge. At the end of the 7th day after the activation, the alveolar bone surface at the apical zone and the crest of ridge had formed a large amount of bone lacuna. Under high power lens, osteoclasts could be seen and bone absorption was active. Root absorption also occurred simultaneously at certain parts of the slices. The apex of the root of teeth showed cementum lacunae (Figures 4 and 5). At the end of the 14th day, the alveolar bones underwent renewal. At the bone lacuna, new bone deposition was observed. The osteoplasts aligned themselves at the surface of the new bones (Figure 6). At the end of the 30th day after the activation, the new bones distributed themselves in an island-like manner. New cementum was seen at the root tip.

In addition, the labial and palatal periodontal tissue of the incisor teeth also showed evident remodeling. Alveolar bone absorption was observed near to the dental cervix at the labial side and at the root tip which is 1/3 of the dental root at the palatal side. The surface of the alveolar bones formed bone lacuna. Osteoclasts could also be seen. New bone formation was observed at the root tip which is 1/3 of the dental root at the labial side and near the dental cervix at the palatal side.

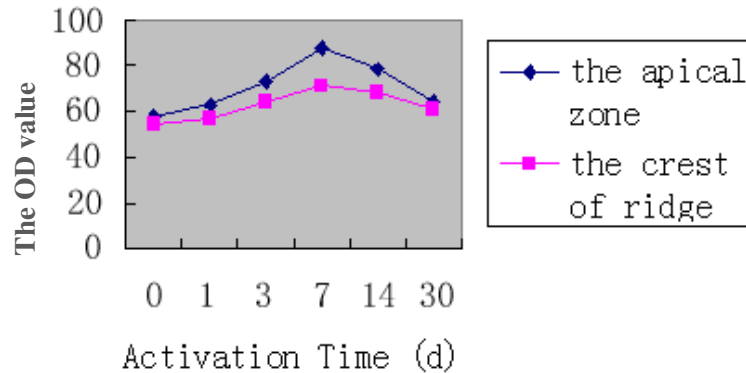
#### Results from RANKL immunohistochemistry staining

At the end of the 0th day, RANKL was tested weakly



**Figure 6.** The apical zone at the end of the 14th day, using HE staining  $\times 50$ . The osteoplasts aligned themselves at the surface of the new bones.

positive and stained brown, and was mainly distributed at the osteoblasts at the alveolar bone surface and a small amount of the endochylema of the desmocYTE of the periodontal membrane. From the 0th to the 7th day, as the number of days of activation increased, the strength of RANKL expression also increased. At the end of the



**Figure 7.** The OD value of RANKL expression in periodontal tissue at each time point of activation.

7th day after the activation, RANKL was tested the most positive, mainly concentrated at the apical zone and the crest of ridge, and was distributed at the osteoplasts and osteoclasts at the alveolar bone surface and the endochylema of the desmocyte of the periodontal membrane. At the 14th day after the activation, the strength of RANKL expression decreased. At the 30th day, RANKL expression was the weakest (Figure 7).

## DISCUSSION

Implants as a new method of anchorage control have been used widely in clinical treatment. They ease the treatment of intractable cases and shorten the time of therapy. Creekmore and Eklund, (1983) was the first person to implant the bone screw into the anterior nasal spine. He used the bone screw as anchorage to intrude the upper anterior teeth. After one year treatment, the upper anterior teeth had been intruded by 6 mm and the lingual root torque occurred by 25°. The bone screw did not loosen. After this, some learners used implants as anchorage to intrude the anterior teeth and results were favorable (Kanomi and Takada, 2000; Chunlei et al., 2004).

This study aimed to observe the periodontal tissue remodeling in application of mini-implant anchorage for incisor intrusion. By histological observation, the remodeling of the periodontal tissue occurred at the whole of the alveolar cavity in the process of intrusion. Bone absorption was the main observation, although there was also bone formation. The periodontal tissue at the apical zone and the crest of ridge of the incisor teeth remodeled most actively. The labial and palatal periodontal tissue also showed obvious remodeling. As the number of days of activation increased, the alveolar bones at the apical zone and the crest of ridge showed remodeling which became gradually more obvious. By HE staining, bone absorption at the end of the 7th day was observed to be the most active. The number of blood vessels of the

periodontal membrane increased obviously. Most absorption lacuna was seen at the edge of the alveolar bones and osteoclasts were also observed. Likewise, RANKL immunohistochemistry staining also showed strong positive results at the apical zone and the crest of ridge on the 7th day. RANKL was mainly distributed at the osteoplasts and osteoclasts at the alveolar bone surface and the endochylema of the desmocyte of the periodontal membrane. On the 14th day, the periodontal tissue underwent renewal. On the 30th day, new bones had basically formed. The strength of RANKL staining also decreased obviously.

The incisors experienced a force towards the root tip direction during application of mini-implant anchorage for incisor intrusion. Because of the extensive bone absorption at the apical zone where stress was concentrated, the teeth would be intruded. Therefore, the histological foundation on tooth intrusion is the remodeling of the alveolar bone at the apical zone. Moreover, the histological staining and RANKL immunohistochemistry staining all showed bone absorption at the crest of the ridge. The bone absorption and the gum shrinkage at this area can effectively minimize the severity of gummy smile caused by imbalance of the lip and the alveolus dentalis, giving the patients an aesthetical result.

According to the histological observation of the anteroposterior axes slices, alveolar bone absorption was observed near the dental cervix at the labial side and at the root tip which is 1/3 of the dental root at the palatal side, and new bone formation was observed at the root tip which is 1/3 of the dental root at the labial side and near the dental cervix at the palatal side. This showed that although the study applied anchorage control that prevented the dental crown from tilting to labial side, the incisor teeth were not only intruded vertically but also showed rotation of the crown towards the labial side and the root towards the palatal side. This was due to unilateral activation of force, and the direction of force was not through the centre of resistance of the teeth, and formed an angle with the direction of the long axis of

teeth. As a result, the component of the force in the labial direction formed caused the rotation of the crown towards the labial side and the root towards the palatal side. This phenomenon shows that in clinical application, if the rotation of incisors at the anteroposterior axes is to be avoided, an opposite moment of couple caused by the interaction between the rectangular wire and the slot of bracket must be applied to the teeth crown.

Moyers (1980) thought that teeth movement might cause absorption of the apex of root of teeth, especially during the process of anterior teeth intrusion. Due to the anatomical and the histological features of the tooth root and the periodontal tissue, teeth intrusion is likely to cause injury of the periodontal and odontal tissue. Thus, extra care should be given during teeth intrusion. Burstone (1977) thought that the most appropriate amount of force applied should be chosen during teeth intrusion, and the low-loading spring should be used to cause a continuous force. Graber's studies showed that in contrast to other types of teeth movement, a light continuous force could intrude the teeth more rapidly (Graber and Vanarsdall, 1985). Many documentary essays have different opinions regarding what is considered to be the most appropriate amount of force due to the variations in the experimental objects used and the methods in which the force is applied. In general, a force within the range of 15 ~ 50 g is appropriate to intrude single-rooted tooth. This study used mini-implants anchorage to intrude six incisor teeth of beagle dogs. Thus, a total of 240 g of force was applied, where each tooth received an average of 40 g of force. Histological observation reflected at the 7th day of activation, some parts of the surface of the apex of the root were uneven and some cementum lacunae were observed. This showed that the absorption occurred only in some of the apex of the root. Hence, we should pay more attention to the amount of force applied during clinical practice. As the teeth of the beagle dogs are much smaller than that of humans, according to the results of the experiment, an appropriate amount of force to intrude a human's incisor should be not more than 40 g, and the force applied during teeth intrusion should be continuous.

## Conclusions

The present study showed that the use of mini-implants to intrude the anterior teeth is effective and easy, and has little side effect. A light continuous force can intrude the teeth more rapidly and securely. It was also seen from the study that the incisor teeth were not only intruded vertically but also showed rotation of the crown towards the labial side and the root towards the palatal side, by using mini-implants as anchorage.

## REFERENCES

- Burstone CJ (1977). Deep overbite correction by intrusion. *Am. J. Orthod.* 72: p. 1.
- Chung KR, Kim SH, Kook YA (2007). The C-implant. In: Cope JB, eds. *OrthoTADs: The Clinical Guide and Atlas*. Dallas, Texas: Under Dog Media. pp. 245-256.
- Creekmore TD, Eklund MK (1983). The possibility of skeletal anchorage. *Clin. Orthod.* 17: 266-269.
- Graber TM, Vanarsdall RL (1985). *Orthodontics Current Principles and Techniques*. St Louis: Mosby Company. pp. 101-119.
- Kanomi R (1997). Mini-implant for orthodontic anchorage. *Clin. Orthod.* 31: 763-771.
- Kanomi R, Takada K (2000). Application of titanium mini-implant system for orthodontic anchorage [M]// Davidovitch Z, Mah J. *Biological mechanism of tooth movement and craniofacial adaption*. Birmingham (AI): EBSCO Media; pp. 253-258.
- Kyung HM, Park HS, Bae SM, Sung JH, Kim IB (2003). Development of Orthodontic micro-implants for intraoral anchorage. *Clin. Orthod.* 37: 321-328.
- Moyers RE (1980). *Handbooks of Orthodontics for the Student and General Practitioner*. London: Lea & Febiger. pp. 426-442.
- Ohnishi H, Yagi T, Yasuda K (2005). A mini-implant for orthodontic anchorage in a deep-overbite case. *Angle Orthod.* 75: 393-401.
- Park HS (2001). *The orthodontic treatment using micro-implant, the clinical application of MIA (micro-implant anchorage)*, Seoul-Narae Publishing.
- Sharawy M, Misch CE, Weller N, Tehemar S (2002). Heat generation during implant drilling: the significance of motor speed. *J. Oral Maxillofac Surg.* 60: 1160-1169.