

*Full Length Research Paper*

# Evaluation of acute toxicity and the effect of single injected doses of zerumbone on the kidney and liver functions in *Sprague Dawley* rats

Mohamed Yousif Ibrahim<sup>1</sup>, Ahmad Bustamam Hj Abdul<sup>1,2\*</sup>, Tengku Azmi Tengku Ibrahim<sup>3,4</sup>,  
Siddig Ibrahim Abdelwahab<sup>1</sup>, Manal Mohamed Elhassan<sup>1</sup> and M. M. Syam<sup>1</sup>

<sup>1</sup>UPM-MAKNA Cancer Research Laboratory, Institute of Bioscience (IBS), Universiti Putra Malaysia (UPM), Serdang, 43400, Selangor, Malaysia.

<sup>2</sup>Department of Bio-Medical Sciences, Faculty of Medicine and Health Sciences, Universiti Putra Malaysia (UPM), Serdang, 43400, Selangor, Malaysia.

<sup>3</sup>Microscopy Unit, Institute of Bioscience (IBS), Universiti Putra Malaysia (UPM), Serdang, 43400, Selangor, Malaysia.

<sup>4</sup>Department Of Pathology, Faculty of Veterinary Medicine, Universiti Putra Malaysia (UPM), Serdang, 43400, Selangor, Malaysia.

Accepted 29 April, 2010

Zerumbone is a natural monosesquiterpene isolated from the rhizomes of *Zingiber zerumbet* Smith. This bioactive compound has been previously shown to have chemo-preventive, anti-inflammatory and free radical scavenging activities. This study was designed to determine the median lethal dose (LD<sub>50</sub>) of zerumbone and the effect of three different single doses of zerumbone below the LD<sub>50</sub> on blood biochemistry, hepatic and renal histopathologies and lipid peroxidation in rats. In the LD<sub>50</sub> experiment, eight groups of animals (n = 5) were injected with various doses of zerumbone (100 - 3000 mg/kg, i.p). The animals were observed continuously for clinical change and mortality. Next, zerumbone was injected in single doses (100, 200 and 500 mg/kg) and sacrificed 24 h later. Probit analysis of this study showed that the LD<sub>50</sub> of this compound is 1.84 gm/Kg. Results from this study further suggested that single injected doses of zerumbone at 100 - 200 mg/kg had no ill effect towards the liver and renal tissues of female *Sprague Dawley* rats. To our knowledge, this paper is the first to report the toxicity effects of zerumbone in rodents.

**Key words:** Zerumbone, hepatotoxicity, nephrotoxicity.

## INTRODUCTION

Traditional use of plant origin remedies for treatment of diseases is widely practiced in developing countries. It is estimated that approximately 60% of the world's population relies on plants for medications. This percentage raise to more than 80% due to the expansion of populations in

developing world, easy access and escalating drug costs (Fransworth and Soejarto, 1994; Cordell, 2002). Plants, therefore, remain the major supplier of active drugs from natural sources (Ogbonnia et al., 2008), which include peptides, unsaturated long chain fatty acids, aldehydes, alkaloids, essential oils, phenols and water or ethanol soluble compounds. These compounds are potentially significant in therapeutic applications against diseases of diverse origins (Parvez et al., 2005; Khan et al., 2003). Most often, these herbal remedies recipes are used in most disease conditions over a long period of time without proper dosage monitoring and consequently toxic effects probably resulted from such prolonged usage. As such, the danger associated with the potential toxicity of such herbal therapies used over a long period of time

\*Corresponding author. E-mail: [ahmadbstmm@yahoo.com](mailto:ahmadbstmm@yahoo.com). Tel: 0060126894693-0060126143371 Fax: 0060389472101

**Abbreviations:** LD<sub>50</sub>, Median lethal dose; **ZER**, zerumbone; **BUN**, blood urea nitrogen; **ALT**, alanine aminotransferase; **ALP**, alkaline phosphatase; **GGT**, gamma-glutamyl transpeptidase; **MDA**, malondialdehyde; **H&E**, haematoxylin and eosin staining; **DMSO**, dimethyl sulfoxide.

necessitates in keeping abreast reported occurrences of renal and hepatic toxicities, consequential from intake of these medicinal herbs (Tédong et al., 2007).

*Zingiber zerumbet* Smith, a plant commonly found in Malaysia is known locally as 'lempoyang' that belongs to the Zingiberaceae family (Abdul et al., 2008). This plant is used traditionally as a cure for swelling, sores and loss of appetite. The volatile oils of the plant rhizomes have shown to contain zerumbone, humulene and camphene (Hasnah, 1991). Zerumbone (ZER), a monosesquiterpene, is recognized as a main compound of this plant. This phytochemical has potential use as an effective anticancer agent, possibly by its apoptosis-inducing and antiproliferative influences (Siddiq et al., 2009 Kirana et al., 2003). Moreover, cytotoxic effects of ZER have been reported to be selective toward cancer cells compared to normal cells (Abdul et al., 2008; Matthes et al., 1980). Furthermore, the compound was found to work synergistically with cisplatin in female cervical cancer mice, whereby it reduced the therapeutic dose of cisplatin used (Abdul et al., 2009). Therefore, the aim of this study was to determine the median lethal dose (LD<sub>50</sub>) and to evaluate the effect of single doses of zerumbone on the extent of tissue damages of liver and kidney in rats.

## MATERIALS AND METHODS

### Plant material

ZER was isolated using the hydrodistillation (steam distillation) method. Briefly, fresh rhizomes of *Z. zerumbet* were initially cleaned and sliced and later positioned in a glass flask containing distilled water and heated immediately using the heating mantel. The flask was immediately connected to special glassware (Dienstag) in order to collect vaporized steam containing the volatile oil. Then volatile oil was crystallized using circulating cool water. The crystals were collected and used. To obtain highly pure ZER, recrystallization was performed using hexane and the solution was left standing to evaporate. Thin layer chromatography was used to examine purification of ZER at each step. The crystals of ZER were kept for further chemical and pharmacological analyses.

### Acute toxicity study

The toxicity study was carried out using forty (40) female Sprague-Dawley rats weighing 150 - 200 g, procured from the Animal House Unit, Faculty of Veterinary Medicine, University Putra Malaysia (UPM) were used. The animals were randomly distributed into eight treated groups, containing five animals per group. They were allowed to acclimatize to the laboratory conditions for seven days before the experiment and they were allowed to fast by withdrawing food and water for 18 h. Each group of animals was injected with various doses of 100, 200, 500, 1000, 1500, 2000, 2500 and 3000 mg/kg body weight (b. wt.) of zerumbone intraperitoneally. Animals were provided with food and water immediately after injecting the compounds. The animals were observed continuously for the first 4 h and then each hour for the next 24 h and at 6 hourly intervals for the following 48 h after administering of the extract, to observe any death or changes in general behavior and other physiological activities (Shah et al., 1997; Bürger et al., 2005). Acute LD<sub>50</sub> of the compound was calculated using software for probit analysis.

### Effect of the single doses of zerumbone

Thirty (30) female rats (*Sprague Dawley*) of 180 - 200 g weight, procured from the Animal House Unit, Faculty of Veterinary Medicine, university Putra Malaysia (UPM) were used. The animal room at Institute Bioscience, UPM was maintained at a temperature of 25 ± 2°C with a 12 h light/dark cycle and a relative humidity of 50 - 60%. Free access to food and water was allowed at all times. Rats were housed five per cage in sterilized plastic cages using homogenized wood shavings as bedding. All experimental protocols held on animals were done according to regulations set by The Institutional Animal Care and Use Committee, Faculty of Medicine and Allied Sciences, UPM. Rats were divided into five groups:

- Group 1 animals were induced a single intraperitoneal injection of 500 mg/kg zerumbone.
- Group 2 animals were given a single intraperitoneal injection 200 mg/kg zerumbone.
- Group 3 animals were induced a single intraperitoneal injection 100 mg/kg zerumbone.
- Group 4 were being as a negative control.
- Group 5 was a positive control, animals were induced a single intraperitoneal injection cisplatin 10 mg/kg either DMSO as a vehicle for 24 injection.

The rats were killed under ether anesthesia; one hour after injection and blood, kidney and liver tissues were then collected. Trunk blood was collected and analyzed for serum creatinine and blood urea nitrogen (BUN) and ALT, ALP and GGT serum's levels. After bleeding, tissues samples were removed and fixed in 10% formaldehyde for histopathological examinations or stored at -80°C for measurement of malondialdehyde (MDA).

### Determination of kidney and liver functions

As indicators of kidney function, serum creatinine and BUN Levels were measured. Serum ALT, AST, ALP and GGT levels were measured to evaluate the liver function. All biochemical assays were performed spectrophotometrically using Hitachi-912 Autoanalyser (Mannheim, Germany) with kits were supplied by Roche Diagnostics (Mannheim, Germany). To obtain data with good sensitivity and validity, serum samples were analyzed in triplicates and blindly analyzed.

### Histopathological examinations

Animal tissues were fixed in 10% formalin. The kidney and liver samples were embedded in parafin and sectioning at 5 µm will stain with hematoxylin-eosin. All sections were examined using a photomicroscope (Olympus BH-2, Japan). The renal injury was based on degeneration of Bowman space and glomeruli, degeneration of proximal and distal tubuli, vascular congestion and interstitial edema. The criteria for liver injury were vacuolization of hepatocytes and pyknotic hepatocyte nuclei, activation of Kupffer cells and enlargement of sinusoids. Each specimen was score using a scale ranging from 0 - 3 (0: none, 1: mild, 2: moderate, and 3: severe) for each criterion. The total score was 9 for both kidney and liver. Histological examination and scoring were performed by an observer (F.E.) unaware of the treatment groups.

### Measurement of tissue MDA

Levels of MDA were assayed by the method of Satoh (Satoh, 1978). Briefly, 10% (weight/volume) homogenate of kidney and liver

**Table 1.** The number of female *Sprague Dawley* rats death following single injected doses of zerumbone.

Doses	Mortality	Survivors (%)	Total
0			
100		100	5/5
200		100	5/5
500		100	5/5
1000		100	5/5
1500	1	80	4/5
2000	2	60	3/5
2500	5	0	0/5
3000	5	0	0/5

**Table 2.** Rats serum kidney markers quantified following injected dose of cisplatin and single injected doses of zerumbone and control.

Enzymes	Doses	Mean	S.D
CREAT(mg/dL)	ZER500 mg/kg	74.17	24.06
	ZER 200 mg/kg	62.40	12.10
	ZER 100 mg/kg	66.00	20.57
	Corn Oil Negative Control	54.80	18.27
	Cisplatin 10 mg/kg	88.00*	22.30
BUN (mg/dL)	ZER 500 mg/kg	8.90	2.64
	ZER 200 mg/kg	6.54	2.12
	ZER 100 mg/kg	7.55	2.51
	Corn Oil Negative Control	6.16	2.01
	Cisplatin 10 mg/kg	10.27*	0.40

CREAT: creatinine; BUN: blood urea nitrogen; Data are means  $\pm$  SD of five rats for each group. \* Denotes significant difference at 0.05.

were made by 0.1 mol/L phosphate buffer was centrifuged at 4°C; 3500 rpm for 10 min. 0.2 mL supernatant was mixed with 0.67% 2-thiobarbituric acid (TBA) and 20% trichloroacetic acid solution, and heated in a boiling water bath for 30 min. The pink-colored chromogen was formed by the reaction of TBA with MDA will measure at 532 nm. The results were expressed as MDA nmol/mg protein. Contents of protein in the supernatant were measured by Lowry's method. (Yingjun et al., 2008).

#### Statistical analysis

All data are expressed as mean  $\pm$  SD. Histological data (Lesion Scoring) were compared using Kruskal- Wallis non-parametric test whilst other parameters were compared by one-way ANOVA followed by *post hoc* Tukey HSD multiple comparison tests. The type one error level was set at  $p < 0.05$  for all tests. All statistical analyses were performed using SPSS software (Chicago, IL, USA) version 16.0.

## RESULTS

### Acute toxicity

In the acute toxicity study (Table 1), 100% death was

observed for all the animals that received 2500 and 3000 mg/kg of the compound whilst 20 and 40% death for animals that received 1500 and 2000 mg/kg, respectively. There was no death in the animals that received 100, 200, 500 and 1000 mg/kg. The median acute toxicity ( $LD_{50}$ ) of the compound was determined to be 1.84 g/kg.

### Effect of single doses of zerumbone on the kidney and liver functions

Results of this study showed that single dose of 500 mg/kg zerumbone caused a significant reduction in renal and hepatic function, as characterized by remarkable increased in serum creatinine and (BUN) and ALT, ALP and GGT levels (Tables 2 and 6). These findings indicate strongly that single intra-peritoneal injection of 500 mg/kg of zerumbone caused abnormalities to the renal and hepatic functions.

Treatment with other single doses of 100 and 200 mg/kg zerumbone for 24 h however did not induce any abnormalities in the serum creatinine and (BUN) and

**Table 3.** Lesions scoring scored in rat kidney tissues of injected cisplatin and single injected doses of zerumbone and control.

Lesions	Single doses	Mean	S.D
Degeneration of Bowman space and glomeruli	ZER 500 mg/kg	1.27	0.41
	ZER 200 mg/kg	0.57	0.19
	ZER 100 mg/kg	0.70	0.22
	Cisplatin 10 mg/kg	3.00*	1.00
	Corn Oil Negative Control	0.00	0.05
Degeneration of proximal and distal tubuli	ZER 500 mg/kg	1.10	0.548
	ZER 200 mg/kg	0.62	0.20
	ZER 100 mg/kg	0.93	0.31
	Cisplatin 10 mg/kg	3.00*	1.00
	Corn Oil Negative Control	0.00	0.05
Vascular congestion and interstitial edema	ZER 500 mg/kg	1.41	0.41
	ZER 200 mg/kg	0.33	0.11
	ZER 100 mg/kg	0.44	0.21
	Cisplatin 10 mg/kg	3.00*	1.00
	Corn Oil Negative Control	0.00	0.05

Data are means  $\pm$  SD of five rats for each group. \* Denotes significant difference at 0.05

**Table 4.** Malondialdehyde (MDA) levels determined in rat kidney tissues following injected dose of cisplatin and single injected doses of zerumbone and control.

Treatments	Mean	SD
ZER 500 mg/kg	1.01	0.20
ZER 200 mg/kg	0.62	0.12
ZER 100 mg/kg	0.83	0.21
Corn Oil Negative Control	0.50	0.01
Cisplatin 10 mg/kg	2.76*	0.16

Data are means  $\pm$  SD. of five rats for each group. \* Significant difference at 0.05.

ALT, ALP and GGT levels. In addition to this, DMSO and corn oil did not induce any abnormal changes in serum levels of kidney and liver enzymes (Tables 2 and 6).

#### Effect of single doses of zerumbone on qualitative and quantitative histopathology and clinical observation

No death was observed amongst all animal groups during the period of this study. Tissue samples were obtained and observed under microscopy. Tissues in the single dose of zerumbone 500 mg/kg administered animals have shown cellular damage. Renal damage was recognized by severe degeneration in glomeruli and tubuli (both

proximal and distal tubuli) while hepatic damage was recognized by severe activation of Kupffer cells, degeneration, and moderate enlargement of sinusoids. In the single dose of 200 mg/kg zerumbone treated animals, the morphology of the tissues is near normal. The morphological feature of the tissues from the 100 mg/kg zerumbone injected animals is similar to the control morphology, which revealed normal and regular appearance of glomeruli and tubuli and normal hepatocytes, Kupffer cells and sinusoids (Figures 1 and 2A - G). With reference to the morphological appearance of the tissues from 500 mg/kg zerumbone injected animals, their quantitative lesions scoring mean is statistically higher than that of normal control group ( $p < 0.05$ ). 100 and 200 mg/kg zerumbone administration did not show microscopic lesion scoring effectively ( $p < 0.05$ ) (Tables 3 and 6).

Total mean scoring, degeneration of Bowman space and glomeruli, degeneration of proximal and distal tubuli, vascular congestion and interstitial edema and sinusoidal dilatation, activation of kupffer cells and vacuolization was used as indices to evaluate the lesions quantitatively. In respect to these indices, the highest mean was observed in the single dose of 500 mg/kg zerumbone and 10 mg/kg cisplatin treated animal groups.

#### Effect of single doses of Zerumbone on MDA level

Lipid peroxidation in the tissues was evaluated using measurements of MDA levels quantitatively. In 500 mg/kg

**Table 5.** Effect towards rats serum liver function enzymes following injected dose of cisplatin and single injected doses of zerumbone and control.

Enzymes	Treatments	Mean	S.D
ALT	ZER 500 mg/kg	88.98	22.3
	ZER 200 mg/kg	63.96	18.00
	ZER 100 mg	62.77	18.20
	Corn Oil Negative Control	60.34	19.05
	CISPLATIN 10 mg/kg	144.10*	34.00
ALP	ZER 500 mg/kg	272.83	66.41
	ZER 200 mg/kg	250.40	42.00
	ZER 100 mg/kg	248.67	42.09
	Corn Oil Negative Control	243.80	67.52
	CISPLATIN 10 mg/kg	318.00*	71.73
GGT	ZER 500 mg/kg	3.33	0.52
	ZER 200 mg/kg	2.06	0.35
	ZER 100 mg/kg	1.83	0.61
	Corn Oil Negative Control	1.00	0.21
	CISPLATIN 10 mg/kg	5.00*	1.30

ALT: Alanine aminotransferase; ALP: Alkaline Phosphatase; GGT: Gamma-glutamyl transpeptidase  
Data are means  $\pm$  SD of five rats for each group.

\* Denotes significant difference at 0.05.

**Table 6.** Lesions scoring scored in rat liver tissues of injected dose of cisplatin and single injected doses of zerumbone and control.

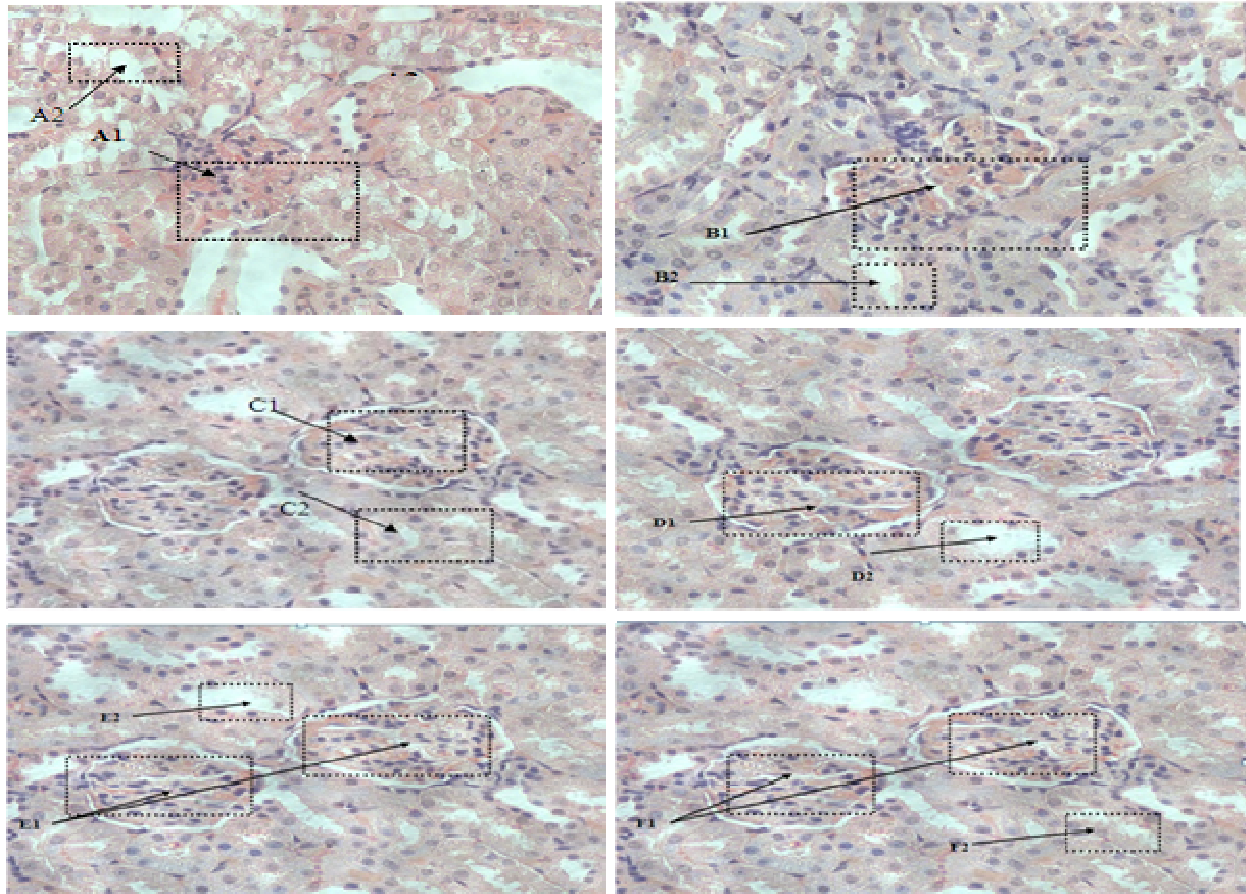
Lesions	Doses	Mean	S.D
Activation of Kupffer cells	ZER 500 mg/kg	2.00	0.45
	ZER 200 mg/kg	0.32	0.06
	ZER 100 mg/kg	0.29	0.09
	Corn Oil Negative Control	0.20	0.05
	Cisplatin 10 mg/kg	3.00*	1.00
Sinusoidal dilatation	ZER 500 mg/kg	1.20	0.40
	ZER 200 mg/kg	0.83	0.21
	ZER 100 mg/kg	0.79	0.20
	Corn Oil Negative Control	0.40	0.12
	CISPLATIN10 mg/kg	3.00*	0.90
Vacuolization	ZER 500 mg/kg	1.90	0.61
	ZER 200 mg/kg	1.09	0.33
	ZER 100 mg/kg	1.07	0.35
	Corn Oil Negative Control	0.00	0.00
	CISPLATIN 10 mg/kg	3.00*	0.08

Data are means  $\pm$  SD of five rats for each group. \* Denotes significant difference at 0.05.

zerumbone and cisplatin injected animals, MDA level is significantly higher compared to normal control ( $P < 0.05$ ). Treatment with the single doses of 100 and 200 mg/kg zerumbone did not show any abnormal levels of MDA (Tables 4 and 7).

## DISCUSSION

Herbal medicines are now being received recently as alternatives to synthetic pharmaceutical products, thus leading to an increased to their demand as natural

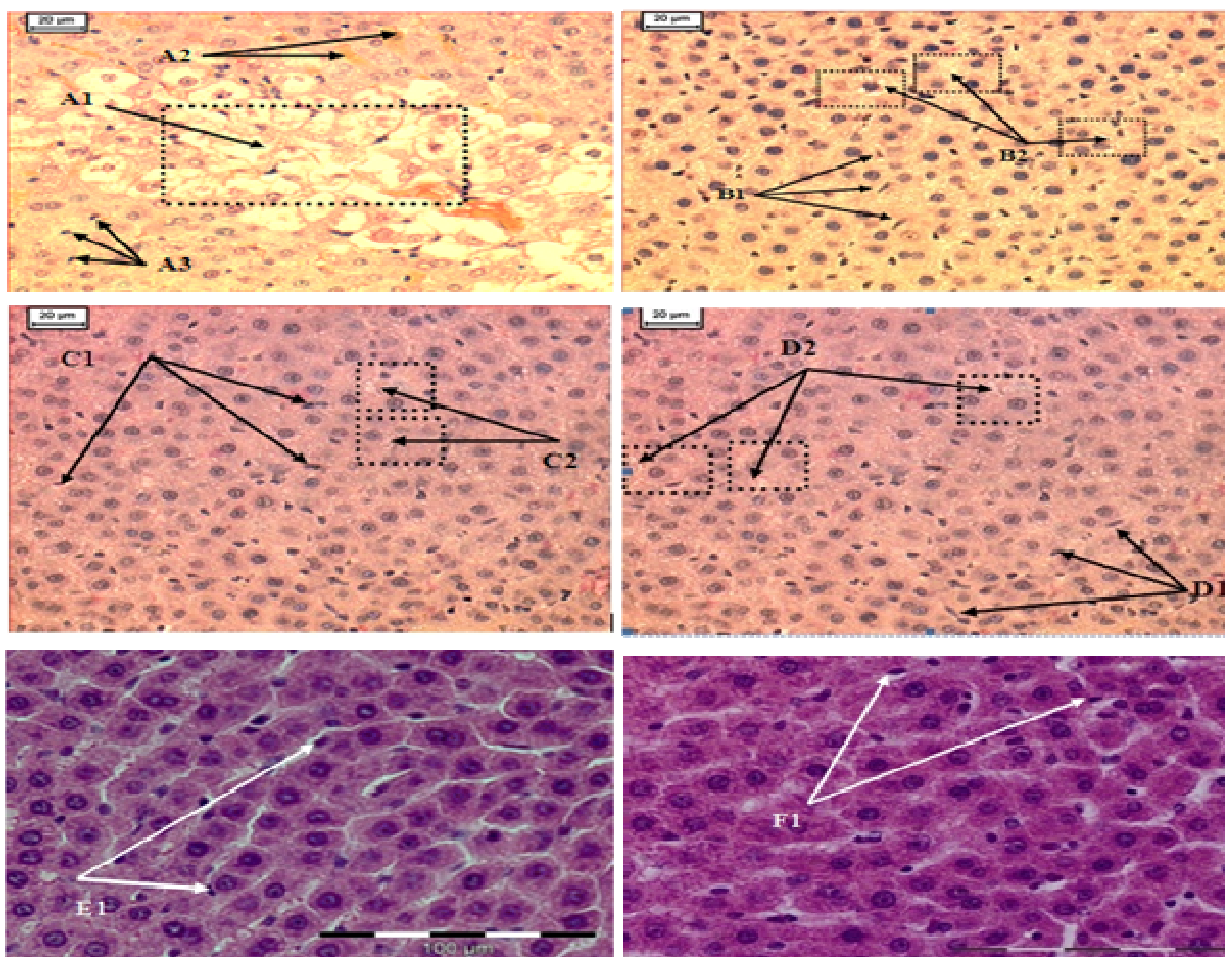


**Figure 1.** Photomicrographs of rat kidney tissue samples of injected 10 mg/kg cisplatin, 100, 200 and 500 mg/kg ZER-treated animal groups. Control groups (E), (F): normal histological appearance of kidney. 10 mg/kg cisplatin group (A): severe glomerular congestion and degeneration, dilatation in Bowman's space, and degeneration in tubular cells in kidney. 200 and 100 mg/kg ZER Group (C), (D): normal histological appearance of kidney. 500 mg/kg ZER Group (B): Moderate degeneration of Bowman space and glomerular congestion. Moderate tubular degeneration in tubular cell: Hematoxylin–eosin staining, Original magnifications:  $\times 200$ . **A**-CISPLATIN 10 mg/kg. **A1** Severe degeneration of Bowman space and glomerular congestion. **A2**- Severe degeneration in tubular cells. **B**-ZER 500 mg/kg. **B1**- Moderate degeneration of Bowman space and glomerular congestion. **B2**- Moderate degeneration of tubular cells. **C**-ZER 100 mg/kg. **C1**- Normal histological appearance of Bowman space and glomeruli. **C2**- Normal histological appearance of tubular cells. **D**-ZER 200 mg/kg control. **D1**- Normal histological appearance of Bowman space and glomeruli. **D2**- Normal histological appearance of tubular cells. **E**- Negative control DMSO. **E1**- Normal histological appearance of Bowman space and glomeruli. **E2**- Semi normal histological appearance of tubular cells. **F**-Negative control corn oil. **F1**- Normal histological appearance Bowman space and of glomeruli. **F2**- Normal histological appearance of tubular cells.

medicine (Mythilypriya et al., 2007). World Health Organization (WHO) survey indicated that about 70 - 80% of the world's populations rely on traditional medicine, mainly herbal source, as their primary healthcare (Dyson, 1998; Chan, 2003). Although medicinal plants produced several biological activities that are useful, very few or none is known regarding their toxicities in humans. As such, the inclusion of toxicological evaluation at preclinical stage will assure its safe usage in humans as a medicine (Tomlinson and Akerele, 1998). Similarly to this context and in the present study, the natural compound zerumbone isolated from *Z. zerumbet*, belonging to the Zingiberaceae plant family was subsequently evaluated toxicologically in rats, principally for safe usage intended as a future

medicine in humans.

Several dietary ingredients of the Zingiberaceae family have been reported and their biological activities elucidated (Aggarwal and Shishodia, 2006; Surh, 1999). In this respect, zerumbone is used initially as an anti-inflammatory adjuvant for sprain and in treating human ailments (Chiu and Chang, 1986). Several reports on the bioactivities of zerumbone have been recently reported, which included anticarcinogenesis (Takada et al., 2005), anti-inflammation (Murakami et al., 2003) and most recently from our own laboratory, zerumbone's anticancer effect on cervical tissues (Abdul et al., 2009). However, despite several evidences of its biological activities and therapeutic benefits, there has been no reported



**Figure 2.** Photomicrographs of liver samples of the control, cisplatin, and 100, 200, 00 mg/kg ZER treated animal groups. Control group (E), (G): normal histological appearance of liver. Cisplatin group (A): severe degenerated hepatocytes sever haemorrhage inside hepatocytes and increased number of activated Kupffer cells. 100 mgZER group (D) mild degenerated hepatocytes and increased number of activated Kupffer cells. 200 mgZER group (C) mild degenerated hepatocytes and increased number of activated Kupffer cells: Hematoxylin–eosin staining, original magnifications:  $\times 200$ . A-CISPLATIN 10 mg \kg. A1 -Severe degenerated hepatocytes (vacuolization). A2- Severe haemorrhage inside hepatocytes. A3- Increased number of activated Kupffer cells. B-ZER 500 mg/kg. B1- Increased number of activated Kupffer cells. B2- Mild degenerated hepatocytes (vacuolization). C- ZER 200 mg/kg. C1- Increased number of activated Kupffer cells. C2- Mild degenerated hepatocytes (vacuolization). (Semi normal histological appearance of liver). D- ZER 100 mg\ kg. D1- Increased number of activated Kupffer cells. D2- Mild degenerated hepatocytes (vaiocuolizatn). (Near normal histological appearance of liver). E-DMSO negative control. E1- Normal number of activated Kupffer cells. Normal histological appearance of liver. F- Corn oil negative control. F1- Normal number of activated Kupffer cells; normal histological appearance of liver.

toxicological evaluation performed to this compound *in vivo*.

Toxicologically, acute toxicity investigation is the initial step towards toxicological analysis of herbal drugs. In relation to this, this report is the first to provide scientific data on acute toxicity effect of zerumbone *in vivo*. In this regard, our data showed that a single dose given intraperitoneally up to 1000 mg/kg in rats did not produce any mortality. The  $LD_{50}$  of zerumbone is found to be 1.84 g/kg. Base on the classification of Loomis and Hayes (1996), this suggests that substances having  $LD_{50}$  between 500 and 5000 mg/kg bodyweight are regarded as being

slightly toxic and practically non-toxic, the present findings showed that zerumbone safety falls between these two values of being almost practically non-toxic.

Single doses effect of zerumbone on the kidney and liver function was carried out to evaluate the nephrotoxicity and hepatotoxicity of this compound on female *Sprague Dawley* rats. During kidney and liver cell damaged, creatinine and blood urea nitrogen (BUN) together with ALT, ALP and GGT enzymes leak out, causing blood levels of these chemical components and enzymes to rise. Increased levels of these chemical components and enzymes in blood are considered good

**Table 7.** Malondialdehyde (MDA) levels determined in rat liver tissues following injected dose of cisplatin and single injected doses of zerumbone and control.

Treatments	Mean	SD
ZER 500 mg/kg	5.38	1.56
ZER 200mg/kg	2.84	0.91
ZER 100mg/kg	2.60	0.84
Corn Oil Negative Control	2.74	0.89
Cisplatin10mg/kg	6.81*	2.06

Data are means  $\pm$  SD. of five rats for each group. \* Significant difference at 0.05.

indicators for kidney and liver cell damage. In this present study, our result showed significant difference in plasma creatinine and blood urea nitrogen (BUN) and ALT, ALP and GGT enzymes between single injected dose of 500 mg/kg zerumbone to 10 mg/kg cisplatin groups ( $p < 0.05$ ). The later showing higher blood levels of both kidney and liver biomarkers comparatively to the injected zerumbone group.

In addition, our findings also indicate no nephrocellular and hepatocellular injury in the other single injected doses of 100 and 200 mg/kg zerumbone. This was later confirmed by histological examinations of tissue sections using H & E staining of light microscope and MDA levels in rat's kidney and liver tissues. Results from this study suggested that single injected doses of zerumbone at 100 - 200 mg/kg had no ill effect on the kidney and liver tissues of female *Sprague Dawley* rats.

## Conclusion

The LD<sub>50</sub> value (1.84 g/kg) obtained was a clear indication that zerumbone could be safe for use in one dose treatment. The study also revealed that the compound at low and moderate doses did not incite toxic effects in the animals' tissues. On the contrary, higher doses of 500 mg/kg zerumbone induced nephrocellular and hepatocellular damage, leading to renal and hepatic failure. Our study also showed that the liver and kidney function tests are useful markers to monitor during treatment in using high doses of injected zerumbone.

## ACKNOWLEDGEMENTS

The authors are grateful and would like to express their deepest appreciations to Dr. Huda Yahia Hamid, a Clinical Veterinarian Histopathologist, in evaluating the histopathology slides. The authors would also like to express their appreciation to The National Cancer Counsel of Malaysia (MAKNA) and Research University Grant Scheme (RUGS) for providing financial supports in this study.

## REFERENCES

- Abdul AB, Adel SA, Nirmala DT, Siddig IA, Zetty NZ, Sharin M, Syam M (2008). Anticancer Activity of Natural Compound (Zerumbone) Extracted from Zingiber Zerumbet in Human HeLa Cervical Cancer Cells. *Int. J. Pharmacol.* 4(3): 160-186
- Abdul AB, Siddig IW, Johari J, Adel SA, Manal MT (2009). Combination of zerumbone and cisplatin to treat cervical intraepithelial neoplasia in female Balb/c mice. *Int. J. Gynecol. Cancer.* 19(6):1004-1010.
- Aggarwal BB, Shishodia S (2006). Molecular targets of dietary agents for prevention and therapy of cancer. *Biochem. Pharmacol.* 71: 1397-1421.
- Bürger C, Fischer DR, Cordenunzi DA, Batschauer De Borba AP, Filho VC, Soares dos Santos AR (2005). Acute and subacute toxicity of the hydroalcoholic extract from *Wedelia paludosa* (*Asteraceae*) in mice. *J. Pharm. Sci.* 8(2):370-373. ([www.cspscCanada.org](http://www.cspscCanada.org)).
- Chan K (2003). Some aspects of toxic contaminants in herbal medicines. *J. Chemosphere*, 52: 1361-1371.
- Chiu NY, Chang KH (1986). Zingiberaceae. Taipei: SMC Publishing Inc.
- Cordell GA (2002). Biodiversity and drug discovery- a symbiotic relationship. *Phytochemistry*, 55: 463-480.
- Dyson A (1998). Discovering Indigenous Healing Plants of the Herb and Fragrance Gardens at Kirstenbosch National Botanical Garden. National Botanical Institute, Printing Press, Cape Town.
- Fransworth NR, Soejarto DD (1994). Potential consequence of plant extinction in the United States on the current and future availability of prescription drugs. *Econ. Bot.* 39: 231-240.
- Hasnah MS (1991). Chemical constituent of some medicinal plants of Zingiberaceae. Medicinal products from tropical rain forest: Proceedings of the Conference, Forest Research Institute Malaysia. Kuala Lumpur. 2: 299-304.
- Khan M, Kibara M, Oinoloso B (2003). The cytotoxicity and chemical constituents of the hexane fraction of *Typhonium flagelliforme* (Araceae). PMID:11483390. *J. Ethnopharmacol.* 77: 129-131.
- Kirana C, McIntosh GH, Record IR, Jones GP (2003). Antitumor activity of extract of *Zingiber aromaticum* and its bioactive sesquiterpenoid zerumbone. *Nutr. Cancer*, 45(2): 218-225.
- Loomis TA, Hayes AW (1996). *Loomis's Essentials of Toxicology*, fourth ed. Academic Press, California.
- Matthes HWD, Luu B, Ourisson G (1980). Cytotoxic components of *Zingiber zerumbet*, *Curcuma zedoaria* and *C. domestica*. *Phytochemistry*, 19(12): 2643-2650.
- Murakami A, Hayashi R, Takana T, Kwon KH, Ohigashi H, Safitri R (2003). Suppression of dextran sodium sulfate-induced colitis in mice by zerumbone, a subtropical ginger sesquiterpene, and nimesulide: separately and in combination. *Biochem. Pharmacol.* 66: 1253-1261.
- Mythilypriya R, Shanthi P, Sachdanandam P (2007). Oral acute and subacute toxicity studies with Kalpaamruthaa, a modified indigenous preparation on rats. *J. Health Sci.* 53(4): 351-358.
- Ogbonnia S, Adekunle AA, Bosa MK, Enwuru VN (2008). Evaluation of acute and subacute toxicity of *Alstonia congensis* Engler



- (*Apocynaceae*) bark and *Xylopiya aethiopica* (Dunal) A. Rich (*Annonaceae*) fruits mixtures used in the treatment of diabetes Afr. J. Biotechnol. 7(6): 701-705.
- Parvez M, Mahboob HK, Zahurul I, Shek MH (2005). Antimicrobial activities of the petroleum ether, methanol and acetone extracts of *kaempferia galangal*. rhizome. J. Life Earth Sci. 1: 25-29.
- Satoh K (1978). Serum lipid peroxide in cerebrovascular disorders determined by new colorimetric method. Clin. Chim. Acta. 90: 37-43.
- Shah Ayub MA, Garg SK, Garg KM (1997). Subacute toxicity studies on Pendimethalin in rats. Indian J. Pharm. 29: 322-324.
- Surh YJ (1999). Molecular mechanisms of chemopreventive effects of selected dietary and medicinal phenolic substances. Mutation Research—Fund. Mol. Mechan. Mutat. 428: 305-327.
- Tomlinson TR, Akerele O (1998). Medicinal Plants their Role in Health and Biodiversity. University of Pennsylvania Press, Philadelphia.
- Yingjun L, Xiuqiang L, Chunwei L, Gexin L, Yaping J, Hao Tang. 2008. Selection of agents for prevention of cisplatin-induced hepatotoxicity. Pharmacol. Res. 57: 125-131.
- Takada Y, Murakami A, Aggarwal BB (2005). Zerumbone abolishes NF- $\kappa$ B and I $\kappa$ B $\alpha$  kinase activation leading to suppression of antiapoptotic and metastatic gene expression, upregulation of apoptosis, and down regulation of invasion. Oncogene, 24: 6957-6969.
- Tédong L, Dzeufiet PDD, Dimo T, Asongalem EA, Sokeng SN, Flejou JF, Callard P, Kamtchouing P (2007). Acute and Subchronic toxicity of *Anacardium occidentale* Linn (*Anacardiaceae*) leaves hexane extract in mice. Afr. J. Tradit. Altern. Med. 4(2): 140-147.