

*Full Length Research Paper*

# Induction of mammary gland tumor in female Sprague-Dawley rats with LA7 cells

Roghayeh Abbasalipourkabir<sup>1\*</sup>, Arash Dehghan<sup>1</sup>, Aref Salehzadeh<sup>1</sup>, Fatemeh Shamsabadi<sup>2</sup>  
and Rasedee Abdullah<sup>2</sup>

<sup>1</sup>Faculty of Medicine, Hamadan University of Medical Science, Iran.

<sup>2</sup>Faculty of Veterinary Medicine, Universiti Putra Malaysia, Malaysia.

Accepted 4 June, 2010

**The current methods for tumor induction in breast cancer research animal models are time-consuming, hazardous, expensive, sometimes irreproducible and inconvenient. We successfully developed a new, simple and cost-effective method in developing solid mammary gland tumor in female Sprague-Dawley rat using LA7 rat mammary tumor cells. Tumors developed in 7- 8 weeks old rats within 6 to 8 days of subcutaneous injection of LA7 cells into the mammary gland pad. Tumor size increased exponentially for four weeks. Histopathology examination confirmed that the induced tumors were adenocarcinomas. Evaluation of blood enzymes showed significantly higher ( $P < 0.005$ ) serum alkaline phosphatase (ALP) and lactate dehydrogenase (LDH) in tumor-bearing than in normal rats. This LA7 cell-induced rat mammary gland tumor model may be useful for studies in breast cancer drug or nutraceutical research and development.**

**Key words:** LA7 cell, mammary gland tumor, Sprague-Dawley rat.

## INTRODUCTION

Due to the importance of carcinogenicity experiment in cancer research studies, many attempts have been devoted to the development of new methods for transduction and evolution of tumor in animals (Salami and Karami, 2003). The induction of mammary gland tumors issue in animal has been a controversial and much disputed subject in cancer research. Immunodeficient and nude mice are normally used for transplantation and xenografts in cytotoxicity studies of various chemotherapy drugs in malignancies (Kim et al., 2006); but they are inconvenient since they are expensive, need to be kept under sterile conditions and have a short life-span.

Recently, there has been an increasing interest in carcinogenic chemicals such as 7,12-dimethylbenz(a)anthracene (DMBA) and N-methyl-N-nitrosourea (NMU) to induce mammary carcinoma in rat models for the study of human breast cancers (salami and karami, 2003). However, the main problems with these applications are their dangerous and time-consuming labors.

However, far too little attention has been paid to rat than mouse and only limited types of transgenic rats have been developed for carcinogenic study (Jacob et al., 2004). In addition, the benefit of rat animal model is its simplicity and different induction methods, transplantation ability and resemblance to human breast cancer in their hormone sensitivity and histology. There is no other animal tumor comparable to these models because of the similarity in the function and structure of certain rat mammary tumors to hormone-sensitive human breast cancer (Young and Hallowers, 1973).

Mammary gland LA7 cells were isolated in 1979 from a DMBA-induced mammary adenocarcinoma in rats (Dulbecco et al., 1979; Bennet et al., 1978). The self-renewal properties of stem cell have showed that these cells are able to differentiate into all kinds of mammary gland cell lineages and develop heterogeneous tumors in (NOD)-SCID mice at a single-cell level (Zucchi et al., 2007). Characterization of a single-cell with the potential of tumor-induction may contribute to the improvement of a suitable therapy.

The purpose of this paper is to design an easy, cost-effective, rapid induction, and readily applied rat mammary

\*Corresponding author. E-mail: [abbasalipourkabir@yahoo.com](mailto:abbasalipourkabir@yahoo.com).

gland tumor model for breast cancer study, using the LA7 cell line.

## MATERIALS AND METHODS

### Animals and management

The experimental procedure was approved by the Institutional Animal Care and Use Committee (IAUC) of Faculty of Veterinary Medicine at University Putra Malaysia (UPM) and research was conducted according to the guidelines for the care and use of laboratory animals of UPM. Twenty virgin female Sprague-Dawley (SD) rats (6- 8weeks old), with weigh of 180 - 200 g were purchased from Sapphire Enterprise, Malaysia. The animals were divided into two groups; ten animals as tumor-bearing and ten as normal control group. Animals were housed two rats per plastic cages and allowed to acclimate in standard conditions (under a 12 h light/dark cycle) for one week. The rats were given free access to distilled water and commercialized food throughout the experiment.

### Cell line

Rat mammary gland tumor cell line, LA7 (ATCC No CRL2283) was kindly offered by Dr Teo Guan Young (Institute Bioscience, UPM). Cells were maintained at 37°C in a humidified atmosphere of 5% CO<sub>2</sub> in Dulbecco's modified eagle's medium (DMEM) supplemented with 10% fetal bovine serum (FBS), 100 µg/ml streptomycin and 100 IU/ml penicillin.

### Cell preparation

When the cells were 90% confluent, the medium was removed and the cells washed with PBS to remove dead and undetached cells. Low amount of trypsin-EDTA was added to detach cells. Cells were obtained immediately by centrifugation at 100 *g* for 10 min at 4°C, washed twice with PBS and dispersed. For viability detection, the cells were stained with trypan blue and counted using a hemocytometer. Cells were eventually suspended in 300 µl of PBS. All harvested cells were used within one hour of preparation.

### Mammary tumor induction

Because of ease of handling and speed of use, the rats were anesthetized by intraperitoneal injections of a mixture of ketamine-HCl and xylazine (150 and 10 mg/kg, respectively). The animals were positioned securely in a stereotactic frame with the top flat surface of the cranium parallel to the ground. The injection site was properly cleaned and sterilized with ethanol. The cell suspension (6 × 10<sup>6</sup> cells in 300 µl PBS) was drawn into 1-cc (1-ml) TB syringes without needles to minimize damage, lysis and death to the cells. The cell suspension was inoculated subcutaneously into the mammary fat pad (right flank) of the SD rats using a TB syringe with #26 gauge needle. The needle was positioned 2 mm posterior and 2.5 mm lateral to the mammary gland, inserted through the skin and then lowered 5 mm into the mammary fat pad. The 300 µl cell suspension was injected slowly over five minutes. The areas surrounding the injection site were washed with a generous amount of warm PBS to dissipate any cells that may have spilled or leaked. The beds of rats were supported with suitable heat lamp because animals may lose body heat during the procedure. The temperature, breathing and heart rates of animals were monitored closely. To maintain a steady breathing rate, they were gently turned over and

back for 10 - 20 s and their position rotated every few minutes.

### Tumor study

The latency period and tumor incidence was determined as tumor growth landmarks (Riveraa et al., 1994). All animals were monitored for mammary tumor development. Tumor diameters and animal weight were measured every week. The tumor mass was measured horizontally and vertically using a digital caliper. Volume of tumor (V) was calculated by the formula determined by Carlsson:  $V = (ab^2)/2$ , where 'a' and 'b' is the longest and shortest diameters of the tumor, respectively (Carlsson et al., 1983).

### X-ray imaging

The tumor mass in rat breast area was confirmed by radiographs using a soft X-ray instrument (Shimadzu, Japan). Prior to imaging, animals were shaved and anesthetized as described earlier. The rats were exposed to the X-ray at 44 kV, for 2.5 milliseconds.

### Blood test (biochemical analysis)

Blood samples were collected from the healthy and tumor-bearing rats by cardiac puncture using #23 gauge needles before and after development of the tumor. After collection, the samples were allowed to clot at room temperature and centrifuged at 300 *g* for 10 min. Serum were then separated and analyzed for lactate dehydrogenase (LDH), alkaline phosphatase (ALP), alanine aminotransferase (ALT) and glutamate dehydrogenase (GGT) by a chemistry analyzer (Hitachi 902, Japan) using standard diagnostic kits (Roche).

### Histological analysis

At the end of the study, the tumor masses, lungs and livers of rats were removed and examined for tissue abnormalities. Sample of tissues were fixed immediately in 10% formalin overnight, embedded in paraffin, cut into 4 µm sections and stained with hematoxylin-eosin (H&E).

### Statistical analysis

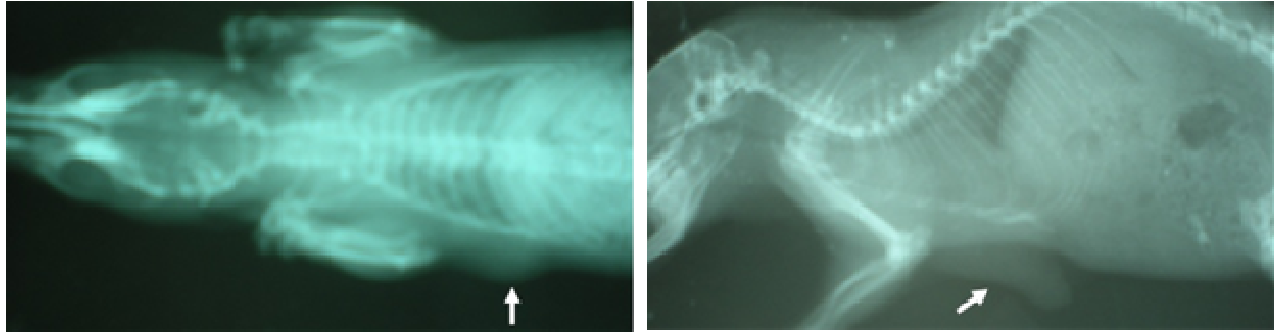
The data obtained were subjected to statistical analysis. The differences in mean values among the two groups were expressed as mean ± standard deviation. All the calculations were performed using the SPSS version 17 and independent t-test.

## RESULTS

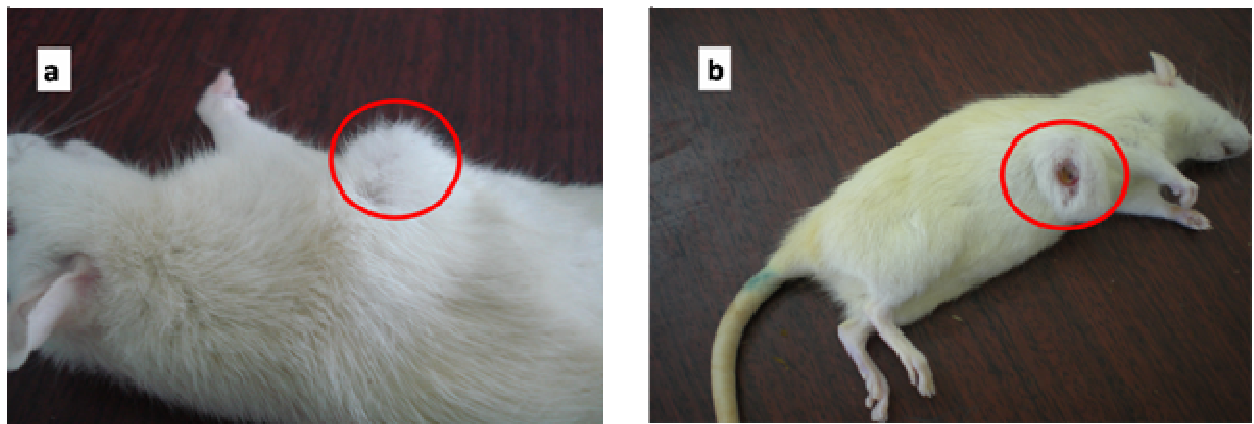
### Tumor development

Mammary tumors were observed as early as 7 to 10 days after LA7 cell injections, which indicated that the cells have strong tumorigenicity properties. The results of soft X-ray images of tumor bearing rats are presented in Figure 1. The tumor was soft, rubbery and as it grew, became irregular and lobulated (Figure 2). Tumors adhered more to the skin than the body wall (Figure 3).

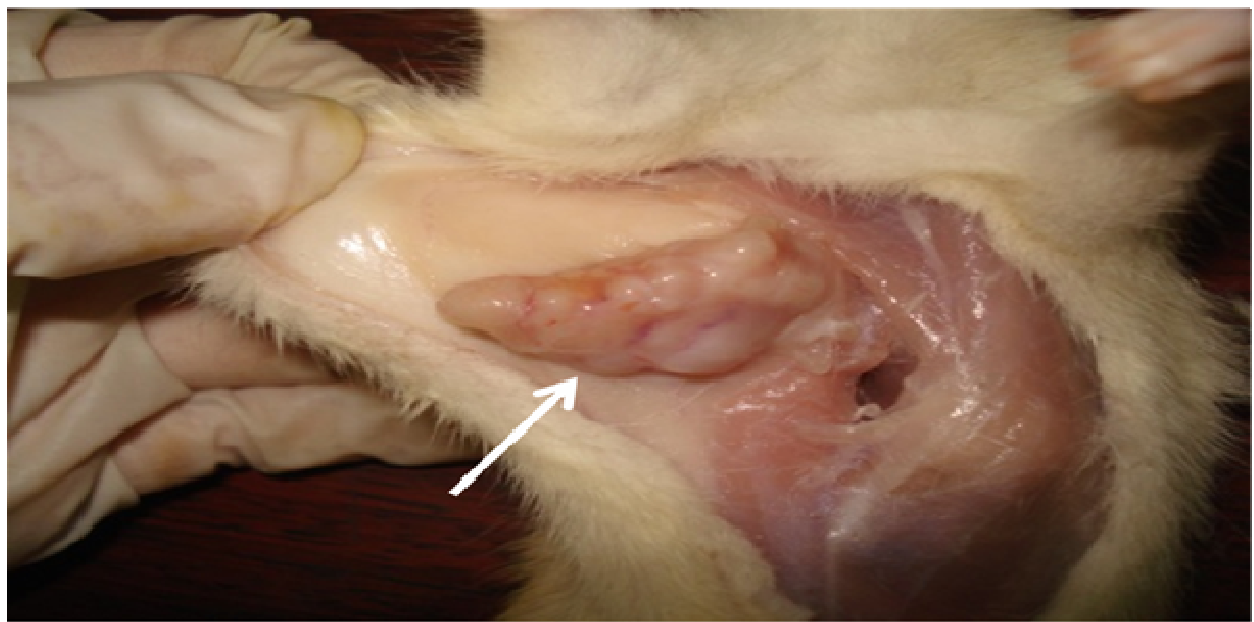
Tumors in the LA7 cell-injected group grew rapidly and reached an average volume of 1821.13 mm<sup>3</sup> by the 30th



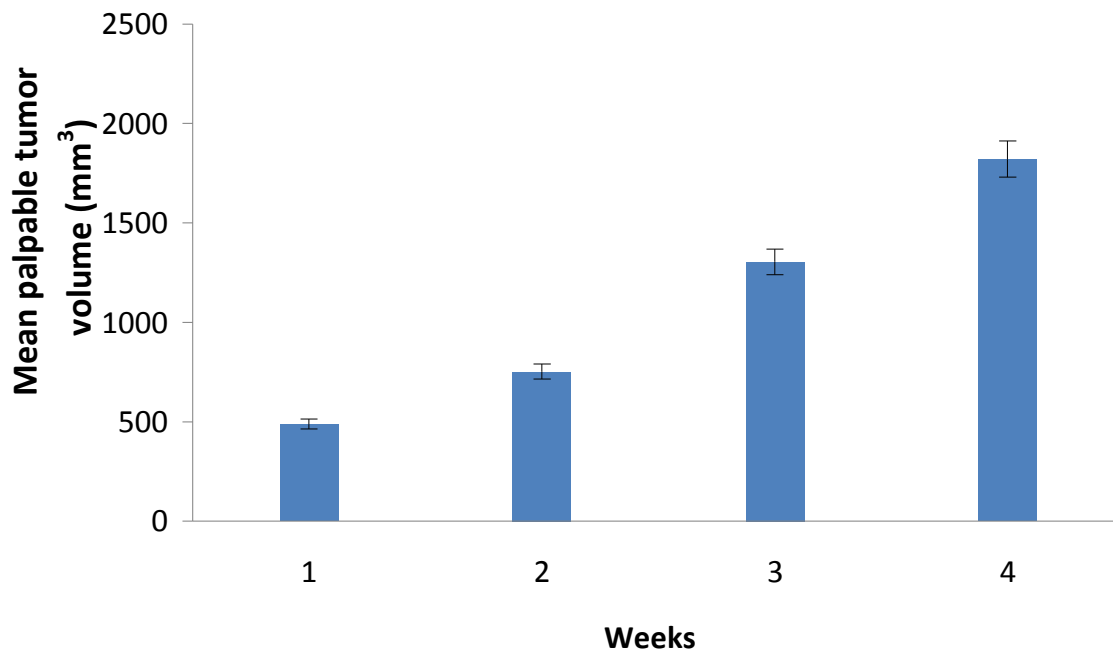
**Figure 1.** Soft X-ray images from two rats bearing breast tumor obtained after one week injection of cancer cells. Total  $6 \times 10^6$  LA7 cells were injected on the right flank of eight female Sprague-Dawley rats.



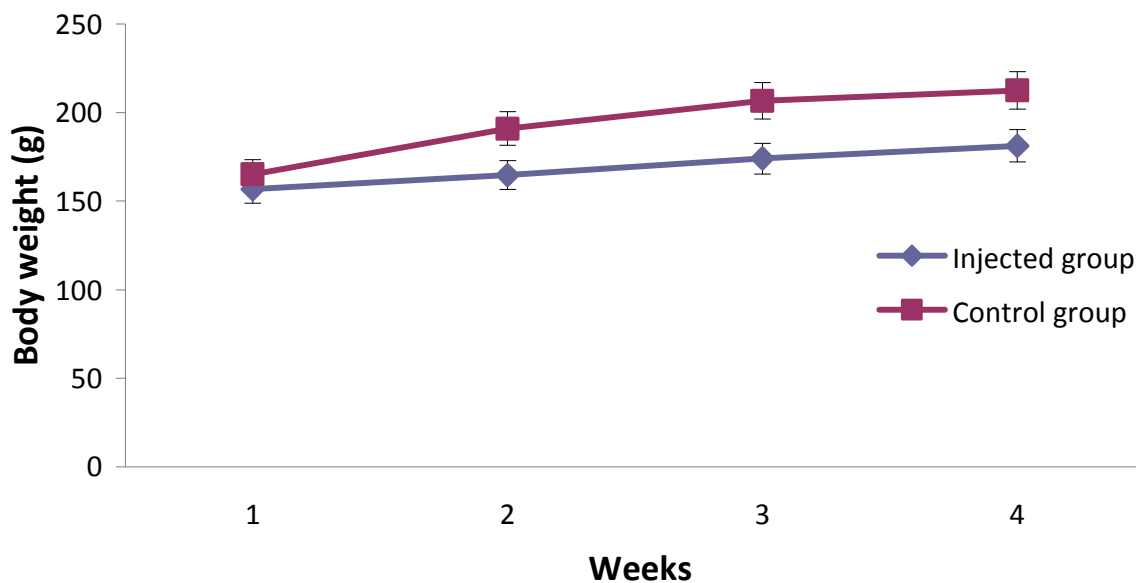
**Figure 2.** Mammary tumors were observed as early as 7 to 10 days after LA7 cell injections in 80% of rats (a). Tumors in the LA7 cell-injected group grew rapidly with Irregular and lobulated appearance of tumors (b)



**Figure 3.** Solid tumor growth in LA7 cell injected rats. The tumor was more adhesive to the skin than to the body wall showing invasiveness of tumor into lung area.



**Figure 4.** Effect of 300  $\mu$ l of LA7 cell (total  $6 \times 10^6$  cells) on tumor volume. After the cancer cell administration, the sizes of tumor were monitored by measuring externally at two dimensions. The tumor volume was calculated by multiplying the length of the tumor with the square of the width and dividing the product by two. Values are means  $\pm$  S.D of results from eight rats.

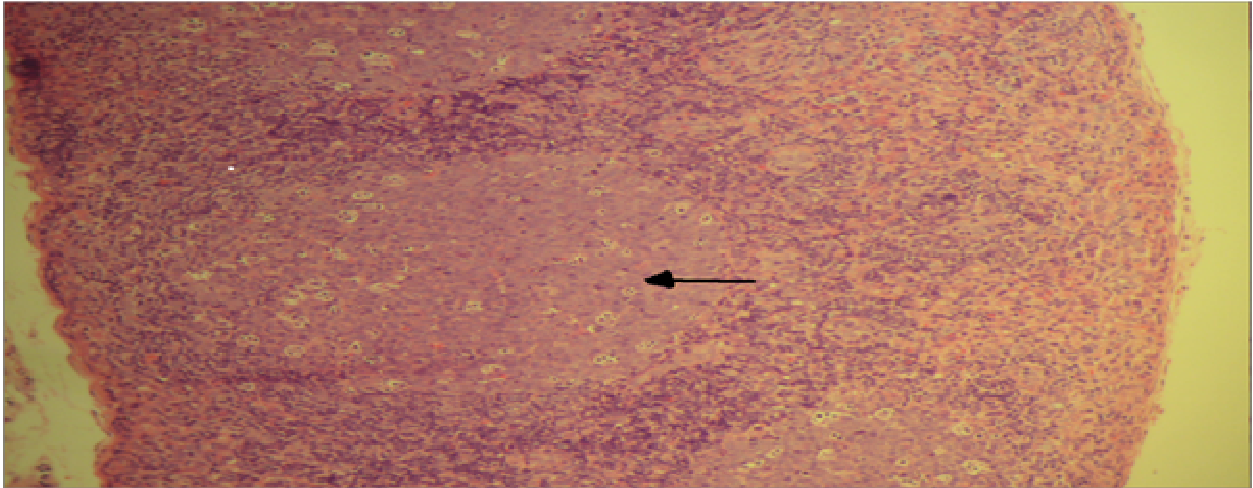


**Figure 5.** Effect of 300  $\mu$ l of LA7 cell (total  $6 \times 10^6$  cells) on body weight changes of injected group. Data are means of results for six rats in control group and eight rats in injected group. Statistical significant are expressed at  $P < 0.05$ .

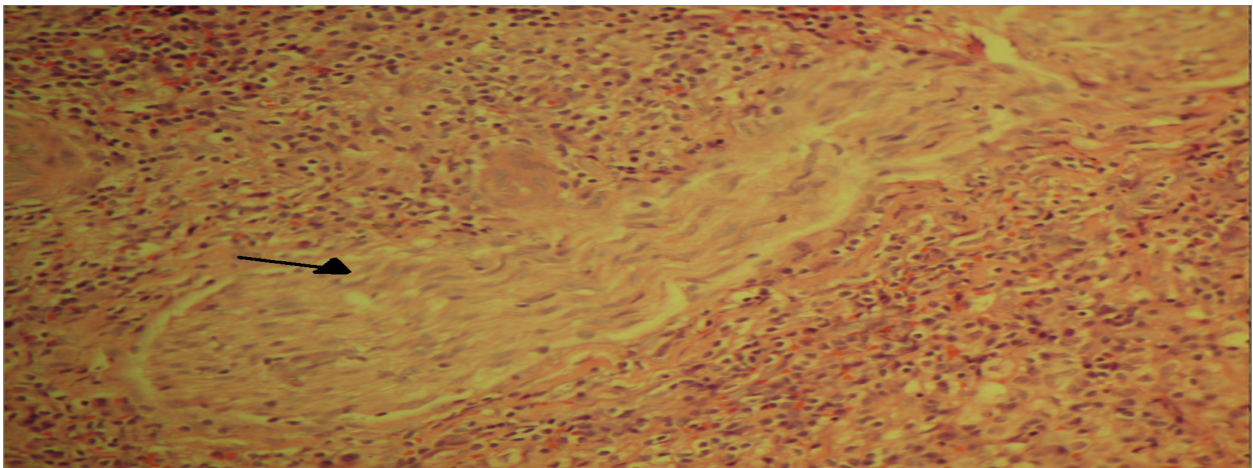
day (Figure 4). The animal weight increased during the study; however, no significant difference was found between healthy and carcinogenic rats ( $P > 0.05$ ) (Figure 5). The rate of mammary tumor developed in these rats was 80%.

#### Pathologic study of tumors

The histopathological features of tumors developed in rats with mammary gland tumors were reactive lymphatic follicular hyperplasia, typical appearance of neoplastic



**Figure 6.** Rat mammary gland tumor section showing reactive lymphatic follicular hyperplasia (arrow).



**Figure 7.** Rat mammary tumor section showing neoplastic cells invasive feature (arrow). (H&E, x25).

cell with invasive features, high mitotic activity and necrosis consistent with adenocarcinomas (Figures 6-9). In adenocarcinoma, malignant tumors are derived glandular epithelium and have an adenomatous appearance. The epithelium cells are arranged in gland-like structures surrounding a lumen. Nucleoli are often prominent and mitotic figures are abundant (Young and Hallowes, 1973). The liver sections of rats in all group represented normal tissue and the lung section of rats were free of neoplastic involvement (data not shown).

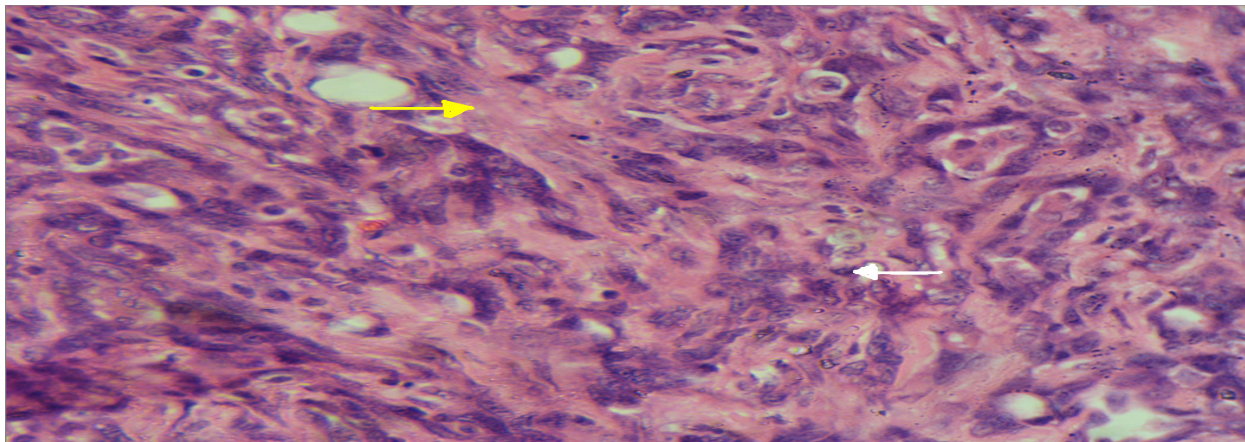
### Blood test analysis

The results obtained from the biochemical assays are shown in Table 1. Data from this table shows that there was significant increase in serum ALP concentration in the tumor-bearing rat from the first to the last week of the

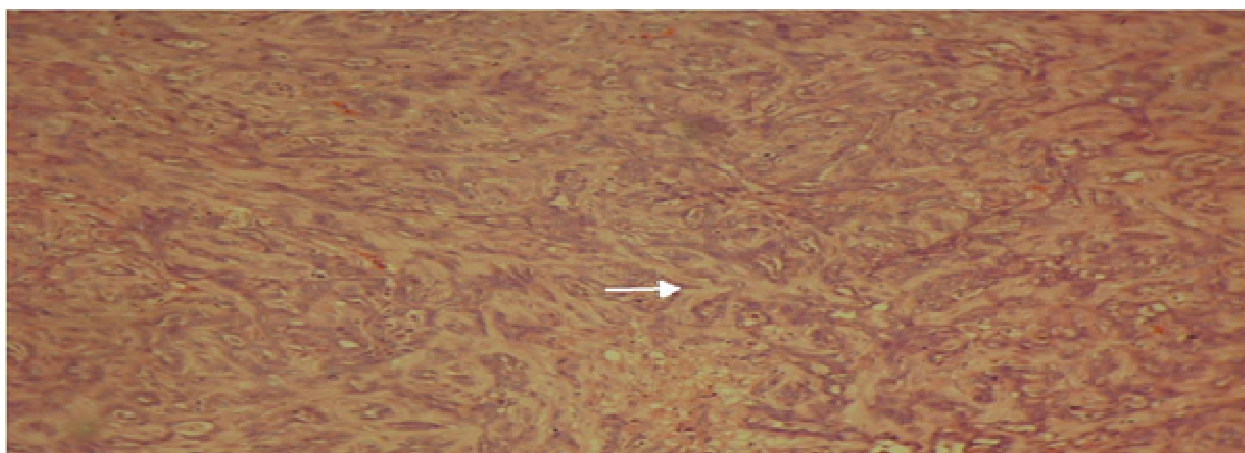
experiment ( $P < 0.05$ ). In our study, the serum ALP concentration in the tumor-bearing rat decreased over week 4, which remained significantly higher than the normal group. Although serum ALT concentrations were observed to be high in tumor-bearing rats, these values returned to normal levels by the end of the study. During experiment period, the tumor-bearing rats showed significant increase in serum lactate dehydrogenase (LDH) concentrations when compared to the normal group. In the final week only, two of LA7 cell-injected rats showed higher GGT compared with the control group (data not shown).

### DISCUSSION

This study set out with the aim of assessing the importance of carcinogenicity in induced rat mammary gland tumor



**Figure 8.** Rat mammary tumor section showing high mitotic activity (white arrow) and necrosis (yellow arrow) (H&E, x40).



**Figure 9.** Rat mammary gland tumour section showing adenocarcinoma (arrow) (H&E, x25).

**Table 1.** Serum enzyme and total protein levels in control and carcinogenesis rats.

Group	Week	ALT (U/L)	ALP (U/L)	LDH (U/L)
Normal		49±2.53	66 <sup>a</sup> ±26.50	584 <sup>a</sup> ±117.25
Cancer	1	73.01±42.1	262.13 <sup>b</sup> ±106.85	2208.37 <sup>b</sup> ±657.75
	4	52.2±14.12	226.13 <sup>b</sup> ±59	3202.88 <sup>b</sup> ±1102.32

All values are expressed as mean ± standard deviation. <sup>a,b</sup>Means with the different superscripts are significantly different;  $p < 0.05$ . ALT = alanine transferase; ALP = alkaline phosphatase; LDH = lactate dehydrogenase.

as a model for breast cancer studies. Although, there have been different methods for tumor induction, such as chemical carcinogens (Huggins et al., 1961) and ionizing radiation (Gross et al., 1988), they are time-consuming and hazardous. In this study, we used the rat mammary tumor cell, LA7, to induce mammary tumors in right flank of rats to produce malignant tumors. Using this method, the mammary gland tumor developed at the site of injection within 7 to 10 days. Kim et al. (2006) showed the tumorigenicity of the rat kidney epithelial cells ( $1 \times 10^7$

cells/200  $\mu$ l) harboring k-ras gene (RK3E-ras) in male SD rats. All of the SD rats injected with RK3E-ras cells developed tumor mass at the inoculated site. In our study, the rate of tumorigenicity of LA-7 cells ( $6 \times 10^6$  cells/300  $\mu$ l) in these rats was 80%. Other advantages of this tumor induction method are the ease of inoculation method, continuity and reproducibility of tumor growth, safe and economical. The model may be used for breast cancer studies, to include determination of the processes of cancer and testing of new chemotherapy agents.

Another important advantage of this model is that the tumor rarely developed metastasis or expressed cell surface molecules which are different from the cells of the origin tissue (Jacob et al., 2004). In our study, the body weights of the rats did not show significant difference between normal and tumor-bearing rats, suggesting that this method did not produce side-effects that could cause weight loss, while in the study of Perumal et al. (2005a) and Padmavathi et al. (2006), although initially, there was no significant change in the body weight of the control and experimental rats, but finally, there was a significant ( $p < 0.001$ ) decrease in the body weight of the DMBA-induced tumor in female SD rats. The histopathological feature of our experimental tumor model was similar to human breast cancers in characteristics, particularly in morphological feature or cellular components. Therefore, this animal model is suitable for application in the study of breast cancers. According to Qin et al. (2007), the outcomes from chemically induced mammary tumor in rats cannot be extrapolated to the development of spontaneous breast cancer in human directly.

Tumor markers are most useful for monitoring response to therapy and early detection of cancer. The result of this study showed elevated serum ALP concentration in the tumor-bearing rats. One study showed that serum ALP concentration increased significantly in cancer patients with metastasis (Mishra et al., 2004). In our rats, there was no evidence of metastasis, suggesting that the increased serum ALP may in fact be due to the primary tumor. Liver metastasis (Wang et al., 2006) and hepatotoxicity (Lynch et al., 2005) also can be determined by changes in serum ALT. However, by the lack of change in serum ALT, it seems that neither hepatotoxicity nor liver metastasis occurred in our tumor-bearing rats. Serum LDH concentrations often increased significantly in cancer patients with endometrial and ovarian cyst adenocarcinomas but not in patients with breast cancers (Koukourakis et al., 2008). According to Perumal et al. (2005b), the elevated activity of LDH may be due to overproduction by tumor cells, or it may be due to the release of isoenzymes from destroyed tissues. Our results are also consistent with the above reports. The significant high ( $P < 0.05$ ) serum LDH concentrations observed in this study were similar to those in human cancer patients with endometrial adenocarcinoma, ovarian cyst adenocarcinomas and breast cancers. However, it was suggested that the serum LDH concentration is nonspecific for the diagnosis of metastasis (Mishra et al., 2004). Some studies showed correlations between serum GGT concentration and malignant neoplasm such as cancers of the digestive, respiratory, female genital, lymphoid and hematopoietic organs (Strasak et al., 2008),

However, our findings showed that the serum GGT concentrations were not significantly different in normal and tumor-bearing rats suggesting that this serum parameter is not a good biomarker for rat mammary gland tumors. In contrast, there are studies (Sani et al., 2004) that reported serum GGT significant increase in

women with breast malignant neoplasm, while others reported no significant increase in GGT levels in cancer patients without metastasis (Durham et al., 1997). It is possible that either this enzyme is not related to mammary tumor development or maintenance or four weeks of tumor development were not sufficient to cause changes in these serum parameters. Longer studies are recommended to determine the importance of these enzymes in the prognosis of mammary gland and breast cancers.

## ACKNOWLEDGEMENTS

This study was funded by Ministry of Science and Innovations, Malaysia and the University Putra Malaysia.

## REFERENCES

- Bennet DC, Peachey LA, Durbin H, Rudland PS (1978). A possible mammary stem cell line. *Cell*, 15: 283-298.
- Carlsson G, Gullberg B, Hafstrom L (1983). Estimation of liver tumour volume using different formulas-an experimental study in rats. *J. Cancer Res. Clin. Oncol.* 105: 20-23.
- Dulbecco R, Bologna M, Unger M (1979). Differentiation of a rat mammary cell line *in vitro*. *Proc. Natl. Acad. Sci. USA*, 76: 1256-1260.
- Durham JR, Frierson HF-Jr, Hanigan MH (1997). Gamma-glutamyl transpeptidase immunoreactivity in benign and malignant breast tissue. *Breast Cancer Res. Treat.* 45: 55-62.
- Gross L, Dreyfuss Y, Tullio F (1988). Incidence and nature of tumors induced in Sprague-Dawley rats by  $\gamma$ -irradiation. *Cancer Res.* 44: 2451-2453.
- Huggins C, Grand LC, Brillantes FP (1961). Mammary cancer induced by a single feeding of polynuclear hydrocarbons and its suppression. *Nature*, 189: 204-209.
- Jacob D, Davis J, Fang B (2004). Xenograftic tumour models in mice for cancer research, a technical review. *Gene Ther. Mol. Biol.* 8:213-219.
- Kim SA, Kim HW, Kim DK, Kim SG, Park JC, Kang DW, Kim SW, Ahn SG, Yoon JH (2006). Rapid induction of malignant tumor in Sprague-Dawley rats by injection of RK3E-ras cells. *Cancer Lett.* 235: 53-59.
- Koukourakis MI, Kontomanolis E, Giatromanolaki A, Sivridis E, Liberis V (2008). Serum and Tissue LDH Levels in Patients with Breast/Gynaecological Cancer and Benign Diseases. *Gynecol. Obstet. Invest.* 67: 162-168.
- Lynch ED, Gu R, Pierce C, Kil J (2005). Combined oral delivery of ebselen and allopurinol reduces multiple cisplatin toxicities in rat breast and ovarian cancer models while enhancing anti-tumor activity. *Anticancer Drugs*, 16: 569-579.
- Mishra S, Sharma DC, Sharma P (2004). Studies of biochemical parameters in breast cancer with and without metastasis. *Indian J. Clin. Biochem.* 19: 71-75
- Padmavathi R, Senthilnathan P, Chodon D, Sakthisekaran D (2006). Therapeutic effect of paclitaxel and propolis on lipid peroxidation and antioxidant system in 7, 12 dimethyl benz(a)anthracene- induced breast cancer in female Sprague Dawley rats. *Life Sci.* 78: 2820-2825
- Perumal SS, Shanthi P, Sachdanadam P (2005a). Augmented efficacy of tamoxifen in rat breast tumorigenesis when gavaged along with riboflavin, niacin, and CoQ<sub>10</sub>: Effect on lipid peroxidation and antioxidants in mitochondria. *Chem. Biol. Int.* 152: 49-58.
- Perumal SS, Shanthi P, Sachdanadam P (2005b). Therapeutic effect of tamoxifen and energy-modulating vitamins on carbohydrate-metabolizing enzymes in breast cancer. *Cancer Chemother. Pharmacol.* 56: 105-114.
- Qin LQ, Xu JY, Tezuka H, Li J (2007). Consumption of commercial whole and non-fat milk increases the incidence of 7, 12-dimethylbenz(a)anthracene-induced mammary tumors in rats. *Cancer*

- Detect. Prev. 31: 339-343
- Riveraa ES, Andradeb N, Martin G, Melitoa, G, Cricco G, Mohamada N, Davioa C, Caroa R, Bergoc RM (1994). Induction of mammary tumors in rat by intraperitoneal injection of NMU: histopathology and estral cycle influence. *Cancer Lett.* 86: 223-228.
- Salami S, Karami-Tehrani F (2003). Biochemical studies of apoptosis induced by tamoxifen in estrogen receptor positive and negative breast cancer cell lines. *Clin. Biochem.* 36: 247-253.
- Sani HA, Rahmat A, Ismail M, Rosli R, Endrini S (2004). Potential anticancer effect of red spinach (*Amaranthus gangeticus*) extract. *Asia Pac. J. Clin. Nutr.* 13: 396-400.
- Strasak AM, Pfeiffer RM, Klenk J, Hilbe W, Oberaigner W, Gregory M, Concin H, Diem G, Pfeiffer KP, Ruttmann E, Ulmer H (2008). Prospective study of the association of gamma-glutamyltransferase with cancer incidence in women. *Int. J. Cancer*, 123: 1902-1906.
- Wang JY, Xu BH, Tian LJ, Wang Y (2006). Clinical characteristics and potential prognostic factors of breast cancer patients with liver metastases. *Zhonghua Zhong Liu. Za. Zhi.* 28: 612-616.
- Young S, Hallows RC (1973). Tumours of the mammary gland. In *Pathology of tumours in laboratory animals-Tumours of the rat*, ed. Turusov VS, IARC. Switzerland. 1: 1.
- Zucchi I, Sanzone S, Astigiano S, Pelucchi P, Scotti M, Valsecchi V, Barbieri O, Bertoli G, Albertini A (2007). The properties of mammary gland cancer stem cell. *PNAS*, 104: 10476-10481.