

*Full Length Research Paper*

# **$\alpha$ -Tocopherol (vitamin E) attenuates the testicular toxicity associated with experimental cryptorchidism in rats**

Saalu, L. C.<sup>1\*</sup>, Oluyemi, K. A.<sup>2</sup> and Omotuyi, I. O.<sup>3</sup>

<sup>1</sup>Department of Anatomy, Lagos State University, College of Medicine (LASUCOM) Ikeja, Lagos, Nigeria.

<sup>2</sup>Department of Anatomy, College of Health Sciences, Igbinedion University Okada, Nigeria.

<sup>3</sup>Department of Biochemistry, College of Health Sciences, Igbinedion University Okada, Nigeria.

Accepted 28 May, 2007

**Cryptorchidism is the most frequent anatomic anomaly observed in an endocrine gland. It is a well-identified risk factor in infertility and testicular cancer. It is believed that increased generation of free radicals and oxidants play an important role in the resulting testicular damage. The present study investigated the role of  $\alpha$ -tocopherol (vitamin E) as an antioxidant in protecting the testis against damage in experimental cryptorchidism. Thirty six Sprague - Dawley rats weighing 250 – 280 g were divided into three groups; A, B and C, with Group A (intact rats) as control. All rats in Group B and C were rendered bilaterally cryptorchid by anchoring the upper pole of testis to the anterior abdominal wall. Group C rats in addition received vitamin E at 25 mg/kg body weight intramuscularly daily. Fifty six days after cryptorchidism induction, bilateral testicular weight, bilateral testicular volume, bilateral caudal epididymal sperm characteristics, bilateral testicular histology and serum hormone levels were all tested. Most of the above parameters were significantly lower ( $P < 0.05$ ) in Groups B and C compared to Group A. The testes of vitamin E treated cryptorchid rats had better functional and histological profiles than those of the untreated cryptorchid rats. Experimental cryptorchidism did not affect the plasma testosterone levels. The results indicated that vitamin E moderated the deleterious effects of experimental cryptorchidism.**

**Key words:** Cryptorchidism, testis, infertility,  $\alpha$ -tocopherol.

## **INTRODUCTION**

Cryptorchidism is a condition in which the testis is hidden or obscure. It results from failure of the testis to descend into the scrotum. With an incidence of between 2 - 6% in new borns, it is the most common disorder of sexual development at full-term birth (Ono and Sofikitis, 1997). Cryptorchidism is a well described clinical condition associated with male infertility. It is believed that the resultant testicular damage is in part, a consequence of increased generation of free radicals and oxidants (Grisham and McCord, 1996).

Most male mammals have scrotums and the scrotal temperature is always lower than that of the abdomen.

The lower levels of the scrotal temperatures are believed to maintain optimal environment for testicular function. According to Waites and Setchell (1990), increasing testicular temperature above normal levels results in altered spermatogenesis in mammals due to effect of heat which brings about oxidative stress on the seminiferous tubules. It is also well known that surgical induction of cryptorchidism in experimental animal causes disruption of spermatogenesis leading to infertility (Seppo et al., 1996; Saalu et al., 2006; Saalu et al., 2007).

Oxidative stress in biological systems originates as the result of an imbalance between the generation of oxidizing species and cellular antioxidant defences (Hallwell and Cuterlage, 1986; Kappus, 1987; Rikans et al., 1991). The radical chain reaction of lipid peroxidation appears to be a continuous physiological process. The process, if out of control, can alter essential cell functions and lead

\*Corresponding author. E-mail: [chiasaalu@hotmail.com](mailto:chiasaalu@hotmail.com). Tel: 234-8033200876.

to cell death (Chance et al., 1979).

A major contributor to non-enzymatic protection against lipid peroxidation is vitamin E, a known free radical scavenger (Kappus, 1987; Hallwell, 1989). Vitamin E as a lipid soluble, chain breaking antioxidant (Chance et al., 1979; Hallwell, 1989) plays a major role against oxidative stress, and prevents the production of lipid peroxides by scavenging free radicals in biological membranes (Suga et al., 1984). Since the discovery of vitamin E in 1922 by H.M. Evans, when it was first described as an antisterility agent, many scientists have sought to elucidate its health benefits and clinical applications.

Vitamin E has been widely investigated due to its action against oxidative stress (Kumar and Daraad, 1988; Tappei, 1982), its protective role on biological membranes (Noguchi et al., 1973) and also its effect on delaying the symptoms of aging (Eneslo and Verdone, 1980). The *in vivo* function of vitamin E as an antioxidant has, however, not yet been fully elucidated. The present study is planned to evaluate the role of vitamin E as a protective agent against testicular oxidative stress associated with experimental cryptorchidism.

## MATERIALS AND METHODS

### Chemicals

Vitamin E injection<sup>R</sup> (Alpha tocopheryl acetate) GB Pharma was obtained from Tabade Pharmacy, Akoka, Lagos, Nigeria.

### Animals

Adult male Sprague – Dawley rats weighing 250 – 280 g were used for the study. The animals were housed in wire mesh cages under standard environmental conditions with the provision of 12 h light and 12 h darkness. Rats (Pfizer feeds Nigeria Limited, Lagos, Nigeria) and water were provided *ad libitum*.

### Experimental protocol

Thirty six male Sprague - Dawley rats were weighed and divided randomly into three groups of twelve rats each. Group A served as the control and the rats were neither rendered cryptorchid nor treated with Vitamin E. Groups B and C served as the experimental groups in which the rats rendered bilaterally cryptorchid. Experimental cryptorchidism was performed by anchoring the testis to the anterior abdominal wall, using a 4 – 0 Nylon suture passing through the connective tissue of the caput epididymis as described by Jegou et al. (1984). Group C in addition had 25 mg/kg body weight of vitamin E injected intramuscularly, daily for fifty six days.

### Autopsy, organ weight and volume estimation

At the end of the experimental period, each rat was weighed and sacrificed by decapitation. The testis were excised, dissected free of surrounding tissue, their weight determined and volume measured by water displacement method.

### Sperm characteristics

The testes from each rat were carefully exposed and removed. They were trimmed free of the epididymides and adjoining tissues.

From each separated epididymis, the cauda part was removed and placed in a beaker containing 1 mL physiological saline solution. Each section was quickly macerated with a pair of sharp scissors and left for a few minutes to liberate its spermatozoa into the saline solution. Sperm motility, concentration and progressive motility were determined as earlier described (Saalu et al., 2006, 2007). Semen drops were placed on the slide and two drops of warm 2.9% sodium citrate were added. The slide was covered with a cover slip and examined under the microscope using X40 objective for sperm motility. Sperm count was done under the microscope using improved Neubauer haemocytometer.

### Estimation of plasma levels of testosterone

Plasma testosterone concentrations were estimated using the Enzyme Immunology Assay (EIA) method as earlier described (Saalu et al., 2006). Plasma samples were collected and stored at – 20°C until assayed. The EIA kits used were obtained from Immunometrics (London U. K) and contained testosterone EIA substrate reagents and EIA quality control samples. A quality control sample was run for the hormone at the beginning and at the end of the assay variation. The EIA kit used had a sensitivity level of 0.3 nmol/L (0.1 ng/mL). The intra and inter assay variations were 11.00 and 10.10%, respectively.

### Histological analysis

This was done as essentially as described by Akpantah et al. (2003). The organs were cut in slabs of about 0.5 cm thick and fixed in Bouin's fluid for a day after which it was transferred to 70% alcohol for dehydration. The tissues were passed through 90% alcohol and chloroform for different durations before they were transferred into two changes of molten paraffin wax for 20 min each in an oven at 57°C. Serial sections of 5 µm thick were obtained from a solid block of tissue and were stained with haematoxylin and eosin stains, after which they were passed through a mixture of equal concentration of xylene and alcohol. Following clearance in xylene, the tissues were oven-dried. Light microscopy was used for the evaluations.

### Statistical analysis

Data were expressed as mean ± SEM. They were subjected to analysis of variance (ANOVA). Statistical significance between the various groups was separated by t – test (SAS, 2002).

## RESULTS

### Body weight changes

Table 1 shows that rats in control group had significant (P < 0.05) increase in weight. Both cryptorchid groups lost weights when compared with their initial weights. However the weight loss by the cryptorchid rats that received Vitamin E was higher than the losses by cryptorchid group that did not receive Vitamin E.

### Weights and volumes of testes

Table 1 also shows that the testicular weights and volumes of the rats of cryptorchid alone group were the least,

**Table 1.** Body weights (g), testicular weights (g) and testicular volumes (mL) of experimental rats with or without cryptorchidism.

Parameter	Cryptorchid without Vitamin E	Cryptorchid with Vitamin E	Control
Initial Live Body Weight	260.30 ± 15.30	280.11 ± 23.50	250.20 ± 40.00
Final Live Body weight	255.24 ± 20.40	240.23 ± 20.60	290.80 ± 33.00
Body weight difference	5.06 (1.95)	39.88 (14.24)	40.6 (16.24)
Testicular Weight	0.51 ± 0.13*	1.55 ± 0.06	1.83 ± 0.20
Testicular Volume	0.52 ± 0.14*	1.64 ± 0.04	1.85 ± 0.30

\*P < 0.05 compared to control group.  
( ) = Percentage.

**Table 2.** Sperm characteristics of experimental rats with or without cryptorchidism..

Parameter	Cryptorchid alone	Cryptorchid with vitamin E	Control
Sperm Concentration (X 10 <sup>6</sup> /mL)	1.05 ± 4.60**	25.0 ± 5.07*	58.6 ± 7.00
Sperm motility (%)	7.5 ± 2.02**	20.5 ± 4.64*	72.4 ± 3.12
Progressivity	b <sub>1</sub>	b <sub>1</sub>	a <sub>1</sub>

\*P < 0.05 compared with the control group.  
\*\*P < 0.01 compared with the control group.  
a<sub>1</sub> = Rapid linear progressive motility.  
b<sub>1</sub> = Sluggish linear or non – linear motility.

**Table 3.** Serum testosterone levels of experimental rats with or without cryptorchidism.

Group	Testosterone level (ng/mL)
Control	2.45±0.40
Cryptorchid alone	2.33±0.5
Cryptorchid with Vitamin E	2.25±0.60

being significantly lower (P < 0.05) compared to the mean testicular weights and volumes of the cryptorchid rats that in addition had Vitamin E.

### Spermatozoa concentration

As shown in Table 2, the cryptorchid alone group had marked oligospermia with their sperm concentration being significantly lower (P < 0.01) compared to the control group. The cryptorchid with Vitamin E group, however, showed only moderate oligospermia; the sperm concentration being significantly lower (P < 0.05) than the control group.

### Spermatozoa motility

Even though sperm motility of both the cryptorchid alone and cryptorchid with vitamin E groups were significantly lower (P < 0.01 and P < 0.05, respectively) compared to the control group, the cryptorchid with Vitamin E group still had a significantly higher (P < 0.05) sperm motility than the cryptorchid alone group (Table 2).

### Progressivity of spermatozoa motility

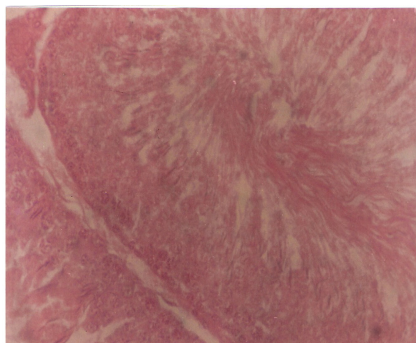
The sperm cells from the cauda epididymides of both cryptorchid alone and cryptorchid with Vitamin E groups showed sluggish linear or non-linear movement. Spermatozoa from the control group exhibited progressive rapid linear movement.

### Serum testosterone levels

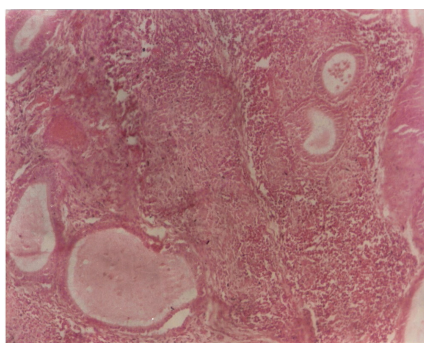
There was no significant (P > 0.05) difference in the peripheral serum basal testosterone levels between the control rats and the other two groups. The testosterone levels in the experimental groups did not also significantly (P > 0.05) differ from one another (Table 3).

### Testis morphology

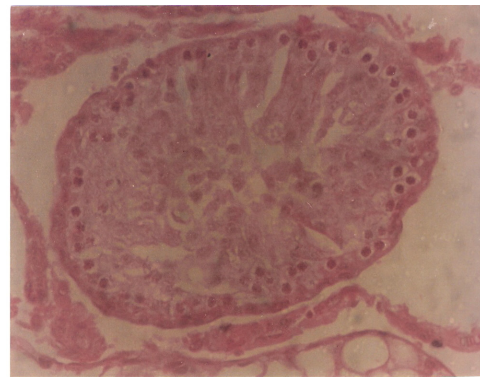
Light microscopy was used for evaluation of testicular histology as shown in Figures 1 - 3. The seminiferous tubules of the control rats were completely differentiated. Spermatozoa are shown in some of the tubules. However, in the two experimental groups the testis showed atrophy of the seminiferous tubules, degeneration of the germinal epithelium and absence of late stage germ cells. These degenerative changes were shown to be more marked in the rats that were made cryptorchid without receiving vitamin E than in those that received vitamin E after being made cryptorchid.



**Figure 1.** Section through testis of control rats (haematoxylin and eosin stains; X 400).



**Figure 2.** Section through testis of cryptorchid rats without vitamin E treatment (haematoxylin and eosin stains; X 400).



**Figure 3.** Section through testis of cryptorchid rats with vitamin E treatment (haematoxylin and eosin stains; X 400).

## DISCUSSION

The findings from our present study demonstrated that experimental cryptorchidism inhibited growth and reproductive capacity of male Sprague -Dawley rats. The gain in live body weights of the control rats could mean that the rats were still in the active growth phase. The loss in live body weights of the experimental groups indicates that artificial cryptorchidism has a negative effect on the body metabolic process (Ezeasor, 1985). The procedure for achieving artificial cryptorchidism and also the daily intramuscular injections confer a conspicuous level of stress on the rats. This stress could affect their metabolic process leading to losses in live weights observed in this study.

The lower testes weights in cryptorchids compared to the control corroborates the report of Ono and Sofikitis (1997). Gutton and Hall (1996) and Senger (1999) reported degenerative changes in the seminiferous epithelium of testes lying within the core body temperature, due to the effects of heat on the spermatogenic cells within the epithelium leading to loss in testicular weight. That the mean testicular weight of cryptorchid with vitamin E rats, which had a lower mean final live weight was significantly ( $P < 0.05$ ) higher than the mean testicular weight of cryp-

torchid alone group, is an indication of the moderating effects of vitamin E treatment.

Retention of the testes inside the abdomen results in disruption of spermatogenesis (Zhang et al., 2002). This results in poor testicular functions (Patkowski et al., 1992; Tellaloglus, 1994; Kawakami, 1995; Nambirajan et al., 2002). Attending degeneration of tubular epithelium, leaving only interstitial structure of the testis, with consequential difficulty in the formation of viable spermatozoa has also been reported (Senger, 1999). That the epididymides of the cryptorchid testes had significantly lower sperm parameters than the unmanipulated testes confirms the deleterious effect of cryptorchidism on testicular functions. Similar results on epididymal sperm concentration and motility have been reported in our recent study (Saalu et al., 2007).

The observed moderate oligospermia ( $25.0 \pm 5.07 \times 10^6/\text{mL}$ ) in cryptorchid rats that had vitamin E is a significant improvement over the marked oligospermia ( $1.05 \pm 4.60 \times 10^6/\text{mL}$ ) shown in cryptorchid rats that were not given vitamin E. This is a confirmation of the attenuating effect of vitamin E which is a potent antioxidant and free radical scavenger (Kappus, 1987; Hallwell, 1989). Thus the increased free radicals generated by the exposure of the testes to the core body temperature as well as the attending oxidative stress conferred by experimental cryptorchidism have been ameliorated by the vitamin E administration.

Data from the present study showed there was no significant difference in the peripheral basal testosterone levels in all the three groups of rats. This suggests that although all cell types of the testes were affected by cryptorchidism, the most prominent damage occurred in the seminiferous epithelium. Thus the Leydig cells, which secrete testosterone, were minimally affected by experimental cryptorchidism. This is in agreement with earlier findings (Guyton and Hall, 1996; Senger, 1999; Shakeel et al., 2001; Saalu et al., 2006). In contrast to these findings however, Jegou et al. (1984) demonstrated impairment in both the spermatogenic and steroidogenic

functions when the testis is exposed to core body temperature. Similar data was obtained from our previous study (Saalu et al., 2007) using immature animals. The variations could, therefore, be due to the differences in the timing of cryptorchidism induction.

The cytoprotective effect of vitamin E is additionally indicated by the significant improvement in the histological profiles of the cryptorchid with Vitamin E group compared to the testicular morphologic features of the cryptorchid alone group. In conclusion, our study demonstrated the detrimental effect of experimental cryptorchidism on testicular function and also showed the capacity of vitamin E in ameliorating these deleterious effects.

## REFERENCES

- Akpantah AO, Oremosu AA, Ajala MO, Noronha CC, Okanlawon AO (2003). The effect of crude extract of *Garcinia kola* seed on the histology and hormonal milieu of male Sprague-Dawley rats' reproductive organs. *Niger. J. Health Biomed. Sci.* 2(1): 40-46.
- Chance B, Sites H, Boverts A (1979). Hydroperoxide metabolism in mammalian organs. *Physiol. Rev.* 59: 527-605.
- Ezeasor DN (1985). Light and electron microscopic observations of the Leydig cells of the scrotal and abdominal testes of naturally unilateral cryptorchid WAD goats. *Am. J. Vet. Res.* 41: 27-40.
- Grisham A, Mc Cord P (1996). Chemistry and cytotoxicity of reactive metabolites. *Biology of oxygen radicals.* AE Taylor, pp. 1-19.
- Guyton AC, Hall JC (1996). *Textbook of Medical Physiology* 9<sup>th</sup> Edn., W. B. Saunders Company. Philadelphia. Pennsylvania, pp. 1006.
- Hallwell B, Cutler JMC (1986). Oxygen free radicals and iron in relation to biology and medicine: Some problems and some Concepts. *Arch. Biochem. Biophys.* 246: 501-504.
- Hallwell B (1989). Oxidants and the central nervous system. Some fundamental questions. Is oxidant damage relevant to Parkinson's Disease, Alzheimer's disease, traumatic injury or stroke? *Acta Neurol Sci.* 126: 23-33.
- Jegou B, Peake RA, Iraby DC, De Krester DM (1984). Effect of the induction of experimental cryptorchidism and subsequent orchidopexy on testicular function in immature rats. *Biol. Reprod.* 30: 179-187.
- Kappus H (1987). Oxidative stress in chemical toxicity. *Arch. Toxicol.* 60: 144-149.
- Kawakami E (1995). Changes in peripheral plasma leutinizing hormone quality in normal and maturation. *Lab. Anim. Sci.* 45: 258-263.
- Kumar DA, Derael R (1988). Physiological antioxidants and antioxidative enzymes in Vitamin E – deficient rats. *Toxicol. Lett.* 44: 47- 54.
- Noguchi T, Cantor A, Scott MC (1973). Mode of action of Selenium and Vit E. in prevention of oxidative stress in chicks. *J. Nutr.* 103: 1502-11.
- Nambirajan LS, Agarwala AK, Dinda J, Mitra DM (2002). Fertility and Unilateral undescended testis in the rat model. III. Ultrastructural changes in the contralateral descended testis. *Ped. Surg. Int.* 18: 276-280.
- Ono k, Sofikitis N (1997). A novel mechanism to explain the detrimental effects of left cryptorchidism on right testicular function. *Yonago Acta Med.* 40: 79-89.
- Patkowski D, Jelen M, Cerni KJ (1992). The natural course of cryptorchidism in rats and efficacy of orchidopexy in its treatment before and after puberty. *J Paediat. Surg.* 27: 870-873.
- Rikans LE, Moor DR, Snowden CD (1991). Sex – dependent differences in the effects of aging on antioxidant defences mechanisms of rat liver. *Biochem. Biophys. Acta.* 1074(1074): 195-200.
- Saalu LC, Togun VA, Oyewopo AO, Raji Y (2006). Artificial cryptorchidism and the moderating effect of melatonin in Sprague – Dawley rats. *J. Appl. Sci.* 6 (14): 2889 –2894.
- Saalu LC, Adesanya AO, Oyewopo AO, Raji Y (2007). An evaluation of the deleterious effect of unilateral cryptorchidism on the contralateral normally descended testis. *Sci. Res. Essays* 2(3): 074-078.
- Senger PL (1999). Pathways to Pregnancy and Parturition. *Current Conception Inc.* 1<sup>st</sup> Rev. Edn. pp. 169-203.
- Seppo T, Outi H, Sakari W (1996). Early treatment of cryptorchidism, semen quality and testicular endocrinology. *J Urol.* 156: 82-84.
- Shakeel M, Farooqui M, Fakhri Al-Bagdalli, Milos D Houslay (2001). Surgically induced cryptorchidism related degenerative changes in spermatogonia are associated with loss of cyclic Adenosine monophosphate dependent phosphodiesterase type 4 in abdominal testis of rats. *Biol. Reprod.* 64: 1583-1589.
- Suga T, Watanabe T, Matsumoto, Hortes Y (1984). Effects of long term Vit E deficiency and Restoration of rat hepatic peroxisomes. *Biochem. Biol. Phys. Acta.* 794: 218-24.
- Tellaloglus S (1994). Cryptorchidism is orchidopexy always. Preventive treatment for infertility. *Acta Chir-Hungatic,* 34: 195-201.
- Waites GMH, Setchell BP (1990). Physiology of mammalian testis. In *Marshall's Physiology of reproduction.* Laming GE (Ed) Churchill Livingstone. London 2: 101-105.
- Zhang RD, Wen XH, Kong LS, Deng XH (2002). Quantitative study of the effects of experimental cryptorchidism and subsequent orchidopexy on spermatogenesis in adult rabbit testis. *Reproduction* 124: 95-105.