

Full Length Research Paper

Histopathology of the gill and liver tissues of the African catfish *Clarias gariepinus* exposed to lead

OLOJO, E. A. A.^{1*}, OLURIN, K. B.,¹ MBAKA, G. and OLUWEMIMO, A. D.¹

¹Department of Biological Sciences, Olabisi Onabanjo University, P. M. B. 2002, Ago-Iwoye, Ogun State, Nigeria.

²Department of Anatomy, College of Basic Medical Sciences, Olabisi Onabanjo University, P.M.B. 2002, Ago-Iwoye, Ogun State, Nigeria.

Accepted 21 July, 2004

An investigation on the effect of the heavy metal, lead (Pb) on the gill and liver of the African catfish *Clarias gariepinus* was carried out in the laboratory. One hundred and sixty (160) fingerlings of the fish were exposed to continuous exposure to sub-lethal concentrations (0.006 mg/l and 0.008 mg/l) of lead for a period of three weeks. The liver and gill of fish were removed every 9 days for histological examination. The results showed that the degree of distortion of the gills and liver was proportional to the exposure periods and concentration of the metals was found to be dose and time dependent.

Key words: Lead, *Clarias gariepinus*, histopathology, gill, liver.

INTRODUCTION

Heavy metal contamination has been reported in aquatic organisms (Rashed, 2001; Adham et al., 2002). These metals build up in the food chain and are responsible for chronic illness and death in aquatic organisms (Farkas et al., 2002) which also may move up in the food chain (Chanin, 1985).

The degree of contamination in aquatic environment is frequently assessed by comparing contaminant concentration in associated biota (Yang and Chen, 1996). Since bioconcentration of compounds have been determined in the environment, it has been observed that there are many quantitative relationships between structure and biological activity of chemicals established in aquatic system.

In heavy metal pollution (e.g., Pb), organs such as the gills and liver have been identified as the storage sites in *C. gariepinus* (Gbem et al., 2001). However, the main sites of these heavy metal uptake and accumulation are the gills and gastrointestinal tracts (Pantreath, 1973; Lovegroove and Eddy, 1982; Annume and Iyaniwura, 1993).

Lead is a common heavy metal found in the environment and is derivable from urban waste waters, industrial discharges and agricultural runoff. Its inclusion in gasoline as anti-knock contribute to its occurrence in the air, which is transported to the streams and rivers by runoffs where fish and other aquatic organisms take it up and incorporate it in their body.

Clarias gariepinus, an omnivore freshwater fish is a popular delicacy relished throughout tropical Africa. It is a prominent culture species because of its hardiness and fast growth rate.

This paper is aimed at determining the gills and liver responses of *C. gariepinus* to sub lethal concentrations of lead which provide an early warning of potential problems. One hundred and sixty (160), *C. gariepinus* juveniles (average body weight 4.19 g; average body length 8.6 mm) were obtained from a commercial supplier (CHI farms). They were supplied in an aerated polythene bag. They were fed daily on a commercially formulated feed containing 65% crude protein and kept in stock aquaria (80 cmx30 cm) for two weeks to acclimatize before the commencement of the experiment. The initial body weight of each juvenile was taken on an electric top loading Mettler balance, and the body length using a meter rule.

*Corresponding author. E-Mail: emmanuelolojo@yahoo.co.uk

Twenty juveniles each were divided into eight experimental aquaria containing fresh water (pH 7.7) for two weeks before introducing the toxicant. The lead was introduced directly into the water in the form of $Pb(NO_3)_2$. Introduction of the toxicant was persistent. Two levels of treatment were used: T1 (0.06 mg/L) and T2 (0.08 mg/L) based on EPA (USA) and EIFAC (Europe) guidelines (Haslam, 1992). Each treatment had three replicates while two aquaria served as the control. The water with appropriate concentration of $Pb(NO_3)_2$ was renewed every two days. Conductivity of water is $13.18 \times 10^{-4} \text{ } \square/s$ with a pH of 7.7.

Four fingerlings were selected at random from each tank at nine days interval, blotted dry with soft absorbent paper and dissected to remove liver and gill tissues. The organs were preserved in labeled sample bottles containing formal saline, sectioned and slide preparations were made for histological investigation under the microscope. Photomicrographs of the various sections showing the effects of Lead on the cell structure of the target organs were made at x 400 magnification.

RESULTS

Light microscopic (LM) examination of photomicrograph of the vertical section of the gills (Figure.1 control) shows the arrangement of the lamella. In the core is a cartilaginous supporting rod (C) and blood vessels with traces of sinusoidal blood spaces. The outer covering of squamous epithelial forms a continuous lining. The primary lamella (P) is rounded at the apices while the projecting secondary lamellas (S) are clearly interspaced.

In the treated aquaria there was a drastic reduction in the activity of the fishes. The swimming became slower and there was reduction in their rate of feeding. In fish exposed to 0.006 mg/l of $Pb(NO_3)_2$ after nine days the gill photomicrograph (Figure 2) shows a gradual process of cyto-architectural distortion of the lamella with primary and secondary lamella overlapping. Thus there was occlusion of inter lamella spaces. The core is thin and indistinct. There is shrinkage of cartilaginous supporting mass resulting in decrease in size of the gills. At higher concentration (treatment 0.08 mg/l of $Pb(NO_3)_2$ for the same exposure, the epithelium is completely disrupted owing to the lysis of the cells. The increase in intracellular vacuolation (Figure 3) signals onset of edematous changes.

The histological appearance following exposure for 18 and 27 days (Figures 4, 5, 6 and 7), respectively, were similar with significant variation in the two concentrations (0.06 mg/l and 0.08 mg/l of $Pb(NO_3)_2$. At 18 days interval, the action of lead was the same at the treated concentrations. The lamellas were thin and elongated, particularly the secondary lamella. The pillar cells appear

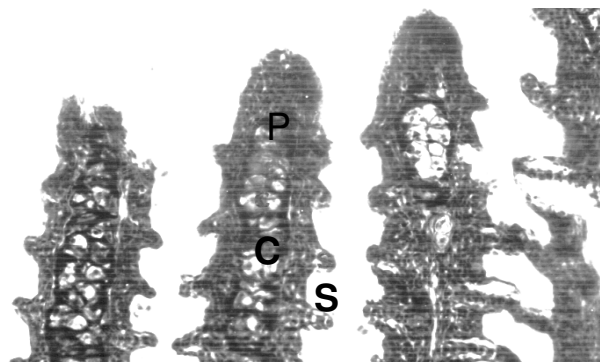


Figure 1. Photomicrograph of gills showing the arrangement of the Primary (P) and Secondary (S) lamella. In the central core is a mass of hyaline Cartilage (C) surrounded with darkly staining blood vessels and sinusoidal spaces. Mg x 400.




Figure 2. The micrograph shows the deformation of the gill tissue after 9 days of exposure to lead (Pb) treatment $T_1 = 0.006\text{mg/L}$. Note the overlapping of secondary lamella. Mg x 400.

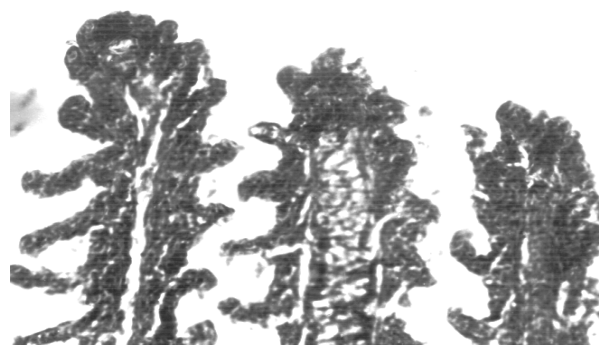


Figure 3. The treatment $T_2 = 0.008\text{mg/L}$ shows the disintegration of epithelial lining leading to diffus mass of the gill lamella after 9 days of exposure. Mg x 4.

much reduced in size. This action consisted of rapid cell lysis throughout the epithelium that became completely

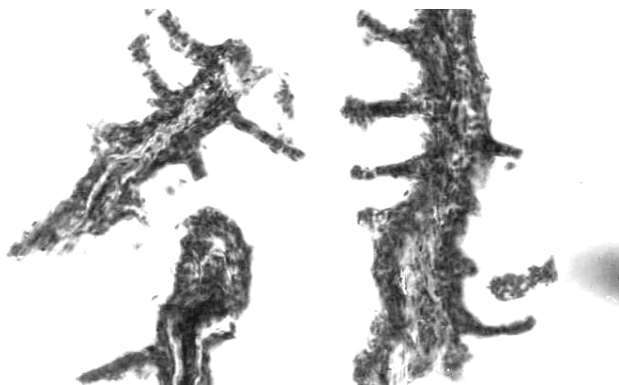


Figure 4. The micrograph shows an increase in the gill deformation and degeneration in th first treatment 18 days after exposure to lead (Pb). T1 = 0.006mg/L. Mg x 400.

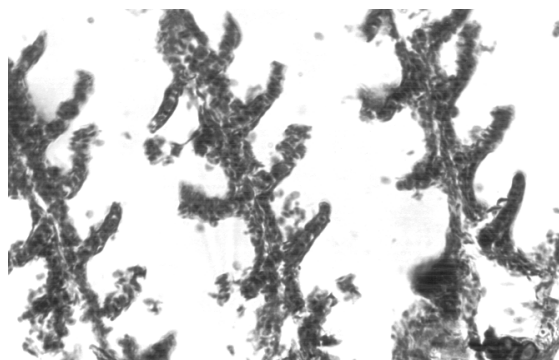


Figure 5. The gill tissue shows a marked decrease in size following rapid cell lysis throughout the epithelium in the second treatment (0.008mg/L) 18 days after exposure to lead (Pb). Mg x 400.

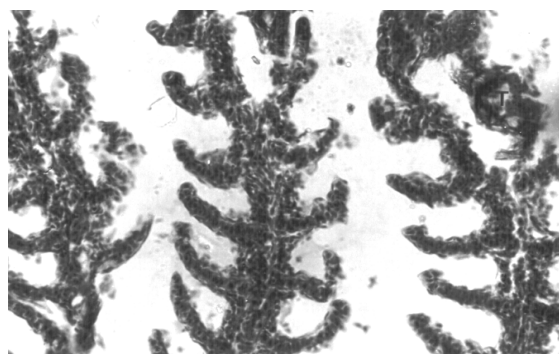


Figure 6. A labelled part (T) indicates the process of sloughing at the tip 27 days after exposure to lead (Pb) in the first treatment (0.006mg/L). Note the large subepithelial spaces, thin but much elongated secondary lamella with disintegrating epithelial lining. Mg x 400.

disrupted in Figure 4. At 27 days interval (Figures 6 and 7), the gills show further shrinkage making the

cartilaginous core absolutely obscured. The sinusoidal blood space is non-existent with element of vascular rupture and tissue ischemia. However, intercellular vacuolation and some detachment of the epithelia resulting to sloughing of the cells occurred at the tip (Figure 6).

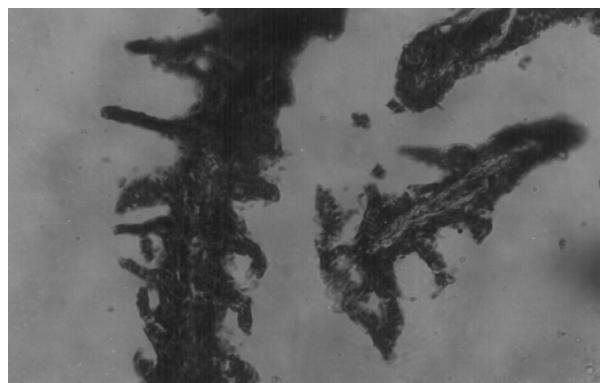


Figure 7. Most of the secondary lamella have degenerated showing a chronic deformation of the gill tissue in the second treatment (0.008mg/L) 27 days after exposure to lead (Pb). Traces of pigmentation can equally be observed. Mg. x 400.

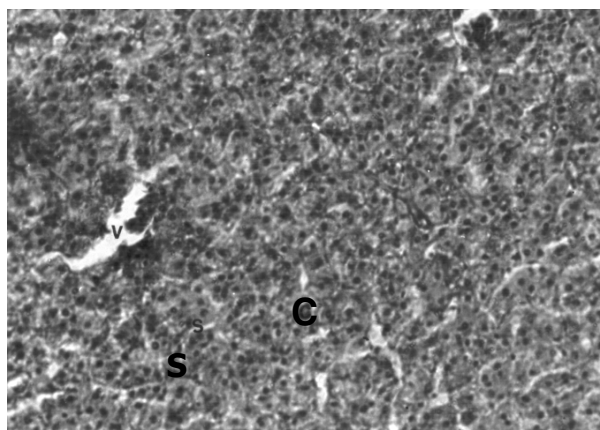


Figure 8.Photomicrograph of liver tissue showing the lattice network of parenchyma Cells (C) forming an irregular clump. The delicate capsule is indistinct while the convergence of Sinusoid (S) into the large central Vein (V) is apparent. Mg. x 400.

The Liver

The photomicrograph of the liver (Figure 8, untreated) shows the parenchyma cells (C) arranged to form a lattice network. The interspaces are the sinusoid (S) of thin strip with sparse connective tissue. The sinusoids make continuous communication as they are seen converging into the central vein (V). Unlike in some mammals, the lobulation is not well delineated.

Hepatic tissue of treated specimens (Figures 9, 10, 11, 12 and 13) show varied degree of hepatic cirrhosis as evident in the density of fibrous connective tissue within and around the hepatic parenchyma. Changes that occurred is also reflected in the two treatments and consisted of damage to the biliary columnar epithelial cells which are separated from the connective tissue.

After nine days of exposure, patchy degeneration and isolated degenerated elements around the parenchyma cells were observed with progressive increase of fibro-connective tissue (Figures 9 and 10). As a result, signs of congestion were noticed at the sinusoid, observed more clearly in Fig. 10. After 18 days interval (Figures 11 and 12), the density of the connective tissue increased markedly leading to more congestion. The size was variable with concentration and was usually located in the vicinity of hepatic arteries and bile ducts.

At prolonged exposure (Figures 13 and 14), the congestion impeded blood circulation resulting in tissue ischemic. Acute and extensive necrosis of liver cells was observed (Figure 14) particularly focal necrosis a common feature in catfish.

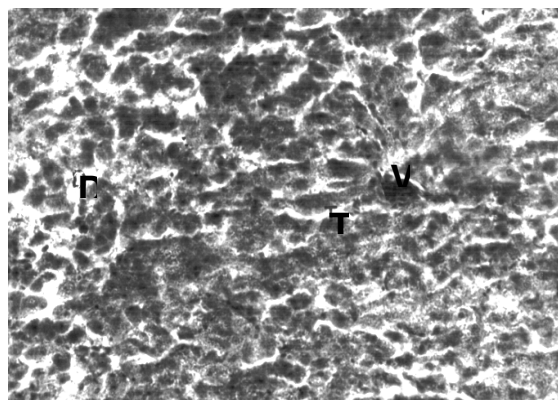


Figure 9. Liver tissue showing deformities in the tissue 9 days after exposure to lead (Pb) treatment 0.006mg/L. Sinusoidal pole bearing blood vessels are well manifest with increase in density of fibre connective (T) radiating towards the central vein (V). Areas of lysed cells (D) are equally indicated. Mg. x 400.

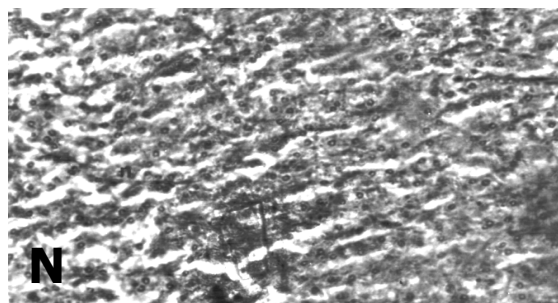


Figure 10. The second treatment (T₂ = 0.008mg/L) 9 days after exposure to lead show increase in density of fibro-connective tissue. Nucleus and the nucleolus (N) are designated. Mg. x 400.

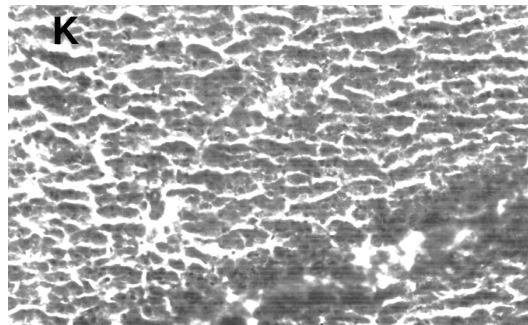


Figure 11. The nucleus is shown conspicuously with an abnormal increase in the surface area of liver tissue, 18 days after exposure to lead treatment (0.006mg/L) with the Kupffer cells (K) more readily visible. Mg. x 400.




Figure 12. Hypertrophy of hepatocyte occurs from the second treatment (T₂) after 18 days of exposure. Mg. x 400.

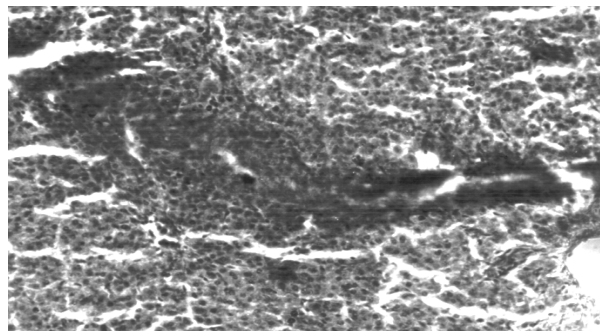


Figure 13. Blood cells are seen around the parenchyma following hemorrhage of the vessel after 27 days of exposure. Mg. x 400.

DISCUSSION

Histological study of the gills shows a typical structural organization of the lamella in the untreated (Figure. 1). The treated (Figures 2, 3, 4, 5, 6 and 7) however, show




Figure 14. In the second treatment $T_2 = 0.008\text{mg/L}$ with lead severe cirrhosis of the liver cells are observed. Note the density of the fibro-connective (T). Mg. x 400

progressive architectural distortion at varied period of exposures. This corroborates with the observation of Strivastava and Strivastava (1994) who reported that teleosts accumulate lead (Pb) both directly from diet and indirectly from the aqueous medium through cutaneous aquatic food chain and through the lamella surface. Accumulation in the gills is considerable because of their external location and necessarily intimate contact with the water that allows for dissolved or suspended materials in the water to be absorbed through the delicate epithelium. The lamella epithelial lining reacts to dissolved lead (Pb) creating tissue osmoregulatory imbalance. The change in physiological property is evident in shrinkage observed at the lamella thus suggesting that lead (Pb) intake mostly occurs via the gills. Prolonged exposure results in marked degeneracy of the epithelium followed by branchial arterial rupture and subsequently, ischemia. There is a drastic reduction in the rate of activity of the fishes in the treated aquaria, the swimming becomes slower and there was a reduction in their feeding habit. Respiratory distress caused by the degeneration of gills is a sign that the total surface area of the gill has been drastically reduced. Asphyxiation occasioned by insufficient gaseous exchange was probably responsible for the death of most of the fingerlings. According to Roberts (1978), it will, in effect, lead to dilation of the lamellar capillary and pooling of blood which thromboses, eventually fibroses and fuses with adjacent lamellae.

The fish responded to the effect of the heavy metal (lead) on its system to keep it alive for sometime. The abnormal elongation was probably as a result of edematous change (Figure 2) as seen in the treated plates, to increase the surface area of the gill. It may be a

form of adaptive measure to survive the effect of the poison on the system. However, it was considered that complete edematous separation of the respiratory epithelium of primary and secondary lamellae will result in lamella epithelial cell necrosis thus leading to osmoregulatory distress (Smith and Piper, 1975).

The numerous cartilaginous cells of the gill arch which were initially degenerated gradually until the traces were no longer seen as the days prolonged. Consequently, there was collapse of the blood vessels, indicating that the quantity of food and oxygen that reach the cells had reduced considerably thereby affecting the growth rate of the few surviving fingerlings and corresponding loss in body weight.

The high accumulation of Lead in the liver which Gbem et al., (2001) also noted in their findings, is related to the fact that liver plays a key role in accumulation and detoxification. Although, according to Frieberg *et al.*, (1971), fishes are known to possess sequestering agent (metallothionein), the bioaccumulation of these trace element in the liver tissue reaches a proportion in which the function of the liver is impeded, thus resulting in gradual degeneration of the liver cells syncytial arrangement. The surface area of the liver cell is also decreased, which may be due to the increase in the intrabiliary fibre-connective tissue. The intercellular spaces seen are zones of total cell degeneration. Thus cirrhosis, the outcome of prolonged hepato-cellular injury is manifested by fibrosis of hepatic cords and peribiliary connective tissue.

Oxygen required to support the intense metabolic activity of the liver is supplied in arterial blood via the hepatic artery.

In effect, necrosis of parenchyma cells had taken place. The condition is said to be associated with dietary toxicity (Anderson et al., 1976). Sinusoids clogs up thereby blocking the blood from the hepatic artery and the interbiliary portal vein which will have to pass through the sinusoids to get to the central vein. The inability of blood to get to the central vein on time makes the liver pump blood harder resulting in stress of the liver. This seriously affects the metabolic activities of liver resulting in a drastic reduction in the food material supplied to the tissue with subsequent weakening of the fingerlings and corresponding loss in weight.

The kupffer cells are attached to the walls of the sinusoids (phagocytic cells of the liver which participate (with the spleen) in the removal of spent erythrocytes and other particulate debris from circulation (Ferri et al., 1981; Hampton et al., 1989; Mosconi-Bac 1991). The function of the kupffer cells will be impeded due to the clogging up of the sinusoids. This makes old erythrocytes to accumulate in the blood. These erythrocytes are weak and their binding power to oxygen is seriously reduced such that not enough oxygen is taken into the body system.

The canaliculi surrounding the liver cells are also clogged by the syncytial arrangement of the degenerated liver cells, and bile secretion into the canaliculi will be impaired. Also, lipid regulation by the liver will be affected.

Conclusively, metals are stored in different sites in animals depending on the metal and on the animal species. To check the continual introduction of these metals into the food chain, a more cautious application of insecticides and pesticides should be employed and effluents from industries must be treated before disposal.

REFERENCES

- Adham Khadiga G, Hamed Sherifa S, Ibrahim Hama, M Saleh, Ramadan A, (2002). Impaired functions in Nile tilapia, *Oreochromis niloticus* from polluted waters. *Acta Hydrochemica et Hydrobiologica*. 29: 278-288.
- Anderson CD, Roberts R J, Mackenzie K, MacVicar A H, (1976). The hepato-renal syndrome in cultured turbot (*Scophthalmus maximus* L.) *J. Fish Biol.* 8: 331 - 41.
- Annune PA, Iyaniwura TT (1993). Accumulation of two trace metals in tissues of freshwater fishes, *Oreochromis niloticus* and *Clarias gariepinus*. *J. Aqua. Food Prod. Technol.* 2(3): 5-18.
- EIFAC (1977). Report on cadmium and freshwater fish. Prepared by European Island Fisheries Advisory Commission. (EIFAC). Working Party on Water Quality Criteria for European freshwater Fish, with the cooperation of the United Nations Environment Programme (UNEP). EIFAC Technical Paper No.30, p.21.
- Environmental Protection Agency (1976). *Water Quality Criteria*, Washington, D.C. p. 256.
- Farkas A, Salanki J, Specziar A, (2002). Relation between growth and the heavy metal concentration in organs of bream, *Abramis brama* L. populating lake Balaton. *Arch. of Environ. Contam. and Toxicol.* 43(2):236-243.
- Ferri S, Sesso A (1981). Ultrastructural study of the endothelial cells in teleost liver sinusoid under normal and experimental conditions. *Cell Tissue Research*. 219: 649-657.
- Franke C (1996). *Chemosphere* 32 (10): 1897-1905.
- Gbem TT, Balogun J, K Lawal, FA., Annune PA, (2001). Trace metal accumulation in *Clarias gariepinus* (Teugels) exposed to sublethal levels of tannery effluent. *The Sci. of the total Environ.* 271: 1-9.
- Gbem TT, Lawal FA, Balogun J, Auta J (1997). Acute toxicity of of tannery effluent to a freshwater fish, *Oreochromis niloticus* (Trewavas). *Conf. Proc. Chemical Engineers Society of Nigeria.* Hamdala Hotel, Kaduna. 13-15 November, 1997. 125-129.
- Hampton JA, Lanz RC, Hinton DE (1989). Functional units in rainbow trout (*Salmo gairdneri*, Richardson) liver: III. Morphometric analysis of parenchyma, stroma and component cell types. *The Amer. J. Anatomy.* 185:58-73.
- Handy RD (1992a). The Assessment of Episodic Metal Pollution. 1. Uses and Limitations of Tissue Contaminant Analysis in Rainbow Trout, *Onchorhynchus mykiss* after short water borne exposure to Cadmium or Copper. *Arch. Environ. Contam. Toxicol.* 22: 74-81.
- Hampton SN (1992). River Pollution and Ecological Perspective.
- Lovegrove SM, Eddy B (1982). Uptake and accumulation of zinc in juvenile rainbow trout, *Salmo gairdneri*. *Environ. Biol. Fish.* 7:285-289.
- Mosconi-Bac N (1991). Effects de l'alimentation sur les caracteres structuraux et metaboliques du foie de long, *Dicentrarchus labrax*, en aquaculture. These de Doctorat (Specialite Sciences), Universite de Perpignan.
- Pantreath RJ (1973). The accumulation and retention of ⁶⁵Zn and ⁵⁴Mn by Plaice, *Pleuronectes platessa* L. *Mar. Biol. Ecol.* 12:1-8.
- Rashed, M. N., (2001). Cadmium and Lead levels in fish (*Tilapia nilotica*) tissues as biological indicator for lake water pollution. *Environ. Monit. and Assess.* 68(1):75-89.
- Roberts RJ (1978). *Fish Pathology*. Baillier Tindall Pub. 1st Edition. pp. 67 - 70.
- Smith CE, Piper RG (1975). Lesions associated with chronic exposure to ammonia. In: *Pathology of Fishes*. Eds WE Ribelin, G Migaki. pp.497-514. Madison, Wis. University of Wisconsin Press.
- Srivastava AK, Srivastava AK (1994). Review of investigations on biological effects of Selenium on fish. *J. Freshwat. Biol.* 6 (4): 285-293.
- Yang HN, Chen HC (1996). Uptake and elimination of cadmium by Japanese eel, *Anguilla japonica*, at various temperatures. *Bull. Environ. Contam. Toxicol.* 56 (4): 670-676.