

Full Length Research Paper

Anti-ulcer activity of aqueous leaf extract of *Nauclea latifolia* (rubiaceae) on indomethacin-induced gastric ulcer in rats

Balogun M. E.¹, Oji J.O.¹, Besong E. E.¹, Ajah A. A.² and Michael E. M.³

¹Department of Physiology, Faculty of Basic Medical Sciences, College of Health Sciences, Ebonyi State University, Abakaliki, Nigeria.

²Department of Physiology, Faculty of Basic Medical Sciences, College of Health Sciences, University of Port Harcourt, Choba, Port Harcourt, Nigeria.

³Department of Anatomy, Faculty of Basic Medical Sciences, College of Health Sciences, Ebonyi State University, Abakaliki, Nigeria.

Accepted 31 July, 2013

***Nauclea latifolia* is known to possess various therapeutic properties. The present study was designed to evaluate the anti-ulcer activity of aqueous leaf extract of *N. latifolia* against indomethacin-induced gastric ulcers in rats. Five groups of albino rats were pre-treated orally with: vehicle, distilled water (ulcer control), cimetidine (100 mg/kg, reference control), and 170, 340 and 510 mg/kg *N. latifolia* leaf extracts (experimental groups) respectively, 60 min prior to oral administration of indomethacin to generate gastric mucosal injury. Seven hours later, the animals were sacrificed by a blow on the head; their stomachs were removed and examined for ulcer index. The extract produced significant ($P < 0.05$), and dose dependent anti-ulcer activity against indomethacin-induced ulcers in rats. These results suggest that the extract possesses significant anti-ulcer activity against experimentally induced gastric lesions and may justify its use as an anti-ulcerogenic agent.**

Key words: Anti-ulcer activity, *Nauclea latifolia* leaf, mucosal injury, indomethacin, rats.

INTRODUCTION

Peptic ulcer disease is the most common gastrointestinal disorder in clinical practice. It is a chronic disease characterized by ulceration in the regions of upper gastrointestinal tract where parietal cells are found and where they secrete Hydrochloric Acid (HCl) and pepsin. The anatomic sites where ulcer occurs commonly are stomach and duodenum, causing gastric and duodenal ulcer, respectively (Rang et al., 2003). Pathophysiology of ulcer is due to an imbalance between aggressive factors (acid, pepsin, helicobacter pylori, and non-

steroidal anti-inflammatory agents) and local mucosal defensive factors (mucus bicarbonate, blood flow and prostaglandins). Integrity of gastro-duodenal mucosa is maintained through a homeostatic balance between these aggressive and defensive factors (Raskin et al., 1995). Herbal medicine deals with plants and plant extracts in treating diseases. These medicines are considered safer because of the natural ingredients with no side effects (Cloutre and Rosenbaum, 1994). Medicinal plants have been shown to possess

gastroprotective activity in animal studies (Malairajan et al., 2007; Rao et al., 2008). One of the herbs that have great potential is *Nauclea latifolia*.

N. latifolia (smith) belongs to the family Rubiaceae. It is commonly known as pin cushion tree being a straggling shrub or small tree, native to the tropical Africa and Asia (Gidado et al., 2005). It bears an interesting flower, large red ball fruit with long projecting stamens. The red fruit is edible but not appealing. *N. latifolia* is an evergreen multi stemmed shrub or tree. It grows up to an altitude of 200 m. It is widespread in the humid tropical rainforest zones or in the savannah wood land of West and Central Africa (Burkil, 1985). *N. latifolia* is commonly known as "Ubulu inu" among the Igbo in the Eastern part of Nigeria; as "Tafashiya" among the Hausas in the Northern part of Nigeria; as "Egbesi" among the Yoruba in the Western part of Nigeria and as "Itu" among the Itsekiri (Arise et al., 2012). *N. latifolia* herbal remedies have been commonly seen in various cultures throughout recorded history and still serve as the main means of therapeutic medical treatment. It is found in areas like Abakaliki, Abuja, Enugu, Akwa Ibom, Cross River, Kontagora, Shaki and other parts of Nigeria. The wood of *N. latifolia* is termite resistant and is used as a live stakes in farms. All parts of the plants species are rich source of mono-terpene indole alkaloid. It is used in the treatment of fever, diarrhea and even as an anti-parasitic drug (Deeni and Hussain, 1991). The sticks are used as chewing stick and a remedy against tuberculosis (Burkill, 1985; Esimore et al., 2003). Scientific studies have established hypolipidemic and hypoglycemic effects like most other plants extracts (Schiff, 1970; Chong, 1991; Udoh, 1998; Eno and Owo, 1999). The anti-hypertensive effect and the phytochemical screening of this herb have been also documented (Udoh, 1998). Infusion and decoction of the stem bark of the leaves of *N. latifolia* are used for treatment of stomach pain and constipation (Eno and Owo, 1999).

In Kano (Nigeria), the plant is used for tuberculosis (Deeni and Husain, 1991). Abbiw (1990) stated that root infusion of *N. latifolia* is used in Sudan for the treatment of gonorrhoea, its roots and leaves are used in Ghana for treating sores. In Nigerian folklores, the fruit are sometimes used in the treatment of piles and dysentery (Reitman et al., 1957). In addition, the plant is used in the treatment of sleeping sickness and to prolong menstrual flow (Elujoba, 1995). Gidado et al. (2005) reported anti-diabetic properties for the root and leaf extracts while Taiwe et al. (2010) reported the anti-depressant and anti-anxiety effects of the root extract of the plant. A decoction of the stem in water has been demonstrated to exhibit a high anti-parasitic potential (Benoit-Vical et al., 1998). However, despite the acclaimed and documented uses, there appears to be a paucity of literature on the anti-ulcerogenic activities of this plant. Therefore, the current study was undertaken to evaluate the anti-ulcer activity of the aqueous leaf extract of *N. latifolia* against indomethacin

-induced gastric ulcer in rats.

MATERIALS AND METHODS

Animals

Thirty (30) adult male albino rats (180 to 250 g) obtained from the Central Animal House, Faculty of Basic Medical Sciences, College of Health Sciences, Ebonyi State University, Abakaliki, Nigeria were used for the experimental study. They were maintained under standard laboratory conditions and were fed with standard rat's pellets (Pfizer Livestock Feeds PLC, Enugu, Nigeria) and tap water were given ad libitum. They were acclimatized for 2 weeks after which they were divided randomly into five groups of six animals each coded to prevent observer bias. Animal experimental studies were conducted according to the guidelines of Institutional Animal Ethical Committee (IAEC) of Ebonyi State University, Abakaliki, Nigeria.

Drugs

Cimetidine was obtained from the Ebonyi State University Medical Centre (EBSUMC) Pharmacy and was used as the reference anti-ulcer drug. Cimetidine is H₂-receptor antagonist drug used for the treatment of peptic ulcers. Cimetidine blocks H₂-receptor channels in the wall of the stomach leading to reduction in acid production allowing the stomach to heal. In this study, the drug was administered orally to reference control group of rats in a dose of 100 mg/kg suspended in distilled water (5 ml/kg).

Plant material and preparation of aqueous extract

The fresh leaves of *N. latifolia* (family: Rubiaceae) were collected within the campus of the Ebonyi State University, Abakaliki, Nigeria, identified and authenticated by Mr. P. O. Ugwuozo in the herbarium of the Botany Department of University of Nigeria, Nsukka, with deposition of authenticated voucher specimen (UNH - 303i). Leaves were separated from the stalks, washed with distilled water, and air-dried in the shade for 7 to 10 days. The dried leaves were pulverized to coarse powder. To 200 g of the powdered leaves in a container with lid, 1 L of boiling water was added and covered. It was allowed to stand for 24 h with intermittent shaking. The mixture was then filtered with NO. 1 Whatman qualitative filter paper to obtain a pure filtrate. The combined filtrate was concentrated in the required doses of 170, 340 and 510 mg/kg/ 5 ml respectively (Akpanbiatu et al., 2005). It was stored in the refrigerator throughout the period of the experiment to preserve the prepared extract.

Indomethacin-induced ulcers

Food was withdrawn 24 h and water 1 h before drug treatment (Ibitoye et al., 2002). Animals in groups 1 and 2 received distilled water and cimetidine, respectively, while those in groups 3, 4 and 5 were pre-treated with 170, 340 and 510 mg/kg of the extract. After 1 h, indomethacin (30 mg/kg/5 ml) was administered orally to all the rats. 7 h later, the rats were killed by a blow on the head (Ukwe and Nwafor, 2004). The rats' stomachs were removed and each opened along the greater curvature. After fixing the tissues by immersing in 10% formalin for 24 h, it was rinsed under a stream of water and examined for ulcers. The ulcers were counted by the aid of a hand lens (X- magnification) and ulcer score was calculated for each animals according to the arbitrary scale used by Singh (1997),

Table 1. Effects of *N. latifolia* aqueous leaf extract on indomethacin- induced ulcers in rats.

| Group | Treatment | Dosage (p.o) | Mean ulcer index \pm SEM | Percentage protection (%) |
|-------|-----------------|--------------|----------------------------|---------------------------|
| 1 | Distilled Water | 5 ml/kg | 3.50 \pm 11.18 | 0.00 |
| 2 | Cimetidine | 100 mg/kg | 0.83 \pm 0.69* | 76.28 |
| 3 | Extract | 170 mg/kg | 1.16 \pm 0.61* | 66.85 |
| 4 | Extract | 340 mg/kg | 0.66 \pm 0.36* | 81.14 |
| 5 | Extract | 510 mg/kg | 0.33 \pm 0.02* | 90.57 |

*Significant. All values are expressed as mean \pm SEM; n = 6 in each group. *P<0.05 as compared with the negative control animal.

where 0 = no lesion, 1 = hyperemia, 2 = one or two slight lesions, 3 = very severe and 4 = mucosal full of lesion. Ulcer index was calculated as mean ulcer scores (Tan et al., 1996).

Histological evaluation of gastric lesions

Immediately after macroscopic evaluation, the stomachs were washed with saline and fixed in 10% buffered formalin solution for histo-pathological studies. Sections of the gastric walls were made at a thickness of 5 to 6 μ m, stained with hematoxylin and eosin (H&E), were assessed for histo-pathological changes such as congestion, edema, necroses and heamorrhage (Shahl and Khan, 1997). The microscopic slides were photographed.

Statistical analysis

Results were expressed as mean \pm S.E.M. The significance of the data was calculated at the 95% confidence interval using the Student's 't' test.

RESULTS

Gross evaluation of gastric lesions

As shown in Table 1, indomethacin induced ulcers in 100% of the animals in the negative control (distilled water; 5 ml/kg) group. The ulcer index was 3.5 \pm 11.18, which is characterized with severe disruption of surface epithelium of gastric mucosa (Figure 1). Pre-treatment with cimetidine significantly (P< 0.05) reduced the severity of indomethacin-induced ulcers compared to rats pre-treated with distilled water (ulcer control). The *N. latifolia* leaf extracts were also shown to exert cytoprotective effects in a dose-dependent manner (Table 1).

Histological evaluation of gastric lesions

The cytoprotective effect was confirmed by histological examination. The rats pre-treated with distilled water (negative control) before administration of ulcer-inducing indomethacin showed markedly extensive damage to the gastric mucosa, with lesions extending deep into the mucosal layer, and edema and leucocytes infiltration of

the sub-mucosa layer (Figure 1). Rats pre-treated with 340 or 510 mg/kg *N. latifolia* leaf extracts had comparatively better gastric mucosal protection compared to rats pre-treated with cimetidine or 170 mg/kg plant extract as evidence by the marked reduction in ulcer index, inhibition of edema and leucocytes infiltration of the submucosa layer (Figures 2, 3 and 4). Percentage inhibition to ulcer formation in rats by the extract was calculated as follows:

$$\% \text{ Inhibition of ulceration} = \frac{\text{Ulcer index}_{\text{Control}} - \text{Ulcer index}_{\text{Test}}}{\text{Ulcer index}_{\text{Control}}} \times 100\%$$

DISCUSSION

This research work was designed to investigate the anti-ulcerogenic activity of aqueous leaf extract of *N. latifolia* against indomethacin-induced gastric ulceration in albino rats. The finding of the present study demonstrate that aqueous extract of *N. latifolia* significantly protected against mucosal damage induced by indomethacin and curative ratios of plant extracts 170, 340 and 510 mg/kg were 66.85, 81.14 and 90.57%, respectively. It is remarkable that the leaf extract at 340 and 510 mg/kg doses produced a greater protection than cimetidine (100 mg/kg) against the indomethacin. The effect of the extract compared favorable to cimetidine 100 mg/kg (positive control). However, the mechanism by which the aqueous leaf extract on *N. latifolia* produced its gastroprotective effects in rats is not clear. It has been established that indomethacin is an ulcerogenic agent especially when administered on an empty stomach (Blaargawa et al., 1993). The ulcerogenic activity of indomethacin and other non-steroidal anti-inflammatory agents as postulated might be due to their ability to inhibit prostaglandin synthesis (Vane, 1971). Several lines of evidence suggest that prostaglandins inhibit gastric secretion and are important to normal gastric physiology and mucosal integrity (Robert et al., 1968; Jacobson, 1970; Main and White, 1976). Some of the mechanisms suggested for their effect include tightening of the gastric mucosal barrier (Bolton and Cohen, 1979) and stimulation of the gastric sodium pump (Robert, 1979).

The protective effect of the extract on indomethacin

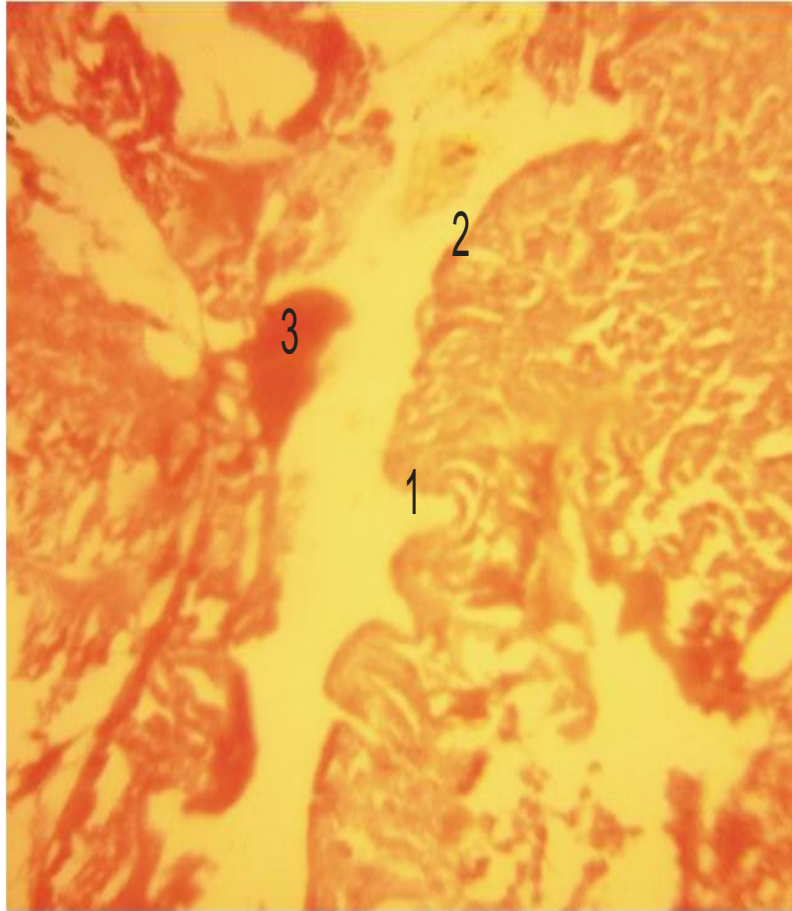


Figure 1. Histological section of the gastric mucosa in a rat pre-treated with distilled water (ulcer control). 1, gastric pit; 2, columnar epithelium; 3, ulcerated section of the epithelium. There is severe disruption of the surface epithelium, deep penetration of necrotic lesions into mucosa and edema of submucosa layer with leukocyte infiltration of ulcerative tissues (H&E stain, 10x).

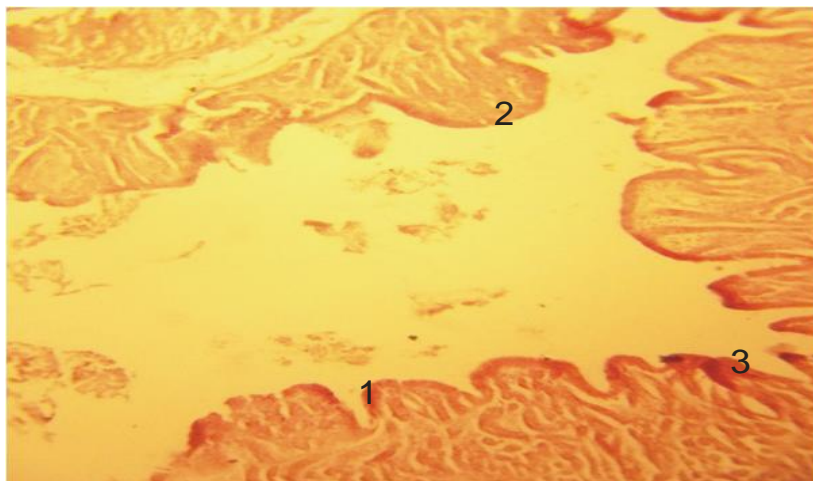


Figure 2. Histological section of the gastric mucosa in a rat pre-treated with cimetidine (100 mg/kg). 1, gastric pit; 2, columnar epithelium; 3, ulcerated section of the epithelium. There is mild disruption of the surface epithelium and edema of submucosa layer with leukocyte infiltration of ulcerative tissues (H&E stain, 10x).

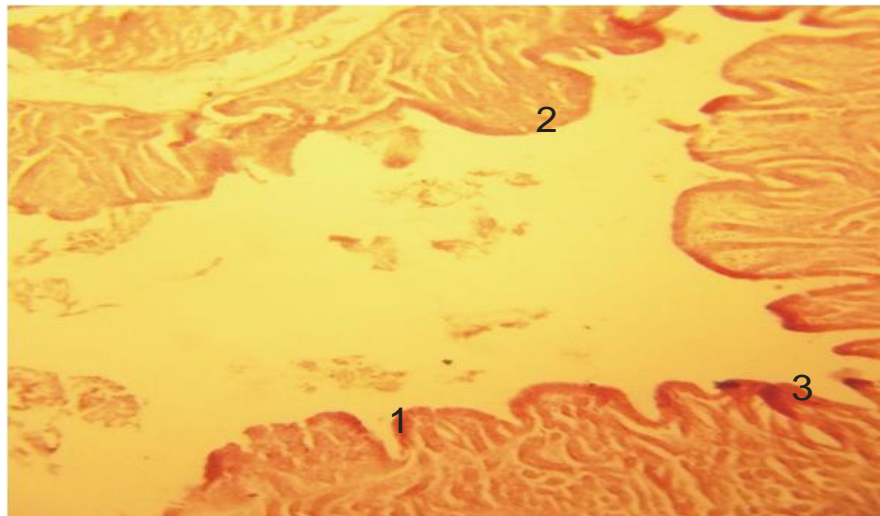


Figure 3. Histological section of the gastric mucosa in a rat pre-treated with *N. latifolia* (170 mg/kg). 1, gastric pit; 2, columnar epithelium; 3, ulcerated section of the epithelium. There is mild disruption of the surface epithelium and edema of submucosa layer with leukocyte infiltration of ulcerative tissues (H&E stain, 10x).

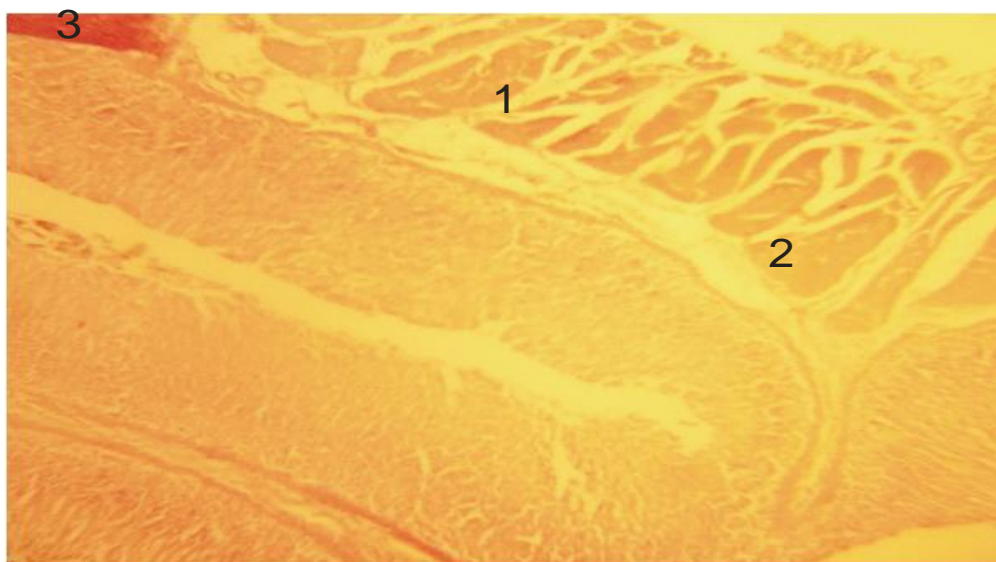


Figure 4. Histological section of the gastric mucosa in a rat pre-treated with *N. latifolia* (510 mg/kg). 1, gastric pit; 2, columnar epithelium; 3, ulcerated section of the epithelium. There is mild disruption of the surface epithelium and there is no submucosal edema and no leukocyte infiltration (H&E stain, 10x).

induced-ulcers in rats might be related to any of the mechanism suggested. Infection of the stomach mucosa with helicobacter pylori a Gram-negative spiral-shaped bacterium is now generally considered to be a major cause of gastro-duodenal ulcer (Rang et al., 2003). Although, a number of anti-ulcer drugs such as H₂ receptor antagonists, proton pump inhibitors and cytoprotectants are available for ulceration, all these

drugs have side effects and limitations. Hot aqueous extract also showed effectiveness against chloroquine resistance strains of *Plasmodium falciparum* (Benoit-Vical et al., 1998). Hot aqueous and ethanolic extracts were demonstrated to exhibit strong anti-bacterial property (Okiei et al., 2011). Alkaloid rich extract of *N. latifolia* can react *in vitro* with mammalian DNA, leading to G2-M cell cycle arrest and heritable DNA- damage. In the liver,

kidney and blood cells, it induces single strand breaks (Traore et al., 2000). Phytochemical analysis identifies indole-quinolizidine, alkaloids (glycoalkaloid), saponins and tannins as the major components (Karou et al., 2011). It has also been reported that, the flavonoids like flavones, glycosides, tannins and isoflavonoid (Indicanine B and C) have been isolated from its leaves (Yadava, 1999; Borrelli and Izzo, 2001).

Flavonoids are among the cytoprotective materials for which anti-ulcerogenic efficacy has been extensively confirmed (Di Carlo et al., 1999; Borrelli and Izzo, 2001; Galati et al., 2001). It is suggested that, these active compounds would be able to stimulate mucus, bicarbonate and the prostaglandin secretion and counteract with the deteriorating effects of reactive oxidants in gastrointestinal lumen (Salvayre et al., 1982; Asuzu and Onu, 1990; Suja et al., 2002). So the antiulcer activity of the leaf may be attributed to its flavonoids content.

Conclusion

The present study showed that pre-treatment with the leaf extract of *N. latifolia* caused a beneficial effect on indomethacin-induced gastric ulcers in rats as evident by the reduction in the ulcer index. The gastroprotective effect of the leaf extract is dose dependent and this may justify its use as an anti-ulcerogenic agent. The exact mechanism of action by which the extract protects laboratory animals from experimentally induced gastric ulcers as studied with indomethacin has not been elucidated. Further studies are necessary to isolate the responsible active compound(s) and elucidate its mechanism of actions. If these findings are extrapolated to man, aqueous leaf extract of *N. latifolia* may be beneficial to peptic ulcer-prone individuals.

ACKNOWLEDGEMENT

The authors are thankful to Mr. Christian Chukwu Bright for his active participation and contribution during the course of this work.

REFERENCES

- Abbiw KD (1990). Useful plants of Ghana, West Africa; Uses of Wild and cultivated plants, Intermediate Technology publication, London. pp. 98-212.
- Akpanabiatu MI, Umoh IB, Eyong EU, Udoh FV (2005). Influence of *Nauclea latifolia* Leaf Extracts on Some Hepatic Enzymes of Rats fed on Coconut Oil and Non-Coconut Oil Meals. *Pharm. Biolo.* 43:153-157.
- Arise RO, Akintola AA, Olarinoye JB, Balogun EA (2012). Effects of *Nauclea latifolia* stem on lipid profile and some Enzymes of Rat Liver and Kidney. *Int. J. Pharmacol.* 10(3):23-39.
- Asuzu IU, Onu OU (1990). Antiulcer activity of the ethanolic extract of *Combretum dolichopetalum* root. *Int. J. Crude Drug Res.* 28:27-32.
- Benoit-Vical FA, Valentin V, Cournac Y, Pellisier M, Mallie JM (1998). Antidepressant, myorelaxant and anti anxiety like effects of *Nauclea latifolia* (Rubiaceae) root extract in murine models. *Int. J. Pharmacol.* 6:364-361.
- Blaargawa KP, Gupta MB, Tangri KK (1993). Mechanism of ulcerogenic activity of indomethacin and oxyphenbutazone. *Eur. J. Pharmacol.* 22:191-195.
- Bolton JP, Cohen MM (1979). Effect of 16,16-dimethyl prostaglandin E2 on the gastric mucosal barrier. *Gut* 20(6):513-517.
- Borrelli F, Izzo AA (2001). The plant kingdom as a source of anti-ulcer remedies. *Phytother. Res.* 53:82-88.
- Burkil HM (1985). The useful plants of West Africa- Whifferrers Press Limited, London. 401-415.
- Chong YH (1991). Effects of palm oil on cardiovascular risk. *Med. J. Malaysia* 46:41-50.
- Clouatre D, Rosenbaum M (1994). The diet and benefits of HCA: Keats Publishing: New York. pp. 23-32.
- Deeni YY, Hussain HSN (1991). Screening for antimicrobial activity and for alkaloids of *Nauclea latifolia* J. *Ethnopharmacol.* 35:91-96.
- Di Carlo G, Mascolo N, Izzo AA, Capasso F (1999). Flavonoid: Old and new aspects of a class of natural therapeutic drugs. *Life Science* 64:337-357.
- Elujoba AAA (1995). Female infertility in the Hands of traditional Birth Attendants in South West Nigeria. *Fitoterapia* 66(3):239-248.
- Eno AE, Owo OI (1999). Cardiovascular effects of extract from the roots of a shrub *Elaeophorbia drupifera*. *phytother. Research* 13:549-554.
- Esimore CO, Ebebe IM, Chan KF (2003). Comparative antibacterial effect of Psidium guajava aqueous extract. *J. Trop. Med. Plants* 4:185-189.
- Galati EM, Monforte MT, Tripodo MM (2001). Anti ulcer activity of *Opuntia ficus indica* L. (Cactaceae): Ultrastructural study. *J. Ethnopharmacol.* pp. 76:19.
- Gidado A, Ameh DA, Atawodi SE (2005). Effect of *Nauclea latifolia* Leaves of aqueous extract on the blood glucose levels of normal and alloxane-induced diabetic rats. *Afri. J. Biotech.* 4(1):91-93.
- Ibitoye SF, Ogunleye D, Fagboun AO, Ekor M (2002). An investigation of the anti-ulcer and gastroprotective effects of *Annona muricata* (Family-Annonaceae) leaf extract in rats. *Nigerian J. Pharm.Res.* 1(1):75-77.
- Jacobson EP (1970). Comparison of prostaglandins EE2 and norepinephrine on the gastric mucosal circulation. *Proceeding of the society of Experimental Biology and Medicine.* 133: 516.
- Karou SD, Tchacondo T, Iboudo DP, Simpore J (2011). SubSaharan *Rubiaceae*: A review of their traditional uses, phytochemistry and biological activities. *Pak. J. Biol. Sci.* 149 -169.
- Main IHM, White BWR (1976). The effects of E and A prostaglandins on the gastric mucosal blood flow and the acid secretion in the rat. *British J. Pharmacol.* pp. 49: 428.
- Malairajan P, Gopalakrishnan G, Narasimhan S (2007). Anti-ulcer activity of crude alcoholic extract of *Toona ciliata* Roemer (heartwood). *J. Ethnopharmacol.* 110 (2): 348-351.
- Okiei WM, Ogunlesi EA, Osibote MK, Binutu, Ademoye MA (2011). Comparative studies of the antimicrobial activity of components of different polarities from the leaves of *Nauclea latifolia*. *Res. J. Med. Plant* 5:321-329.
- Rang HP, Dale MM, Ritter M, Moore PK (2003). *Pharmacology*, 5th edition. Churchill, Livingstones, Edinburgh, p. 797.
- Rao CV, Verma AR, Vijayakumar M, Rastogi S (2008). Gastroprotective effect of standardized extract of *Ficus glomerata* fruit on experimental gastric ulcer in rats. *J. Ethnopharmacol.* 15: 323-326.
- Raskin JB, White RH, Jackson JE, Weaver AL, Tindall EA, Lies RB, Stanton DS (1995). Misoprostol dosage in the prevention non-steroidal anti-inflammatory drug-induced gastric and duodenal ulcers. A comparison of three regimens. *Ann. Int. Med.* 123:344-350.
- Reitman S, FrankelS (1957). A colourimetric method for determination of Serum glutamate-oxaloacetate and pyruvate transaminases. *Am. J. Clin. Pathol.* 28:56-63.
- Roberts A (1979). Cytoprotection by prostaglandins. *Gastroenterology* 77:761-767.
- Roberts A, Phillips JP, Nezamis JE (1968). Effect of prostaglandin E on gastric secretion and ulcer formation in rats. *Gastroenterology* 55:481.
- Salvayre R, Braquet P, Perochot L, Douste-Blazy L (1982). Comparison

- of the scavenger effect of bilberry anthocyanosides with various flavonoids. *Flavonoids Bioflavonoids* 11:437-442.
- Schiff PL (1970). *Thalictrum* alkaloids *Lloydia* 33:403-452.
- Shah AH, Khan ZA (1997). Gastroprotective effects of pretreatment with *Zizyphus sativa* fruits against toxic damage in the rats. *Fitoterapia* 3:226-234.
- Singh GB (1997). Anti-inflammatory activity of Lupeol. *Fitoterapia* 68:9-16.
- Suja PR, Anuradha CV, Viswanathan P (2002). Gastroprotective effect of fenugreek seeds (*Trigonella foenum graecum*) on experimental gastric ulcer in rats. *J Ethnopharmacol.* 8: 393-397.
- Taiwe GS, Bum EN, Dimo T, Talla, Weiss N (2010). The Effects of aqueous extract of *Nauclea latifolia* leaf in glucose concentration in rat. A paper biochemistry and molecular biology (Calabar),1-5.
- Tan PV, Nditafon NG, Yewah MP, Dimo T, Ayafor FI (1996). *Eremomastix speciosa*: effect of leaf aqueous extract on ulcer formation and gastric secretion in rats. *J. Ethno.Pharmacol.* 54: 139-142.
- Tan PV, Nyasse B, Dimo T, Mezui C (2002). Gastric cytoprotective anti-ulcer effects of leaf methanolic extract *ocimum suave* (Lamiaceae) in rats. *J. Ethnopharmacol.* 82:69-74.
- Traore FM, Gasquet M, Laget H, Guirand, Di-Giorgio C (2000). Toxicity and genotoxicity of antimalarial alkaloidrich extracts Derived from *Myrtagyna inermis* O. kuntze and *Nauclea latifolia*. *Phytother.Res.*14:608-611.
- Udoh FV (1998). Effect of leaf and root extract of *Nauclea latifolia* on cardiovascular antagonist on radiation induced system. *Fitoterapia* 69: 141-145.
- Ukwe CV, Nwafor SV (2004). Anti-ulcer activity of leaf extract of *Persea Americana*. *Nig. J. Pharm. Res.* 3 (1):91-95.
- Vane JR (1971). L inhibition of prostaglandin synthesis as a mechanism of action for Aspirin like drugs. *Nature New Biol.* 231-232.
- Yadava RN, Reddy KIS (1999). A novel prenylated flavone glycosides from the seeds of *Erythrina indica*. *Fitoterapia* 70: 357-360.