

## Full Length Research Paper

## Nigerian mistletoe (*Loranthus micranthus* Linn) aqueous leaves extract modulates some cardiovascular disease risk factors in monosodium glutamate induced metabolic dysfunction

Emmanuel O. Ajani<sup>1\*</sup>, Olugbenga O. Ogunlabi<sup>2, 4</sup>, Bukunola O. Adegbesan<sup>2,3</sup>,  
Oluwatobi E. Adeosun<sup>2</sup> and Olalekan Akinwande<sup>2</sup>

<sup>1</sup>Department of Biosciences and Biotechnology, College of Pure and applied Sciences, Kwara State University, Malete, Kwara state, Nigeria.

<sup>2</sup>Department of Biochemistry, Faculty of Basic Medical Sciences, College of Health Sciences, Olabisi Onabanjo University, Ikenne, Ogun State, Nigeria.

<sup>3</sup>School of Pharmacy and Pharmaceutical Sciences, the University of Manchester, U. K.

<sup>4</sup>Faculty of life Science, the University of Manchester, U. K.

Received 7 July, 2014; Accepted 15 August, 2014

The safety of monosodium glutamates (MSG's) usage has generated much controversy locally and globally. This study investigates the efficacy of *Loranthus micranthus* in modulating the metabolic disorder associated with MSG intake. Thirty five (35) female rats randomized to three groups labeled 1 (7 rats), 2 (21 rats) and 3 (7 rats), respectively were used. They were administered with normal saline, MSG (200 mg/Kg) and MSG (200 mg/kg) + *L. micranthus* (600 mg/Kg), respectively for 28 days. Seven rats were then sacrificed from each group. The remaining rats in group 2 were then redistributed to groups labeled 4 and 5 consisting of 7 rats each. MSG was then withdrawn from all the rats. Group 4 was treated with *L. Micranthus* (600 mg/Kg) while normal saline was administered to group 5. All administrations were carried out for 30 days. The rats were then sacrificed and the serum was used for analysis. Analysis showed increase total cholesterol, triglyceride, low-density lipoprotein (LDL) - cholesterol, glucose and total protein concentrations and a reduced high-density lipoprotein (HDL) - cholesterol (when MSG was administered). These parameters were restored to normal with *L. micranthus* treatment. Although no histological change was observed in the uterus, there was a significant increase in organs relative weight when rats were placed on MSG but this was reversed with *L. micranthus*. The study suggests the efficacy of *L. micranthus* in reversing cardiovascular disorder and its ability to prevent MSG induced fibroid in rat.

**Key words:** Cardiovascular diseases, cholesterol, Lipid profile, *Loranthus micranthus*, of monosodium glutamates (MSG).

### INTRODUCTION

A report by World Health Organization (WHO) indicates that over 80% of the world population still relies on herbs

for treatment of diseases and in the past few decades, there has been an increasing demand for medicinal plants

and plant products as alternative to orthodox medicines especially in developing countries (Bright, 2013; WHO, 2008).

Mistletoes are a polyphyletic group of flowering plants comprising over 1300 species from a broad range of habitats across all continents except Antarctica (Nickrent, 2001). They are semiparasitic plants and grow on various host trees and shrubs where they survive by depending on their respective host for mineral nutrition and water, although they produce their own carbohydrates through photosynthesis (Griggs, 1991). Mistletoe was described as "an all-purpose herb" due to its rich traditional uses and it has been widely used in ethnomedicine for various purposes, including antihypertensive, anticancer, anti-spasmodic, antidiabetic and for treatment of epilepsy, headache, infertility, menopausal syndrome and rheumatism (Moghadamtousi et al., 2013).

Nigeria has wide distribution of mistletoes with different local names that depend on the area where they occur. *L. micranthus*, a member of the Loranthaceae family is a Nigeria species of the African mistletoe. It grows on various host trees including *Persia americana*, *Baphia nitida*, *Kola acuminata*, *Pentaclethra macrophylla*, and *Azadirachta indica* (Osadebey et al., 2012, Moghadamtousi et al., 2013). The plant is widely reputed in folk medicine for its use as antimicrobial, antihypertensive, anticancer, and antidiabetic agent and also for the treatment of headache, infertility, epilepsy, cardiovascular diseases, menopausal syndrome, agglutination, and rheumatism. Some of these ethnomedicinal uses have been supported with scientific data in the literatures (Nkanu et al., 2002; Osadebe and Ukweze; 2004, Grossarth et al., 2007; Orji et al., 2013). Of particular interest to this study is the reported use of the plant among some local people in Nigeria for the management of fibroid [an overgrowth of tissue in the endometrium (inner lining of the uterus)] in women.

Monosodium glutamate (MSG), (2-amino pentane dioic or 2-amino glutaric acid) is the sodium salt of the non-essential amino acid glutamic acid commonly used as a flavor enhancer especially in foods. It is a popular condiment in Nigeria and marketed as Ajinomoto, vedan, vetsin, Accent and Tasting powder (Palamisamy et al., 2012; Ogunlabi et al., 2014). Despite its wide uses, the safety of MSG's usage has generated much controversy. In Nigeria, many people often use MSG as a bleaching agent for the removal of stains from clothes (Obochi et al., 2009; Eweka, 2007). As a result, there is a growing apprehension that its excellent bleaching properties could be harmful to the stomach mucosa or worse still inducing terminal diseases in consumers when ingested as a flavor enhancer in food (Huthman et al., 2009; Eweka, 2007). To support this, some authors have reported brain

damaging potentials, stunted skeletal development, behavioral aberration, neuro-endocrine disorder, possible learning deficits, seizures (epileptic fits), learned taste aversion and hyperglycemia as possible adverse effects of abuse of the use of MSG (Farombi and Onyema, 2006; Onyema et al., 2006; Ortiz et al., 2006).

Some studies have shown that MSG induces oxidative stress and hepatotoxicity in rats (Onyema et al., 2012; Onyema et al., 2006; Diniz et al., 2004) as well as impaired glucose-induced insulin secretion by pancreatic islets of obese mice (Andreazzi et al., 2009). Another report by Park et al. (2010) proposed that MSG produces altered lipid profile with elevation in reactive oxygen species (ROS) formation and reduction of antioxidant activities. This observation agrees with earlier studies that reported hyperleptinemia (Hollopeter et al., 1998), adiposity and increase of plasma fatty acids and triacylglycerols (Dawson et al., 1997) with oral administration of MSG into rats. Obochi et al. (2009) also reported that MSG administration leads to increased cholesterol, protein and oestrogen which lead to induction of fibroid in rats.

Therefore, the present study was carried out to investigate the efficacy of *L. micranthus* in preventing or reversing alter plasma lipid profile and cardiovascular disease risk factors associated with MSG administration in rats.

## MATERIALS AND METHODS

### Monosodium glutamate

MSG was obtained from Sigma Chemical Company Japan. A solution was prepared by dissolving 10 g of MSG in 500 ml distilled water.

### Plant authentication and extraction

Fresh leaves of mistletoe were obtained from a farm garden at Odogbolu, Ogun State, Nigeria in August 2013. The plant was identified as *L. micranthus* at the Botany Department of Olabisi Onabanjo University, Ago-Iwoye, Ogun State. A voucher number EH135IO was thereafter assigned after which specimen was deposited at the herbarium. The leaves were then washed and air dried at room temperature for two weeks. The dried leaves were pulverized into coarse form. The coarse powdered form was weighed and 362 grams was soaked in 1000 ml distilled water. The mixture was left to stand for 48 h with occasional stirring. The extracted product was then sieved into a clean container and further concentrated using a rotary evaporator at 40°C. The concentrated product was then lyophilized. The yield of the extract was 8.7%.

### Experimental design

Thirty five (35) mature virgin female Wistar rats weighing 155 to

\*Corresponding author. E-mail: emmanuel.ajani@kwasu.edu.ng. Tel: +234805553192.

164 g were used in the study. The rats were obtained from the animal house, Department of Physiology, Olabisi Onabanjo University, Ago-Iwoye, Nigeria and were acclimatized for seven days at the Animal Facility Centre, Department of Biochemistry, Olabisi Onabanjo University, Nigeria. All the animals were housed in metallic cages and maintained in well ventilated room provided with 12:12 h light and dark cycle for each 24 h period at a temperature of approximately 25°C. They were all maintained on standard rat pellets and tap water *ad libitum* throughout the period of the study. All the rats used in the study showed regular estrous cycle length (4 to 5 days). The phases of estrous cycle were determined by observing the vaginal smear in the morning (08: 00h to 10:00 h) according to procedure described previously (Solomon et al., 2010). The animals were initially randomly assigned to three groups labeled as normal control/group 1 (7 rats), test control /group 2 (21 rats) and test group / group 3 (7rats). Rats in each group were treated as follow: Group 1 (Normal control): administered with normal saline; Group 2 (Test control): administered with MSG (200 mg/kg body weight); Group 3 (Test group): administered with MSG (200 mg/kg b. w) and *L. micranthus* 600 mg/kg body weight).

All administrations were carried out as a single dose daily for 28 days by oral galvage. After 28 days of administration, seven rats were sacrificed from each group after 12 h fasting; the rats were then evaluated on the basis of preventive effects of *L. micranthus*. The remaining rats in group 2 were redistributed to two groups of seven rats each, labeled, group 4 (extract treated) and 5 (self-recovery). Administration of MSG was discontinued in the two groups while rats in group 4 were administered with *L. micranthus* (600 mg/kg) extract; rats in group 5 were treated with normal saline. All administrations were carried out for the next 30 days after which the rats were sacrificed.

All the rats were sacrificed after anesthesia with diethyl ether in a closed jar. Blood was collected by cardiac puncture into plain bottles and the rats were evaluated based on the curative potential of the extract. The uterus, kidney and liver were harvested cleaned of blood and weighed. The uterus was thereafter used for histopathology study.

### Biochemical assay

Initial and the final body weight of all the rats were measured using a Mettler weighing balance (Mettler Toledo Type BD6000, Greifensee, Switzerland). Serum was prepared from the collected blood samples by centrifugation and used for analysis. Fasting blood glucose was measured according to method adopted previously by Miwa et al. (1972) using a glucose kit (enzymatic method) (Sigma). Serum protein determination was by the method of Lowry et al. (1951). Triglyceride was determined using enzymatic colorimetric kits (Wahlefeld, 1974). Both total cholesterol and HDL-C were determined in the serum by the methods previously described (Stein, 1986). From the results, LDL cholesterol was calculated based on the method of Friedewald et al. (1972). According to the method, LDL can be calculated as follows:

$$\text{LDL} = \text{Total cholesterol} - \text{HDL-TG}/5$$

Atherogenic index was calculated from serum HDL and cholesterol levels using the equation previously reported by Gillies et al. (1986).

$$\text{Atherogenic index} = \frac{\text{Serum cholesterol level} - \text{serum HDL level}}{\text{Serum HDL level}}$$

Coronary risk index was obtained by the method of Alladi and Khada (1989).

$$\text{Coronary risk index (CRI)} = \frac{\text{Total cholesterol}}{\text{HDL- cholesterol}}$$

### Histopathology study

The dissected uterus was immersion-fixed in bouins fluid over night at room temperature after which the tissues were transferred to ascending grades of alcohol for dehydration. The tissues were cleared with two changes of xylene for one and half hours each, transferred into two changes of molten paraffin wax I and II for one and half hour each and wax- III for overnight in an oven at 65°C for infiltration.

The tissue was then processed according to the method previously described (Solomon et al., 2010). The tissue block was serially sectioned at 6 µm thickness using microtome. Strips of sections were gently lowered into the surface of a warm water bath at 40°C. The floated sections were mounted on egg albumin coated microscopic slides, and put in an oven maintained at 60°C for 30 min to fix the tissue firmly on the slide. The slides were dewaxed with two changes of xylene and hydrated with decreasing alcohol concentration and then immersed in water for 5 min. The sectioned tissues were then stained regressively with Ehrlich's hematoxylin and counter stained with Eosin.

After staining with eosin, tissues were washed in tap water and dehydrated by rinsing in increasing concentration of alcohol and then xylene-I. They were then placed in xylene-II until mounting. Finally, a drop of mountant DPX (A mixture of Distyrene, a Plasticizer, and Xylene) was placed on top of the sections and the cover slip was applied.

### Animal care

The care of the animals was in accordance with the U.S. Public Health Service Guidelines (NRC, 1999) and was approved by the Olabisi Onabanjo University, College of Health Sciences Animal Ethics Com.

### Statistics

All data were expressed as mean ±SEM. One-way analysis of variance (ANOVA) was used to analyze the data. Comparisons between the groups were made at a two-sided alpha level of 0.05.  $p < 0.05$  was considered statistically significant.

## RESULT

Table 1 depicts the variation in serum lipid profile, atherogenic index (AI) and coronary risk index (CRI) with MSG administration and during treatment with *L. micranthus*. There was a significant increase ( $p < 0.05$ ) in plasma triglyceride, total cholesterol and LDL-cholesterol and a reduction in HDL-cholesterol when MSG was administered. Combined administration of MSG with *L. micranthus* significantly brought these parameters to the pre-treatment values. Table 1 also indicates that when the rats were treated with *L. micranthus* for the 30 days after the 28 days of continuous administration of MSG, the observed values of serum triglyceride, total cholesterol, LDL-cholesterol and HDL-cholesterol (96.41±5.93, 120.16±5.93, 41.27±5.15, 26.90±4.02 mg/dl

**Table 1.** The results of the effect of *L. micranthus* treatment on plasma lipid profile, atherogenic and coronary risk indexes.

Group	Treatment	Plasma lipid profile				Atherogenic index (AI)	Coronary risk index (CRI)
		Triglyceride (mg/dl)	Total cholesterol (mg/dl)	HDL (mg/dl)	LDL (mg/dl)		
1	Normal control (normal saline)	87.03±5.90 <sup>a</sup>	102.42±2.11 <sup>a</sup>	45.91±3.63 <sup>a</sup>	20.64±4.79 <sup>a</sup>	0.45±9.01 <sup>a</sup>	2.21±0.11 <sup>a</sup>
2	Test control (MSG)	114.41±9.95 <sup>b</sup>	174.18±16.20 <sup>b</sup>	24.59±5.57 <sup>b</sup>	54.98±11.39 <sup>b</sup>	2.24±0.01 <sup>b</sup>	7.08±0.30 <sup>b</sup>
3	Test group (co-administration of MSG and <i>L. micranthus</i> )	92.71±3.82 <sup>a</sup>	118.11±5.75 <sup>a</sup>	42.09±5.19 <sup>a</sup>	26.99±4.02 <sup>a</sup>	0.64±0.03 <sup>c</sup>	2.82±0.01 <sup>a</sup>
4	Treatment with <i>L. micranthus</i> after MSG withdrawal from group 2	96.41±4.27 <sup>a</sup>	120.16±5.93 <sup>a</sup>	41.27±5.15 <sup>a</sup>	30.01±5.11 <sup>a</sup>	0.73±0.11 <sup>c</sup>	2.91±0.10 <sup>a</sup>
5	Normal saline after withdrawal of MSG from group 2	113.88±8.70 <sup>b</sup>	171.63±15.31 <sup>b</sup>	25.45±5.59 <sup>b</sup>	54.09±11.00 <sup>b</sup>	2.43±0.02 <sup>b</sup>	6.74±0.10 <sup>b</sup>

Values are mean± SEM of 7 determinations, All mean in the same column with similar superscripts are not significantly different from each other, Significant between the mean were established at p<0.05.

**Table 2.** Effect of *L. micranthus* treatment on fasting blood glucose and total protein.

Group	Treatment	Fasting blood glucose (mg/dl)	Serum protein (mg/dl)
1	Normal control (normal saline)	82.00±0.93 <sup>a</sup>	9.89±0.48 <sup>a</sup>
2	Test control (MSG)	112.00±3.86 <sup>b</sup>	24.55±2.80 <sup>b</sup>
3	Test group (co-administration of MSG and <i>L. micranthus</i> )	89.83±2.57 <sup>a</sup>	11.13±0.88 <sup>a</sup>
4	Treatment with <i>L. micranthus</i> after MSG withdrawal from group 2	91.67±2.11 <sup>ab</sup>	19.82±0.84 <sup>c</sup>
5	Normal saline after withdrawal of MSG from group 2	97.67±1.65 <sup>b</sup>	25.46±3.00 <sup>b</sup>

Values are mean± SEM of 7 determinations. All mean in the same column with similar superscripts are not significantly different from each other. Significance between the mean were established at p<0.05.

respectively) were not significantly different from the values obtained when MSG and *L. micranthus* were co-administered for 28 days (92.71±3.82, 118.11±5.75, 42.09±5.19, 26.99±4.02 mg/dl respectively). When compared however, the serum lipid of rats that were allowed to recover by itself (without treatment after 28 days administration of MSG) were not different from the observed values prior to withdrawal of MSG. Table 1 also show a significant increase (p<0.05) in atherogenic and coronary risk indexes during MSG administration and when the rats were

allowed to recover from MSG administration without treatment (when compared with the normal control values). However, combined administration of MSG and *L. micranthus* and treatment with *L. micranthus* after the initial administration of MSG brought the coronary risk index to the pre-treatment values. Although the atherogenic index values were raised above the normal control level both during combined administration of MSG and *L. micranthus* and when *L. micranthus* was administered after withdrawal of MSG, the observed AI were

significantly lowered than the values observed when MSG was administered alone and was also higher than the value that was obtained during the self-recovery process.

Administration of MSG significantly increased (p<0.05) the fasting blood glucose above the normal control value (Table 2). Thirty (30) days after withdrawal of MSG without subsequent treatment, the fasting blood glucose level was still observed to be significantly higher (p<0.05) than the normal control value. When MSG was however co-administered with *L. micranthus*, the

**Table 3.** Effect of treatment on body weight changes and relative organ weight ratio.

Group	Treatment	Body weight (g)	Organ weight (g)			Organ/body weight ratio (%)		
			Kidney	Uterus	Liver	Kidney	Uterus	Liver
1	Normal control (normal saline)	175.83±2.71 <sup>a</sup>	1.22±0.05	4.81±0.35	0.33±0.02	0.73±0.02 <sup>a</sup>	0.20±0.02 <sup>a</sup>	2.90±0.62 <sup>a</sup>
2	Test control (MSG)	175.00±4.28 <sup>a</sup>	1.32±0.02	4.90±0.26	0.43±0.04	0.88±0.06 <sup>b</sup>	0.36±0.04 <sup>b</sup>	3.51±0.30 <sup>b</sup>
3	Test group (co-administration of MSG and <i>L. micranthus</i> )	175.67±4.00 <sup>a</sup>	1.27±0.10	4.84±0.55	0.35±0.02	0.76±0.05 <sup>a</sup>	0.23±0.05 <sup>a</sup>	2.93±0.19 <sup>a</sup>
4	Treatment with <i>L. micranthus</i> after MSG withdrawal from group 2	179.72±5.83 <sup>a</sup>	1.29±0.11	4.82±0.41	0.40±0.02	0.76±0.02 <sup>a</sup>	0.23±0.01 <sup>a</sup>	2.98±0.34 <sup>a</sup>
5	Normal saline after withdrawal of MSG from group 2	174.17±6.38 <sup>a</sup>	1.41±0.03	4.88±0.26	0.44±0.03	0.73±0.06 <sup>a</sup>	0.52±0.02 <sup>b</sup>	3.61±0.19 <sup>b</sup>

Values are mean± SEM of 7 determinations. All mean in the same column with similar superscripts are not significantly different from each other. Significance between the mean were established at  $p < 0.05$ .

observed fasting blood glucose level of 89.83±2.57 mg/dl was neither different from the normal control value nor was it different from the fasting blood glucose level of 91.67±2.11 mg/dl observed when *L. micranthus* was administered continuously for 30 days after MSG withdrawal. Similarly, administration of MSG was observed in the study to increase the serum total protein significantly ( $p < 0.05$ ) above the normal control value. The observed serum protein concentration of 24.55±2.80 mg/dl after 28 days of MSG administration was not different from the value of 25.46±3.00 mg/dl observed 30 days after withdrawal of MSG without treatment. Combined administration of MSG and *L. micranthus* significantly brought the serum protein concentration to the pre-treatment level. When *L. micranthus* was administered for 30 days after withdrawal of MSG, the serum protein concentration was observed to be lower than the value obtained in the group of rats that were not treated though the observed value was still higher than the value in the normal control group.

Table 3 is the result of the effect of treatment on percentage relative change in kidney, liver and uterus weights. Administration of MSG signifi-

cantly increased ( $p < 0.05$ ) the percentage relative weight of the uterus, kidney and liver above the normal control value. The same trend was maintained when the weights were monitored 30 days after MSG withdrawal without treatment. The result however showed that combined administration of MSG and *L. micranthus* and treatment of the rats with *L. micranthus* for 30 days after MSG withdrawal restored the relative organ weights to the pre-treatment level.

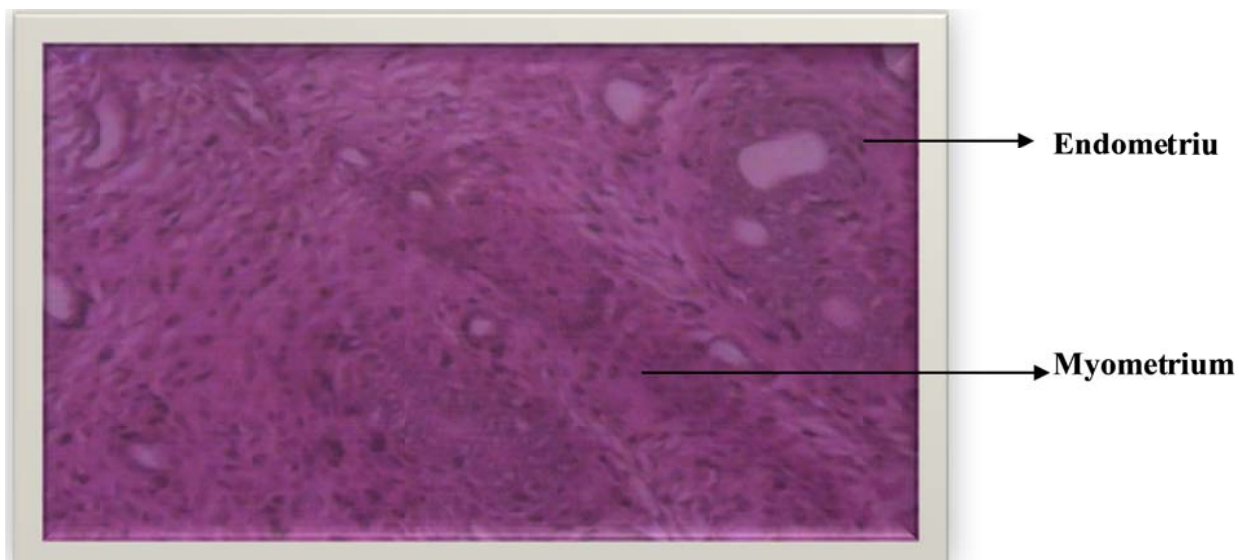
Figures 1 to 5 is the result of the effect of treatment on the histology of endometrium of the uterus. The uterine histology of the control rats showed normal features: single layered columnar epithelial cell with elongated nuclei at the base of the cells, highly folded epithelial lining, numerous and tortuous endometrial glands (Figure 1). No significant alterations were also observed in the histology of all other treatment groups.

## DISCUSSION

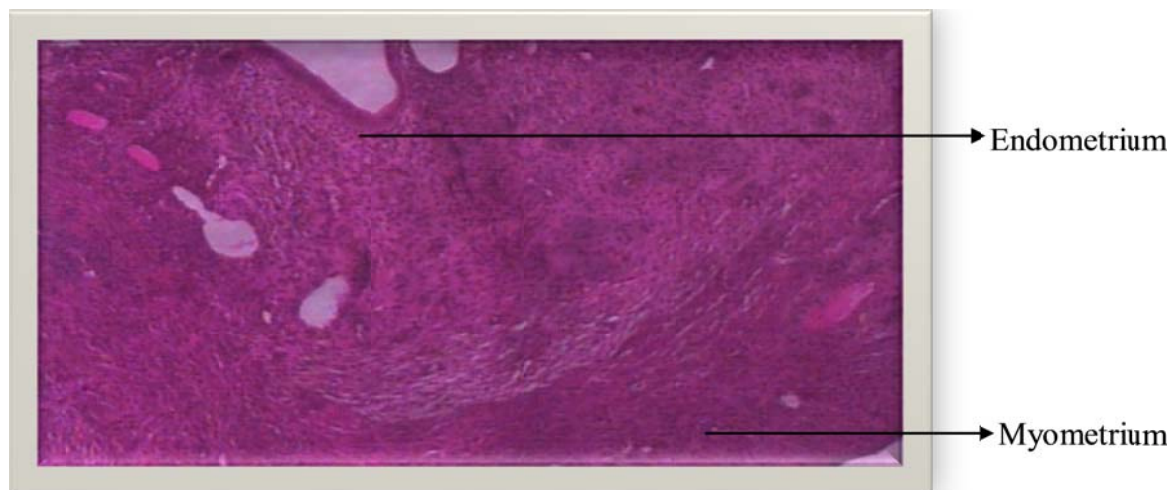
Iwase et al. (1998) and Suga et al. (1999) has reported that post-natal administration of MSG in rats induces insulin resistance, body weight gain,

hyperleptinemia and serum glucose level alteration even though the exact mechanisms for these alterations were not clearly defined. In an effort to find out the exact mechanisms by which MSG predispose to tissue injuries, a study by Onyema et al. (2006) reported that MSG is capable of inducing oxidative stress which leads to hepatotoxicity in rats. Another study with obese mice also reported that MSG may impair insulin secretion by pancreatic islets (Andreazzi et al., 2009).

The report from our study confirmed that MSG is capable of causing metabolic alterations in rats. In line with previous study, our study has demonstrated that oral administration of MSG in rats could cause metabolic abnormalities in lipid metabolism which is indicated by marked elevation serum total cholesterol, triglyceride and LDL-cholesterol (hyperlipidemia) with concomitant decrease in plasma HDL-cholesterol level. These observations are in agreement with previous reports by some other authors (Obochi et al., 2009; Pal, 2009; Ogunlabi et al., 2014). This alteration in plasma lipid profile was also reflected in increased atherogenic and coronary risk indices. This is in agreement with report by



**Figure 1.** Photomicrographs of hematoxylin and eosin stained tissue cross-section of the control rat showing a normal histological picture of a uterine tissue. Photographed at a magnification x 400

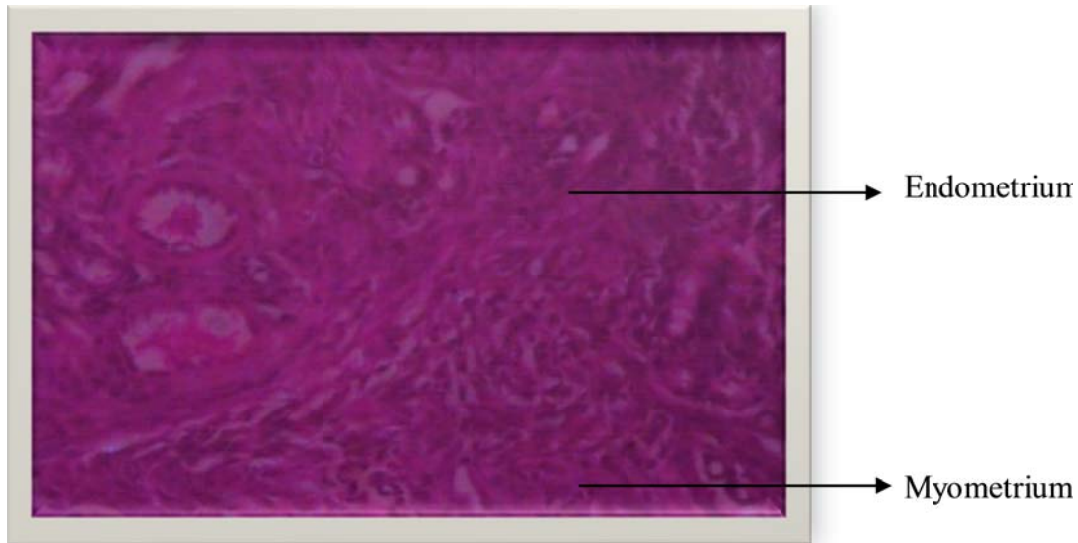


**Figure 2.** Photomicrographs of hematoxylin and eosin stained tissue cross-section of the MSG administered rat showing a normal histological picture of a uterine tissue. Photographed at a magnification x 400.

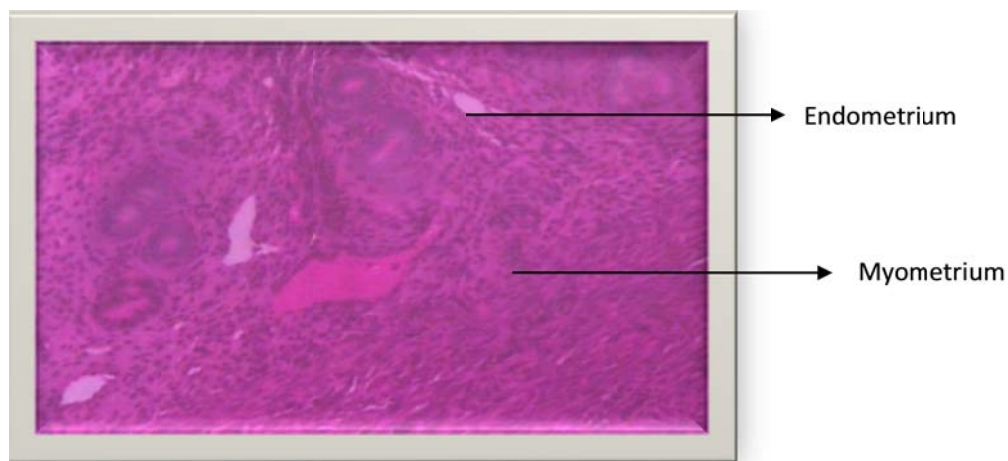
Nagata et al. (2006). Our study also shows that both combined administration of MSG and *L. micranthus* and treatment with *L. micranthus* after prolonged exposure to MSG is capable of ameliorating these serum lipid alterations. It has been proposed that MSG elevates reactive oxygen species (ROS) formation and reduction of antioxidant activities (Park et al., 2010) which we opined may be the biochemical basis for the altered lipid profile. Some authors have reported that MSG induces oxidative stress and Reactive Oxygen Species (ROS) production which have been noted play specific roles in

the modulation of cellular events (Diniz et al., 2005; Nagata et al., 2006). The ROS react with protein thiol moieties to produce a variety of sulfur oxidations, thus diminishing the insulin receptor signal and inhibiting cellular uptake of triacylglycerol from the blood (Mohamed et al., 2008; Chen et al., 2003). Some studies have linked hypertriglyceridemia to higher serum small dense LDL particles, atherothrombosis and impaired endothelial function, the hallmarks of several prevalent cardiovascular diseases as well as their complications (Lupattelli et al., 2000; Lundman et al., 2001; Ginsberg,





**Figure 3.** Photomicrographs of hematoxylin and eosin stained tissue cross-section of the MSG + *L. micranthus* administered rat showing a normal histological picture of a uterine tissue. Photographed at a magnification x 400.

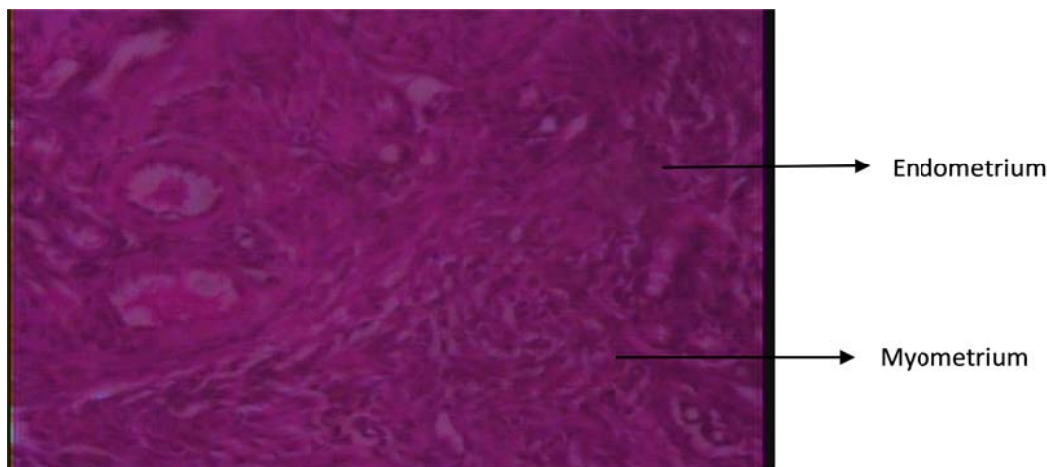


**Figure 4.** Photomicrographs of hematoxylin and eosin stained tissue cross-section of the MSG + *L. micranthus* treated rat (post administration) showing a normal histological picture of a uterine tissue. Photographed at a magnification x 400.

2002).

The elevated serum concentration of total cholesterol noted in the rats administered with MSG suggests that MSG predispose to hypercholesterolemia. The increase in the levels of LDL-cholesterol with a simultaneous decreased concentration of HDL-cholesterol reflected that MSG will induce abnormalities in lipoprotein metabolism. Because of the changes in the cholesterol profile and other lipid molecules noted in the present study in the MSG-treated rats, we opined that they may be due to the ability of MSG toxicity to inhibit the activity of hydroxy 3-methylglutaryl-coenzyme A reductase (HMG-CoA)

which plays an important regulatory role in cholesterol biosynthesis, and inhibition of its activity is known to alter the metabolism of all lipids, including cholesterol (Ness and Chambers, 2000). Hypercholesterolemia and abnormalities in lipoprotein metabolism are considered as serious risk factors and important early events in the pathogenesis of atherosclerosis in both peripheral and coronary circulation (Maxfield and Tabas, 2000; Mallick, 2007; Grover-Paez and Omez, 2009). Lipid compounds and products of their oxidation especially LDL accumulate during formation of atherosclerotic lesions (Mallick, 2007).



**Figure 5.** Photomicrographs of hematoxylin and eosin stained tissue cross-section of the MSG administered rat treated with normal saline showing a normal histological picture of a uterine tissue. Photographed at a magnification x 400.

The LDL functions in the atheroma formation whereas the HDL plays an important role in inhibiting the formation of atheroma (Maxfield and Tabas, 2000; Mallick, 2007). The antiatherosclerotic action of HDL resides in its ability to remove cholesterol from vascular wall, stimulate prostacyclin formation and inhibit the synthesis of adhesive molecules (Pal, 2009). So, lowering the plasma lipid levels through dietary or drug therapy may be beneficial in decreasing the risk of vascular disease.

As regards the ability of *L. micranthus* to reverse these alterations as reported in this study, we opined, that it is an indication of the efficacy of *L. micranthus* to prevent predisposition to cardiovascular disease and atherogenesis during MSG intake. Species of mistletoe, *Viscum album* was reported in a previous study carried out by Yusuf et al. (2013) to show a dose-dependent relationship for the reducing ability, free radical scavenging and the  $Fe^{2+}$  chelating tendency. The study observed that *V. album* extracts from cola tree compares favorably with the standards agents (ascorbic acid, ethylenediamine tetraacetic acid and buthylated hydroxytoluene used. A phytochemical screening report by Orji et al. (2013) indicated the presence of tannins, flavonoids, saponins, phenols, alkaloids and anthocyanins in the leaves of ethanolic extracts of *L. micranthus* leaves. A correlation between the total phenol content of plant food and their antioxidant properties has been well reported. This may be the biochemical explanation for the efficacy of *L. micranthus* leaves extract as reported in this study. Another hypothesis may be that *L. micranthus* is efficacious in decreasing HMG-CoA reductase activity (an enzyme required for cholesterol synthesis) thereby decreasing the predisposition to increase atherogenic and coronary risk index of MSG (Arai et al., 2000; Lapointe et al., 2006).

The results of our study also show that, administration of MSG to rats induced hyperglycemia which is indicated

by elevated level of fasting blood glucose when compared with the normal control rats. Our result corroborates previous report by some other authors who attributed the increase in serum glucose in response to MSG administration to hypertrophy of pancreatic islets with associated hyperinsulinemia, an early marker of insulin resistance, together with impaired glucose uptake by tissues due to the decrease in the number of glucose transporter-4 (GLUT 4) (Seraphim et al., 2001; Diniz et al., 2005; Nagata et al., 2006). Insulin resistance is often associated with clustering of coronary risk factors, which leads to an increased risk of cardiovascular disease, presumably due to promotion of atherosclerosis (Zavaroni et al., 1989; Roberts and Sindhu, 2009). The observed hypertriglyceridemia induced with MSG administration reported in our study may thus be a response to the increased blood glucose level. A positive correlation between hypertriglyceridemia and hyperglycemia induced by MSG has been previously reported (Nayira et al., 2009). The regulation of energy balance is essential to maintain the control of metabolism and body composition (Scharrer, 1999). Importantly, MSG has been widely used to induce obesity through hypothalamic lesions in neonatal period (Nakayama et al., 2003). Though a study by Grassioli et al. (2007) reported glucose disturbances only in neonatal MSG-treated animals compared to adult MSG treatment our study observed elevated fasting blood glucose in adult female rats placed on MSG. For one of the main causes of hyperglycemia in these rats, we opined, it may be related to a decreased amount of GLUT 4 protein found in adipocytes (Macho et al., 2000). It seems true that insulin sensitivity is influenced by the redox state of the organism, whereby oxidative processes may trigger the development of insulin resistance (Evans et al., 2002). Data has been reported to prove that ROS react with protein thiol moieties to produce a variety of sulfur oxida-



tions which attenuates insulin receptor signal and inhibits cellular uptake of triglyceride from blood stream (Chen et al., 2003). This may be the basis for the observed increased plasma triglyceride levels in MSG animals reported in this study.

MSG was also observed in this study to increase the level of total protein. Elevated total protein and cholesterol among some other alterations has been implicated in the induction of fibroid in rats (Obochi et al., 2009). The effect of MSG on protein alteration has been attributed to the activation of transcriptional promoter and enhancer elements used for the control of gene expression which promoted the ability of RNA polymerase to recognize the nucleotide at the initiation stage thereby increasing protein synthesis (Obochi et al., 2009). Our report also shows the efficacy of *L. micranthus* extract to reverse these alterations.

Organ weights are widely accepted in the evaluation of test article-associated toxicities (Black, 2002; Bucci, 2002; Woolley, 2004). In toxicological experiments, comparison of organ weights between treated and untreated groups of animals have conventionally been used to evaluate the toxic effect of the test article and its changes often precede morphological changes. Data from our study indicates that oral administration of MSG predispose to increased relative organ weight of the tissues investigated. This result corroborates previous report by Manal and Nawal (2012) where treatment with MSG was reported to lead to increased liver and kidney relative weight. *L. micranthus* was also observed in this study to be able to restore the relative organ weight in the treated rats to the normal level. When the histopathology of the uterus was however compared, these variations in relative organ weight were not seen to be accompanied with gross morphological changes.

## Conclusion

In conclusion, MSG was seen to have predisposed to serious biochemical alterations and that both pretreatment with *L. micranthus* and administration of *L. micranthus* subsequent to MSG withdrawal successfully improves these parameters and ameliorates the metabolic alterations caused by MSG administration. Furthermore, *L. micranthus* administration is reported in this study to normalize the MSG induced weight changes in the liver, kidney and uterus of rats.

## Conflict of Interests

The author(s) have not declared any conflict of interest.

## REFERENCES

Alladi S, Khada SM (1989). Induction of hypercholesterolemia by

- supplementing soy protein with acetate generating amino acids. *Nutr. Rep. Int.* 40: 893-899.
- Andreazzi AE, Scomparin DX, Mesquita FP, Balbo SL, Gravena C, De Oliveira JC (2009). Swimming exercise at weaning improves glycemic control and inhibits the onset of monosodium L-glutamate-obesity in mice. *J. Endocrinol.* 201:351-359
- Arai Y, Watanabe S, Kimira M, Shimoi K, Mochizuki R, Kinai N (2000). Dietary intakes of flavonols, flavones and isoflavones by Japanese women and the inverse correlation between quercetin intake and plasma LDL cholesterol concentration. *J. Nutr.* 30:2243-2250
- Black H (2002). Preparation of the report for a toxicology/pathology study. In: Haschek WM, Rousseaux CG., Wallig MA, eds. *Handbook of Toxicologic Pathology.* Academic Press, San Diego, CA. pp. 419-433.
- Bright A (2013). Utilization of traditional herbal medicine and its role in health care delivery in Ghana: The case of Wassu Amenfi West District. A Thesis submitted to the Department of Geography and Rural Development. Kwame Nkrumah University of Science and Technology.
- Bucci TJ (2002). The practice of toxicologic pathology: basic techniques. In: Haschek WM, Rousseaux CG, Wallig MA, eds. *Handbook of Toxicologic Pathology.* Academic Press, San Diego, CA. pp. 681-784.
- Chen K, Thomas SR, Keaney JF (2003). Beyond LDL oxidation: ROS in vascular signal transduction. *Free Radic. Biol. Med.* 35: 117-132.
- Dawson R, Pellemounter MA, Millard WJ, Liu S (1997). Attenuation of leptin-mediated effects by monosodium glutamate-induced arcuate nucleus damage. *Am. J. Physiol.* 22:E202-E206
- Diniz YS, Faine LA, Galhardi CM, Rodrigues HG (2005). Monosodium glutamate in standard and high-fiber diets: Metabolic syndrome and oxidative stress in rats. *Nutrition* 21:749-755.
- Diniz YS, Fernandes AA, Campo KE, Mani F, Ribas BO, Novelli EL. (2004). Toxicity of hypercaloric diet and monosodium glutamate: oxidative stress and metabolic shifting in hepatic tissue. *Food Chem. Toxicol.* 42(2):319-325.
- Evans JL, Goldfine ID, Maddux BA, Grodsky GM (2002). Oxidative stress and stress-activated signaling pathways: a unifying hypothesis of type 2 diabetes. *Endocr. Rev.* 23: 599-622
- Eweka AO (2007). Histological studies of the effects of Monosodium-glutamate on the medial geniculate body of adult wistar rats. *Internet J. Health* 6(2):121-128.
- Farombi EO, Onyema OO (2006). Monosodium glutamate - induced oxidative damage and genotoxicity in the rat: modulatory role of vitamin C, vitamin E and quercetin. *Hum. Exp. Toxicol.* 25: 251-259.
- Friedewald WT, Levy RI, Fredrickson DS (1972). Estimation of the concentration of low-density lipoprotein cholesterol in plasma, without use of the preparative ultracentrifuge. *Clin. Chem.* 18: 499-502
- Gillies PJ, Rathgeb KA, Perri MA, Robinson JL (1986). Regulation of acyl-oA: Cholesterol acyltransferase activity in normal and atherosclerotic rabbit aortas: Role of a cholesterol substrate pool. *Exp. Mol. Pathol.* 44: 329-339.
- Ginsberg HN (2002). New perspectives on atherogenesis: Role of abnormal triglyceride-rich lipoprotein metabolism. *Circulation* 106: 2137-2142
- Grassioli S, Gravena C, de Freitas M, Mathias PC, Muscarinic M (2007). H receptor is active on pancreatic islets from hypothalamic obese rat. *Eur. J. Pharmacol.* 556: 223-228.
- Griggs P (1991). Mistletoe, myth, magic and medicine. *Biochemist* 13: 3-4.
- Grossarth MR, Ziegler R (2007). Prospective cohort studies on long term therapy of cervical cancer patients with mistletoes preparations *Forsch Komplementmed.* 14: 140-147.
- Grover-Paez F, Omez ABZ (2009). Endothelial dysfunction and cardiovascular risk factors. *Diabetes Res. Clin. Practice.* 84: 1-10.
- Hollopeter G, Erickson JC, Palmiter RD (1998). Role of neuropeptide Y in diet-, chemical- and genetic-induced obesity of mice. *Int. J. Obes. Relat. Metab. Disord.* 22:506-512.
- Huthman I, Shoyebo O, Akinbowale O, Ajayi R, Huthman A, Adenowo T, Adefule A. (2009). *Monosodium Glutamate: A Good Replacement For Hydrogen Peroxide In Bone Preparations.* *Internet J. Biol. Anthropol.* 4 (1): 45-51.
- Iwase M, Yamamoto M, Lino K, Ichikawa K, Shinohara N, Yoshinari M

- (1998). Obesity induced by neonatal monosodium glutamate treatment in spontaneously hypertensive rats: an animal model of multiple risk factors. *Hypertens. Res.* 21:1-6.
- Lapointe A, Couillard C, Lemieux S (2006). Effects of dietary factors on oxidation of low-density lipoprotein particles. *J. Nutr. Biochem.* 17:645-658.
- Lowry DH, Rosebrough NJ, Farr AL (1951). Protein measurement with the folin-phenol reagent. *J. Biol. Chem.* 193:265-275.
- Lundman P, Eriksson MJ, Stuhlinger M, Cooke JP, Hamsten A, Tornvall P (2001). Mild-to-moderate hypertriglyceridemia in young men is associated with endothelial dysfunction and increased plasma concentrations of asymmetric dimethylarginine. *J. Am. Coll. Cardiol.* 38:111-116.
- Lupattelli G, Lombardini R, Schillaci G, Ciuffetti G, Marchesi S, Siepi D, Mannarino E (2000). Flow-mediated vasoactivity and circulating adhesion molecules in hypertriglyceridemia: Association with small, dense LDL cholesterol particles. *Am. Heart J.* 140:521-526.
- Macho L, Ficková M, Jezová C, Zórad S (2000). Late effects of postnatal administration of monosodium glutamate on insulin action in adult rats. *Physiol. Res.* 49: S79-S85.
- Mallick HN (2007). Understanding safety of glutamate in food and brain. *Ind. J. Physiol. Pharmacol.* 51:216-234.
- Manal ST, Nawal AB (2012). Adverse Effects of Monosodium Glutamate on Liver and Kidney Functions in Adult Rats and Potential Protective Effect of Vitamins C and E. *Food Nut. Sci.* 3:651-659.
- Maxfield FR, Tabas I (2005). Role of cholesterol and lipid organization in disease. *Nature* 438:612-621
- Miwa I, Okuda J, Maeda K, Okuda G (1972). Mutarotase effect on colorimetric determination of blood glucose with D-glucose oxidase. *Clin. Chem. Acta.* 37: 538-540.
- Moghadamtousi SZ, Hajrezaei M, Abdul Kadir H, Zandi K. (2013). *Loranthus micranthus* Linn.: Biological Activities and Phytochemistry. Evid. Based Complement. Alternat. Med. 9 pages. Article ID 273712.
- Mohamed ME, Nagawa MNE, Inas ED (2008). The possible cytoprotective effect of vitamin C and E and L-carnithine on monosodium glutamate induced oxidative stress in the rat. *Bull. Alex. Fac. Med.* 44(1):205-211
- Nagata MW, Suzuki S, Iizuka M, Tabuchi C, Maruyama H (2006). Type 2 diabetes mellitus in obese mouse model induced by monosodium glutamate. *Exp. Anim.* 55: 109-115.
- Nakayama D, Magami Y, Azuma T, Inokuchi H, Furukawa M, Ohyashiki J (2003). Turnover of acinar and islet cells in the pancreas of monosodium glutamate-treated obese mice. *Obes. Res.* 11:87-94.
- National Research Council (NRC) (1999). Guide for the Care and Use of Laboratory Animals. National Academy Press, Washington, DC.
- Nayira A, Abdel BA, Mohamed M, Faddah LM (2009). Protective Effect of N-acetyl Cysteine and/or Pro Vitamin A against Monosodium Glutamate-Induced Cardiopathy in Rats. *J. Pharmacol. Toxicol.* 4:178-193.
- Ness GC, Chambers CM (2000). Feedback and hormonal regulation of hepatic 3-hydroxy-3-methylglutaryl coenzyme a reductase: The concept of cholesterol buffering capacity. *Proc. Soc. Exp. Biol. Med.* 224: 8-19.
- Nickrent DL (2001). Mistletoe Phylogenetics: Current relationships gained from analysis of DNA sequences. In Geils B and Mathiasen R eds. *Proc. West. Int. For. Dis. Work Conf., USDA for. Serv., Kona HI.*
- Nkanu RE, Umoh FB, Ofem DT, Eno AE (2002). The effect of ageous extract from the leaves of European Mistletoe on blood glucose level and lipid profile in male wistar rats. *NG J. Physiol. Sci.* 7: 108-112.
- Obochi GO, Malu SP, Obi-Abang M, Alozie Y, Iyam MA (2009). Effect of garlic extracts on monosodium glutamate (MSG) induced fibroid in wistar rats. *Pak. J. Nut.* 8(7):970-976.
- Ogunlabi OO, Adegbesan BO, Sumaoya OB, Ajani EO (2014). Modulating effects of *Allium sativum* (garlic) extract in monosodium glutamate induced injuries in rats. *Med. Plants Int. J. Phytomed. Rel. Ind.* 6(1):28-35.
- Onyema OO, Alisi CS, Ihetuge AP (2012). Monosodium Glutamate Induces Oxidative Stress and Affects Glucose Metabolism in the Kidney of Rats. *Int. J. Biochem. Res. Rev.* 2(1):1-11.
- Onyema OO, Farombi EO, Emerole GO, Ukoha AI, Onyeze GO (2006). Effect of vitamin E on monosodium glutamate induced hepatotoxicity and oxidative stress in rats. *Indian J. Biochem. Biophys.* 43:20-24.
- Orji FA, Nwachukwu NC, Onyia AU, Nkwocha JO (2013). Phytochemical and antimicrobial properties of leaves of African mistletoe (*Loranthus micranthus*) on some selected microbial pathogens in Abia State, Nigeria. *Glob. Adv. Res. J. Microbiol.* 2(1):011-016.
- Ortiz GG, Bitzer-Quintero OK, Zarate CB, Rodriguez-Reynoso S, Larios-Arceo F, Velázquez-Brizuela IE, Pacheco-Moisés F (2006). Rosales-Corral SA, Monosodium glutamate- induced damage in liver and kidney: a morphological and biochemical approach. *Biomed. Pharmacol.* 60: 86-89.
- Osadebe PO, Abba CC, Agbo MO (2012). Antimotility effects of extracts and fractions of Eastern Nigeria mistletoe (*Loranthus micranthus* Linn). *Asian Pac. J. Trop. Med.* 5(7):556-60.
- Osadebe PO, Ukwueze SE (2004). A comparative study of the phytochemical and antimicrobial properties of the Eastern Nigerian Species of African Mistletoe (*Loranthus micranthus*) sourced out from different host trees. *J. Biol. Biotechnol.* 2 (1):18-23.
- Pal M (2009). HDL Therapeutics for the treatment of atherosclerosis: A brief overview of the synthetic approaches. *Tetrahedron* 65:433-447.
- Palanisamy P, Selvaraju S, Krishnamoorthy SS, Natarajan M, Ragunathan Y, Perumal P (2012). Monosodium glutamate modulates the circadian rhythms of biochemical variables and behavioral activity in rats under constant light. *Int. J. Nutr. Pharmacol. Neurol. Dis.* 2: 251-257.
- Park CH, Kim MY, Sok DE, Kim JH, Lee JH, Kim MR (2010). Butterbur (*Petasites japonicas* Max.) extract improves lipid profiles and antioxidant activities in monosodiumL-glutamate-challenged mice. *J. Med. Food.* 13: 1216-1223.
- Roberts CK, Sindhu KK (2009). Oxidative stress and metabolic syndrome. *Life Sci.* 84: 705-712.
- Scharrer E (1999). Control of food intake by fatty acid oxidation and ketogenesis. *Nutrition* 15:704-714.
- Seraphim PM, Nunes MT, Machado UF (2001). GLUT 4 protein expression in obese and lean 12-month-old rats. *Braz. J. Med. Biol. Res.* 34:1353-1362.
- Solomon TL, Mekbebb Z, Eyasu AM, Asfaw D (2010). Effect of *Rumex steudellii* methanolic root extract on ovarian folliculogenesis and uterine histology in female albino rats. *Afr. Health Sci.* 10: 353-361.
- Stein EA (1986). Textbook of Clinical Chemistry. W.B. Saunders, Philadelphia. pp. 583-584.
- Suga A, Hirano T, Kageyama H, Kashiba M, Oka J, Osaka T (1999). Rapid increase in circulating leptin in ventromedial hypothalamus-lesioned rats: role of hyperinsulinemia and implication for upregulation mechanism. *Diabetes* 48: 2034-2038.
- Wahlefeld AW (1974). Method of Enzymatic Analysis. Vol. 5, Academic Press, New York. pp. 1831-1835.
- WHO (2008). Traditional Medicine. World Health Organization Fact Sheet N 134, December 2008. (Accessed from <http://www.who.int/mediacentre/factsheets/fs134/en/> on 11 August 2010.
- Woolley A (2004). Determination—General and reproductive toxicology. In: Taylor and Francis, ed. *A Guide to Practical Toxicology Evaluation, Prediction and Risk.*, New York. pp. 80-106.
- Yusuf L, Oladunmoye MK, Ogundare AO, Akinyosoye FA, Daudu OA, Hassan GA (2013). Antimicrobial and antioxidant properties of mistletoe (*viscum album*) growing on cola (*cola nitida*) tree in Akure North, Nigeria. *J. Microbiol. Res. Rev.* 1(3):35-41.
- Zavaroni IE, Bonora M, Pagliara E, Dall'Aglio C, Luchetti L (1989). Risk factors for coronary artery disease in healthy persons with hyperinsulinemia and normal glucose tolerance. *N. Engl. J. Med.* 320:702-706.