

*Full Length Research Paper*

# Histomorphometric evaluation of small intestinal mucosa of red jungle fowl and commercial broiler from one day to four months of age

K. Khalid Kadhim<sup>1</sup>, A. B. Z. Zuki<sup>2\*</sup>, M. M. Noordin<sup>3</sup>, S. M. A. Babjee<sup>3</sup> and M. Zamri-Saad<sup>3</sup>

<sup>1</sup>Department of Veterinary Preclinical Sciences, Faculty of Veterinary Medicine, Universiti Putra Malaysia, 43400 UPM, Serdang, Selangor.

<sup>2</sup>Institute of Bioscience, Universiti Putra Malaysia, 43400 UPM, Serdang, Selangor.

<sup>3</sup>Department of Veterinary Pathology and Microbiology, Faculty of Veterinary Medicine, Universiti Putra Malaysia, 43400 UPM, Serdang, Selangor.

Accepted 25 May, 2011

**Histomorphometry of the small intestinal mucosa of the red jungle fowl (RJF) and commercial broiler breed (CBC) from day one to four months post-hatch were investigated. For the sake of comparison between these two breeds, the following parameters were included: the number of villi, villus surface area and the intestinal surface area for each small intestinal segment. New procedure for enumerating the intestinal villi was performed by using the standard paraffin sections, whereby the villi were counted through their cross sections using an image analyzer. The numbers of villi were significantly higher in the RJF than the CBC for all the intestinal segments from the day one to four months post-hatch. The villi numbers showed a decreased with age. The villus surface area was significantly higher in the CBC than the RJF for all intestinal segments for all the ages. For the duodenal surface area, the RJF showed a higher value than the CBC at one day old chick, but data was reversed on day 20 post-hatch; the data in the remaining days showed no significant differences. While for the jejunal and ileal surface areas, the CBC exhibited significantly higher values except day 10 where both breeds showed no difference for the jejunum and day 120 for the ileum, the RJF showed higher value. The selection for high body weight decreased the villi number of the small intestine, but in the same time increased the villus surface area for all the intestinal segments which reflects the increase in mucosal surface area particularly the jejunum and ileum.**

**Key words:** Intestinal villi, villi number, surface area, red jungle fowl.

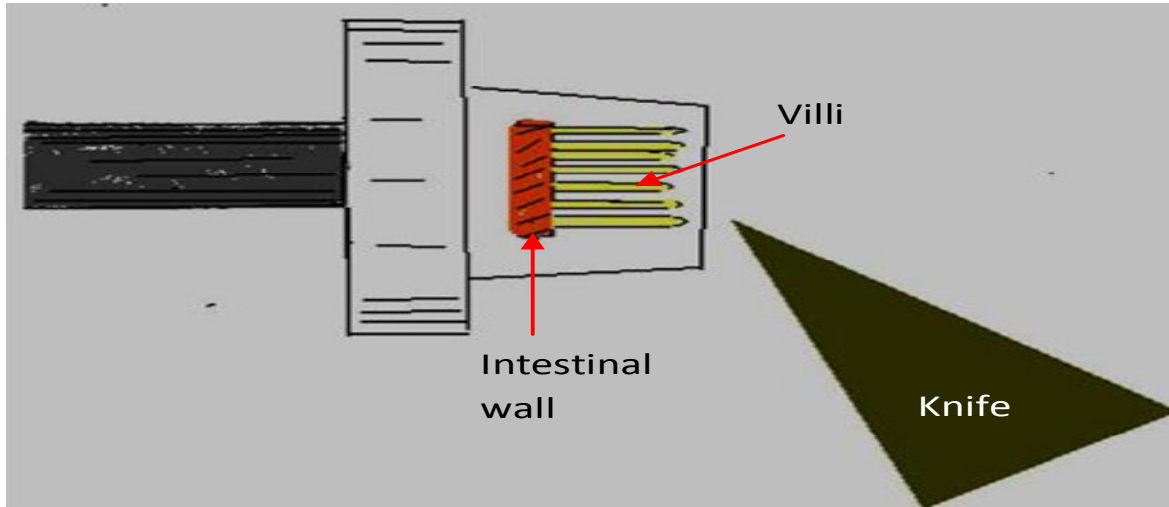
## INTRODUCTION

Counting of the intestinal villi has many purposes, and is vital to follow the development of the intestinal mucosa or to evaluate the intestinal function during development. In addition, it can be used as an indicator to reflect the intestinal surface area which is an important parameter used for selection plan for high body weight (Clarke, 1977; Viguera et al., 1999). Counting of intestinal villi has been done by placing a graticule close to the villus surface. However, this procedure has some parallax error

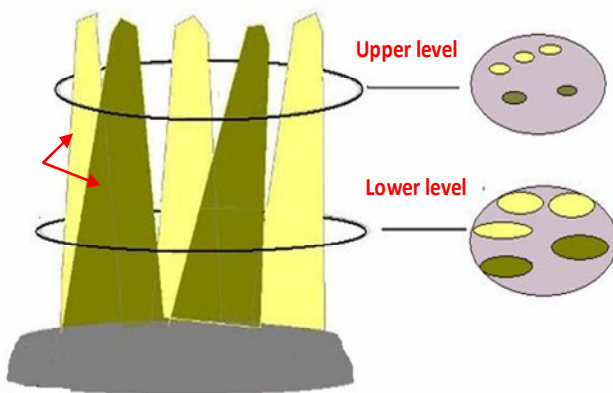
(Forrester, 1972). Uni et al. (1995) estimated the villi number per area in a horizontal section after estimating the area of the villus base.

In rats, the villi number is higher in duodenum, and declines towards the ileum (Mayhew and Middleton, 1985; and Clarke, 1977). However, the number of villi is decreased when the animals gained weight (Clarke 1977; Viguera et al., 1999) or decreases with age (Clarke, 1972). In the duodenum, particularly in the first week after hatching, the intestinal segments for breeds with low body weight has higher villi number than the breed with high body weight (Uni et al., 1995). However, the number of villi decreases from day one to ten, but remains constant thereafter (Denbow, 2000). One of the suitable

\*Corresponding author. E-mail: [zuki@vet.upm.edu.my](mailto:zuki@vet.upm.edu.my). Fax: 603-89468333.



**Figure 1.** The drawing showing the direction of the intestinal sample during sectioning the villi facing the microtome knife.



**Figure 2.** The drawing showing that the number of the villi is constant at any level along the villi axis.

parameter to assess the villus function is the villus surface area (Maneewan and Yamauchi, 2003).

Differences in growth rates are correlated with changes in villus surface area between high and low growth rates (Smith et al., 1990; Mitchell and Smith, 1991). In broiler chicks, the villus surface area increases in the duodenum more than that of the other segments (Geyra et al., 2001; Noy et al., 2001), and increases with age (Iji et al., 2001). The villus surface area reaches a plateau for the duodenum and ileum, followed by the jejunum (Sklan and Noy, 2003). However, increased food intake has resulted in the modification of the villus surface area (James et al., 1988).

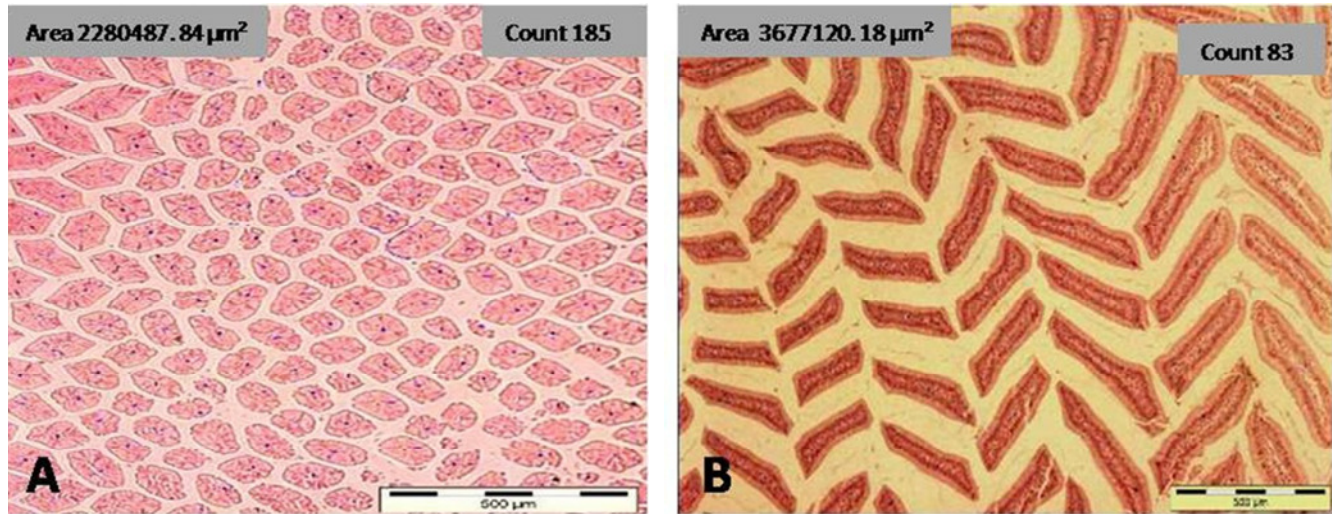
The mucosal surface area of the small intestine of albino rat increased with age (Kapadia and Baker, 1976). However, Ecknauer et al. (1982) stated that it is restricted to the ileum only. In contrast, it appeared constant in older rats (Penzes and Skala, 1977), or with a temporary

reduction (Clarke, 1977). Meanwhile, Permezel and Webling (1971) have stated that the surface area of the small intestine increases in the jejunum more than in any other segments, and in the duodenum more than that of the ileum. Still, the surface area in the jejunum and ileum are greater in heavy line of mice than in the light line ones (Ogiolda et al., 1998).

The aim of this study was to compare the morphology of the small intestinal mucosa of an unselected breed of red jungle fowl with a commercial broiler breed which had gone through an assortment for a high body weight.

## MATERIALS AND METHODS

A total of 35 birds for each RJF and CBC breed were used in this study. Seven birds from each breed were serially euthanized at days 1, 10, 20, 56 and 4 months of age, by intravenous (cutaneous ulnar vein) administration of sodium pentobarbitone (80 mg/ kg) (Mitchell and Smith, 1991). The small intestine was then divided into duodenum, jejunum and ileum, following the demarcation set by Mitchell and Smith (1990) and Geyra et al. (2001). These organs were washed with saline solution to remove the intestinal contents. For counting the intestinal villi, to avoid technical errors and obstacles faced by the previous methods, here we suggested the new method for the preparation of the histological slides for counting the villi. Sample from the mid portion of each intestinal segment were taken, and fixed in 10% neutral buffered formalin after the opening of the lumen by median incision. After fixation, processing in the routine standard histological procedure was done. During embedding in liquid paraffin, care was considered to orient the sample where the villous placed down. Thus, during sectioning where mucosal surface of the intestinal segments faced the sectioning side (Figure 1), fine cross sections of villi were obtained. The sectioning was done at any level along the villi axis (Figure 2), however, the lower level may be better in order to include the short villi if found. The sections were stained by H&E and from each bird, the numbers of villi cross sections were counted within the specific area; the mean of three to four readings from each intestinal segment were attributed to the square millimeter. The histomorphometric evaluation was done by using the image analyzer



**Figure 3.** Microphotographs of the duodenal villi of RJF in day one old (A) and in two months of age (B) showing villi cross sections. H&E; Bar 500 µm.

(Olympus Image Analysis, BX 51 TF) provided with CC12 camera. The villus surface area was obtained from ten intact villi selected from the mid-point of each intestinal segment by using fine hypodermic needles to separate the villi under the dissection microscope (Kruss Ootronic, Germany). The villi surface area was finally doubled, assuming that each villus is consisted of two flat sheets that are bent to meet each other only in the vicinity of the villus perimeter (Smith et al., 1990).

The surface area of each intestinal segment was estimated by multiplying the surface area of individual villus in that segment by the number of villi in the same segment. All the data were analyzed statistically, comparing the means between the breeds at the same age using independent T- test samples.

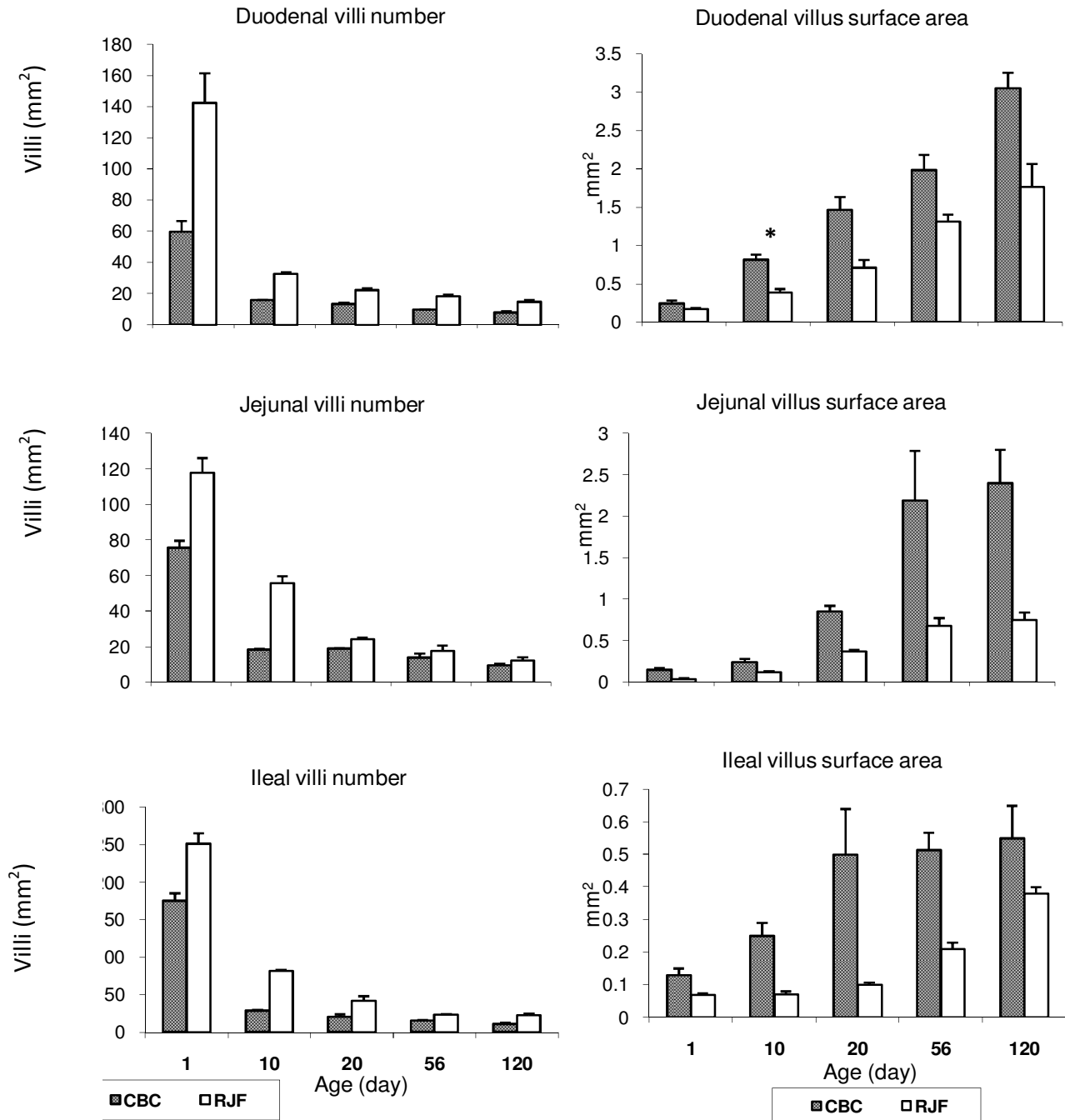
## RESULTS AND DISCUSSION

According to the previous reports, the counting of the intestinal villi was done by placing a graticule closed to the villous surface on top of the coverslip. However, this procedure is subject to the parallax error because the villi and graticule are not precisely in the same plane as reported by Forrester (1972) who also added that the enumeration is easy at the lower end of the small intestine, but towards the upper end, the pattern is more difficult to be discriminated into single units as the villi may be wide and sinuous, and may overlap each other. The duodenum was then excluded for this reason. Furthermore, by using the graticule for counting villi, the short villi may become invisible due to the presence of either the long villi or presence of the debris above and between the villi, which may impede the clear vision and interfere with the counting. On the other hand, Uni et al. (1995) estimated the villi number per area of intestinal wall in a horizontal section after counting the diameter of the villi base. In facts, it was observed that the zigzage arrangement of the villi make it difficult to estimate the correct area of the villi base through the longitudinal

section of the villus, because we cannot get the accurate diameter of the villi base by such old method.

In addition, according to the results of this study the villus shape varied with age. Where the cylindrical-shape villus was only identical with the young birds, it was changed to tongue or leaf-like shapes with age. Thus, the estimation of the villi number through the histological slide of calculating the area of the villus base, by considering that the villi are cylindrical in shape as reported by Uni et al. (1995), seem to have great error.

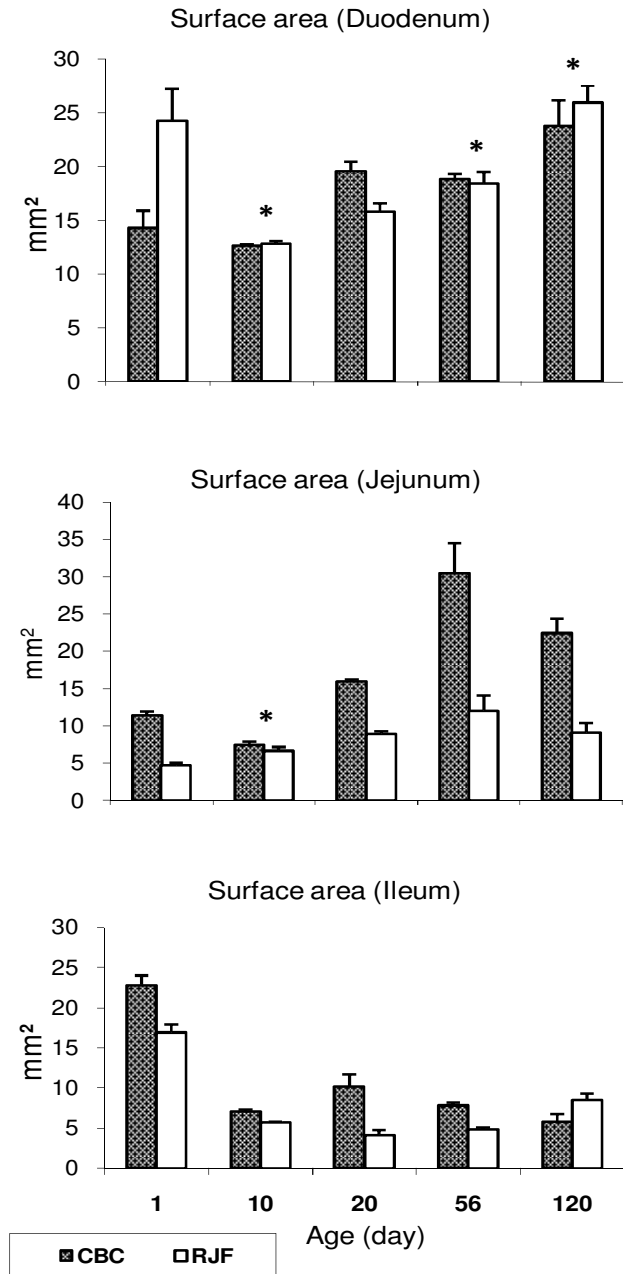
Errors resulting from the previous methods were avoided using this a new procedure, where the villi cross sections were enumerated in the same plane and in any intestinal segment regardless of the intensity or villi overlap particularly in the older birds (Figure 3). Furthermore, using the lower section level, both the long villi as well as the short villi were included regardless to the presence or absence of debris among some villi which may impede the clear vision. This study showed that the villus number (per mm<sup>2</sup>) of all the intestinal segments had marked difference, where the RJF showed higher value than CBC throughout the experiment. The villi numbers were markedly decreased with age in all of the intestinal segments for both breeds. However, the villi showed increase in numbers from the duodenum to the ileum in all the birds (Figure 4, left). That was due to the clear increases or decreases in the villi size. The obtained results are similar to that of the other researchers, where the number of villi decreased when the animals gained weight (Clarke, 1977; Viguera et al., 1999). In this study, there was high decrease in the number of villi in all of the small intestine segments up to the age of 20 days, thereafter the decrease continued slowly up to 120 days of age. It is likely that the decreasing trend in the number of the villi was due to the enlargement of the villi size as a result of an increased in the connective tissue components



**Figure 4.** Number of villi (per mm<sup>2</sup>) for each intestinal segment (left), and the villus surface area (per mm<sup>2</sup>) of each intestinal segment (right), for CBC and RJF from day 1 post-hatch to 4 months of age. Values are means  $\pm$  SD and N = 7. Comparisons of the mean were made between lines at each age; (\*) not significantly different ( $P > 0.05$ ) between breeds in the same age.

or the fusion of the adjacent villi (Forrester, 1972). Similar increases in villi numbers for different small intestinal segments have been reported in the first week post-hatch for breeds with low body weights compared with high body weights birds (Uni et al., 1995). However, it has been shown that the numbers of villi decrease from day one to day ten, but thereafter remain constant (Denbow,

2000). Similar to our result, the villi numbers per unit area decreased with age (Clarke, 1972), particularly in the duodenum of the chicken (Uni et al., 1996). The acquired data seems to be in contrast with those reported by Mayhew and Middleton (1985) and Clarke (1977) on rat, where the villi number was higher proximally and declined towards the terminal ileum.



**Figure 5.** The surface area (mm<sup>2</sup>) per square millimeter of intestinal segment for CBC and RJF from day 1 post-hatch to four months of age. Values are means  $\pm$  SD and N = 7. Comparisons of the mean were made between lines at each age, (\*) not significantly different ( $P > 0.05$ ) between breeds in the same age.

The results of this study showed that the villus surface area of all the intestinal segments was higher in CBC except for the duodenum at day 10 post-hatch, where both breeds showed no differences (Figure 4 right). James et al. (1988) suggested that increasing food intake through the small intestine is the most potent factor, resulting in the modification of the villus surface area.

Geyra et al. (2001) and Noy et al. (2001) reported that the villus surface area increases steadily in the duodenum and more slowly in the jejunum and ileum for the 12 day-old broiler breed chicks. Iji et al. (2001) suggested that the villus surface area increases significantly with age in all three regions of the small intestine of broiler breed. In our data, the duodenal surface area increased with age in both breeds, while the surface area reached a plateau at 56 days for jejunum from the first day and declined after that in the ileum. These results appeared to differ from those reported by Sklan and Noy (2003) who stated that the duodenum and ileum surface area reaches a plateau after 11 days, whereas the jejunal surface area continues to increase until 19 days, or all the intestinal segments continues to increase until 19 days (Thouvenelle et al., 1995). However, the results in this study are in line with Smith et al. (1990) and Mitchell and Smith (1991) who observed that the villus surface area of the small intestinal segments is increase in the heavy breeds more than light breeds.

In this experiment, the intestinal surface area decreased from the duodenum to the ileum in all the birds, except for the jejunum of CBC at 56 days post-hatch and for the ileum at first day for both the CBC and RJF, in which greater values were monitored. The surface area of duodenum at first day chicks was significantly greater in the RJF than in the CBC. However, these data were reversed at 20 days, and there were no more differences between the breeds for the remainder of the days. Data on the jejunum and ileum were found to be higher in the CBC than the RJF. Except for the jejunum at 10 days post-hatch, both of the breeds showed no differences, and at 120 days, the RJF showed a higher value than CBC in regard with the ileum (Figure 5). Despite of a marked decrease in the numbers of the villi in the intestinal segments, the increases in the surface area of these segments were due to the increase in the surface area of the individual villi whereas, the results that indicated an increase in the mucosal surface area with age were reported by Kapadia and Baker (1976). However, the intestinal surface area seem constant in the older rat (Penzes and Skala, 1977), or a lack of change in the surface area showed a temporary reduction in the rat as reported by Clarke (1977). However, according to the findings of Ecknauer et al. (1982), the surface area in rat increased with age in the ileum but not in the jejunum.

The result in this experiment is in line with Permezel and Webling (1971) who stated that the surface area of the small intestine increases in the duodenum more than the ileum. Even though, there were some exceptions in the results of this study, but for the first day, and 56 days chicks of the CBC, the ileum and jejunum appeared to have higher values respectively than those for the other segments. Therefore, such results indicating a higher mucosal surface area for the jejunum and the ileum in the heavy breeds than the light ones can be accepted (Ogiolda et al., 1998; Watkins et al., 2004).

## Conclusion

The new technique used in this experiment for the enumeration of the intestinal villi was closer to the reality of avoiding the usual errors of the previous methods.

Unlike the RJF, domestication in chicken and selection for high body weight increased the intestinal villus surface area due to the increase in the villus size. This in turn increased the mucosal surface area of the small intestinal segments, particularly in the jejunum and ileum, despite the fewer villi number in these segments for CBC when compared to the unselected breed like RJF. Also, it offers a good parameter to estimate the efficiency of the bowel in favor of the conversion and absorption of food.

## REFERENCES

- Clarke RM (1972). The effect of growth and of fasting on the number of villi and crypts in the small intestine of the albino rat. *J. Anat.* 112: 27-33.
- Clarke RM (1977). The effects of age on mucosal morphology and epithelial cell production in rat small intestine. *J. Anat.* 123: 805-811.
- Denbow DM (2000). Gastrointestinal anatomy and physiology. In *Avian Physiology*, Edn V, ed. Whittow GC. San Diego, California: Academic Press. pp. 299-325.
- Ecknauer, R., Vadakel, T. and Weplers, R. (1982). Intestinal morphology and cell production rate in aging rats. *J. Gerontol.* 37: 151-155.
- Forrester JM (1972). The number of villi in rat's jejunum and ileum: effect of normal growth, partial enterectomy, and tube feeding. *J. Anat.* 111: 283-291.
- Geyra A, Uni Z, Sklan D (2001). Enterocyte dynamics and mucosal development in the posthatch chick. *Poult. Sci.* 80: 776-782.
- Iji PA, Hughes RJ, Choct M, Tivey DR (2001). Intestinal structure and function of broiler chickens on wheat-based diets supplemented with a microbial enzyme. *J. Anim. Sci.* 14: 54-60.
- James PS, Smith MW, Tivey DR (1988). Single villus analysis of disaccharidase expression by different regions of the mouse intestine. *J. Physiol.* 401: 533-545.
- Kapadia S, Baker SJ (1976). The effects of alterations in villus shape on the intestinal mucosal surface of the Albino rat; the relationship between mucosal surface area and the crypts. *Digestion*, 14: 256-268.
- Mayhew TM, Middleton C (1985). Crypt, villi and microvilli in the small intestine of the rat, A stereological study of their variability within and between animals. *J. Anat.* 141: 1-17.
- Maneewan B, Yamauchi K (2003). Effects of semi-purified pellet diet on the chicken intestinal villus histology. *Poult. Sci.* 40: 254-266.
- Mitchell MA, Smith MW (1990). Jejunal alanine uptake and structural adaptation in response to genetic selection for growth rate in the domestic fowl (*Gallus domesticus*). *J. Physiol.* 424: 7-15.
- Mitchell MA, Smith MW (1991). The effects of genetic selection for increased growth rate on mucosal and muscle weights in the different regions of the small intestine of the Domestic fowl (*Gallus domesticus*). *Comp. Biochem. Physiol.* 99: 251-258.
- Noy Y, Geyra A, Sklan D (2001). The effect of early feeding on growth and small intestinal development in the posthatch poultry. *Poult. Sci.* 80: 912-919.
- Ogiolda L, Wanke R, Rottmann O, Hermanns W, Wolf E (1998). Intestinal dimensions of mice divergently selected for body weight. *Anat. Rec.* 250: 292-299.
- Penzes L, Skala J (1977). Changes in the mucosal surface area of the small gut of rats of different ages. *J. Anat.* 124: 217-222.
- Permezel NC, Webling DD (1971). The length and mucosal surface area of the small and large gut in young rats. *J. Anat.* 108: 295-296.
- Sklan D, Noy Y (2003). Functional development and intestinal absorption in the young poultry. *Br. Poult. Sci.* 44: 651-658.
- Smith MW, Mitchell MA, Peacock MA (1990). Effects of genetic selection on growth rate and intestinal structure in the domestic fowl (*Gallus domesticus*). *Comp. Biochem. Physiol.* 97: 57-63.
- Thouvenelle ML, Haynes JS, Sell JL (1995). Astrovirus infection in hatchling turkeys: alterations in intestinal maltase activity. *Avian Dis.* 39: 343-8.
- Uni Z, Noy Y, Sklan D (1995). Posthatch changes in morphology and function of the small intestines in heavy-and light-strain chicks. *Poult. Sci.* 74: 1622-1629.
- Uni Z, Noy Y, Sklan D (1996). Development of the small intestine in heavy and light strain chicks before and after hatching. *Br. Poult. Sci.* 37: 63-71.
- Vigueras RM, Rojas-Castaneda J, Hernandez R, Reyes G, Alvarez C (1999). Histological characteristics of the intestinal mucosa of the rat during the first year of life. *Lab. Anim.* 33: 393-400.
- Watkins EJ, Butler PJ, Kenyon BP (2004). Posthatch growth of the digestive system in wild and domesticated ducks. *Br. Poult. Sci.* 45: 331-341.