

Full Length Research Paper

Pre-clinical toxicity of *Morinda citrifolia* Linn. leaf extract

Mairim Russo Serafini¹, Claudio Moreira de Lima¹, Rodrigo Correia Santos¹, Grace Anne Azevedo Dória¹, Josepha Yohanna de Jesus¹, Marcelia Garcez Dória de Melo¹, João Paulo Almeida dos Santos¹, Thallita Kelly Rabelo¹, Vanessa Silveira Fortes², Maria José Vieira Fonseca², Ricardo Luiz Cavalcanti de Albuquerque Junior³, Lucindo José Quintans-Júnior³ and Adriano Antunes de Souza Araújo^{1*}

¹Departamento de Fisiologia, Universidade Federal de Sergipe, São Cristóvão, Sergipe, Brazil.

²Faculdade de Ciências Farmacêuticas de Ribeirão Preto, Universidade de São Paulo, USPRP, Ribeirão Preto, SP, Brazil.

³Universidade Tiradentes, Aracaju, Sergipe, Brazil.

Accepted 8 August, 2011

This investigation was carried out to evaluate the safety of an aqueous extract of *Morinda citrifolia* leaves (AEMC) by determining its potential toxicity after acute administration (5 g/kg) in rodents and cytotoxic studies. General behavior adverse effects and mortality were determined for up to 14 days. Biochemical and hematological parameters were determined after 14 days. Cytotoxic effects of the AEMC were determined by spectrophotometric 3-(4,5-dimethylthiazole-2-yl)-2,5-diphenyltetrazolium bromide (MTT) assay (at concentration of 0.05 to 25 mg/ml). The results showed that in the acute study in rats, the AEMC did not cause general behavior adverse effects and mortality. Also, AEMC did not show any cytotoxic effect at 0.05 to 12.5 mg/ml, only at 25 mg/ml. The AEMC does not appear to have significant toxicity.

Key words: *Morinda citrifolia*, cytotoxicity, acute toxicity.

INTRODUCTION

In recent years, there has been a growing interest in identifying naturally occurring minor dietary constituents against the development of several diseases. Plant derived foodstuffs, particularly fruits and vegetables are generally considered to be highly beneficial components of the human diet (Calixto and Siqueira, 2008; Yunes, 2001).

Empirical use of medicine derived from plants has been widely disseminated since ancient times to treat a wide range of diseases. In the last decades, the interest in alternative therapies has raised markedly in a worldwide shape. The occurrence of side effects from plant derived medicines, when used in an appropriate manner, are relatively less frequent when compared to synthetic

drugs. However, experimental data have shown that they are not absent of adverse reactions even in these cases, which makes toxicological controlled studies necessary to assess their safety (Calixto, 2000). *Morinda citrifolia* L. (Rubiaceae), the “noni”, has been used in traditional Polynesian medicine for over 2000 years. Chi-Tang Ho and researchers have successfully identified several new flavonol glycosides and iridoid glycoside from the “noni” leaves (Wang et al., 2002). A number of major components have been identified in the “noni” plant such as scopoletin, octoanoic acid, potassium, vitamin C, terpenoids, alkaloids, anthraquinones, β -sitosterol, carotene, vitamin A, flavone glycosides, linoleic acid, Alizarin, amino acids, acubin, *L*-asperuloside, caproic acid, caprylic acid, ursolic acid, rutin and a putative proxeronine (Wang et al., 2002; Simonsen, 1920; Heinicke, 1985).

The leaves and especially the fruit are consumed in different forms by various communities throughout the

*Corresponding author. E-mail: adriasa2001@yahoo.com.br.
Tel: +55-79-21056841. Fax: +55-79-21056827.

world. The fruit is claimed to prevent and cure several diseases. It is primarily used to stimulate the immune system and thus to fight bacterial, viral, parasitic and fungal infections. It is also used to prevent the formation and proliferation of tumors, including malignant ones (Chan-Blanco et al., 2006; Wang et al., 2002). Despite of this reputation and the market around the “noni”, consumption of this fruit is currently high, not only in the producing countries, but also in the United States, Japan and Europe (Chan-Blanco et al., 2006).

However, no scientific information is available about the pharmacological, biological and toxicological effects of leaves of *M. citrifolia*. Thus, the overall objective of the present work was to evaluate the effects of the aqueous extract of *M. citrifolia* (AEMC) leaves on the cytotoxicity, oxidative damage and acute toxicity.

MATERIALS AND METHODS

Samples

M. citrifolia leaves were collected in São Cristóvão, Sergipe, Brazil (10°18'20.7"(S); 36°39'7.2"(W)). Herbarium voucher specimens (registry number 13503) were prepared and deposited at the Department of Biology of the Federal University of Sergipe. The AEMC was prepared by boiling in distilled water (7.5%; w/v) for 15 min, the solvent evaporated off under reduced pressure and lyophilized.

In vitro experiments

MTT assay

L929 mice fibroblast from the Rio de Janeiro Cell Bank, University of Rio de Janeiro, Rio de Janeiro, Brazil, were routinely grown in 150 cm² tissue culture flasks in DMEM supplemented with 1% (v/v) of an antibiotic solution containing 5 mg of penicillin, 5 mg of streptomycin and 10 mg of neomycin per ml, and 7.5% or 10.0% (v/v) heat-inactivated Fetal Bovine Serum at 37°C under 5% CO₂.

The sensitivity of cells to AEMC was determined by a standard spectrophotometric 3-(4,5-dimethylthiazole-2-yl)-2,5-diphenyltetrazolium bromide (MTT) assay (Mossmann, 1983). Cells were seeded at a density of 10⁵ cells/well into 96 well plates and incubated for 24 h at 37°C in atmosphere of 95% air and 5% CO₂. Then, 20 µl of AEMC, at different concentrations in phosphate buffer saline (PBS) was added to the culture plates for 24 h. After treatment, cells were rinsed once with PBS and serum-free culture medium without phenol red was replaced in all wells. Cells were then incubated for 4 h with MTT solution (5 mg/ml).

The yellow tetrazolium salt was metabolized by viable cells to form purple crystals of formazan. The crystals were solubilized overnight (12 h) in a mixture consisting of 20% sodium dodecyl sulfate (SDS) in HCl (0.01 M). The product was quantified spectrophotometrically by measuring absorbance at 570 nm using a microplate reader (µQuant™, BioTek Instruments Inc., USA). The cellular viability was expressed as the percentage of viable cells compared to the control group.

In vivo experiments

Male and female wistar rats (150 to 200 g) were obtained from the

Federal University of Sergipe (Sergipe, Brazil). The animals were kept under conventional conditions of temperature (20 ± 2°C) and lodged in polypropylene cages, with food and water *ad libitum*. Experimental protocols were approved by the Committee on Animal Research at the Federal University of Sergipe (CEPA/UFES 23/2010).

Acute toxicity study

Toxicological assays were performed with the animals distributed in 4 groups of 6 animals (experimental and control groups of male and female rats). The animals were treated by oral administration (gavage), adopting 5 g/kg as the maximum dose to be used (Lorke, 1983).

AEMC was dissolved in saline (vehicle) and it was given to the experimental groups, whereas only saline was given to the control groups. Specific behaviors (piloerection, palpebralptosis, abdominal contortions, locomotion, hypothermia, muscular tonus, trembling, forepaws paralysis, sedation, ambulation reduction, response to touch, analgesia, and defecation) were observed and graded according to Almeida et al. (1999) for 0, 15 and 30 min and 1, 2, 3 and 4 h after gavage.

Thus, behavioral changes and general appearances were observed once a day, as well as body weights, food and water consumption. Also, the animals were monitored daily for 14 days to verify lethality.

A necropsy was performed at the end of the experiment. Blood samples were collected from the abdominal aorta under light ether anesthesia. Subsequently, a detailed study of the gross and microscopic features of the internal organs, as well as a hematological and biochemical analyses of blood, were carried out. The position, shape, size, texture, consistency and color of the internal organs (lungs, heart, stomach, liver, brain and kidneys) were macroscopically observed, looking for any signs of gross changes. These organs were then weighed to determine relative organ weights and preserved in 10% phosphate buffered formalin solution and the organs were routinely processed for embedding in paraffin, sectioned and stained with hematoxylin and eosin for subsequent histological procedures.

Hematological analysis

Blood samples were collected into EDTA tubes. Measurements of erythrocyte, hemoglobin, hematocrit, leukocyte, neutrophil, lymphocyte, eosinophil, monocyte, basophil, atypical lymphocyte and platelets were determined by using Pentra-120 (ABX-HORIBA) automated equipment according to the method described by Morris and Davey (1999).

Biochemical parameters

The serum was separated from the non-heparinized blood and assayed for serum urea, creatinine, total protein, globulin, albumin, aspartate amino transferase (AST), alanine amino transferase (ALT), Gamma-glutamyl transferase (GGT), total bilirubin (TBil), direct bilirubin (DBil), alkaline phosphatase (ALP), calcium, sodium, potassium and uric acid. Biochemical parameters were determined by using dimension RXL (DADE BEHRING) automated equipment.

Tissue analysis

Formalin-fixed samples of the internal organs were dehydrated, diafanized and embedded in paraffin according to routine protocol of histological procedures. Five micrometer thin sections of the

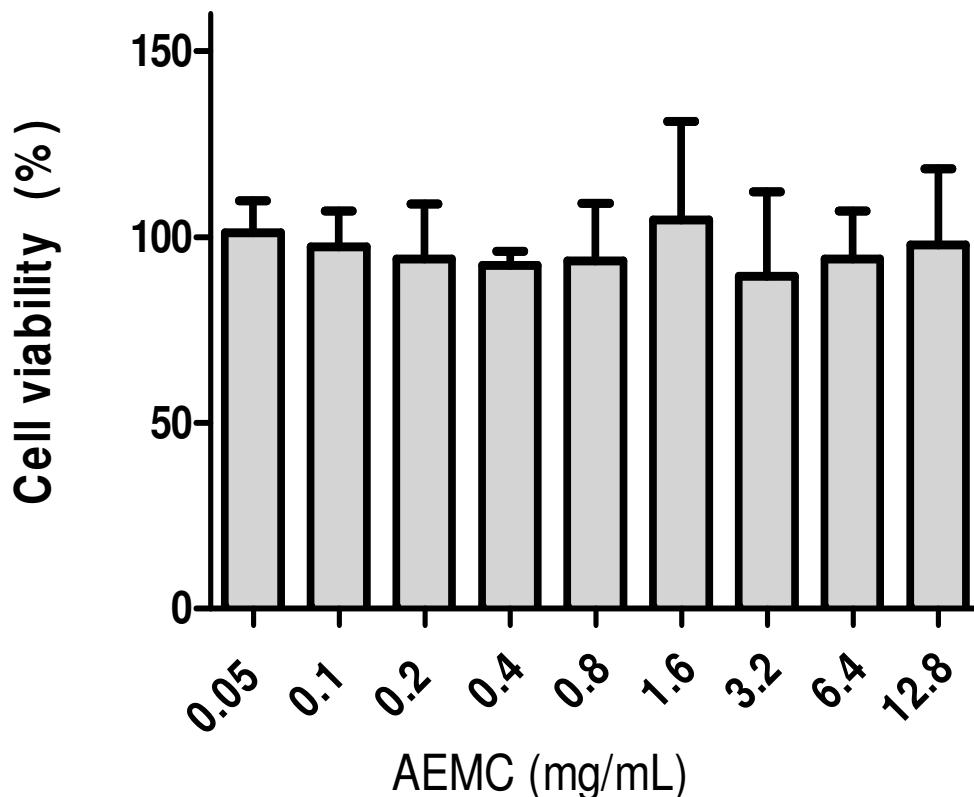


Figure 1. Cytotoxic effect of the AEMC in L929 cell line pretreated with the extracts at concentrations (0.05 to 12.8 mg/ml) for 24 h. Each value represents the mean \pm SD.

paraffin-embedded tissues were obtained and stained by means of hematoxylin eosin histochemical method. Morphological analysis of the histological sections was performed by light microscopy following a closed numerical protocol in such a manner as the pathologist was not aware of what group was being evaluated until the end of the experiment.

Ex vivo experiments

Oxidative damage

About 1 g of liver was homogenized in 2 ml of buffer solution of PBS 1:2 (w/v; 1 g tissue with 2 ml PBS, pH 7.4). Homogenates were centrifuged at $10,000 \times g$ for 15 min at 4°C , and the resultant supernatant was used for the determination of thiobarbituric acid reactive substances (TBARS).

The lipid peroxidation level in liver homogenate was measured as malondialdehyde (MDA) according to Buege and Aust (1984). Thus, 125 μl of supernatant were homogenized by sonication with 50 μl of PBS, 125 μl of trichloro acetic acid – butyl hydroxyl toluene (TCA–BHT) in order to precipitate proteins, and then centrifuged ($1000 \times g$, 10 min and 4°C). Afterwards, 200 μl of supernatant were mixed with 40 μl of HCl (0.6 M) and 160 μl of TBA dissolved in Tris and then the mixture was heated at 80°C for 10 min. The absorbance of the resultant supernatant was obtained at 530 nm.

Statistical analysis

All experiments were performed in triplicate and data was

statistically analyzed with the ANOVA and Tukey or Dunnett's test or test t, using the Prism Software (5.0).

RESULTS AND DISCUSSION

It is well known that the cytotoxicity induced by compounds can be tested by different methods such as lactate dehydrogenase leakage, MTT, protein synthesis inhibition, kenacid blue, Janus Green and trypan blue assays. However, MTT assay are the most common employed for the detection of cytotoxicity or cell viability following exposure to toxic substances (Fotakis and Timbrell, 2006).

MTT assay

The AEMC was evaluated on mice fibroblast cell line (L929) in order to examine their cytotoxic effects on normal cells. Cytotoxicity of the AEMC on the growth of the L929 cell line is showed in Figure 1. Cell proliferation was analyzed 24 h after L929 cells had been cultured with the AEMC at 0.05, 0.1, 0.2, 0.4, 0.8, 1.6, 3.2, 6.4 and 12.8 mg/ml in the final concentration using the MTT assay. The AEMC at concentrations of 0.05 to 12.8 mg/ml did not show any cytotoxic effect in L929 cell line.

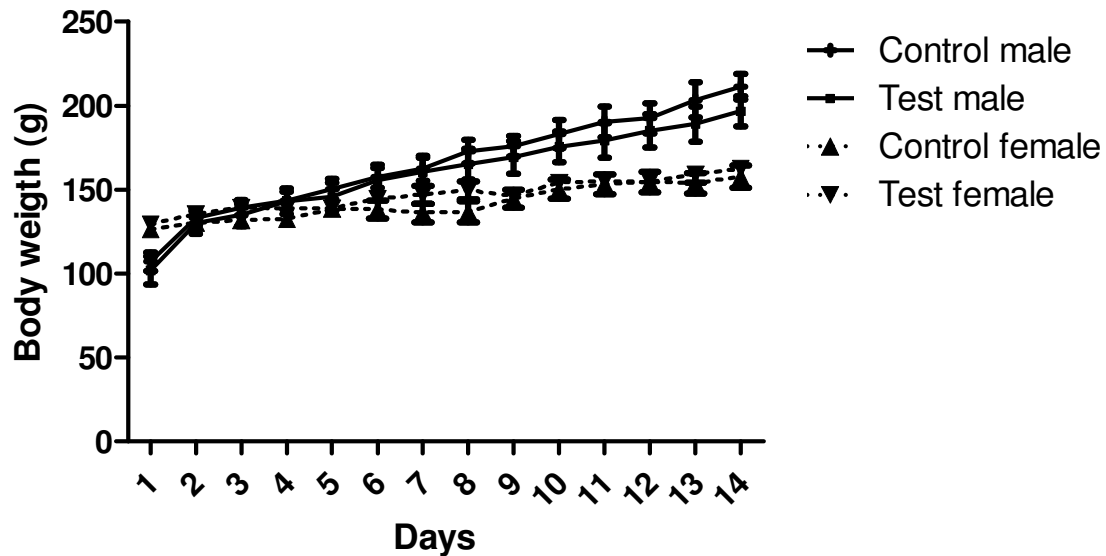


Figure 2. Body weight curves for male and female mice treated with AEMC or salina solution for 15 days. Each value represents the mean \pm SD.

Several studies have shown that results from toxicity studies such as the MTT test might be used to predict the possible toxicity of compounds for the animal (Ekwall et al., 1989; Roguet et al., 1993) and using *in vitro* and *in vivo* methods, it is usually possible to achieve toxic concentrations with even the most innocuous materials (Phillips, 1996).

Acute toxicity study

In the acute toxicity test, 5 g/kg of AEMC did not cause the death during a 14-day observation period. The rats did not show any sign of toxicity or change in behavioral changes or other physiological activities. A 5 g/kg dose was considered as the "Limit test", as recommended by acute toxicity testing procedures. Therefore, administration of further higher doses was considered physiologically unsound and is not generally recommended (Araujo et al., 2008).

The experiments *in vivo* showed that the administration of AEMC (5 g/kg, p. o.) after 15 days did not modify the profile of weight when test and control groups were compared (Figure 2). Besides, food and water consumption for the control group and for the treated group were kept within the means established for this animal species.

There were no verified changes in the weight of the organs (Table 1), fourteen days after acute treatment with 5 g/kg of AEMC. Only in the male rats were there significant differences in the relative weights of the livers, as shown.

These data might be related either to some casual variabilities in the weight of the livers, unrelated to the

hepatic functions, or to some subclinical abnormalities which had determined a possible condition of hypertrophy or hyperplasia of the liver tissues. Therefore, further morphometric analyses are necessary in order to compare to the test and control groups and clarify the real nature of such results.

Hematological analysis

Results of the hematological studies are presented in Table 2. The data shows that leukocyte, erythrocytes, hemoglobin, mean corpuscular hemoglobin (MCH), hemoglobin, platelets, neutrophil, lymphocyte, monocyte, basophil and eosinophil levels for the control rats were not significantly different from those treated with AEMC during the period of study. Only the hematocrit, mean corpuscular volume (MCV) and mean corpuscular hemoglobin concentration (MCHC) levels were significantly different in the female treated groups, as compared to the control group ($p < 0.05$).

Biochemical parameters

Results of the biochemical parameters are presented in Table 3. The data shows that total, indirect and direct bilirubin (T Bil., I Bil., D Bil.), creatinine, gamma-glutamyl transferase (GGT), glucose, potassium, lactate dehydrogenase (LDH), urea and uric acid levels for the control rats were not significantly different from those treated with AEMC during the period of study. Nevertheless, the albumin, alkaline phosphatase, alanine amino transferase (ALT), aspartate amino transferase

Table 1. Weight of the organs after acute treatment with 5 g/kg of AEMC.

Organ	Group			
	CF	TF	CM	TM
Left kidney	0.613 ± 0.033	0.660 ± 0.021	0.843 ± 0.033	0.806 ± 0.037
RightKidney	0.615 ± 0.033	0.671 ± 0.023	0.873 ± 0.040	0.835 ± 0.051
Stomach	1.897 ± 0.152	1.667 ± 0.041	2.417 ± 0.218	3.067 ± 0.327
Heart	0.660 ± 0.026	0.685 ± 0.011	0.863 ± 0.157	0.930 ± 0.049
Lung	1.385 ± 0.113	1.353 ± 0.126	1.515 ± 0.118	1.320 ± 0.046
Liver	5.175 ± 0.175	5.173 ± 0.180	7.818 ± 0.165	6.522 ± 0.266**
Brain	1.638 ± 0.056	1.673 ± 0.035	1.657 ± 0.045	1.712 ± 0.076

CF (control female), TF (test female), CM (control male) and TM (test male). Data is expressed as mean ± S.D., n= 6. * Indicate statistical difference between the control and treated group (p < 0.05) and ** p < 0.01.

Table 2. Results of the hematological studies after acute treatment with 5 g/kg of AEMC.

Parameter	Group			
	CF	TF	CM	TM
Leukocyte ($\times 10^3/\text{mm}^3$)	9.348 ± 0.5171	9.660 ± 0.7909	7.622 ± 0.6129	9.727 ± 1.3730
Erythrocytes ($\times 10^6/\text{mm}^3$)	7.868 ± 0.0518	7.890 ± 0.0920	7.318 ± 0.1982	7.103 ± 0.0954
Hemoglobin (g/dl)	14.68 ± 0.1376	14.53 ± 0.1116	13.68 ± 0.3016	13.68 ± 0.2040
Hematócrit (%)	42.80 ± 0.5526	41.38 ± 0.2344*	40.98 ± 0.7373	40.32 ± 0.6680
MCV (fl)	54.40 ± 0.5972	52.48 ± 0.4061*	56.10 ± 1.0090	56.77 ± 0.6830
CMH (pg)	18.67 ± 0.1282	18.43 ± 0.1054	18.73 ± 0.1764	19.25 ± 0.1875
MCHC (g/dl)	34.32 ± 0.1922	35.12 ± 0.1046**	33.38 ± 0.4743	33.93 ± 0.0881
Platelets ($\times 10^6/\text{mm}^3$)	1221 ± 68.690	1136.0 ± 58.95	1252 ± 71.130	1152 ± 45.640
Neutrophil (%)	20.920 ± 1.641	23.980 ± 3.414	24.73 ± 2.6410	25.42 ± 5.0120
Lymphocyte (%)	73.720 ± 1.782	70.370 ± 3.647	69.62 ± 2.3760	70.27 ± 5.1430
Monocyte (%)	4.517 ± 0.6824	4.367 ± 0.4128	4.383 ± 0.5108	3.683 ± 0.4230
Eosinophil (%)	0.850 ± 0.0763	1.283 ± 0.4206	1.267 ± 0.5566	0.633 ± 0.0760
Basophil (%)	0.000 ± 0.0000	0.000 ± 0.0000	0.000 ± 0.0000	0.000 ± 0.0000

CF (control female), TF (test female), CM (control male) and TM (test male). Data is expressed as mean ± S.D., n = 6.

* Indicate statistical difference between the control and treated group (p < 0.05) and ** p < 0.01.

(AST), globulin, sodium and total protein levels in test groups were significantly lower than control group (p < 0.05).

Tissue analysis

Pathological examination of the tissues on a gross basis indicated that there were no detectable abnormalities; either in weight or in appearance and no significant differences were grossly detected between control and experimental groups. Moreover, the organs of both groups were unremarkable and comparable to each sex.

Microscopical analysis of the examined internal organs revealed that their architectural and cellular appearance were comparatively unremarkable in both groups and

sexes. Nevertheless, some pulmonary samples from both experimental and control groups revealed a picture of slight and focal atelectasy. According to Araújo et al. (2008), this morphological alteration might have been a result of some already expected changes in their blood pressure and respiratory rhythm, probably due to the conditions of continuous stress caused by experimental manipulation of the animals. Therefore, it seems absolutely clear that the focal morphological picture of atelectasy is not related to the AEMC oral administration.

Oxidative damage

Hepatocytes, which make up the majority of the liver structure, are very active in the metabolism of exogenous

Table 3. Results of the biochemical parameters after acute treatment with 5 g/kg of AEMC.

Parameter	Group			
	CF	TF	CM	TM
Albumin (g/dL)	3.067 ± 0.033	2.90 ± 0.0365**	2.900 ± 0.0577	2.90 ± 0.0365
Alkalinephosphatase (U/L)	85.67 ± 8.508	71.83 ± 7.387	187.8 ± 13.30	139.3 ± 7.451**
ALT (U/L)	39.00 ± 2.840	32.67 ± 0.802	55.67 ± 1.978	46.50 ± 2.187*
AST (U/L)	117.7 ± 1.626	91.83 ± 7.993*	120.3 ± 6.453	102.0 ± 4.008*
IBil. (mg/dL)	0.000 ± 0.000	0.000 ± 0.000	0.000 ± 0.000	0.000 ± 0.000
D Bil. (mg/dL)	0.010 ± 0.000	0.010 ± 0.000	0.010 ± 0.000	0.010 ± 0.000
T Bil. (mg/dL)	0.010 ± 0.000	0.010 ± 0.000	0.010 ± 0.000	0.010 ± 0.000
Creatinine (mg/dL)	0.490 ± 0.008	0.470 ± 0.009	0.475 ± 0.011	0.471 ± 0.013
GGT (U/L)	< 4.00 ± 0.000	< 4.00 ± 0.000	< 4.00 ± 0.000	< 4.00 ± 0.000
Globulin (mg/dL)	3.333 ± 0.076	3.000 ± 0.082*	2.983 ± 0.075	2.867 ± 0.105
Glucose (mg/dL)	78.00 ± 5.138	88.17 ± 6.369	97.50 ± 7.706	91.83 ± 6.478
K ⁺ (mmol/L)	4.600 ± 0.100	4.667 ± 0.092	4.883 ± 0.225	4.917 ± 0.070
Na ⁺ (mmol/L)	140.2 ± 0.307	139.5 ± 0.428	142.8 ± 0.401	140.2 ± 0.872*
Total protein (g/dL)	6.400 ± 0.089	5.90 ± 0.0894**	5.883 ± 0.127	5.767 ± 0.117
LDH (mg/dL)	94.83 ± 11.84	76.83 ± 6.560	113.0 ± 9.633	120.8 ± 15.70
Urea (mg/dL)	36.17 ± 2.442	32.67 ± 3.007	35.33 ± 1.382	49.83 ± 5.082
Uric acid (mg/dL)	1.100 ± 0.000	1.016 ± 0.183	1.150 ± 0.152	0.9333 ± 0.092

CF (control female), TF (test female), CM (control male) and TM (test male). Data is expressed as mean ± S.D., n = 6.

* Indicate statistical difference between the control and treated group (p < 0.05) and ** p < 0.01.

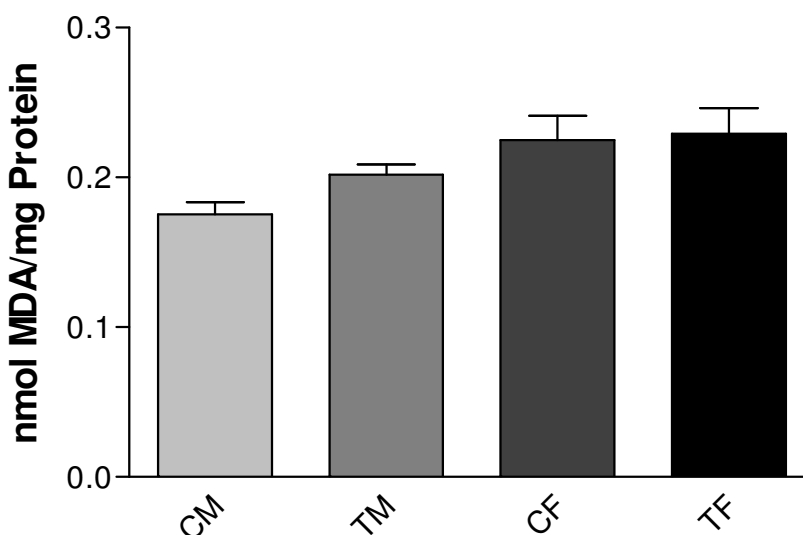


Figure 3. Oxidative damage after acute treatment with 5 g/kg of *M. citrifolia*. CM (control male), TM (test male), CF (control female) and TF (test female). Data are expressed as mean ± S.D., n = 6. There is no statistical difference between the control and treated group. (test t: control male x test male and control female x test female).

chemicals and this is one of the major reasons why the liver is a target for toxic substances (Timbrell, 2001). During the detoxification of xenobiotics, reactive oxygen species (ROS) are generated which cause oxidative stress (Kohen and Nyska, 2002).

A primary measure of oxidative damage in liver is lipid peroxidation, where TBA is measured as and the index of lipid peroxidation. Thus, after pre treatment with AEMC, the liver was evaluated and the decrease of the damage caused by AEMC was observed, as shown in Figure 3.

These results indicate that there was no induction of repair mechanisms.

Conclusion

In conclusion, this investigation demonstrates that at doses consumed in the traditional medicine (620 mg 2x/day, 1000 mg/day or 30 ml/day), the AEMC may be considered as safe, as it did not cause either any lethality or changes of the general behavior in the acute toxicity and cytotoxicity studies in rodents. However, the results reported here do not imply that AEMC would have no toxic effects in humans, but simply constitute a baseline data for further studies. Studies of this type are needed before a phytotherapeutic agent can be generally recommended for use.

Abbreviations

AEMC, aqueous extract of *Morinda citrifolia*; **MTT**, 3-(4,5-dimethylthiazole-2-yl)-2,5-diphenyltetrazolium bromide; **DMEM**, Dulbecco's Modified Eagle's Medium; **PBS**, phosphate buffer saline; **SDS**, sodium dodecyl sulfate; **EDTA**, Ethylenediaminetetracetic acid; **AST**, aspartate amino transferase; **ALT**, alanine amino transferase; **GGT**, Gamma-glutamyltransferase; **TBil**, total bilirubin, **DBil**, direct bilirubin; **ALP**, alkaline phosphatase; **TBARS**, thiobarbituric acid reactive substances; **TBA**, thiobarbituric acid; **MDA**, malondialdehyde; **TCA-BHT**, trichloro acetic acid – butyl hydroxyl toluene; **MCH**, mean corpuscular hemoglobin; **MCV**, mean corpuscular volume; **MCHC**, mean corpuscular Hemoglobin concentration; **LDH**, lactate dehydrogenase; **ROS**, reactive oxygen species.

REFERENCES

- Araujo AAS, Bonjardim LR, Mota EM, Albuquerque Jr. RLC, Estevam CS, Cordeiro L, Seixas SRS, Batista JS, Quintans-Junior LJ (2008). Antinociceptive activity and toxicological study of aqueous extract of *Egletes viscosa* Less (Asteraceae). *Braz. J. Pharm. Sci.* 4: 707-715.
- Almeida RN, Falcão ACGM, Diniz RST, Quintans Jr. LJ, Polari RM, Barbosa-Filho JM, Agra MF, Duarte JC, Ferreira CD, Antonioli AR, Araújo CC (1999). Metodologia para avaliação de plantas com atividade no Sistema Nervoso Central e alguns dados experimentais. (Kingly Translate to English). *Rev. Bras. Farm.* 80: 72-76.
- Buege JA, Aust SD (1984). Microsomal lipid peroxidation. *Methods Enzymol.* 105: 302–310.
- Calixto JB (2000). Efficacy, safety, quality control, marketing and regulatory guidelines for herbal medicines (phytotherapeutic agents). *Braz. J. Med. Biol. Res.* 33: 179–189.
- Calixto JB, Siqueira Jr. JM (2008). Desenvolvimento de Medicamentos no Brasil: Desafios. (Kingly Translate to English). *Gaz. Méd. Bahia*, 78: 98-106.
- Chan-Blanco Y, Vaillant F, Perez AM, Reynes M, Brillouet JM, Brat P (2006). The noni fruit (*Morinda citrifolia* L.) a review of agricultural research, nutritional and therapeutic properties. *J. Food Compos. Anal.* 19: 645–654.
- Ekwall B, Bondesson I, Castel 1JV, Gomez-Lechon MJ, Hellberg S, Hiigberg J, Jover R, Ponsoda X, Romert L, Stenberg K, Walum E (1989). Cytotoxicity evaluation of the first ten MEIC chemicals: acute lethal toxicity in man predicted by cytotoxicity in five cellular assays and by oral LD50 tests in rodents. *Atla*, 17: 83-100.
- Fotakis G, Timbrell JA (2006). *In vitro* cytotoxicity assays: Comparison of LDH, neutral red, MTT and protein assay in hepatoma cell lines following exposure to cadmium chloride. *Toxicol. Lett.* 160: 171-177.
- Heinicke R (1985). The pharmacologically active ingredient of Noni. *Bull. Pac. Trop. Bot. Gard.* 15: 10-16.
- Kohen R, Nyska A (2002). Oxidation of biological systems: oxidativestress phenomena, antioxidants, redox reactions, and methods for their quantification. *Toxicol. Pathol.* 30: 620-650.
- Lorke DA (1983). New Approach to Practical Acute Toxicity Testing. *Arch. Toxicol.* 54: 275-287.
- Morris MW, Davey FR (1999). Exame básico de sangue. In: Henry JB. (Ed.), *Diagnósticos Clínicos e Tratamento por Métodos Laboratoriais*, 19th ed. Manole, São Paulo. (Kingly Translate to English). p. 1552.
- Mossmann T (1983). Rapid colorimetric assay for cellular growth and survival: application to proliferation and cytotoxicity assays. *J. Immunol. Methods.* 65: 55-63.
- Phillips BJ (1996). Development of cell culture techniques for assessment of the toxicity of plant products. *Toxicol. in vitro.* 10: 69-76.
- Roguet R, Cotovio J, Gaetani Q, Dossou KG, Rougier A (1993). Cytotoxicity of 28 MEIC chemicals to rat hepatocytes using two viability endpoints: correlation with acute toxicity data in rat and man. *Atla*. 21: 216-224.
- Simonsen JL (1920). Note on the constituents of *Morinda citrifolia*. *J. Chem. Soc.* 117: 561-4.
- Timbrell J (2001). Introduction to toxicology, Third ed. Taylor & Francis, New York. 4: 57-71.
- Wang M, West BJ, Jensen CJ, Nowicki D, Su C, Palu A, Anderson G (2002). *Morinda citrifolia* (Noni): a literature review and recent advances in noni research. *Acta. Pharmacol. Sin.* 23: 1127–1141.
- Yunes RA, Pedrosa RC, Filho VC (2001). Fármacos e Fitoterápicos: A necessidade do desenvolvimento da indústria de fitoterápicos e fitofármacos no Brasil. *Quím Nova*, 24: 147-152.