



# PATTERN OF MUSCULOCUTANEOUS AND MEDIAN NERVE COMMUNICATION IN ADULT CADAVERS

Mya Thein Shin, Phone Myint Htoo

Department of Human Anatomy, UCSI University Spring Hill Campus Negri Sembilan Malaysia.

Corresponding Author: Professor Mya Thein Shin. Email: [myatheinshin009@gmail.com](mailto:myatheinshin009@gmail.com)

ORCID ID: <https://orcid.org/0009-0004-1733-0222>

## ABSTRACT

**Background:** Variations in connections between the musculocutaneous and median nerves in the arm are not as uncommon as was once thought. Lesions of the communicating nerve may give rise to patterns of weakness that may impose difficulty in diagnosis. **Objective:** The aim of this study is to determine the variation of the musculocutaneous nerve (MCN) and analyze the incidence of nerve communication between the musculocutaneous and median nerves. **Methods:** Anatomical dissection was performed in the present work by using 62 arms from 31 adult cadavers, age ranging from eighteen to eighty years, which was donated to Medical Universities in Myanmar. Among the 62 studied arms, 26 arms (41.9%) were male, and 36 arms (58.1%) were female. **Results:** Nerve variation patterns were seen in four out of 62 studied arms (6.4%) and one arm (1.6%) showed no musculocutaneous nerve. One out of 62 studied arms (1.6%) revealed the musculocutaneous nerve did not pierce the coracobrachialis muscles but communicated with the median nerve in the upper third of arm. One out 62 studied arms (1.6%) revealed a musculocutaneous nerve piercing the coracobrachialis muscle and communicated with the median nerve in the upper third of arm. Communicating branch was found in two upper limbs (3.22%). **Conclusion:** The knowledge of these variations will allow physicians to correctly interpret anomalous innervation patterns of the upper limb.

**Keywords:** Anatomical variations, Musculocutaneous nerve, Median nerve

**DOI:** <https://dx.doi.org/10.4314/aja.v12i3.9>

## INTRODUCTION

The musculocutaneous nerve, a mixed peripheral nerve, arose from the lateral cord of the brachial plexus (C5, C6, and C7) opposite to the lower border of the pectoralis minor. It pierced the coracobrachialis muscle and then continued distally between the biceps and brachialis and innervated the muscles of the anterior compartment of the arm. At the lateral border of the tendon of the biceps, the musculocutaneous nerve became the lateral cutaneous nerve of the forearm [Sunderland, S, 1978; Snell, 2019]. The muscles supplied by the musculocutaneous nerve include coracobrachialis, biceps brachii, and brachialis. While the branch to the coracobrachialis left the musculocutaneous nerve before it entered the muscle, but branches to the biceps and brachialis left after passing through the muscle

[Krishnamurthy et al, 2007; Hayashi M et al, 2017 and Darvishi M, Moayeri A, 2019] description of the anatomical relationships of the musculocutaneous nerve and the motor branches to the biceps muscle had been widely documented in the literature [Linell,1921; Bergman, 1988; Buchanan and Erickson, 1996; Eglseder and Goldman, 1997; Chiarapattanakom et al, 1998 and Sungpet et al, 1998].

Instead of penetrating the coracobrachialis muscle the nerve may pass behind it or between it and the short head of the biceps muscle. Occasionally, the nerve perforates not only the coracobrachialis but also the brachialis or the short head of the biceps muscles [Bergman et al, 1988; Buchanan T.S, Erickson J.C, 1996; Eglseder and Goldman, 1997; Nakatani et al, 1997; and Prasada et al,2000]. This nerve arises from

the lateral cord (90.5%), from the lateral and posterior (4%), from the median nerve (2%), as two separate bundles from the medial and lateral cords (1.4%), or from the posterior cord (1.4%) [Budhiraja V et al, 2011; Hussain NS.2016; Nasrabadi HT et al, 2017 and Chrysikos D et al, 2020].

The variations of the musculocutaneous and median nerve may be classified in five types [Le Minor, 1992]. (Fig. 1).

**Type I:** there are no receiving fibers between the musculocutaneous and median nerve.

The musculocutaneous nerve pierces the coracobrachialis muscle and innervates the coracobrachialis, the biceps brachii, and the brachialis muscle.

**Type II:** although some fibers of the medial root of the median nerve unite the lateral

root of the median nerve and form the median nerve., other fibers run into the musculocutaneous nerve and after some distance leave it to join their proper trunk.

**Type III:** the lateral root of the median nerve from the lateral cord runs into the musculocutaneous nerve and after some distance leaves it to join their proper trunk.

**Type IV:** the fibers of the musculocutaneous nerve unite the lateral root of the median nerve after some distance, the musculocutaneous nerve arises from the median nerve.

**Type V:** the musculocutaneous nerve is absent. The fibers of the musculocutaneous nerve run into the median nerve along its course. The musculocutaneous nerve does not pierce the coracobrachialis muscle in this type.

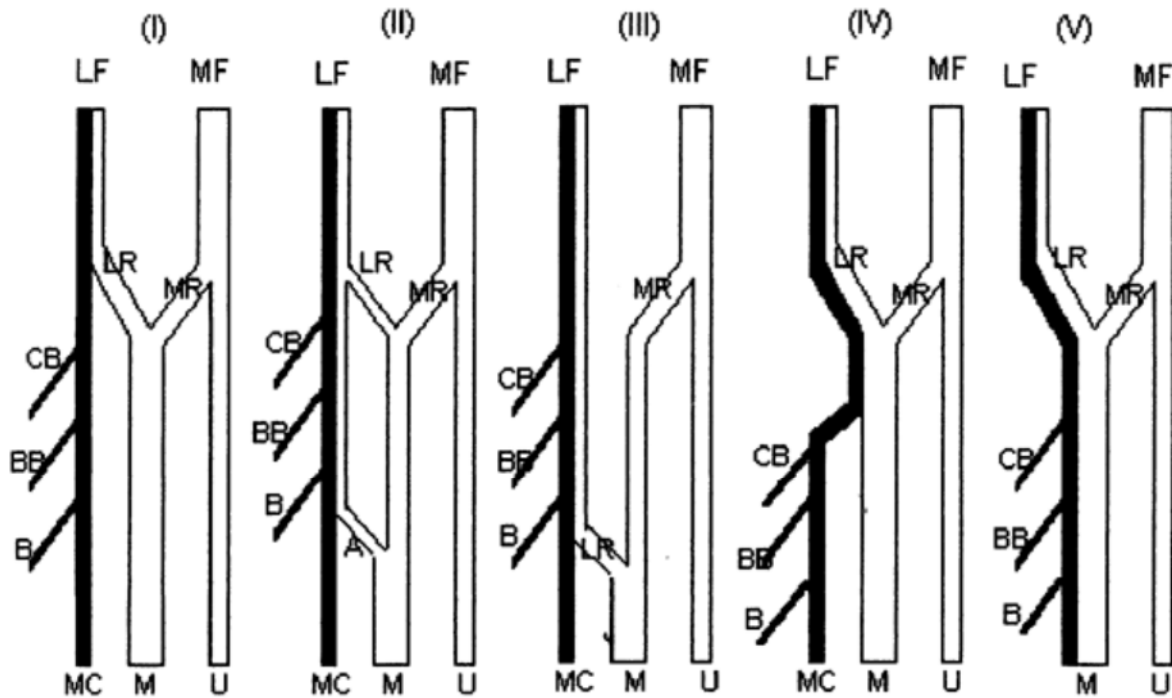


Fig. 1. shows, illustrations of five types of the musculocutaneous and median nerve. (I-V). [Le Minor, 1992]

Several variations in the course and distribution of the musculocutaneous nerve (MCN) have been reported. Instead of piercing the coracobrachialis muscle, the nerve may adhere to the median nerve for some distance down the arm and then, either

as a single trunk or as several branches pass between the biceps and brachialis muscles to supply all three muscles. Sometimes only a part of the nerve follows this course; this part then rejoins the main trunk after it transits through and supplies the coracobrachialis. In

some cases, instead of the whole trunk of the nerve piercing the coracobrachialis, only its muscular branch or only its cutaneous branch, pierces the muscle [Bergman et al, 1988; Venieratos D, Anagnostopoulou S, 1998; Krishnamurthy et al, 2007; Prasada R et al, 2001; Loukas M, Aqueelah H, 2005; Uzel AP et al, 2011; Parchand MP et al, 2016 and Chrysikos D et al, 2020]. The knowledge of the absence of MCN is important especially when performing plexus bloc or Latarjet's procedure [Uzel AP et al., 2011].

The musculocutaneous nerve and the lateral root of the median nerve originate from the lateral cord of the brachial plexus. It is possible that in embryonic development, some nerve fascicles that originally were part of the median nerve were transferred to the musculocutaneous nerve, and through these nerve communications in the arms, these fascicles are recovered by the median nerve [Uysal II et al, 2009, Ballesteros LE et al, 2015].

The communication between the musculocutaneous nerve and median nerve were clinically important, particularly in relation to the correct interpretation of clinical neurophysiology, understanding median and musculocutaneous nerve dysfunction. Variant nerves, having abnormal origin, course, and distribution might be prone to accidental injury and entrapment neuropathies. Lack of awareness of such variations in the median nerve and musculocutaneous nerve might thus complicate surgical repair of the nerves [Sunderland, 1978; Yang et al, 1995; Eglseder and Goldman, 1997; Nakatani et al, 1997; Rosen et al, 1998; Sungpet A et al, 1998; Prasada et al, 2000; Choi et al, 2002; Saeed M, 2003; Guerri RA, 2009; Maeda et al,

2009; Mehta V et al, 2009; El Falougy H et al, 2013; Caetano et al, 2016 and Emamhadi M et al, 2016]. Variable interconnections between the musculocutaneous and median nerves must be considered in the diagnosis of nerve lesions in the axillary and arm regions, making us aware of why debility after trauma to the lateral aspect of the upper arm may be more than expected, and this study considers the clinical and surgical importance of these variations of the MCN.

Anatomical variations of the brachial plexus and especially those of the MCN are quite common. Awareness of these variations is of paramount importance in clinical practice, mainly in achieving the best results in minimal invasive or surgical procedures. Knowledge of such anatomical variations is helpful for surgeons treating neoplasm or repairing trauma.

One of these variations belongs to the musculocutaneous nerve. However, a good knowledge of nerve pathways and their variations is essential for surgeons in posttraumatic evaluation, exploratory interventions, and/or administration of neuromuscular blocks in the axillary region for surgical therapy. Compound musculocutaneous and median nerve neuropathy would occur in lesions of the interconnecting branches. Injury of the musculocutaneous nerves, proximal to these branches can cause particular and unexpected symptoms, such as weakness of forearm flexors and thenar muscles.

The objective of this study is to demonstrate through anatomical dissection in the arms of adult cadavers, to determine the presence of anastomoses (nerve communication) between the musculocutaneous and median nerves and variations of the MC.

## **MATERIALS AND METHODS**

It is a dissection-based cross-sectional descriptive study, using adult cadavers (62 arms), among the 62 studied arms, 26 arms (41.9%) were male, and 36 arms (58.1%)

were female. Included arms from the Myanmar adult cadavers, age range from twenty to eighty years, which were donated to the Departments of Anatomy, University

of Medicine 1 and University of Medicine 2, Myanmar. Excluded those with upper limb deformities and those with disease or abnormalities of the upper limb.

A straight incision was made in the anterior compartment of the arm following the anterior midline, beginning in the supraclavicular region, and ending in the cubital fossa. Two flaps including the skin and subcutaneous tissue were folded on the medial and lateral sides, respectively. The same was done in relation to the arm fascia, thereby exposing the whole musculature. Dissection was done from proximal to distal,

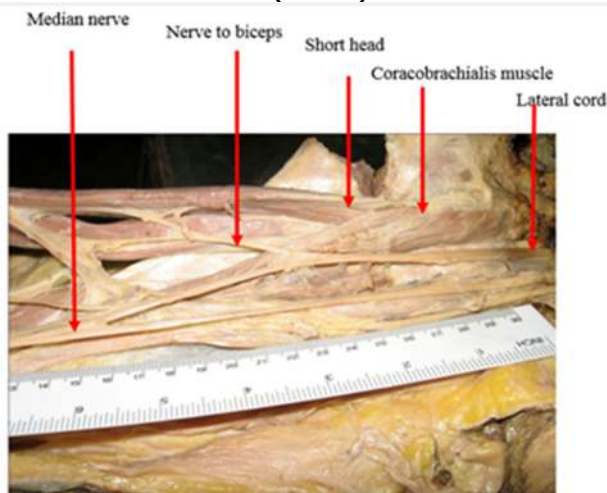
following the median and musculocutaneous nerve, certifying the presence or absence of variation and nerve communication. At the end, all dissections were photographed and cataloged.

Data were collected by a data master sheet and then installed into Statistical Package for Social Sciences SPSS 16.0 software. Data were checked for missing values. Consent was obtained from each family members for the cadavers donated to the Medical Universities for teaching and research purposes.

## RESULTS

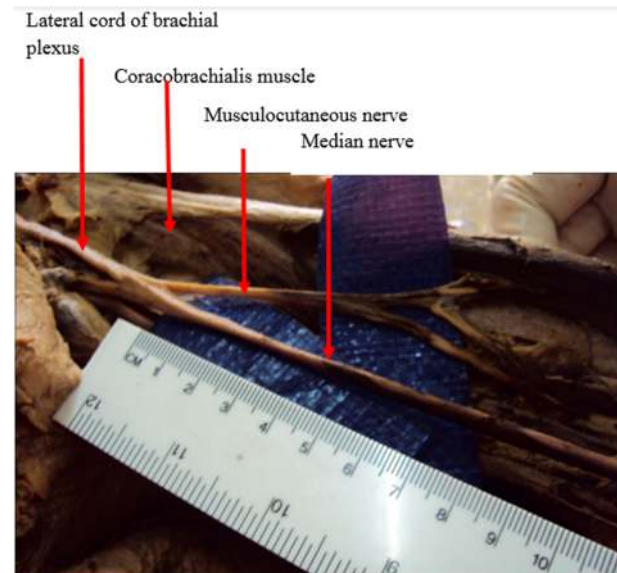
Nerve variation pattern was seen in 4 out of 62 studied arms (6.4 %) (Table 1). One arm (1.6 %) showed absence of a musculocutaneous nerve in the right arm of a male cadaver (Fig 2). One out of 62 studied arms (1.6 %) revealed the musculocutaneous nerve did not pierce the coracobrachialis muscles in the left arm of the male cadaver (Fig.3). One out of 62 studied arms (1.6%) revealed the

musculocutaneous nerve did not pierce the coracobrachialis muscle and communicated with the median nerve in the upper one-third of the left arm of the female cadaver (Fig.4). One out of 62 studied arms (1.6%) revealed a musculocutaneous nerve communicating with the median nerve after piercing the coracobrachialis muscle in the left arm of the female cadaver (Fig.5).



**Figure 2.** Photograph of medial view of the right arm showing absence of musculocutaneous nerve.

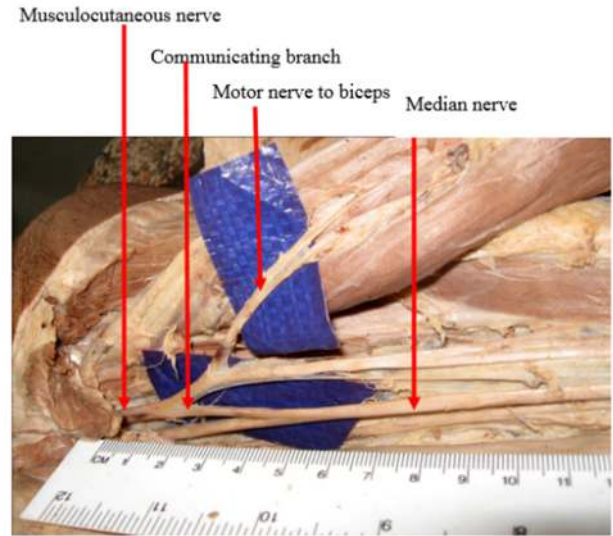
(a)the lateral cord does not pierce the coracobrachialis muscle, (b) nerve to the biceps brachii muscle arises from the lateral cord, (c) median nerve formation in the mid arm of the right side. (Cadaver No 6, male)




**Figure 3.** Photograph showing the musculocutaneous nerve did not pierce the coracobrachialis muscle in the left arm. (Cadaver No11, male).

Table 1: Nerve variation pattern

Sex	Side	Nerve variation pattern	Frequency
Case No (6) Male	Right	No musculocutaneous nerve; Median nerve formed at the mid arm; lateral cord supply muscles of the anterior compartment of arm (Figure.2)	1
Case No (11) male	Left	Musculocutaneous nerve does not pierce the coracobrachialis muscle. (Figure.3)	1
Case No (9) Female	Left	Musculocutaneous nerve did not pierce the coracobrachialis muscle but communicated with the median nerve in the upper 1/3 of arm (Figure.4)	1
Case No (14) Female	Left	Musculocutaneous nerve pierced the coracobrachialis muscle and communicated with the median nerve in the upper 1/3 of arm (Fig.5)	1



**Figure 4.** Photograph showing the musculocutaneous nerve did not pierce the coracobrachialis muscle and communicated with the median nerve in the upper one-third of the left arm. (Cadaver No 9, female)



**Figure 5.** Photograph showing the musculocutaneous nerve communicating with the median nerve after piercing the coracobrachialis muscle in the left arm. (Cadaver No 14, female)

**DISCUSSION**

There had been many reports of the occurrence of a communication between the musculocutaneous and median nerves ranging from 10% to 42% by the following author [Sunderland (1978), Le Minor (1992), Kosugi et al (1992), Yang et al (1995), Eglseider and Goldman (1997), Rosen J.E et

al (1998), Prasada and Chaudhary (2000), Uzun A (2001), Choi et al (2002), Saeed and Rufai (2003), Loukas M and Aqueelah H (2005), Pacha Vicente D et al (2005), Krishnamurthy et al (2007), Uysal et al (2009), Kervancioglu P (2011), Uzel AP et al (2011), Parchand MP (2012), Ballesteros LE

et al (2014), Caetano et al (2016), Emamhadi M et al (2016), Hussain NS (2016), Hayashi M et al (2017), Nasrabadi HT et al (2017), Darvishi M (2019), Chrysikos D et al (2020)]. The most frequently reported variants include (i) the presence of a communicating branch on the median nerve, (ii) the musculocutaneous nerve did not perforate the coracobrachialis muscle. (iii) absence of MCN. According to the above authors, the absence of musculocutaneous nerve was variant. Choi et al (2002) reported the absence of MCN in 5% of cases, in this study, the incidence of unilateral absence of MCN is only 1.6%. In this study, the incidence of communicating branches between MCN and MN is 3.22%. Venieratos and Anagnostopoulou (1998) classified the communication of the MCN and MN in the upper arm into three types. Type I: communication proximal to the entry of the MCN into the coracobrachialis muscle, Type II: communication distal to the coracobrachialis muscle, and Type III: the MCN as well as the communicating branch did not pierce the coracobrachialis muscle. In this study, Type II and III communication were found. Kosugi K (1992) and Gueri-Guttenberg RA (2009) reported MCN-MN communication incidence higher than 40% of cases, but according to Uysal II (2009), Bhattarai C (2009) less than 15%. Caetano EB et al (2016), Ballesteros LE (2015), and Kervancioglu (2011) recorded nerve communication in 25% incidence in limbs of dissected fetuses. Multiple factors such as the sample size and the biological characteristics of the studied population may interfere with the variability of the results. In this study, there was no bilateral occurrence of communication between MCN and MN. The low incidence of bilateralism was also recorded by [Kosugi K (1992), Venieratos D and Anagnostopoulou S (1998), Prasada Rao (2000), Choi D et al (2002), Loukas M (2005)]. The present study could place into categories II and III the classification of the above authors. It is

useful for orthopedic surgeons while dealing with injuries in the arm and elbow region. Knowledge of these communications may help to explain when a high median nerve paralysis exists in the axilla or proximal part of the arm in a patient presenting weakness of forearm flexion and supination and useful in avoiding unnecessary distal release of the median nerve.

MCN was absent in amphibians and reptiles whose muscles in the upper arm were solely innervated by the median nerve [Prasada and Chaudhary, 2000]. Because of the anatomical findings reported in dogs, monkeys, and some apes, it has been suggested that these communications might present a primitive nerve supply of the anterior arm muscle.

There were several studies in the literature which reported the concurrent occurrence of MCN and MN communication with accessory heads of the biceps brachii muscle. Maeda et al (2009) reported 148 (25.8%) cases of accessory heads of the biceps brachii muscle out of 574 cases, communications between MCN and MN were observed in 71 (48%) of those 148 cases. Kosugi et al (1992) found a third head of biceps brachii in 75 out of 546 arms (13.7%). In 43 arms out of 75 there were communications present between MN and MCN (57.3%). It was concluded that the presence of a supernumerary head seemed to affect the course and branching pattern of the musculocutaneous nerve.

Presence of a third head on the left side and absence of musculocutaneous nerve on the right side were found only in one case in this study (1.6%). The third head associated with the communication between MN and MCN on the same side was not found in this study.

The findings in this study are consistent with the literature concerning to the predominance of unilateral occurrence over bilateral occurrence [Kosugi.K et al, 1992; Choi.D et al, 2002; Loukas.M and



Aqueelah.H, 2005; EL Fa Lougy.H et al, 2013; Chitra R, 2007; Venieratos D and Anagnostopoulou S,1998]. All prior studies established the significant predominance of the presence of a single communicating branch within the range of 90–93.2% and the presence of two communicating branches with a low frequency (6.8–10.7%) [Venieratos D and Anagnostopoulou S,1998; Loukas.M and Aqueelah.H, 2005; Chitra R, 2007; Pacha Vicente D et al, 2005;].

This study describes the presence of Type I MCN-MN communication. This communication is reported by most authors as the most common with an incidence of 45–72%. [Maeda S et al, 2009; Choi D et al, 2002; Venieratos D and Anagnostopoulou S,1998]. Similarly, the communicating branch that arose from the mid-segment of the MCN (subtype b) indicated by some authors [Bhattarai C, Poudel PP, 2009; Chiarapattanakom P et al, 1998; Maeda S et al, 2009] as the most common one agrees with the findings of this study.

The communications reported by other studies that are present before the MCN pierces the coracobrachialis muscle [Venieratos D and Anagnostopoulou S,1998; Choi D et al, 2002; Loukas.M and Aqueelah.H, 2005] were not found in this study. It is probably due to the differences of the researcher's interpretation about how the lateral and medial fascicles form the MN. Most authors only refer that the communicating branch goes from MCN to MN [Venieratos D and Anagnostopoulou S, 1998; Beheiry.EE, 2004; Loukas.M and Aqueelah.H, 2005; Pacha Vicente D et al, 2005; Bhattarai C, Poudel P.P, 2009; Uysal II et al, 2009; Budhiraja V et al, 2011; Krishnamurthy A et al, 2007; Prasada Rao P.V, Chaudhary S.C, 2000], however Type II communication from MN to MCN was not found in this study in 2.8% according to reported in other studies with an incidence of 4.4–12.8%, [Chiapattanakom P et al,1998; Krishnamurthy A et al, 2007;Maeda S et al, 2009], whereby

the communication between MCN and MN may occur both ways.

Most research has made a qualitative description about MCN-MN communication, and only a few prior studies have reported the length of the communicating branch [Elgseder and Goldman, 1997; Loukas.M and Aqueelah.H, 2005; Chitra R, 2007;]. In this study, the length of the communication branch is not measured.

The MCN-MN communicating branch was associated with an additional head of the biceps brachii in 1.6% cases in this study, it has also been highlighted by other authors [Kosugi K, Shibata S et al, 1992; Maeda S et al, 2009; Ozturk N.C et al, 2010]. During the planning of surgical procedures in the arm, it is important to remember that approximately 1 in 4 upper limbs assessed may present an MCN-MN communication associated with an additional head of the biceps brachii.

MCN entrapment is rare. It can occur due to an inadequate positioning of the arm during sleep (Merrell G.A et al, 2001 and Yang L.J et al, 2012) because the coracobrachialis muscle and brachialis muscle act as an anchor point for MCN. If this situation coexists with a communicating branch where a part of MN passes through the coracobrachialis muscle, the clinical signs could be like those found in MN neuropathy in the hand [Wertsch J.J, Melvin J, 1982; EL Falougy H et al, 2013;]. The diagnosis of MCN-MN communication in this clinical presentation by electromyographic methods could prevent unnecessary release of the carpal tunnel.

The MCN-MN communication should be considered for clinical examination of nerve injuries at the axilla and the arm, as well as in surgical procedures on this region like neuromuscular flaps, peripheral nerve repair or even for nerve blocks at the upper extremities in anesthetic practice. The MCN or MN injuries proximal or distal to the

communicating branches could determine beneficial or deleterious modifications in the function and movement of the upper extremity [Loukas.M and Aqueelah.H, 2005; Bhattarai C, Poudel P.P, 2009]. The MCN injury proximal to the MCN-MN communication can lead to an unexpected weakness of the forearm flexor muscles and thenar muscles with clinical signs like those seen in a MN injury at the level of the arm. Furthermore, the MN injury proximal to the MN-MCN communication can lead to a clinical presentation characterized by functional preservation of the forearm and hand muscles innervated by MN [EL Falougy H et al, 2013].

It was well known that MCN innervates the elbow flexors, and function could be improved by intercostal nerve transfer or graft to the musculocutaneous nerve or its motor branches [Samii et al, 1997; Chung I.H,1998; Millesi H, 1988]. For clinical investigation and surgical treatment of peripheral nerve injury, a more precise knowledge than that found in classical anatomical texts, was necessary. In view of the above applications and the increase in reconstructive brachial plexus surgery, the incidence of communication between the musculocutaneous and median nerves is essential in this study. Spastic flexion deformity of the elbow is mainly mediated by the biceps brachii and the brachialis muscles, innervated by the musculocutaneous nerve. Selective neurectomy of the musculocutaneous nerve showed promising results to relieve excessive spasticity in the long term but lacks a consensual surgical strategy. [Malessy, M.J, Thomeer, R.T, 1998; Merrell G.A et al, 2001;Cambon-Binder A, 2014; Leclercq C and Gras M, 2016].

Such variations have also clinical importance, especially in posttraumatic evaluation and exploratory innervation of the arm for peripheral nerve repair.

Table 2. Incidence of musculocutaneous – median nerve communication in a diverse population according to several authors.

Author, year	Population	Sample size	MC-MN(%)	MN-MCN(%)	Total
Kosugi et al., 1992	Japanese	75	54.7	–	54.7
Yang et al., 1995	Singaporean	24	12.5	–	12.5
Eglseder et al., 1997	American	108	36	–	36
Chiarapattanakon et al., 1998	Thai	112	11.6	4.4	16
Venieratos et al., 1998	Greek	158	13.9	–	13.9
Prasada Rao PV, Chaudhary SC.,2000	Zimbabwe	24	33		33
Choi et al., 2002	British	276	26.4	–	26.4
Beheiry. 2004	Egyptian	60	5	–	5
Loukas et al., 2005	American	258	46.1	–	46.1
Pacha et al., 2005	Spanish	46	28.3	–	28.3
Krishnamurthy et al., 2007	Indian	44	9.1	6.8	15.9
Bhattarai et al., 2009	Nepalese	32	6.3	–	6.3
Guerri-Guttenberg et al., 2009	Argentinean	56	53.6	–	53.6
Maeda et al., 2009	Japanese	453	18.8	12.8	41.5
Uysal et al., 2009	Turkish	140	10	–	10
Budhiraja et al., 2011	Indian	116	20.7	–	20.7
Kervancioglu et al., 2011	Turkish	20	25	–	25
Ballesteros et al.,2015	Colombian	106	17	2.8	19.8
Caetano et al., 2016	Brazil	40	25	-	25



Present study	Myanmar	62	3.2	-	3.2
---------------	---------	----	-----	---	-----

The knowledge of the variations of this communication between the musculocutaneous and median nerves in the distal third of the arm is important in the anterior approach for the fracture of the humerus. This knowledge is also important for the clinicians to avoid unnecessary release of the carpal tunnel by them. Lesions of the communicating nerve may give rise to patterns of weakness that may impose difficulty in diagnosis. Clinical implication of this could be that injury of the musculocutaneous nerve proximal to the anastomotic branch between the musculocutaneous and median nerves may lead to an unexpected presentation of weakness of the forearm flexors and thenar muscles [Sunderland, S. 1978].

## CONCLUSION

Variations of the median nerve, musculocutaneous nerve, and their

communicating branches are of interest for anatomists and surgeons. These variations may be vulnerable to damage in surgical procedures. It is essential to know these anatomical variations, especially when considering clinical examination, diagnostic, prognostic, and surgical treatment.

This present study provides the evidence of variation of musculocutaneous nerves in Myanmar adults. The knowledge of the anatomical variations of the peripheral nerve system can help explain an incomprehensible clinical sign. In conclusion, this study confirms many aspects of the previously mentioned literature, the better understanding of the variations of MCN, and the presence of a communicating branch to the median nerve that emerges from this study will aid in developing better surgical repair procedures and postoperative results.

## Conflict of interest

No conflict of interest

## REFERENCES

1. Ballesteros LE, Forero PL, Buitrago ER. (2015). Communication between the musculocutaneous and median nerves in the arm: an anatomical study and clinical implications. *Rev Bras Ortop.* 2014 Dec 27;50(5):567-72. doi: 10.1016/j.rboe.2014.08.009. eCollection 2015 Sep-Oct. PMID: 26535190 Free PMC article.
2. Beheiry EE. (2004). Anatomical variations of the median nerve distribution and communication in the arm. *Folia Morphol (Warsz)* 2004;63(3):313–318. - PubMed
3. Bergman, R.A., Thompson, S.A., Afifi, A.K. and F.A. Saadeh. (1988) *Compendium of Human Anatomic Variation.* Munich and Baltimore.
4. Bhattarai C, Poudel PP. Unusual variation in musculocutaneous nerves in Nepalese. (2009). *Kathmandu Univ Med J (KUMJ)* 2009;7(28):408–410. - PubMed
5. Buchanan, T.S., Erickson, J.C. (1996) Selective block of the motor point of biceps brachii muscle. An anatomic investigation of musculocutaneous nerve branching. *Reg Anesth.* 21:89-92.
6. Budhiraja V, Rastogi R, Asthana AK, Sinha P, Krishna A, Trivedi V. (2011). Concurrent variations of median and musculocutaneous nerves and their clinical correlation--a cadaveric study. *Ital J Anat Embryol.* 2011;116(2):67-72 PMID: 22303635.
7. Caetano EB, Vieira LÂ, Cavalheiro CS, Razuk M Filho, Almargo MA, Caetano MF. (2016). The anatomic study of the nervous communication between the median and musculocutaneous nerves. *Acta Ortop Bras.* 2016 Jul-Aug;24(4):200-203. doi: 10.1590/1413-785220162404159372. PMID: 28243174 Free PMC article.

8. Cambon-Binder A, Leclercq C. (2014). Anatomical study of the musculocutaneous nerve branching pattern: application for selective neurectomy in the treatment of elbow flexors spasticity. *Surg Radiol Anat.* 2015 May;37(4):341-8. doi: 10.1007/s00276-014-1371-x. Epub 2014 Sep 6 PMID: 25193328
9. Chiarapattanakom P, Leechavengvongs S, Witoonchart K, Uerpairojkit C, Thuvasethakul P.J. (1998) Anatomy and internal topography of the musculocutaneous nerve: the nerves to the biceps and brachialis muscle. *Hand Surg Am.* 1998 Mar;23(2):250-5. doi: 10.1016/S0363-5023(98)80122-6 PMID: 9556264
10. Choi D, Rodríguez-Niedenführ M, Vázquez T, Parkin I, Sañudo JR. (2002). Patterns of connections between the musculocutaneous and median nerves in the axilla and arm. *Clin Anat.* 2002 Jan;15(1):11-7. doi: 10.1002/ca.1085. PMID: 11835538 Review.
11. Chrysikos D, Athanasopoulos A, Georgakopoulos P, Antonopoulos I, Samolis A, Troupis T. (2020). Anatomical Variation of a Communicating Branch between the Musculocutaneous and the Median Nerve: A Case Report. *Acta Med Acad.* 2020 Apr;49(1):71-74. doi: 10.5644/ama2006-124.286. PMID: 32738120
12. Chung, I.H., Yeh, M.C., Yoon, K.M. (1998) Intercostal nerve transfer of musculocutaneous nerve in avulsed brachialis plexus injury *J Hand Surg* 17:822-828.
13. Darvishi M, Moayeri A. (2019). Anatomical Variations of the Musculocutaneous and Median Nerves: A Case Report. *Folia Med (Plovdiv).* 2019 Jun 1;61(2):327-331. doi: 10.2478/folmed-2018-0080. PMID: 31301650
14. Eglseder Jr., W.A. and M. Goldman (1997). Anatomic variations of the musculocutaneous nerve in the arm. *Am. J. Orthop.* 26(11):777-780.
15. El Falougy H, Selmeçiova P, Kubikova E, Stenova J, Haviarova Z. *Bratisl Lek Listy.* (2013). The variable communicating branches between musculocutaneous and median nerves: a morphological study with clinical implications. 2013;114(5):290-4. doi: 10.4149/bll\_2013\_061. PMID: 23611054
16. Emamhadi M, Chabok SY, Samini F, Alijani B, Behzadnia H, Firozabadi FA, Reihanian Z. (2016). Anatomical Variations of Brachial Plexus in Adult Cadavers; A Descriptive Study. *Arch Bone Jt Surg.* 2016 Jun;4(3):253-8. PMID: 27517072 Free PMC article.
17. Guerri-Guttenberg RA, Ingolotti M. (2009). Classifying musculocutaneous nerve variations. *Clin Anat.* 2009 Sep;22(6):671-83. doi: 10.1002/ca.20828. PMID: 19637305 Review. Dec;95(311):146-50. doi: 10.1016/j.morpho.2011.10.001. Epub 2011 Nov 10. PMID: 22079600 Review. French.
18. Hayashi M, Shionoya K, Hayashi S, Hatayama N, Kawata S, Qu N, Hirai S, Miyaso H, Itoh M. (2017). A novel classification of musculocutaneous nerve variations: The relationship between the communicating branch and transposed innervation of the brachial flexors to the median nerve. *Ann Anat.* 2017 Jan;209:45-50. doi: 10.1016/j.aanat.2016.08.004. Epub 2016 Oct 17. PMID: 27765675
19. Hussain NS. (2016). Cadaveric Study of Anatomic Far Distal Musculocutaneous and Median Nerve Communication. *Cureus.* 2016 Jun 2;8(6): e627. doi: 10.7759/cureus.627. PMID: 27433406 Free PMC article. Retracted.
20. Kervancioglu P, Orhan M, Kilinc N. (2011) Patterns of motor branching of the musculocutaneous nerve in human fetuses and clinical significance. *Clin Anat.* 2011;24(2):168–178. - PubMed
21. Kosugi K, Shibata S, Yamashita H. (1992) Supernumerary head of biceps brachii and branching pattern of the musculocutaneous nerve in Japanese. *Surg Radiol Anat.* 1992;14(2):175–185. - PubMed

22. Krishnamurthy A., Nayak S.R., Venkatraya Prabhu L., Hegde R.P., Surendran S., Kumar M. The branching pattern and communications of the musculocutaneous nerve. *J Hand Surg Eur.* 2007;32(5):560–562. - PubMed
23. Le Minor JM (1992) A rare variant of the median and musculocutaneous nerves in man. *Arch Anat Hist Embr* 73 33-42
24. Leclercq C and Gras M., (2016) Hyperselective Neurectomy in the treatment of the spastic upper limb. *Phys Med Rehabil Int.* 2016; 3(1): 1075.
25. Linell, E.A. (1921) The distribution of nerves in the upper limb, with reference to variabilities and their clinical significance. *J. Anat.* 55:79-112.
26. Loukas M, Aqueelah H. (2005) Musculocutaneous and median nerve connections within, proximal and distal to the coracobrachialis muscle. *Folia Morphol (Warsz).* 2005 May;64(2):101-8.PMID: 1612132
27. Maeda S, Kawai K, Koizumi M, Ide J, Tokiyoshi A, Mizuta H, et al (2009). Morphological study of the communication between the musculocutaneous and median nerves. *Anat Sci Int.* 2009;84(1-2):34–40. - PubMed
28. Malessy, M.J., Thomeer, R.T. (1998) Evaluation of intercostals to musculocutaneous nerve transfer in reconstructive brachial plexus surgery. *J Neurosurg:* 88:266-271.
29. Mehta V., Yadav Y., Arora J., Kumar H., Suri R., Rath G. (2009). A new variant in the brachium musculature with reinforced innervation from a median-musculocutaneous nerve communication. *Morphologie.* 2009;93(301):63–66. - PubMed
30. Merrell G.A., Barrie K.A., Katz D.L., Wolfe S.W. Results of nerve transfer techniques for restoration of shoulder and elbow function in the context of a meta-analysis of the English literature. *J Hand Surg Am.* 2001;26(2):303–314. [PubMed] [Google Scholar]
31. Millesi, H. (1988) Nerve grafting in brachial plexus injuries. *Clin Orthop Rel Res.*237:36-42.
32. Nakatani, T., Mizukami, S. and S. Tanaka. (1997) Three cases of the musculocutaneous nerve not perforating the coracobrachialis muscle. *Kaibogaku Zashi.* 72(3): 191-194.
33. Nasrabadi HT, Abedelahi A, Shoorei H, Shokoohi M, Salimnejad R, Dolatkah MA, Seghinsara AM.(2017).A variation of Musculocutaneous nerve without piercing the coracobrachialis muscle while communicating to the median nerve: A case report and literature review. *Int J Surg Case Rep.* 2017 Nov 15;41:453-455. doi: 10.1016/j.ijscr.2017.11.020. e Collection 2017.PMID: 29546015 Free PMC article.
34. Pacha Vicente D., Forcada- Calvet P., Carrera- Burgaya A., Llusá- Pérez M. (2005) Innervation of biceps brachii and brachialis: anatomical and surgical approach. *Clin Anat.* 2005;18(3):186–194. - PubMed
35. Parchand MP, Patil ST. (2012). Absence of musculocutaneous nerve with variations in course and distribution of the median nerve. *Anat Sci Int.* 2013 Jan;88(1):58-60. doi: 10.1007/s12565-011-0126-6. Epub 2012 Jan 12. PMID: 22237923
36. Prasada Rao PV, Chaudhary SC. (2000). Communication of the musculocutaneous nerve with the median nerve. *East Afr Med J.* 2000 Sep;77(9):498-503.PMID: 12862142
37. Rosen, J.E., Rokito, A.S., Khabie, V., and J.D. Zuckerman. (1998) Examination of the lateral antebrachial cutaneous nerve: an anatomic study in human cadavers. *Am. J. Orthrop.* 27(10):690-692.
38. Saeed, M., Rufai, A.A. (2003) Median and musculocutaneous nerve variant, formation and distribution. *Clin Anat* 16: 197-203.
39. Samii, M., Carvalho, G.A., Nikkhah, G., Penkert, G. (1997). Surgical reconstruction of the musculocutaneous nerve in traumatic brachial plexus injuries. *J Neuro Surg;* 87:881-886.
40. Snell, Richard S., (2019). *Clinical anatomy by regions, 10th ed. / LAWRENCE E. WINESKI*

41. Sunderland, S. (1978) Nerves and Nerves injuries. 2nd ed. Edinburgh, London and New York; Churchill Livingstone: p 656-727.
42. Sungpet, A, Suphachatwong, C., Kawinwonggowit, V (1998) Surgical anatomy of bicipital branch of musculocutaneous nerve. J Med; Assoc: Thai: 81: 532- 535.
43. Uysal II, Karabulut AK, Büyükmumcu M, Unver Dogan N, Salbacak A. (2009) The course and variations of the branches of the musculocutaneous nerve in human fetuses. Clin Anat. 2009;22(3):337–345. - PubMed
44. Uzel AP, Bulla A, Steinmann G, LaurentJoye M, Caix P. (2011). Absence of the musculocutaneous nerve and its distribution from median nerve: About two cases and literature review. Morphologie. 2011
45. Uzun A, Seelig LL Jr (2001). A variation in the formation of the median nerve: communicating branch between the musculocutaneous and median nerves in man. Folia Morpho (Warsz). 2001;60(2):99-101.PMID: 11407150
46. Venieratos D, Anagnostopoulou S (1998). Classification of communications between the musculocutaneous and median nerves. Clin Anat. 1998;11(5):327-31. doi: 10.1002/(SICI)1098-2353(1998)11:5<327: AID-CA6>3.0.CO;2-M.PMID: 9725577
47. Wertsch J.J., Melvin J. Median nerve anatomy and entrapment syndromes: a review. Arch Phys Med Rehabil. 1982;63(12):623–627. [PubMed] [Google Scholar]
48. Yang, Z.X. Pho R.W., Khour, A.K. and B. P. Periera (1995) The musculocutaneous nerve and its branches to the biceps and brachialis muscles. J. Hand Surg. (Am) 20(4):671-67