



# RESTORATIVE EFFECTS OF SILYMARIN MILK THISTLE ON THE LIVER FOLLOWING PARACETAMOL-INDUCED HEPATOTOXICITY IN ADULT ALBINO RATS

Davis Kiprono Ngetich<sup>1</sup>, Scolastica Korir<sup>2</sup>, Molly Okoth<sup>3</sup>

<sup>1</sup>Department of Human Anatomy, School of Medicine, Maseno University, Kisumu, Kenya.

<sup>2</sup>Department of Medical Microbiology, School of Medicine, Maseno University, Kisumu, Kenya

<sup>3</sup>Department of Pharmacology, School of Pharmacy, Maseno University, Kisumu, Kenya

Corresponding Author: Davis Kiprono Ngetich. Email: [davis.ngetich@yahoo.com](mailto:davis.ngetich@yahoo.com)

ORCID ID: <https://orcid.org/0000-0002-6488-4162>

## ABSTRACT

**Background:** Paracetamol-induced hepatotoxicity has been on the rise worldwide and there is a need for restorative measures to counter its effect. Silymarin milk thistle is an herb that has been used for the treatment of liver conditions. This current study aimed at determining the restorative effects of silymarin milk thistle on the liver morphology and terminal body weight of paracetamol-induced hepatotoxicity among albino rats. **Methodology:** This study was conducted at Maseno University, and a posttest-only experimental design was used. A total of 24 adult albino rats were randomly selected and grouped into four groups, each consisting of six albino rats. Positive control received (5 days of high-dose paracetamol 750mg/kgbw) and negative control received no drug intervention. Three experimental groups received high-dose paracetamol for five days and were thereafter given varying doses of silymarin milk thistle (low-dose group: 200 mg/kgbw, medium-dose: 400 mg/kgbw and high-dose: 600 mg/kgbw) of silymarin milk thistle. Gross liver morphological data and body weight were expressed as mean  $\pm$  SEM. A one-way ANOVA analysis of variance was used to test the mean groups and a post hoc test was used to test the difference between the mean groups. A  $p \leq 0.05$  was found to have statistical significance at a 95% confidence interval. **Results:** This current study found that there was a significant ( $p \leq 0.0001$ ) increase in mean weight, volume, length, and width of the liver in the high dose silymarin milk thistle group as compared to the positive control group. There was a significant ( $p \leq 0.0001$ ) reduction in the terminal mean body weight of the rats in the positive control group, low dose silymarin group and the medium dose silymarin group respectively, as compared to the negative control group. **Conclusion:** Silymarin milk thistle was found to have restorative effects on the liver morphology and body weight following paracetamol toxicity at high dose.

**Keywords:** silymarin milk thistle, hepatotoxicity, liver morphology, animal weight, paracetamol.

**DOI:** <https://dx.doi.org/10.4314/aja.v12i3.5>

## INTRODUCTION

Paracetamol is the commonly used analgesic and antipyretic around the world, readily available for use among the population. It is regarded as the drug of choice for people who have sensitivities to non-steroidal anti-inflammatory drugs, the underage and also pregnant and lactating women (Jozwiak-Bebenista, 2014). It has been found that paracetamol is the most common drug that causes liver toxicity since it is metabolized in the liver, and its overdose may cause injury

to the liver. Its availability worldwide, with or without a prescription, has steadily increased the number of paracetamol-induced liver intoxications (Jozwiak-Bebenista, 2014).

Prolonged use of paracetamol or at high doses causes oxidative metabolites N-acetylpara-benzoquinone mine (NAPQI) to cause the liver cells to be under oxidative stress. This, therefore, will cause the hepatocellular mitochondria to burst, leading to free oxygen radicals and nitrogen ions causing necrosis of

hepatocellular cells leading to liver damage (Majee, 2013).

Paracetamol has long been considered nontoxic when given in therapeutic doses, though it might result in hepatotoxicity when taken singly, repeated in high doses, or after it's been chronically ingested (Tittarelli *et al.*, 2017). Toxicity may also arise when there is poor dietary intake and nutritional status of an individual or in alcohol intake, even when administered at a therapeutic dose (Kurtovic & Riordan, 2003; Eriksson *et al.*, 1992).

Silymarin, an edible herb, has been found to have hepato-protective effects on the liver, and it has antioxidant, scavenging and regulation of glutathione contents within the cell thus causing cell membrane stabilization and regulation of permeability into the cell, thereby preventing hepatotoxic agents from getting into the hepatocytes (Fraschini *et al.*, 2002). These anti-oxidant properties of silymarin have been found to greatly reduce free radicals that are produced secondary to the metabolism of toxic substances such as paracetamol and alcohol, thereby improving the integrity of the mitochondria and maintaining redox balance, thus maintaining liver function. Silymarin also increases (Vargas-Mendoza *et al.*, 2014; Surai, 2015) glutathione which will promote the antioxidant defense of the liver.

Silymarin milk thistle has also been found to have significant improvement in liver histology and liver biomarkers for patients with chronic liver disease, with it also playing a critical role in liver defense by increasing liver glutathione, hepatocyte protein synthesis by stimulating RNA polymerase I

activity (Jacobs *et al.*, 2002; Vargasdoza *et al.*, 2014). The effects of silymarin on the hepatocytes of alcohol-induced liver cirrhosis were found to have a significant reduction in tumor cell proliferation, angiogenesis and resistance to insulin, liver fibro-genesis and promotion of hepatocyte regeneration (Feher & Lengyel, 2012).

From the literature reviewed, there is still a deficiency of information on the hepato-restorative morphological changes and terminal body weight changes associated with paracetamol toxicity. Paracetamol is a drug that is tolerable by a large population, however, paracetamol toxicity causes side effects in the liver. This present study was conducted on adult albino rats of the species *Rattus Norvegicus* to determine changes in the liver morphology and terminal body weights upon administration of varying doses of silymarin milk thistle on paracetamol-induced toxicity.

With the increasing level of liver failures arising from toxicities from various agents such as drugs or alcohol (Stefan & Hamilton, 2010), a restorative remedy should be sought to help in managing the disease and improve the quality of life and health in the population. Scientific data on dosage and administration is of great importance in the application of various types of medicinal herbs to counter liver toxicities. Silymarin milk thistle is a medicinal herb that widely grows in most of the climatic conditions worldwide, and it has been used in managing liver conditions, though there is still inadequacy of data on the hepato-restorative effects that this study sought to find out.

## MATERIALS AND METHODS

### Study subjects

This study was conducted on pure bred albino rats of the species *Rattus norvegicus* from a pure colony sourced from the Department of Biomedical Sciences of Maseno University. This study used albino

rats as study subjects due to various facts; they have a short gestational period, they are small in size and easy to handle during the experimental study, are able to withstand a wide range of medicines and they share similar biological characteristics with humans

therefore, they replicate same results (Pritchett & Corning, 2004). They were put in polycarbonate cages in the animal house and fed with standard rodent pellets and water *ad libitum* throughout the entire experimental period. **Study design:** A Posttest-only experimental study design was used.

### **Sample size determination and sampling technique**

The sampled size was arrived at using Modified Resource equation method (Arifin, 2017). A total of 24 albino rats were used in this study.

**Sampling technique;** a simple random sampling method was used to obtain the 24 animals from a colony in the animal house and also randomly sampled into the two major groups of Experimental groups and Control groups. These included;

A: Negative control group- this group did not receive any drug intervention.

B: Positive control group- high dose paracetamol (750 mg/kgbw) for five days.

C: Low dose Silymarin group- received high dose of paracetamol (750 mg/kgbw) for five days for hepatotoxicity induction, thereafter low dose of silymarin milk thistle (200 mg/kgbw) for the remaining days.

D: Medium dose Silymarin group- received high dose of paracetamol (750 mg/kgbw) for five days for hepatotoxicity induction, thereafter medium dose of silymarin milk thistle (400 mg/kgbw) for the remaining days.

E: High dose Silymarin group- received high dose of paracetamol (750 mg/kgbw) for five days for hepatotoxicity induction, thereafter high dose of silymarin milk thistle (600 mg/kgbw) for the remaining days.

### **Drugs**

The paracetamol tablets were obtained from Litein Central Chemist, Kericho County, Kenya (BN: 2H103), while the silymarin milk thistle tablets were obtained from Dynapharm Kenya Limited, Nakuru City.

They were prepared by dissolving in water for injection before being administered orally.

### **Data collection**

To achieve the liver morphological parameters of length and width, a digital Vanier caliper was used, while a digital weighing scale was used to obtain liver weight and animal weight. The animal weights were taken at the beginning of the experiment (initial body weight) and at the end of the experiment (terminal body weight). To estimate liver volume, Archimedes' principle was used to obtain the independent volumes of all rats' livers. This principle works by estimating the volume of the liver by inserting the fixed liver organ that was extracted into the 100 ml graduated beaker, half-filled with normal saline, with measurements of displaced volumes taken.

### **Laboratory procedure**

All the rats were fed with standard rodent pellets and water *ad libitum* throughout the experimental period within polycarbonate cages. The drugs (paracetamol and silymarin milk thistle) were all dissolved in water for injection and given in varying doses as per the weights and dosages for each group. Administration of these drugs was via the oral route using gastric gavage. The animals were handled solely by the principal investigator and a certified animal technician for purposes of drug administration and daily weighing.

At the end of the 21 days, the rats were left for 12 hours after the last drug administration before being sacrificed. They were anesthetized by being put in a jar filled with concentrated chloroform. They were mounted on a mounting board in supine position with an incision from the sternal angle to the pubis symphysis. They were then sacrificed and liver tissues harvested for measurements of morphological parameters such as volume, width and length.

### **Data Analysis**

The data were entered into an Excel sheet and analyzed using SPSS (26) Chicago, Illinois. Gross morphological data such as volume, weight, length and width of the liver were analyzed descriptively using the mean and the standard error of the mean. One-way ANOVA analysis of variance was used to test the mean groups and a post hoc test was used to test the difference between the mean groups. A  $p \leq 0.05$  was found to have statistical significance at a 95% confidence interval.

### **Morphological restorative effects of different doses of silymarin milk thistle on paracetamol-induced hepatotoxicity**

The mean volume, width, length and weight of the liver of the control groups were compared to the experimental groups that received high, medium and low dose of silymarin milk thistle. The terminal body weights of the experimental groups were also compared to the control groups to illustrate body weight restoration after administration of varying doses of silymarin milk thistle.

There was a significant ( $p \leq 0.0001$ ) reduction in the mean length, weight, width and volume of the liver in the positive control group as compared to the negative control group. A One-way ANOVA was used to test the significance and  $p \leq 0.05$  at 95% confidence interval was found to be significant (Table 1).

There was a significant ( $p \leq 0.0001$ ) increase in the mean of all liver parameters of volume, width, length and weight in the high dose group as compared to the positive control group. All the liver weights and gross morphological parameters of the low dose group and medium dose group were not statistically ( $P \leq 1.000$ ) significant (Table 2).

**Ethical considerations:** The ethical approval to carry out the study was sought from the University of Eastern Africa, Baraton-Kenya, number UEAB/ISERC/11/01/2023. Licensed from the National Commission for Science, Technology and Innovation (NACOSTI), license number: NACOSTI/P/23/23588. All protocols for handling and humane sacrificing of animals were adhered to throughout the entire study period.

## **RESULTS**

There was a significant ( $p \leq 0.0001$ ) reduction in the mean of all liver parameters (length, width, weight and volume) in the low dose and medium dose groups as compared to the negative control group. There was no significant difference ( $p \leq 1.000$ ) in the liver morphologic parameters of the high dose group as compared to the negative control group (Table 3).

### **Terminal body weight of the adult albino rats**

The body weight of the albino rats was taken at the beginning and at the end of the study. The terminal body weight was the one that was found to be of statistical significance. There was reduction in the terminal mean body weight of the rats in the positive control group, the low dose silymarin group and the medium dose silymarin group respectively as compared to the negative control group with a significant ( $p \leq 0.0001$ ) increase in the liver weights in the high dose silymarin group (Figure 1).

Table 1: Morphological changes in paracetamol induced hepatotoxicity

Variable per groups	Volume of the liver (ml) Mean ±SEM	Width of the liver (mm) Mean ±SEM	Length of the liver (mm) Mean ±SEM	Weight of the liver (g) Mean ±SEM
Negative Control (water + feeds)	11.76 ± 0.04	41.14 ± 0.23	64.61 ± 0.19	11.04 ± 0.11
Positive control (750mg/kgbw of paracetamol)	8.88 ± 0.11	35.50 ± 0.19	50.97 ± 0.10	8.41 ± 0.09
	<b>P ≤ 0.0001</b>	<b>P ≤ 0.0001</b>	<b>P ≤ 0.0001</b>	<b>P ≤ 0.0001</b>

Table 2: Liver morphological changes in paracetamol induced hepatotoxicity following administration of different doses of silymarin milk thistle and positive control

Variable per groups	Volume of the liver Mean ±SEM	Width of the liver Mean ±SEM	Length of the liver Mean ±SEM	Weight of the liver Mean ±SEM
Positive control (750mg/kg/bwt of paracetamol)	8.88 ± 0.11 <b>P ≤ 0.0001</b>	35.50 ± 0.19 <b>P ≤ 0.0001</b>	50.97 ± 0.10 <b>P ≤ 0.0001</b>	8.41 ± 0.09 <b>P ≤ 0.0001</b>
High dose (600 mg/kgbw of silymarin)	11.23 ± 0.07 <b>P ≤ 0.0001</b>	40.35 ± 0.10 <b>P ≤ 0.0001</b>	62.48 ± 0.20 <b>P ≤ 0.0001</b>	10.87 ± 0.10 <b>P ≤ 0.0001</b>
Medium dose (400 mg/kgbw of silymarin)	8.62 ± 0.18 <b>P ≤ 1.000</b>	35.67 ± 0.22 <b>P ≤ 1.000</b>	50.95 ± 0.13 <b>P ≤ 1.000</b>	8.61 ± 0.25 <b>P ≤ 1.000</b>
Low dose (200 mg/kgbw of silymarin)	8.76 ± 0.19 <b>P ≤ 1.000</b>	35.59 ± 0.19 <b>P ≤ 1.000</b>	50.59 ± 0.27 <b>P ≤ 1.000</b>	8.35 ± 0.04 <b>P ≤ 1.000</b>

Key: SEM- standard error of mean. Mg/kgbw -milligrams kilo body weight, Volume measured in milliliters (ml), width and length (mm), weight (g)

Table 1: Liver morphological changes in paracetamol induced hepatotoxicity following administration of different doses of silymarin milk thistle and negative control

Variable per groups	Volume of the liver Mean ±SEM	Width of the liver Mean ±SEM	Length of the liver Mean ±SEM	Weight of the liver Mean ±SEM
Negative control (water + feeds)	11.76 ± 0.04 <b>P ≤ 0.0001</b>	41.14 ± 0.23 <b>P ≤ 0.0001</b>	64.61 ± 0.19 <b>P ≤ 0.0001</b>	11.04 ± 0.11 <b>P ≤ 0.0001</b>
High dose (600 mg/kgbw of silymarin)	11.23 ± 0.07 <b>P ≤ 1.000</b>	40.35 ± 0.10 <b>P ≤ 1.000</b>	62.48 ± 0.20 <b>P ≤ 1.000</b>	10.87 ± 0.10 <b>P ≤ 1.000</b>
Medium dose (400 mg/kgbw of silymarin)	8.62 ± 0.18 <b>P ≤ 0.0001</b>	35.67 ± 0.22 <b>P ≤ 0.0001</b>	50.95 ± 0.13 <b>P ≤ 0.0001</b>	8.61 ± 0.25 <b>P ≤ 0.0001</b>
Low dose (200 mg/kgbw of silymarin)	8.76 ± 0.19 <b>P ≤ 0.0001</b>	35.59 ± 0.19 <b>P ≤ 0.0001</b>	50.59 ± 0.27 <b>P ≤ 0.0001</b>	8.35 ± 0.04 <b>P ≤ 0.0001</b>

Key: SEM- standard error of mean. Mg/kgbw -milligrams kilo body weight. Volume measured in milliliters (ml), width and length (mm), weight (g)

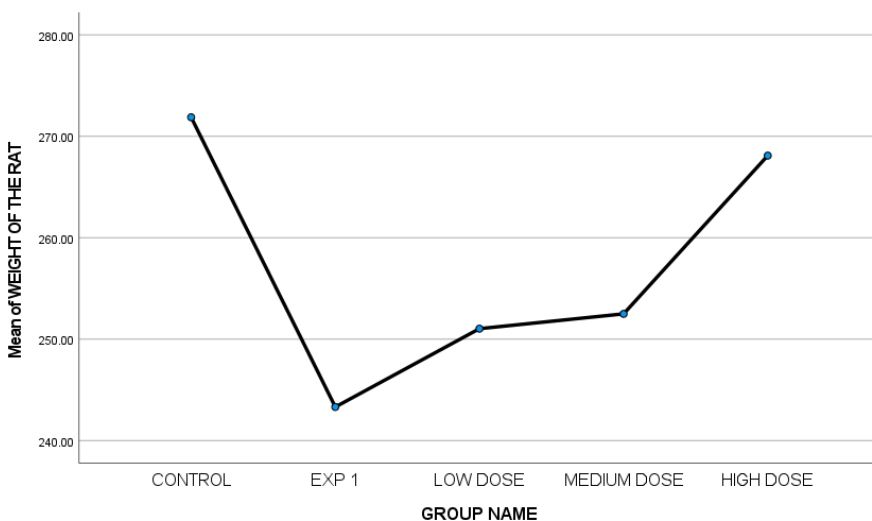


Figure 1: Line graph showing the mean terminal body weight of the control group compared the experimental groups. EXP1- positive control group, CONTROL- Negative control group

## DISCUSSION

Silymarin milk thistle an edible herb, is believed to have antioxidant, radical scavenging and regulation of glutathione levels properties. It has been used over time in treating various conditions, including stomach upset, liver and kidney problems; however, its pharmacokinetics and pharmacodynamics have not been well documented. In this study, different doses of silymarin milk thistle (high dose of SIL-600 mg/kbwt, medium dose of SIL-400 mg/kbwt, low dose of SIL-200 mg/kbwt) were administered to the experimental group and there was a significant improvement in liver morphological parameters of weight, volume, width and length as compared to the positive control group (Tables 1, 2, & 3). The high dose SIL group showed that there was marked restoration of these parameters as compared to the low dose SIL and medium dose SIL groups. This might have been due to silymarin improving the glutathione levels in the blood and the liver counteracting the effects on paracetamol toxicity, hence lowering the effects of NAPQI. These changes may also be due to the reduction in superoxide anion levels in the bloodstream, causing improvement and restoration of these parameters as compared to those of the negative control. From literature

reviewed, silymarin milk thistle was found to potentiate the restoration of relative liver weights, glutathione levels and plasma lipid levels in metabolic syndromes and nonalcoholic fatty liver disease (Tajmohammadi *et al.*, 2018; Abenavoli *et al.*, 2011). Khazaei *et al.*, also recorded that silymarin milk thistle led to a reduction in the weights of spleen in laboratory animals, hence concurring with the current study (Khazaei *et al.*, 2022).

From literature reviewed, it was found out that post-administration of silymarin milk thistle on carbon tetrachloride induced liver fibrosis, liver morphological parameters were greatly improved, leading to resolution of liver fibrosis (Tsai *et al.*, 2008), hence concurring with this present study that demonstrates restorative effects of silymarin milk thistle on paracetamol-induced hepatotoxicity. Upon administration of silymarin milk thistle to diazinon-treated rats, it was found that liver volume and weight increased significantly as compared to those that never received silymarin, concurring with this study that liver volume and weight were positively impacted by the administration of silymarin milk thistle (Masoumi *et al.*, 2020).

A study by Cetinkunar *et al.*, 2015 on the effects of silymarin on liver regeneration after partial hepatectomy, found that silymarin was able to speed up the rate of liver regeneration, thereby increasing the relative liver weights. Silymarin was also found to bring about a restoration of body weights and an increase in kidney weights in drug-induced nephrotoxicity, either from acetaminophen, chloroform, gentamycin, or even cisplatin (Mashayekhi, 2012; Shahbazi *et al.*, 2012).

Paracetamol toxicity has been associated with a reduction in the body weight of the animals (Figure 1). This could be due to the injurious effects of paracetamol on the body organs, specifically the liver and kidney. The oxidative stress and free radical production cause hepatocellular and nephro-cellular damage that triggers inflammatory mediators that cause cell damage. These toxic levels would lead to oxidative stresses that would likely affect the normal physiological functions of the body, leading to a general decline in body metabolism and functioning, leading to a decline in terminal body weights (Nuriye Ezgi Bektur, 2016).

A study done on pigs to determine the effects of silymarin milk thistle on animal weight and organ weight showed that there was an increase in the average weight of the liver and kidneys, though there was a reduction in the weights of the heart and the lungs. There was also an increase in the terminal weights of the pigs given silymarin milk thistle. This could possibly be an indication that silymarin has a positive impact on the cardiorespiratory as well as restorative properties on the liver and kidneys (Kropiwiiec-Domańska *et al.*, 2022).

A study by Khazaei *et al.*, on the effects of silymarin milk thistle on some laboratory animals found out that on administration of this medicinal plant, there was an increase in body weight and carcass components in Japanese quail (Khazaei *et al.*, 2022). Kumar

Das & Vasudevan, also recorded that silymarin milk thistle had a protective effect against weight loss in ethanol-induced oxidative stress in the liver (Subir Kumar Das, 2006). In a study on the anti-aflatoxin effects of silymarin milk thistle on broilers, it was noted that on administration of silymarin milk thistle, there was an increase in weight gain in the animals (Alhidary *et al.*, 2017). This improvement in the body weights of the animals could be due to the phytochemical silymarin countering the hazardous effects of various components of toxic drugs on the body and restoring the normal physiology of the organs. These studies imply that silymarin has restorative effects on the body weights of various animals, thus concurring with this current study.

## **CONCLUSIONS**

Silymarin milk thistle has been found to have restorative effects on liver tissue at higher doses, even though its pharmacodynamics and pharmacokinetics in humans have not been confirmed. It was further recorded that silymarin milk thistle had an impact on improving the body weight of the albino rats that had paracetamol-induced hepatotoxicity.

## **Strengths and limitations of the study**

No deaths among the study subjects were recorded during the entire experimental process. One limitation encountered was the expensive reagents used in the experimental process.

## **Acknowledgements**

We are thankful to Maseno University, Department of Human Anatomy and Department of Biomedical Sciences, where the acquisition and rearing of the albino rats were done. I am grateful to my co-authors for their constant input towards the development of this manuscript.

## **Conflict of interests**

None declared.

## **Source of funding**

This article received no funding

## REFERENCES

1. Abenavoli, L., Aviello, G., Capasso, R., Milic, N., & Capasso, F. (2011). Milk thistle for treatment of nonalcoholic fatty liver disease.
2. Arifin, M. Z. (2017). Sample Size Calculation in Animal Studies Using Resource Equation Approach Malaysian. *Journal of Medical Sciences.*, 24(5), 101–105.
3. Bektur, N. E., Sahin, E., Baycu, C., & Unver, G. (2016). Protective effects of silymarin against acetaminophen-induced hepatotoxicity and nephrotoxicity in mice. *Toxicology and Industrial Health*, 32(4), 589-600.
4. Cetinkunar, S., Tokgoz, S., Bilgin, B. C., Erdem, H., Aktimur, R., Can, S., ... & Polat, Y. (2015). The effect of silymarin on hepatic regeneration after partial hepatectomy: is silymarin effective in hepatic regeneration? *International journal of clinical and experimental medicine*, 8(2), 2578.
5. Eriksson, L. S., Broome, U., Kalin, M., & Lindholm, M. (1992). Hepatotoxicity due to repeated intake of low doses of paracetamol. *Journal of internal medicine*, 231(5), 567-570.
6. Fraschini, F., Demartini, G., & Esposti, D. (2002). Pharmacology of silymarin. *Clinical drug investigation*, 22, 51-65.
7. IA Alhidary, Z. R. R. K. M. Tahir. (2017). Anti-aflatoxin activities of milk thistle (*Silybum marianum*) in broiler. *World's Poultry Science Journal*, 73(3), 559–566.
8. Jacobs, B. P., Dennehy, C., Ramirez, G., Sapp, J., & Lawrence, V. A. (2002). Milk thistle for the treatment of liver disease: a systematic review and meta-analysis. *The American journal of medicine*, 113(6), 506-515.
9. Janos Feher, G. Lengyel. (2012). Silymarin in the prevention and treatment of liver diseases and primary liver cancer. *Current Pharmaceutical Biotechnology*. 13(1), 210–217.
10. Jóźwiak-Bebenista, M., & Nowak, J. Z. (2014). Paracetamol: mechanism of action, applications and safety concern. *Acta poloniae pharmaceutica*, 71(1), 11-23.
11. Khazaei, R., Seidavi, A., & Bouyeh, M. (2022). A review on the mechanisms of the effect of silymarin in milk thistle (*Silybum marianum*) on some laboratory animals. *Veterinary Medicine and Science*, 8(1), 289-301.
12. Kropiwięc-Domańska, K., Babicz, M., Kędzińska-Matysek, M., Szyndler-Nędzka, M., Skrzypczak, E., & Woliński, B. (2022). Effect of Milk Thistle (*Silybum marianum*) Supplementation on Pork Offal Quality. *Animals*, 12(12).  
<https://doi.org/10.3390/ani12121526>
13. Kurtovic, J., & Riordan, S. M. (2003). Paracetamol-induced hepatotoxicity at recommended dosage. *Journal of internal medicine*, 253(2), 240-243.
14. Majeed, S. K., Ramadhan, M. A., & Monther, W. (2013). Long-term toxicological effects of paracetamol in rats. *Iraqi Journal of Veterinary Sciences*, 27(1), 65-70
15. Masoumi, F. , Shariati, M. , & Mokhtari, M. (2020). Effects of *Silybum marianum* Aqueous Extract and L-carnitine on Stereological Changes in Diazinon-Treated Rat Liver. . *Jurnal Ilmu Ternak Dan Veteriner*, 25(2), 91–98.
16. Mohammad Mashayekhi. (2012). Renoprotective effect of silymarin on gentamicin-induced nephropathy. *African Journal of Pharmacy and Pharmacology*, 6(29).  
<https://doi.org/10.5897/ajpp12.628>
17. Pritchett, K. R., & Corning, B. F. (2004). Biology and medicine of rats. *Laboratory Animal Medicine and Management. International Veterinary Information Service. Ithaca NY.*
18. Shahbazi, F., Dashti-Khavidaki, S., Khalili, H., & Lessan-Pezeshki, M. (2012). Potential Renoprotective Effects of Silymarin Against Nephrotoxic Drugs: A Review of Literature. In *J Pharm Pharmaceut Sci (www.cspsCanada.org)* (Vol. 15, Issue 1). [www.cspsCanada.org](http://www.cspsCanada.org)



19. Stefan David, J. P. Hamilton. (2010). Drug-induced liver injury. *US Gastroenterology & Hepatology Review.*, 6, 73.
20. Subir Kumar Das, D. V. (2006). Protective effects of silymarin, a milk thistle (*Silybium marianum*) derivative on ethanol induced oxidative stress in the liver. *CSIR*.
21. Surai, P. F. (2015). Silymarin as a natural antioxidant: an overview of the current evidence and perspectives. *Antioxidants*, 4(1), 204-247.
22. Tajmohammadi, A., Razavi, B. M., & Hosseinzadeh, H. (2018). *Silybum marianum* (milk thistle) and its main constituent, silymarin, as a potential therapeutic plant in metabolic syndrome: A review. *Phytotherapy research*, 32(10), 1933-1949.
23. Tittarelli, R., Pellegrini, M., Scarpellini, M. G., Marinelli, E., Bruti, V., DI LUCA, N. M., ... & Zaami, S. (2017). Hepatotoxicity of paracetamol and related fatalities. *European Review for Medical and Pharmacological Sciences*, 21(1 Suppl), 95-101.
24. Tsai, J. H., Liu, J. Y., Wu, T. T., Ho, P. C., Huang, C. Y., Shyu, J. C., ... & Liu, Y. C. (2008). Effects of silymarin on the resolution of liver fibrosis induced by carbon tetrachloride in rats. *Journal of viral hepatitis*, 15(7), 508-514.
25. Vargas-Mendoza, N., Madrigal-Santillán, E., Morales-González, Á., Esquivel-Soto, J., Esquivel-Chirino, C., y González-Rubio, M. G. L., ... & Morales-González, J. A. (2014). Hepatoprotective effect of silymarin. *World journal of hepatology*, 6(3), 144.