



# ALTERATIONS IN HISTOMORPHOLOGY, BIOCHEMICAL PARAMETERS AND GROSS MORPHOMETRY IN LIVER OF ALBINO RATS FOLLOWING ADMINISTRATION OF RIFAMPICIN AND ISONIAZID

Hans Lwunza Libamila<sup>1</sup>, Geoffrey Arasa Ouno<sup>2</sup> and Rodgers Norman Demba<sup>3</sup>.

<sup>1</sup>Department of Human Anatomy, School of Medicine, Maseno University, Maseno, Kenya.

<sup>2</sup>Department of Medical Microbiology, School of Medicine, Maseno University, Kenya.

<sup>3</sup>Department of Medical Laboratory Science, School of Medicine, Maseno University, Kenya.

Corresponding Author: Hans Lwunza Libamila. Email: [hlibamila@mail.com](mailto:hlibamila@mail.com)

ORCID ID: <https://orcid.org/0000-0001-5400-7716>

## ABSTRACT

**Background:** Rifampicin (RIF) and Isoniazid (INH) are two main medicinal drugs used as first line regimen in the treatment of Tuberculosis. These drugs have shown to induce hepatotoxicity and alteration of liver parenchyma upon their administration. The aim of this study was to investigate the gross morphometric, histomorphological and biochemical effect of INH and RIF on the liver architecture. **Methods:** Adult albino rats with an average weight of between 150g to 250g were used in the study. A total of 12 rats were randomly assigned into 2 groups each group containing 6 rats. Group one was the control group (no intervention). Group two was the experimental group, given INH (50mg/kgbw) and RIF (50mg/kgbw). At the end of the experiment, after 21 days, the albino rats were sacrificed humanely, liver harvested, weighed and the gross parameters measured using a ruler and caliper. Blood samples were taken for liver serum biomarkers analysis. Thereafter, the livers were processed and stained with Haematoxylin and Eosin for histological examination. **Results:** There was a significant ( $p$  value  $< 0.0001$ ) decrease in gross morphometric measurements of the weight, length, width, thickness in experimental group. The three selected liver biochemical parameters (ALT, AST and ALP) were observed to be high above their normal ranges. The liver sections in positive control group showed deranged histomorphological features. **Conclusion:** co-administration of Rifampicin and Isoniazid can have effect on gross morphometric, histomorphology and liver biochemical parameters of the liver therefore, their administration should be done in caution.

**Keywords:** hepatotoxicity, morphometric, Isoniazid, Rifampicin, histomorphology

**DOI:** <https://dx.doi.org/10.4314/aja.v12i2.9>

## INTRODUCTION

Hepatotoxicity refers to as harm to the liver or disruption of hepatic function induced by exposure to xenobiotic such as alcohol, drugs, chlorinated solvents, food additives, peroxidized fatty acids, fungal toxins, environmental toxicants and radioactive isotopes (Gulati et al., 2018). The liver is the major organ for drug elimination and metabolism (Choijamts et al., 2018). Anti-tubercular drugs such as rifampicin (RIF) and isoniazid (INH) are among the drugs contributing to liver toxicity (Mathers *et al.*, 2015; Zeinab, 2012; Shah *et al.*, 2011)

Rifampicin (RIF) and Isoniazid (INH) are the two main drugs being used to treat Tuberculosis (TB) for 4-6 months (Zeinab, 2012). INH is an anti-mycobacterial drug which has been applied clinically for about 70 years and is still currently being used for TB treatment. It is a bactericide that prevents the mycolic acids formation in the cell wall of bacterial (Tayal et al., 2007). The ability to cause liver damage and even eventual hepatic failure during INH and RIF's management forms a major challenge (Li et al., 2015; Ghosh *et al.*, 2011; Kuwabar *et al.*,

2011). Despite of hepatotoxicity caused by these drugs, they are still first line regimen in the treatment of TB because of their high level of efficacy.

The duration of manifestation of liver toxicity vary between 1-25 weeks with an average of 12 weeks. Elevation of liver biomarkers has been reported to occur as early as first week and as late as 9<sup>th</sup> month (Arif et al., 2022). The level of liver toxicity is high in cases of other risk factors such: high alcohol consumption, HIV/AIDS (Sankar et al., 2015). Additionally, the liver is prone to several diseases including hepatitis, allergic

reactions, hepatic encephalopathy and non-alcoholic fatty liver disease among others (Gulati et al., 2018).

The aim of this study was to investigate the gross morphometric, histomorphological and biochemical effect of INH and RIF on the liver architecture. This will address the gap on the gross morphometric changes on the liver which is lacking in the available published literatures. The findings in the histomorphology and liver biochemical parameters will aid in confirmation of the gross morphometric changes.

## MATERIALS AND METHODS

### Experimental animals

Adult albino rats were bred in a condition which is microbiologically controlled for all the experimental and control groups. They were obtained from University of Nairobi. The albino rats were bred in cages which hold a maximum of 6 rats per cage. The rats were acclimatized for 1 week in an animal house (26±2°C) with 12h light and dark cycles in the animal house in zoology department, Maseno University. Animal feeds were obtained from Unga Feeds in Kisumu Town. The animals were fed with standard rodent pellets and water provided ad libitum. The albino rats were fed each morning at 0800 hours in their spacious polycarbonate cages. Animal ethical approval was obtained from Institutional Scientific Ethical Review Committee (ISERC) of University of Eastern Africa Baraton. The study research license was obtained from National Commission for Science Technology and Innovation (NACOSTI).

### Inclusion criteria

- All healthy albino rats in the cage
- Animals with average weight of 150-250g were included in this study.
- Animals between 6-8 weeks of age

### Exclusion criteria:

Sick animals in the cage

### Animal ethics

All procedures were performed in line with the Guide for the Care and Use of Laboratory Animals (Albus, 2012).

### Drugs and chemicals

They were obtained from Yala sub-county Referral Hospital. (Batch No. NRT2103A). Rifampicin and Isoniazid were administered at a dosage of 50mg/kg/day, which was converted to animal equivalent dosage and administered for 21 days. (Sue et al., 2021; Rana et al., 2006)

### Grouping of the animals and drug administration.

A total of 12 rats were randomly assigned into 2 groups each group containing 6 rats. Group one was the control group (no intervention), was given food and water only. Group two was the experimental group, given INH (50mg/kgbw) and RIF (50mg/kgbw) orally. At the end of the experiment, after 21 days, the albino rats were sacrificed humanely, and liver harvested.

### Morphometric measurement

After 21 days of experimentation, the animals were sacrificed by use of chloroform in jar, the liver morphometric measurements, which includes the weight, length, width and thickness were taken using a ruler and

caliper. The liver was then stored for histological examinations.

### **Biochemical analysis**

Blood samples were obtained from the posterior venacava. The blood samples were centrifuged at 3000rpm for 10 minutes, sera collected and analyzed using ELISA kits.

### **Microscopic & Photographic Examination of Histological Section**

**H&E Staining.** The right lobe of each liver (5 mm × 5 mm × 3 mm) was fixed with 4% formaldehyde solution and embedded in paraffin. Next, tissue slices were prepared and stained with hematoxylin (Servicebio, China) for 5 mins, differentiated by exposure to hydrochloric acid alcohol solution for 20 s, and then exposed to a weak ammonia solution (Sinopharm, Ecuador, 100021600) for 20 s. After staining with eosin (Solarbio, Turkey; G1100), the slices were dehydrated and made transparent. Finally, the pathological characteristics of the liver tissues were observed under a microscope (Olympus BP). The microscopic examination of the tissue sections prepared from the samples prepared for the study was carried out using an imaging light microscope and

then photographs of the sections were taken using a compound microscope equipped with a Novel type camera.

### **Statistical analysis**

The data was entered into excel sheet and then analysis done through SPSS version 25 (IBM). The results are expressed as a mean value ± standard error of mean (SEM). Student's t test was used to analyze differences between the two groups. Significance levels was P value less than or equal to 0.05 ( $p \leq 0.05$ ) at 95% confidence level.

### **Ethical approval**

The proposal was initially presented and cleared by the School of Medicine, and then the School of Graduate Studies (SGS), Maseno University (SGS=MSC/SM/00023/020). Animal ethical approval was obtained from Institutional Scientific Ethical Review Committee (ISERC) of University of Eastern Africa Baraton (UEAB/ISERC/01/09/2023). The study research license was obtained from National Commission for Science Technology and Innovation (NACOSTI-P/23/23412).

## **RESULTS**

### **Gross morphometric findings.**

The liver gross morphometric measurements entail weight, length, width and thickness. There was no gross anatomical changes observed on the liver between the control and experimental groups. The liver was observed to have four lobes, dark brown in colour with a smooth texture (figure 1).



Figure 1. Gross appearance of the liver showing four lobes and dark brown in colour.

### Mean liver weight in comparison with mean final body weight between experimental and control groups.

A decrease ( $184.78 \pm .78$ ) in mean final body weight was observed in experimental group (RIIH 50kg/kgbw), compared to  $245.39 \pm .57$  in control group (Food+water).

Table 1. Gross morphometric measurements between control and experimental groups.

Gross parameters	ANIMAL GROUPS		Sig.
	control group (Food+water)	Experimental group (RIIH 50mg/Kg/bwt)	
MFBW (grams)	$245.39 \pm .57$	$184.78 \pm .78^{**}$	0.0001
MLW (grams)	$11.86 \pm .20$	$9.197 \pm .26^{**}$	0.0001
Length (cm)	$57.00 \pm .53$	$44.90 \pm .40^{**}$	0.0001
Width (cm)	$45.20 \pm .33$	$36.31 \pm .19^{**}$	0.0001
Thickness (cm)	$0.53 \pm .02$	$0.35 \pm .01^{**}$	0.0001
Lobes	6	6	

All values are expressed and presented as the mean  $\pm$  the standard error of the mean (SEM); n=6. Data analyzed by dependent t-test. Asterisks\*\* represents significant ( $p < 0.0001$ ), RIIH-Rifampicin and Isoniazid Induced Hepatotoxicity, MFBW=Mean final body weight, MLW= Mean liver weight.

### Comparative mean liver length, width and thickness between positive and negative control

A decrease in the mean of liver length, width and thickness was observed in experimental group compared to control group (Food+water). The length of  $44.90 \pm .40$ , width of  $36.31 \pm .19$  and thickness of  $0.53 \pm .02$  in experimental (RIIH 50kg/kgbw) group while length of  $57.00 \pm .53$ , width of  $45.20 \pm .33$  and thickness of  $0.35 \pm .01$  in control group. There was statistically significant difference ( $p \leq 0.0001$ ) in experimental group as shown in Table 1.

### Liver biochemical parameters changes.

This current study selected three (ALT, AST and ALP) liver biochemical indicators to assess the hepatotoxic effect of Isoniazid and Rifampicin.

All the three biochemical parameters; ALP, AST and ALT in control group were within the normal ranges with their means at  $24.17 \pm 1.1$ ,  $60.43 \pm 3.4$  and  $74.67 \pm 5.7$  respectively. In the experimental (RIIH

Similarly, there was a decrease ( $9.197 \pm .26$ ) in mean liver weight in experimental group as compared to negative control ( $11.86 \pm .20$  respectively). A statistically significant difference ( $p \leq 0.0001$ ) between experimental groups as seen in Table 1.

50kg/kgbw) group, it was observed increase in ALT ( $100.4 \pm 4.7$ ), AST ( $116.7 \pm 8.6$ ) and ALP ( $131.1 \pm 6.3$ ) above the normal ranges. There was statistically significant difference ( $p \leq 0.0001^*$ ) in experimental group as shown in Table 2.

Liver Biochemical Parameters	control group (Food+water)	experimental group (RIIH 50mg/Kg/bwt)	sig.
ALT ( $\mu$ L)	$24.17 \pm 1.1$	$100.4 \pm 4.7$	0.0001**
AST ( $\mu$ L)	$60.43 \pm 3.4$	$116.7 \pm 8.6$	0.0001**
ALP ( $\mu$ L)	$74.67 \pm 5.7$	$131.1 \pm 6.3$	0.0001**

All values are expressed and presented as the mean  $\pm$  the standard error of the mean (SEM); n=6. Data analyzed by dependent t-test. Asterisks\*\* represents significant ( $p < 0.0001$ ), RIIH-Rifampicin and Isoniazid Induced Hepatotoxicity, MFBW=Mean final body weight, MLW= Mean liver weight. AST-Aspartate Transaminase, ALT- Alanine Transaminase, ALP- Alkaline Phosphatase.

### Histomorphological findings.

A normal liver histomorphological features was observed in the control group (food and water ad-libitum), where the central vein, hepatocytes, hepatic triad and capillary sinusoid appeared normal as shown in Figure 2. This was different from the experimental (RIIH 50kg/kgbw) group that showed deranged histomorphological features, where areas of necrosis, dilatation of sinusoidal capillaries, disrupted central vein and inflamed Kupffer cells was observed as shown in figure 3.

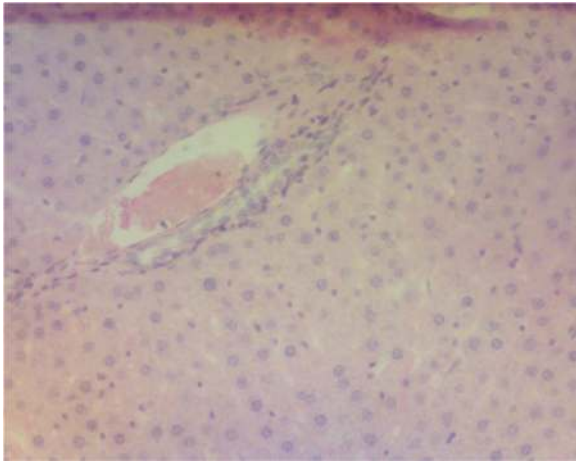


Figure 2. Liver sections from control group (food & water), showing normal histological findings; normal central vein, hepatocytes, sinusoid and Kupffer cells (X100, H&E)

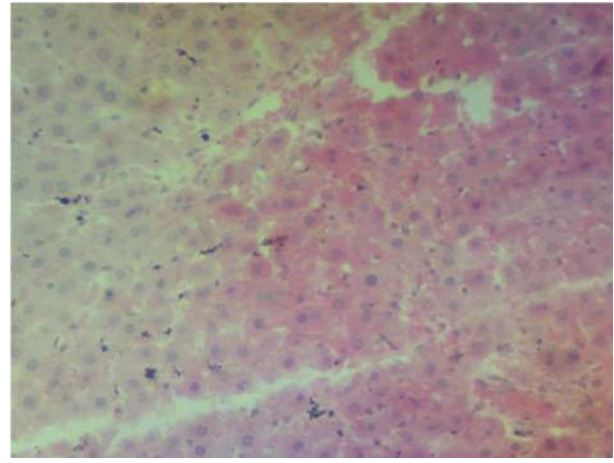


Figure 3; Liver sections from experimental group (RIIH 50mg/kgbw) showing disrupted central vein, dilated sinusoid and necrosis. (X100, H&E)

## DISCUSSION

### Gross morphometric changes

Gross morphometric measurements of the liver include weight, length, width and thickness. The measurements are vital in determining the gross changes on the liver between control and experimental groups (Buabeid et al., 2022).

In this current study, the liver gross appearance was dark brown in colour with a smooth texture after administration of rifampicin and isoniazid. There were no obvious gross anatomical changes observed between control and experimental group. These findings are in line with (Humayun et al., 2017) who also observed similar features.

However, Shabbir *et al.*, (2020) observed a significant ( $p$  value  $< 0.0001$ ) decrease in liver weight and mean terminal body weight have been recorded when antitubercular drugs were administered among albino rats (Shabbir et al., 2020). The observation by Shabbir *et al.*, (2020) was consistent with the present study findings which recorded a decrease ( $184.78 \pm .78$ ) in mean final body weight in experimental (RIIH 50kg/kgbw) group, compared to  $245.39 \pm .57$  in control (food and water ad-libitum) group. The mean liver weight was recorded at ( $9.197 \pm .26$ ) in experimental (RIIH 50kg/kgbw) group and  $11.86 \pm .20$  in control

(food and water ad-libitum) group. These findings are also similar to Nawar *et al.*, (2006) and Oloo *et al.*, 2021.

The current study also recorded significant ( $p$  value  $< 0.0001$ ) decrease in the length, width and thickness of the liver. Other studies also observed significant ( $p \leq 0.05$ ) decrease in the gross morphometric measurements, after administration of paracetamol in albino rats. (Rono K Walter, 2020; Mahmood et al., 2014 and Girish *et al.*, 2009). These derangements in the length, width, thickness of the liver and terminal body weight could be attributed to hepatotoxic injury to liver parenchyma induced by rifampicin and isoniazid.

Contrary to this, a study by Jaber et al., (2018) on morphometric effect of Tegretol on liver of albino mice shows no significant ( $p > 0.05$ ) difference between control and experimental group (Jaber *et al.*, 2018). This difference in findings could be attributed to the duration of the experiment which was done for thirty days.

### Changes in liver bio-chemical parameters (ALT, AST and ALP)

The three (ALT, AST and ALP) selected liver biochemical parameters were determined to assess the effect of Rifampicin and Isoniazid on liver in adult albino rats. In cases where

liver is damaged, these enzymes are usually released into the blood stream (Buabeid et al., 2022). In the present study, all the three biochemical parameters; ALP, AST and ALT in control (water and food ad-libitum) group were within the normal ranges with their means at  $24.17 \pm 1.1$ ,  $60.43 \pm 3.4$  and  $74.67 \pm 5.7$  respectively.

Contrary to this, the three parameters showed significant ( $p$  value  $< 0.0001$ ) increase above their normal ranges in experimental (RIIH 50kg/kgbw) group compared to control group with their means at  $100.4 \pm 4.7$ ,  $116.7 \pm 8.6$  and  $131.1 \pm 6.3$  respectively. Other studies observed similar findings when Isoniazid and Rifampicin were administered in mice (Xi et al., 2011; Parameswari et al., 2012; Sankar et al., 2015; Oloo et al/2021; Usmani et al., 2016;). The increase in enzyme activities might be attributed to rise in liver functionality induced by the drugs biochemical parameters which have toxic properties that induce injury to liver parenchyma.

### Histomorphological findings

Histomorphological features of the liver include; central vein, capillary sinusoids, portal triad, lobules and Kupffer cells. The features are important in assessing injury to the liver histo-architecture (Buabeid et al., 2022).

The present study observed normal liver histomorphological features in control group (food and water ad-libitum). This observation was different from the experimental group (isoniazid and rifampicin) that showed deranged features where areas of necrosis, dilatation of sinusoidal capillaries, disrupted central vein and inflamed Kupffer cells was observed. These observations are in harmony with other studies that recorded deranged

histological features on liver when they introduced Isoniazid and Rifampicin among albino rats (Salah & Abdoul, 2021; Dubiwak et al., 2021; Zodape & Bhise, 2018). These findings are attributed to necrosis caused by rifampicin and isoniazid which induces oxidative stress leading to injury to hepatocytes.

Contradicting findings were observed when 40mg/kg of paracetamol was administered orally for twenty-eight days. There were no derangement in histomorphology of the liver sections. These changes were attributed to low dose of paracetamol administered. (Oloo et al., 2020).

### CONCLUSION

In conclusion, the results obtained indicate that co-administration of Isoniazid and Rifampicin may induce alteration in gross morphometric measurements, histomorphology and biochemical parameters on the liver. This is due to hepatotoxic properties of the two drugs which causes injury to the liver parenchyma.

### RECOMMENDATION

The study recommends that co-administration of Isoniazid and Rifampicin over a long period of time should be done cautiously, with serial monitoring of the stated liver biochemical parameters so as to assess for development of hepatotoxicity. Furthermore, studies should be done on adjuvants or polyherbal formulations to be done in human patients which would be administered concurrently with Isoniazid and Rifampicin to prevent injury to the liver.

### CONFLICT OF INTEREST

There is no conflict of interest regarding the publication of this article.

### REFERENCES

1. Albus, U. (2012). Guide for the care and use of laboratory animals (8th edn). In: SAGE Publications Sage UK: London, England.
2. Arif, I. S., Raof, I. B., Luaibi, H. H., & Ibraheem, S. K. (2022). Role of miRNA in drug-

- induced hepatic injury. *AJPS*, 1.
3. Buabeid, M., Arafa, E.-S., Rani, T., Ahmad, F., Ahmed, H., Hassan, W., & Murtaza, G. (2022). Effects of Solanum lycopersicum L.(tomato) against isoniazid and rifampicin induced hepatotoxicity in wistar albino rats. *Brazilian Journal of Biology*, 84.
  4. Chojjamts, G., Batsyren, C., Otgontyr, Narantsetseg, D., Erdenesuvd, Enkhbayar, Pyrevbazar, Oyundelger, Tungalag, Erdenetsetseg, Enkhtsetseg, Sarantuya, & Palaniyamma, a. (2018). Role of Liv . 52 DS Tablets as a Hepatoprotective Agent in Tuberculosis Patients Receiving Antitubercular Drugs : A Double Blind Placebo Controlled Study.
  5. Ghosh K, Ghosh K, Chowdhury JR. Tuberculosis and female reproductive health. *Journal of Postgraduate Medicine* 2011; 57:307.
  6. Girish, C., Chandra, B., Jayanthi, S., & Rao, K. R. (2009). Hepatoprotective activity of picroliv , curcumin and ellagic acid compared to silymarin on paracetamol induced liver toxicity in mice, *Fundamental & Clinical Pharmacology*, 23(6), 735–745.
  7. Gulati, K., Reshi, M., Rai, N., & Ray, A. (2018). Hepatotoxicity: Its mechanisms, experimental evaluation and protective strategies. *Am J Pharmacol*. 2018; 1 (1), 1004.
  8. Humayun, F., Tahir, M., & Lone, K. P. (2017). HISTOLOGIC EFFECTS OF ISONIAZID ON THE LIVER OF ALBINO MICE. *Khyber Medical University Journal*, 9(2).
  9. Jaber, N. R., & Al-Bakri, N. A. (2018). Tegretol (Carbamazepine) Effect on the Morphometric Assay of Liver in Female White Mice (Mus musculus). *Ibn AL-Haitham Journal For Pure and Applied Sciences*, 31(3), 1–9. <https://doi.org/10.30526/31.3.1997>
  10. Kuwabara K. Anti-tuberculosis chemotherapy and management of adverse reactions, *Nihon Rinsho* 2011; 69:1389-93
  11. Li, S., Tan, H.-Y., Wang, N., Zhang, Z.-J., Lao, L., Wong, C.-W., & Feng, Y. (2015). The role of oxidative stress and antioxidants in liver diseases. *International journal of molecular sciences*, 16(11), 26087-26124.
  12. Mahmood, N. D., Mamat, S. S., Kamisan, F. H., Yahya, F., Kamarolzaman, M. F. F., Nasir, N., ...& Zakaria, Z. A. (2014). Amelioration of Paracetamol-Induced Hepatotoxicity in Rat by the Administration of Methanol Extract of Muntingia calabura L. Leaves. *BioMedical Research International*, 2014, 695678.
  13. Mathers CD, Stevens GA, Boerma T, et al. Causes of international increases in older age life expectancy. *Lancet* 2015; 9967:540-8
  14. Muna Salah Rashid, & Israa Abdoul munem. (2021). Histological effect of isoniazid drug in the kidney and liver tissues of albino mice Mus Musuclus. *Tikrit Journal of Pure Science*, 26(5), 27–33. <https://doi.org/10.25130/tjps.v26i5.173>
  15. Oloo Q.P, Mburu D, Ngugi M. (2021). Effects of paracetamol on the liver and kidney functions of a rat model following prolonged alcohol administration.
  16. Parameswari, S. A., Chetty, C. M., & Chandrasekhar, K. B. (2013). Hepatoprotective activity of Ficus religiosa leaves against isoniazid+rifampicin and paracetamol induced hepatotoxicity. *Pharmacognosy research*, 5, 271–276. <https://doi.org/10.4103/0974-8490.118828>
  17. Rana, S. V., Pal, R., Vaiphie, K., & Singh, K. (2006). Effect of different oral doses of isoniazid rifampicin in rats. *Molecular and cellular biochemistry*, 289, 39–47.
  18. Rono .k walter, K. j. K., Kibe G. Kafanya, Thuo Rueben, Kanyoni j.Mwangi (2020). Histological and Morphometric Effects of Liv 52 on Acetaminophen Induced Liver Toxicity in Adult Albino Rats *IOSR Journal Of Pharmacy And Biological Sciences (IOSR-JPBS)*, 14, 44-51 [www.Iosrjournals.Org](http://www.Iosrjournals.Org)
  19. Shah NS, Richardson J, Moodley P, et al. Increasing drug resistance in extensively drug-

- resistant tuberculosis. *South African Emerging Infectious Diseases* 2011; 17:510-3.
20. Su, Q., Kuang, W., Hao, W., Liang, J., Wu, L., Tang, C., Wang, Y., & Liu, T. (2021). Antituberculosis Drugs (Rifampicin and Isoniazid) Induce Liver Injury by Regulating NLRP3 Inflammasomes. *Mediators of inflammation*, 2021, 8086253. <https://doi.org/10.1155/2021/8086253>
  21. Sankar, M., Rajkumar, J., & Sridhar, D. (2015). Hepatoprotective activity of heptoplus on isoniazid and rifampicin induced liver damage in rats. *Indian journal of pharmaceutical sciences*, 77(5), 556.
  22. Shabbir, M., Afsar, T., Razak, S., Almajwal, A., & Khan, M. R. (2020). Phytochemical analysis and Evaluation of hepatoprotective effect of *Maytenus royleanus* leaves extract against anti-tuberculosis drug induced liver injury in mice. *Lipids in health and disease*, 19, 1-15.
  23. Tayal, V., Kalra, B. S., Agarwal, S., Khurana, N., & Gupta, U. (2007). Hepatoprotective effect of tocopherol against isoniazid and rifampicin induced hepatotoxicity in albino rabbits.
  24. Zeinab, Y. (2012). Biochemical evaluation of some natural products against toxicity induced by antitubercular in rats. *NY Sci J*, 5, 69-80.