



## STUDY OF VARIATIONS IN THE BRONCHO-ARTERIAL PEDICLES OF THE UPPER RIGHT LUNG LOBE

MAR Ndeye Bigué<sup>1</sup>, YACOUBA GARBA Karim<sup>2</sup>, SEYE Cheikh<sup>3</sup>, SECK Issa Dior<sup>2</sup>, WADE Racky<sup>2</sup>, NDIAYE Mamadou<sup>2</sup>, TIREIRA Daouda<sup>2</sup>, THIAM Sokhna Astou<sup>2</sup>, GAYE Magaye, NDIAYE Aïnina<sup>2</sup>, MANYACKA MA NYEMB Philippe<sup>4</sup>, NDOYE Jean Marc Ndiaga<sup>2</sup>, DIOP Mamadou<sup>2</sup>, NDIAYE Abdoulaye<sup>2</sup>, NDIAYE Assane<sup>5, 6</sup>.

<sup>1</sup>UFR of Health Sciences. Iba Der Thiam University, Thiès, Senegal

<sup>2</sup>Laboratory of Anatomy and Organogenesis. Faculty of Medicine, Pharmacy and Odontology UCAD, Dakar, Senegal

<sup>3</sup>UFR of Health Sciences, Alioune DIOP University, Bambey, Senegal

<sup>4</sup>UFR of health sciences. Gaston BERGER University of Saint-Louis, Senegal

<sup>5</sup>UFR of health sciences. Assane Seck University of Ziguinchor- Senegal

<sup>6</sup>Cardiovascular Surgery FANN Hospital in Dakar Senegal

Correspondence to: Ndeye Bigué MAR. Email: [biguemarmbaye@yahoo.fr](mailto:biguemarmbaye@yahoo.fr)

### ABSTRACT

Bronchial distribution and functional arterial vascularization of the upper lobe of the right lung are subject to many anatomical variations. The control of these variations is essential for endoscopic and angiographic examinations. It also offers a better guarantee for safe and controlled surgery. In this preliminary work, the exploitation of 15 heart-lung blocks treated by the injection-corrosion method allowed us to study the general arrangement of the broncho-arteries of the right upper lung lobe and their anatomical variations in the Senegalese population. Our results were as follows: the right upper lobar bronchus was born on average at 1.25 cm from the tracheal bifurcation, with an average length of 1.13 cm. It ended with trifurcation into apical (B1), dorsal (B2) and ventral (B3) segmental bronchi in 10 cases (66.66%); in 3 cases (20%), it ended with bifurcation into the dorsal segmental bronchus and the apico-ventral trunk (B1+B3) (1 case), the apico-dorsal trunk (B1+B2) and the ventral segmental bronchus (B3), finally, in ventral and dorsal segmentary bronchi giving each one an apical branch (1 case); in a last case, it ended by quadrifurcation, giving an external parabronche. The right upper lobe was vascularized by 1 to 4 arteries, with eight modes of vascularization. It received more frequently two arteries. The anterior mediastinal artery was the most common (100%). These results allowed us to discuss anatomical variations in the bronchial tree of the right upper lung lobe and the pulmonary arterial distribution in that lobe. These variations must be taken into account during endoscopic examinations of imaging and surgery of pulmonary excision, under penalty of accidents.

**Key words:** bronchial arteries, right upper lobe variations, surgery.

DOI: <https://dx.doi.org/10.4314/aja.v11i2.5>

### INTRODUCTION

The development of pulmonary surgery, which is increasingly precise, elective and economical, as well as the progress of bronchoscopy and imaging, have made the mastery of the anatomy of the broncho-vascular pedicles of the lung an essential point.

Knowledge of broncho-arterial variations is essential for the interpretation of

investigation methods such as endoscopy and angiography (1). In addition, the right upper lobe has many arterial variations that must be taken into account during surgery, under penalty of a dramatic vascular accident (2-3). The purpose of this preliminary work is to study variations in bronchial and arterial distribution in the

upper lobe of the right lung in Senegalese population.

## MATERIALS AND METHODS

This is a preliminary study of bronchial branching and functional arterial distribution in the human lung based on the exploitation of pulmonary bronchial and arterial moulding by injection-corrosion technique. To do this, we took 15 heart-lung blocks from fresh corpses of adults of both sexes, without trauma or chest-pulmonary macroscopic lesions. The samples were taken at the Pathology Laboratory of CHU A. Le Dantec. The piece thus obtained was sent to the Anatomy Laboratory where it was treated, either immediately or after storage in the freezer at -20°C.

In order to obtain the casts, five pairs of lungs were injected with rhodopas, diluted to 30% in acetone. It was coloured in blue for the pulmonary arteries and colourless for the bronchi. The arteries were injected first, while the lungs were injected with air. The injection of the bronchi was done after the plastic was taken into the vessels. The solidification of the resin by polymerization required freezing the piece for 24 to 48 hours. Ten other pairs of lungs were injected with polyester resin. We used the same colors as before. The injection was done manually using 60cc syringes; the arteries first.

The corrosion was carried out by dipping the room in a 30% hydrochloric acid bath for 7 to 10 days. After corrosion, the resulting part was rinsed under a small stream of tap water to remove the necrotic residues.

Thus, each mold was finely analyzed, specifying the mode of bronchial branching and arterial distribution at the level of lobar and segmental pedicles of the right upper lung lobe of 15 anatomical parts. We studied the topographical relationships between the pulmonary arteries and the bronchial trunks, specifying the situation, the origin, the route, the mode of distribution and the measurements. The reference points were the measurements obtained by means of compasses and centiflex according to topographical references taking into account the situation (origin, path, termination). To minimise measurement errors, the measurements were made by the same person using a compass and then the distance of the compass was plotted on a centiflex to have the exact equivalent value in cm. For the measurement of the arteries, the reference points were also those obtained by means of compasses and centiflex according to topographical references taking into account the situation (origin, path, termination)

## RESULTS

### Right Upper Lobar Bronchus

It was born laterally from the right main bronchus, an average of 1.25 cm from the tracheal bifurcation. Its average length was 1.13 cm (extremes: 0.8-1.4 cm). Oblique at the top and laterally, it ended with trifurcation into apical (B1), dorsal (B2) and ventral (B3) segmental bronchi in 10 cases (66.66%); and in 3 of these cases, the apical segmental bronchi (B1) was reduced to its

posterior branch, The anterior twig came from the B3. We noted variations of this termination type of: Bifurcation in 3 cases (20%) in the dorsal segmental bronchus (B2) and apico ventral trunk (B1 + B3) (1 case); in the apico-dorsal trunk (B1 + B2) and the ventral segmental bronchus (B3) (1 case) (Figure 1) ; finally in the dorsal segmental bronchi (B2) and ventral bronchi (B3) giving each apical branch (1 case); Quadrifurcation

in 1 case (6.3%), in apical (B1), dorsal (B2), axillary or para-external (Bx) and ventral (B3) segmental bronchi. In 1 case (6.3%), the upper lobar bronchus was double with an apico-ventral trunk emerging directly from the right main bronchus 1.3 cm from the tracheal bifurcation followed 0.8 cm lower by a dorsal segmental bronchus (B2).

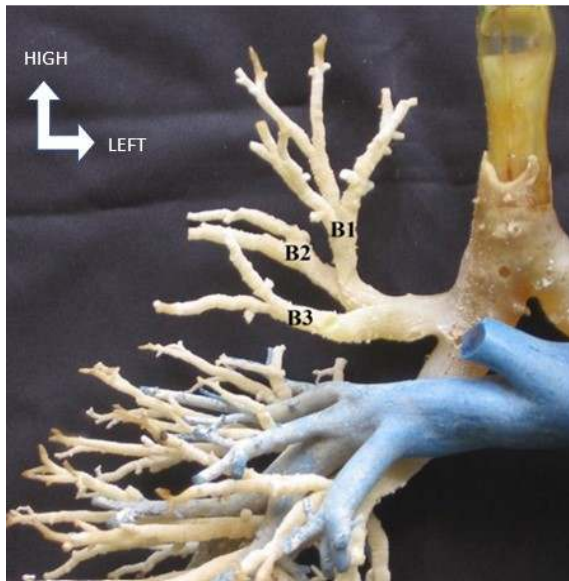


Figure 1. Anterior view of the bifurcation of the upper lobar bronchus. B1: Apical Bronchus; B2: Dorsal Bronchus; B3: Ventral Bronchus

### The Segmental Bronchi

The apical segmental bronchus (B1). It is born either directly from the upper lobar bronchus (8 cases), or from an apico-ventral trunk (2 cases), or from an apico-dorsal trunk (1 case). Oriented upwards, its average length was 0.94 cm (extremes: 0.5-1.2 cm). It typically ended in two sub-segmental anterior and posterior branches for the apical segment in 11 cases (73.33%). In 4 cases (26.64%), there was a split. Three times the posterior sub-segmental twig was born from the trifurcation of the upper lobar bronchus and the anterior sub-segmental twig from the ventral segmental bronchus (B3). In the remaining case, its sub-segmental anterior and posterior branches were born respectively from the ventral and dorsal segmental bronchi.

The dorsal segmental bronchus (B2). It was born directly from the upper lobar bronchus in 13 cases (86.68%), from an apico-dorsal trunk in 1 case (6.66%) and directly from the right main bronchus in 1 case (6.66%). Oblique back, up and laterally, its average length was 1.07 cm (extremes: 0.6-1.5 cm). It was distributed to the dorsal segment by its two sub-segmental lateral and posterior branches. In 1 case, it gave the dorsal sub-segmental branch of the apical bronchus.

The ventral segmental bronchus (B3). It was born directly from the upper lobar bronchus in 13 cases (86.68%) and twice (13.32%) from an apico-ventral trunk. Its average length was 1.02 cm (extremes 0.5-1.8 cm) and its oblique direction forward and slightly down, distributed in the ventral segment. In 4 cases, it gave the anterior subsegmental branch of the apical bronchus.

The apico-ventral trunk. Observed twice, for one, it was born directly from the right main bronchus, and for the other from the bifurcation of the right superior lobar bronchus. It was 0.75 cm long and divided into apical and ventral segmental bronchi.

The apico-dorsal trunk. Observed once, it was born from the bifurcation of the upper lobar bronchus. Its length was 1.1 cm. It ended by bifurcation into apical and dorsal segmental bronchi.

### Arteries Of The Right Upper Lobe

One to four arteries irrigated the upper lobe of the right lung. The mediastinal artery of the right upper lobe: first and largest branch of the right pulmonary artery, it was constant (100%). It was born from the upper part of the anterior face of the right pulmonary artery. Oblique at the top and right, it was forward of the right upper lobar bronchus, its average length was 1.50 cm. Its termination was variable. In 9 cases (60%), it typically ended in the ventral segmental artery and apico-dorsal trunk (Figure 2). In 1 case (6.66%), it bifurcated into ventral and apical

segmental arteries. In 2 cases (13.33%), it constituted only an apico-dorsal trunk. In 1 case (6.66%) (fig 9), it trifurcated in the apico-dorsal trunk, ventral artery and apical artery. In another case, it ended in a bouquet irrigating all segments of the lobe. Finally, in one last case, there was a quadrifurcation in two apical arteries and two dorsal arteries.

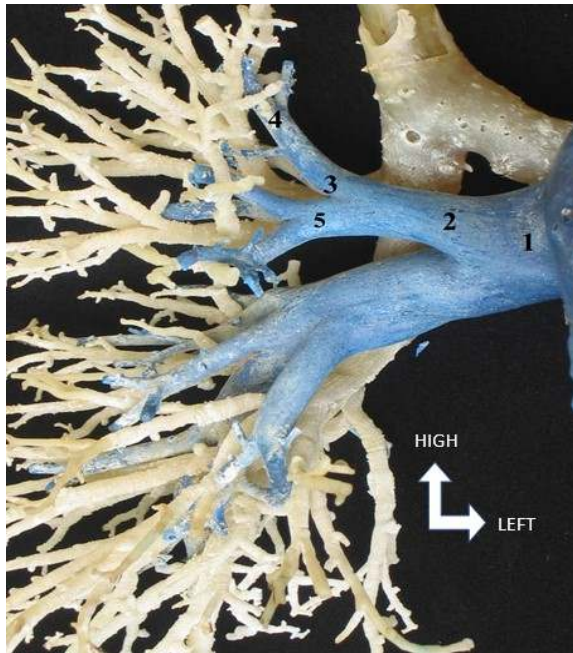


Figure 2. Anterior view of right mediastinal artery bifurcation. 1 : Right pulmonary artery; 2: Right mediastinal artery; 3 : Apico-dorsal trunk (A1 + A2) ; 4 : Apical Segmental Artery A ; 5: Ventral Segmental Artery A3

The inferior mediastinal ventral artery (Figure 3): it was present in 8 cases (53.33%). It was born from the trunk of the pulmonary artery 0.75 cm downstream of the mediastinal artery of the upper lobe. It ended in the ventral segment. In these cases, twice, the mediastinal artery of the upper lobe did not give a ventral branch; The split arteries: we have distinguished three ventral and seven dorsal arteries. They were born on average 1.5 cm from the mediastinal artery of the upper lobe.

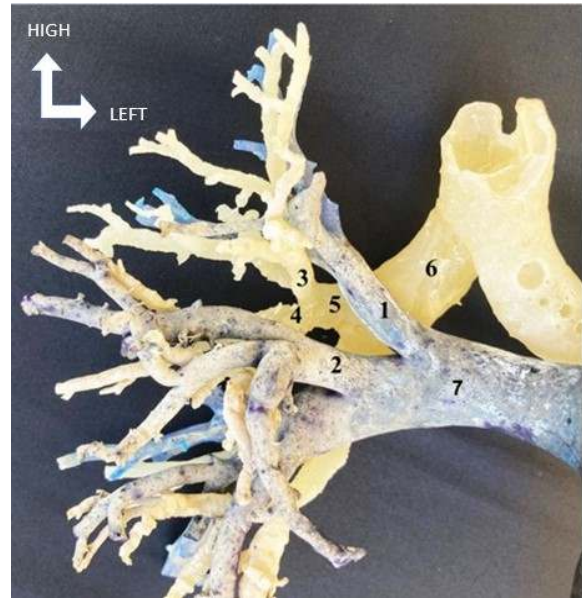


Figure 3. Anterior view of the upper right lobe. 1 : Right mediastinal artery ; 2 : Inferior mediastinal ventral artery ; 3 : Apico-dorsal trunk (B1 + B2) ; 4 : Ventral-dorsal trunk (B3 + B2) ; 5 : Upper lobar bronchus ; 6 : Right Main Bronchus ; 7 : Right pulmonary artery.

The ventral split arteries distributed to the ventral segment and in 1 case the artery shared a common trunk with the upper artery of the middle lobe (Figure 4). The dorsal split arteries distributed to the dorsal segment and in 2 cases the dorsal split artery shared a common trunk with the apical artery of the lower lobe (Figure 5);

Dorso-ventral trunk: It was observed in 1 case, 0.3 cm from the mediastinal artery of the upper lobe that it accompanied in 1 case of quadrifurcation of the right superior lobar bronchus. We encountered eight modes of right upper lobe vascularization grouped into four main types summarized in Table 1.

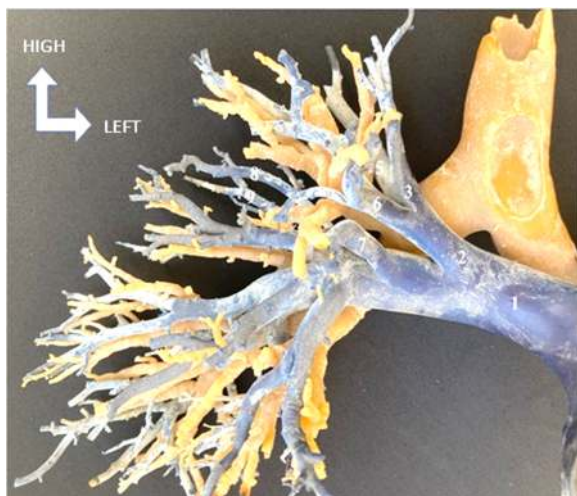

Figure 4. Anterior view of the upper right lobe. 1: Right pulmonary artery ; 2 : Right mediastinal artery ; 3 : Apico-dorsal trunk (A1 + A2) ; 4 : A1 Apical Segmental Artery ; 5 : Dorsal Segmental Artery A2 ; 6 : Ventral Segmental Artery A3 ; 7 : Inferior mediastinal ventral artery ; 8 : Ventral Split Artery ; 9 : Dorsal split artery

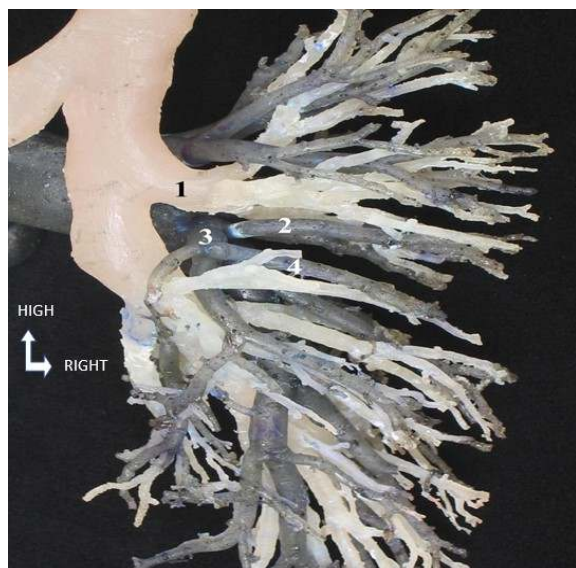


Figure 5. Posterior view of the arteries of the upper lobe. 1 : Right Upper Lobar Bronchus. 2: Dorsal split artery ; 3: Core Curriculum (A2 + A4) ; 4 : Nelson Artery

Table 1. Types of arterial vascularization of the upper right lung lobe

TYPE	SUBTYPE	ARTERY
I		- Mediastinal artery of right upper lobe.
II	Iia	- Mediastinal artery of right upper lobe - Inferior mediastinal ventral artery
	Iib	- Mediastinal artery of right upper lobe - Dorsal split artery
	Iic	- Mediastinal artery of right upper lobe - Dorso-ventral trunk.
III	IIIa	- mediastinal artery of right upper lobe; - Inferior mediastinal ventral artery - Ventral split artery
	IIIb	- Mediastinal artery of right upper lobe - Inferior mediastinal ventral artery - Dorsal split artery
	IIIc	- Mediastinal artery of right upper lobe - Dorsal split artery - Ventral split artery.
IV		- Mediastinal artery of right upper lobe - Inferior mediastinal ventral artery - Dorsal split artery - Ventral split artery

## DISCUSSION

The existence of a double right lobar bronchus was reported in two cases by

Boyden (4). Unlike us, he found an apical bronchus and a ventro-dorsal trunk instead

of a dorsal bronchus and an apico-ventral trunk. This type of variation emphasizes the importance of pre-operative endoscopy. The configuration of the upper right lobar bronchus is often consistent with the literature (5, 6, 7). Its origin is always above the point of crossing of the bronchial trunk by the pulmonary artery, hence the old name of «eparterial bronchus» (AEBY).

At 1.25 cm from the tracheal bifurcation, its origin is more cranial. However it does not hinder the realization of a right pneumonectomy as fears Boyden (8). As for its length, we did not find any significant variation. It is always sufficient to allow a good closure of the stump after an upper right lobectomy (9). We agree with Cabrol (5) that the existence of a common trunk giving the termination the appearance of a bifurcation does not affect the path and the usual arrangement of the segmental bronchi. Trifurcation termination, predominant in our series, is not the most common for Liang (10) and Boyden (11). The latter finds 54% of cases of bifurcation of the right superior lobar bronchus.

The quadrifurcation observed in 1 case, which gives the termination the classic appearance of a four-pointed candelabra, would be due to the sliding of the lateral sub-segmental branch of the dorsal bronchus (5).

This segmental bronchus that ventilates a particular area of the axillary region is the first external parabronche (7) or the axillary bronchus of the anglosaxons. Boyden (11) reported 16% and Scannel (12) 20%. The outer parabronche constantly ventilates the area above the horizontal split, behind the upper ventral territory, forward of the upper dorsal territory and below the apical territory (13).

Vascularization of the right upper lobe is highly variable (14,15), no less than 15 vascularization modes. The number of arteries entering the lobe varies from one to

four, but more often two (15,16). The mediastinal artery of the right upper lobe is always the first if not the only branch to emerge from the right pulmonary artery. Because of its large size, it is recommended that a wide dissection be conducted during the right upper lobectomy so as not to confuse it with the pulmonary artery (6,15). In 60% of cases, it ends with a bifurcation in the ventral branch and apico-dorsal trunk, as confirmed by Maciejewsky (16) and Boyden (11). However, it may be missing (11,16) and in these cases, Maciejewsky (16) finds an apico-ventral trunk in 20% and an apico-dorsal trunk in 12% of the specimens.

The lower mediastinal ventral artery, present in more than half of our cases, has not been studied much in the literature. It incidentally vascularizes the anterior segment of the upper lobe, but, it takes a completely different value when there is no ventral segmental artery (5). The frequency of the split arteries is confirmed by Milloy (15) and Appleton (17). Dorsal split arteries are more common and most often unique (15). The formation of a common trunk with an artery of the lower lobe is not uncommon (15), especially with the apical artery of the lower lobe. As for the ventral split artery, the accessory vessel of the ventral segment, it can become the main artery of this segment in a small percentage (15). The existence of a common trunk with the artery of the middle lobe, although rare, is confirmed by some authors (5, 14, 15). Usually, these are short trunks imposing a separate ligature of the arteries.

Given the frequency of variations, it is recommended to "always look for an aberrant artery even when you think you have found them all" (14). During the reconstruction of an incomplete split, the vessels must be linked only after checking their destiny, as common trunks can give apical arteries of the lower and dorsal lobe of the upper or ventral lobe of the upper and upper middle lobe (6).

## CONCLUSION

The broncho-arterial pedicles of the right upper lobe show many anatomical variations due to the frequent phenomena of slippage and scission which the consideration is necessary for any surgery of pulmonary excision. Thus the identification and identification of the arteries during any lobectomy must be systematic in order to preserve intact the vascularization of the remaining lobes, and to avoid sometimes dramatic vascular accidents.

## ACKNOWLEDGEMENTS

The authors wish to thank Professor Assane NDIAYE for the follow-up and encouragement during the redaction of this document.

## CONFLICTS OF INTEREST

The authors affirmed that there are not any conflicts of interest.

## REFERENCES

1. Beder Beder S., Kupeli E., Karnak D., Kayacan O. Tracheobronchial variations in Turkish population. *Clin Anat* 2008; 21(6): 531-538.
2. Seizeur R., Gerard R., Marion J., Lefevre C., Nonent M., Forlodou P., Senecail B. Anatomic study and CT angiography with 3D reconstructions of the pulmonary arterial tree. *Morphologie*, 2010; 94(306): 45-50.
3. Levasseur Ph. Principes généraux de la chirurgie d'exérèse pulmonaire. *Encycl. Med. Chir., Paris, Techniques Chirurgicales - Thorax*, 42230, 1992, 15p.
4. Boyden EA, Tompsett DH. Anomalous splitting of the upper lobe bronchus in right and left lungs: with a note on the incidence in the London area of left medial basal segments. *J. Thorac. Surg.*, 1959, 37, 4 : 460-463.
5. Cordier G, Cabrol C. Les pédicules segmentaires du poumon. *Le poumon droit*. Esf, Paris, 1952, Tome 1, 309p.
6. Couraud L, Jougon J. Lobectomies pulmonaires. *Encycl. Med. Chir., Paris, Techniques Chirurgicales - Thorax*, 42-350, 1993, 24p.
7. Lucien M. Beau A. La systématisation pulmonaire. Ses bases morphologiques et ses modalités. *Bull. Ass. Anat.*, 1951, 64 : 3-55.
8. Boyden EA. Intrahilar and related segmental anatomy of the lung. *Surgery*, 1945, 18 : 706-751.
9. Kent EM, Blades B. The surgical anatomy of the pulmonary lobes. *J. Thorac. Surg.*, 1942, 12 : 18-30.
10. Liang LS, Snel CAR. The bronchial tree in Indonesians of East-Java (The right upper lobe bronchus). *Bull. Ass. Anat.*, 1956, 91 : 924-932.
11. Boyden EA, Scannel JG. An analysis of variations in the bronchovascular pattern of the right upper lobe of fifty lungs. *Am. J. Anat.*, 1948, 82 : 27-73.
12. Scannel JG. Study of variations of the bronchopulmonary segments in the left upper lobe. *J. Thorac. Surg.*, 1947, 31, 4 : 530-537.
13. Beau MM, Cayotte Lux, Streiff. The outer parabronch of the upper lobe of the human lung. *Bull. Ass. Anat.*, 1951, 65 : 128-133.
14. Cory RAS, Valentine EJ. Varying patterns of the lobar branches of the pulmonary artery. A study of 524 lungs and lobes seen at operation on 426 patients. *Thorax*, 1959, 14 : 267-280.

15. Milloy FJ, Wragg LE, Anson BJ. The pulmonary arterial supply to the right upper lobe of the lung based upon a study of 300 laboratory and surgical specimens. *Surg. Gynécol. Obstét.*, 1963, 116: 35-41.
16. Maciejewski R. Branches of the right pulmonary artery to the right upper lobe of the lung. *Folia Morphol.*, 1991, 50, 3-4 : 179-186.
17. Appleton AB. Segments and blood vessels of the lungs. *Lancet, Lond.*, 1944, 2 : 592-594.