

ORIGINAL COMMUNICATION



# RELATIONSHIP OF THE NEUROVASCULAR STRUCTURES OF THE INFRATEMPORAL FOSSAE IN BLACK ZIMBABWEANS: A CADAVERIC STUDY

TAPERA MAKOSA<sup>1,2</sup>, SILAS BERE<sup>2</sup>, ROBSTEIN CHIDAVAENZI<sup>1</sup>, GILBERT MAWERA<sup>1</sup>

<sup>1</sup>Department of Anatomy, Faculty of Medicine and Health Sciences, University of Zimbabwe, Harare, Zimbabwe.

<sup>2</sup>Department of Dentistry, Faculty of Medicine and Health Sciences University of Zimbabwe, Harare, Zimbabwe.

Corresponding Author: Dr. Silas Bere. Email: [silasbere2020@gmail.com](mailto:silasbere2020@gmail.com)

## ABSTRACT

The Maxillary Artery (MA) is known to vary in its relationship to lateral pterygoid muscle (LPM) and its relationship to inferior alveolar nerve (IAN) and lingual nerve (LN). The variation poses surgical challenges and complications in anesthetic injection. This cadaveric study sought to describe the anatomy of the inferior alveolar nerve, lingual nerve and maxillary artery in infratemporal fossa and its associated variations. Thirty hemi-sections from 15 male cadavers were used. Dissection of the infratemporal fossae was done to expose the MA, LPM, IAN and LN. The relationship of MA to LPM was noted, roots of IAN were noted and relationship of structures were scrutinized. Pictures were taken for further analysis. Out of 30 hemi-sections, dissected 43.3% had a medial relationship to LPM while 56.7% of MA had a lateral relationship. Three (20%) of the cadavers showed asymmetry whereby MA passed on the medial side of LPM on one side while the other side it passed on the lateral aspect. Most of the hemi-sections (86.7%) had IAN originating with one (1) root, 3 hemi-sections (10%) with two roots and one (3.3%) with three roots. Only one hemi-section showed presence of a communicating branch between IAN and LN. The variations in MA in this population displays patterns comparable to other populations. There was high prevalence of MA passing lateral to LPM, which is consistent with studies done elsewhere. There were variations of IAN originating with multiple roots and presence of communicating branch between IAN and LN, which was consistent with case reports in literature.

**Keywords:** Inferior Alveolar Nerve, Lingual Nerve, Maxillary Artery, Infratemporal fossa, Lateral pterygoid muscle

**DOI:** <https://dx.doi.org/10.4314/aja.v11i1.7>

## INTRODUCTION

The infratemporal fossa is an enclosed anatomical area located on the lateral side of the head. It is bounded medially by lateral surface of the lateral pterygoid plate; laterally by the ramus of the mandible; anteriorly by posterior surface of maxillae; superiorly by infratemporal surface of the greater wing of the sphenoid bone. The fossa contains deep

part of the parotid gland and pterygoid muscles. The neurovascular structures in the fossa include maxillary artery, pterygoid venous plexus, the mandibular nerve and its branches (inferior alveolar, lingual nerve, auricular temporal), the otic ganglion and chorda tympani nerve (Sinnatamby, 2006)

The artery of the infratemporal fossa is the maxillary artery, and its course and branching pattern within the fossa has been reported to be variable with regard to its relation to the parotid gland and the lateral pterygoid muscle. (Pretterlieber, et al., 1991). The variations display population differences (Sashi, et al., 1996; Fujimura, et al., 2006).

Also prominent within the fossa are inferior alveolar and lingual nerves, both sensory branches from the posterior division of mandibular nerve. The inferior alveolar nerve enters the mandible through the mandibular foramen, to give sensory supply to the lower jaw. The reported variations of IAN were variable number of roots and existence of a connecting nerve branch that originate from the auriculotemporal nerve to join IAN (Bhardwaji, et al., 2016; Anil, et al., 2003).

The lingual nerve supplies general sensation to the anterior two-thirds of the tongue. It is joined by the chorda tympani nerve, a branch of the facial nerve, responsible for the taste sensation of the anterior two thirds of the tongue and supply the submandibular plexus. There are few variations that has been reported, which include its relation to LTM and the position where chorda tympani joins the Lingual nerve (Mcmanus, 2012).

In clinical practice cases of incidental injury to maxillary artery involving intra-arterial injection of anesthetic have been reported and documented in surgical procedure involving the infratemporal fossa (Webber, et al., 2001). The incidental injuries are common during mandibular nerve block and inferior alveolar nerve block with probability of up to 20% of cases concerned (Frangiskos, et al., 2003; Malamed, 2019). Inferior alveolar nerve block is the technique most frequently used for local anesthesia when performing restorative and surgical procedures in the mandible. Occasionally an inferior alveolar nerve block can damage the

inferior alveolar nerve, lingual nerve or both (Pogrel & Thamby, 2000) through direct needle insertion, chemical trauma or hematoma (Harn & Durham, 1990).

The anatomical knowledge of the courses of these neurovascular structures, and their variations could improve our understanding of surgical procedures and contribute to the effectiveness of surgical interventions. The infratemporal fossa is often the site of pathology or surgical intervention especially when removing infratemporal tumors and/or jugular tumors. Adequate anatomical knowledge of this closed region is important in the resultant combined approaches and multidisciplinary planning required for management of cases in this region (Eravci, et al., 2016). In this cadaveric study, we sought to map out the course of the Maxillary artery and relationship of the IAN, LN and Maxillary artery to lateral pterygoid muscle within infratemporal fossa among black Zimbabweans

### **Maxillary Artery**

The relationship of the MA to LPM can be either superficial or deep to the muscle. In a Caucasian population in Canada, it was found that in the majority (68%), the MA was superficial to the lower head of LPM. The gender orientation was 71% in males and 65% in females. There were no variations between right and left side noted in that study (Hassain, et al., 2008). However, a different study by Pretterlieber et al showed an appreciable asymmetry within the same population (Pretterlieber, et al., 1991). Among the Turkish population, it was reported that the MA is superficial to LPM in 57% and being deep in 43% of the cases (Uysal, et al., 2011). These results are consistent with those reported in New Zealand (Dennison, et al., 2009).

Within the Asian population, the MA course on the superficial side of LPM in 82% of the

cases and being deep in only 18% of the cases (Kim, et al., 2010). These findings are consistent with the report by Sashi et al of a study on Japanese population (Sashi, et al., 1996). In another research among the Japanese population, it was reported that in 3.6% of the cases the MA passes deep to the LPM and in 96.4% of the cases passes superficial to LPM (Otake, et al., 2011). In 2014, Verma and his team describe a case report where the MA was seen passing deep to the LPM and crosses through the nerve loop formed between two roots of the auriculotemporal nerve and the posterior division of the mandibular nerve. Such tortuous course of MA may result in entrapment of the artery, which causes headache and associated irritations (Verma, et al., 2014). Fujimura et al through their study describes the racial variations. The MA passed superficial to LPM in 9 to 55% in the whites, 69% in blacks and 90% in Japanese (Fujimura, et al., 2009). Laska et al also reported various racial variations where MA passed on the deep to LPM in 46% of white individuals and 31% within African-American population (Laska, et al., 1951).

### **Inferior Alveolar Nerve**

The Inferior alveolar nerve (IAN) is a branch of the posterior division of the mandibular nerve, which exit the infratemporal fossa through mandibular foramen. It enters the mandible through mandibular foramen and supply sensory sensation to the lower jaw, it gives motor supply to mylohyoid muscle and the anterior belly of digastric muscle. Variations in the course and origin of the IAN was reported in a number of the studies. Anil et al reported that variations in the anatomy of IAN was seen in 10% of the cases during

their study. The variations were existence of a connecting nerve branch that originate from the auriculotemporal nerve to join IAN. The second part of MA passed between the mandibular nerve, the root of IAN and the connecting nerve branch, which formed a loop. The maxillary artery seems to be entrapped between nerve roots (Anil, et al., 2003). In their study Bhardwaj et al among Indian population, they reported existence of a rare communication between branches of the posterior division of the mandibular nerve. They also confirmed a case of IAN originating by a single root but a communicating branch was present between the auriculotemporal nerve and IAN (Bhardwaj, et al., 2016)

### **Lingual Nerve**

The lingual nerve is a branch of the posterior division of the mandibular nerve, which supplies general sensory innervation (not the gustative one) to the anterior two thirds of the tongue. It is found in the infratemporal fossa. Iwanaga in the study for IAN and LN they reported that in all cases the LN was anterior to IAN (Iwanaga et al 2018). It is important to establish the relationship between the two nerves

The chorda tympani (a branch of the facial nerve, CN VII) joins the LN at an acute angle in the infratemporal fossa, carrying taste fibers from the anterior two thirds of the tongue and parasympathetic fibers to the submandibular ganglion. Bhardwaj et al in their study on nerves of the infratemporal fossa reported that there are slight variations of distances of fusion of chorda tympani nerve to lingual nerve, which is not significant (Bhardwaj et al 2016).

## **METHODOLOGY**

A descriptive cross-sectional study on 15 Human adult black Zimbabweans cadavers at

University of Zimbabwe, Department of Human Anatomy in Gross Anatomy laboratory were used that met the inclusion

criteria. This translated to 30 infratemporal fossae through hemi-section dissections.

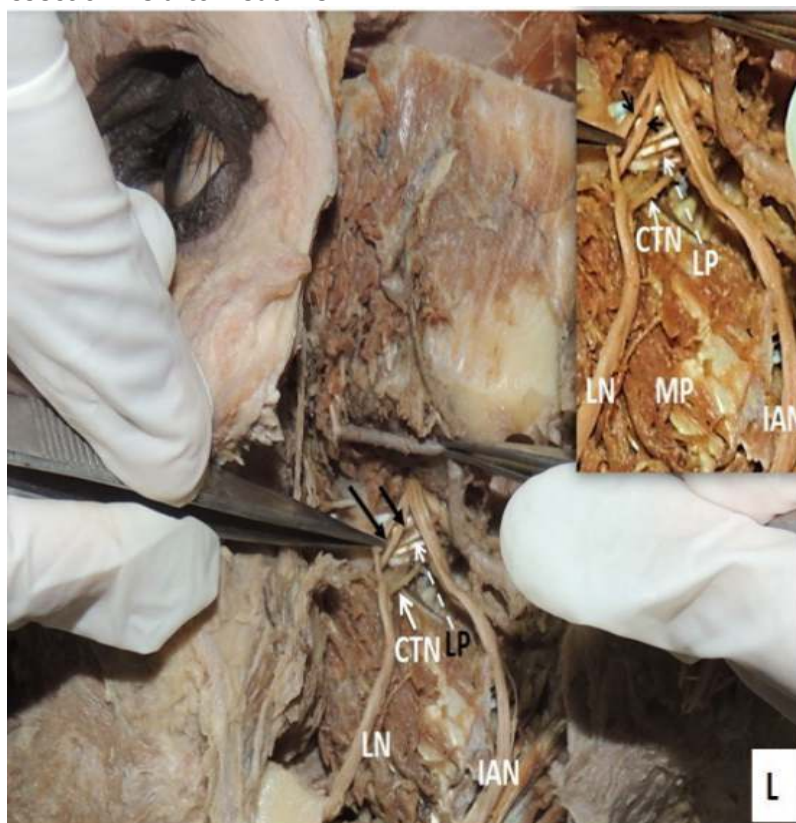
Material required 30 human cadaver hemisections, common dissecting tools and digital camera for photography. A preauricular incision was made and skin reflected. Parotid gland and masseter muscle were removed completely and the mandibular condyle and ramus were exposed. The external carotid artery was identified and followed to identify the origin of maxillary artery. The zygomatic arch, ramus of the mandible and the coronoid were resected using oscillating saw. Temporalis muscle was removed along with the cut on coronoid process. The lateral pterygoid muscle was exposed, and the maxillary artery visualised and its relation to lateral pterygoid muscle was noted.

The lateral pterygoid muscle was then removed from the dissection field to visualize

underlying neurovascular structures. The two branches of the posterior division of the mandibular nerve (lingual and inferior alveolar nerves), were identified and exposed carefully. The possible communications between the lingual and inferior alveolar were checked for. Root(s) of the LN and IAN were exposed and analysed.

The variable course of the maxillary artery and its relation to nerves was observed.

All this information was recorded for each cadaver that was dissected. A digital camera was used to take pictures of the dissected infratemporal fossa for further analysis. The variations observed were classified in the following categories a) relationship of MA and LPM b) communication between the lingual and inferior alveolar nerves, c) multiple roots of the inferior alveolar nerves, d) the unusual relationship of the maxillary artery and roots of IAN.



**Figure 1:** Neurovascular structures of a dissected infratemporal fossa

The research was approved by Medical Research Council of Zimbabwe (MRCZ) & Research Ethics Committee (JREC)

of the University of Zimbabwe, College of the Health Sciences in accordance with the Joint Law of Republic of Zimbabwe (JREC ref:120/19)

### RESULTS

The Maxillary Artery (MA) originate directly from external carotid artery in as a single trunk bilaterally in all cadavers. The relationship of MA to the LPM was described as either lateral or medial to LPM (Moore, et al., 2014). Out of 30 hemi-sections dissected

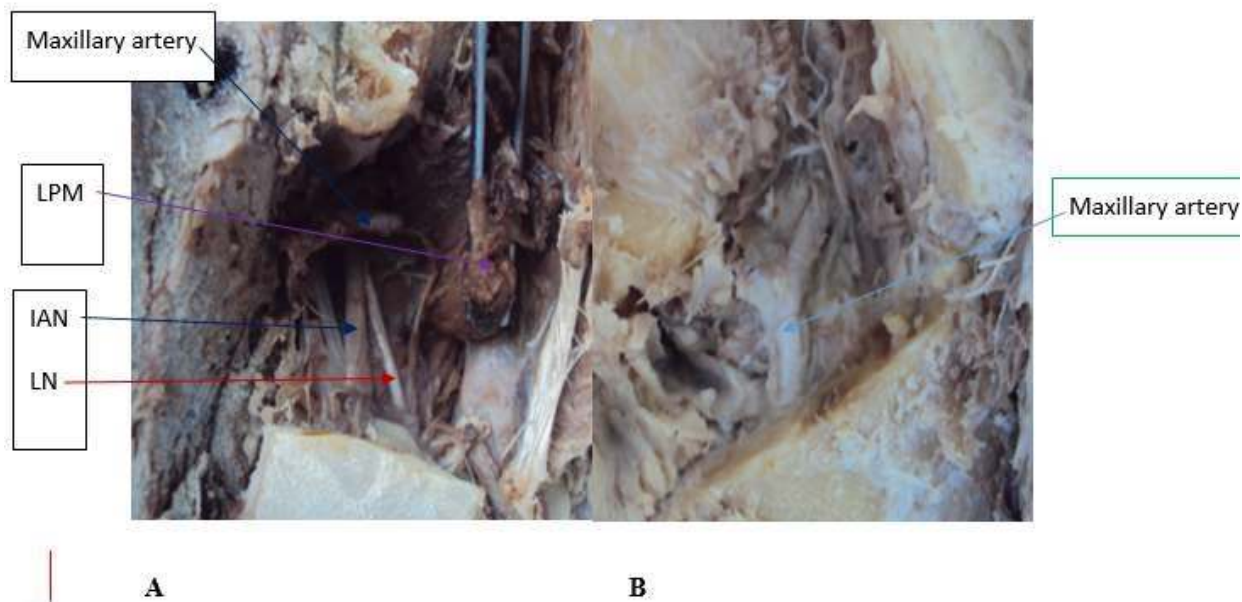
13 (43.3%) of the MA had a medial relationship to LPM while 17 (56.7) had a lateral relationship. On the right side, most of the MA had a medial relationship to LPM. The results are shown on table 1 below.

**Table 1. Relationship of the maxillary artery to the lateral pterygoid (LPM)**

Side	Medial to LPM	Lateral to LPM	Total
Right	8 (53.3%)	7 (46.7%)	15 (100%)
Left	5 (33.3%)	10 (66.7%)	15 (100%)
Total	13 (43.3%)	17 (56.7%)	30 (100%)

Out of 15 cadavers, three (20%) showed asymmetry whereby the MA passed on the

medial side of the LPM on one side while the other side passed on the lateral side of LPM.



**Figure 2.** A showing the maxillary artery passing medial to lateral pterygoid muscle and B passing on the lateral side of LPM

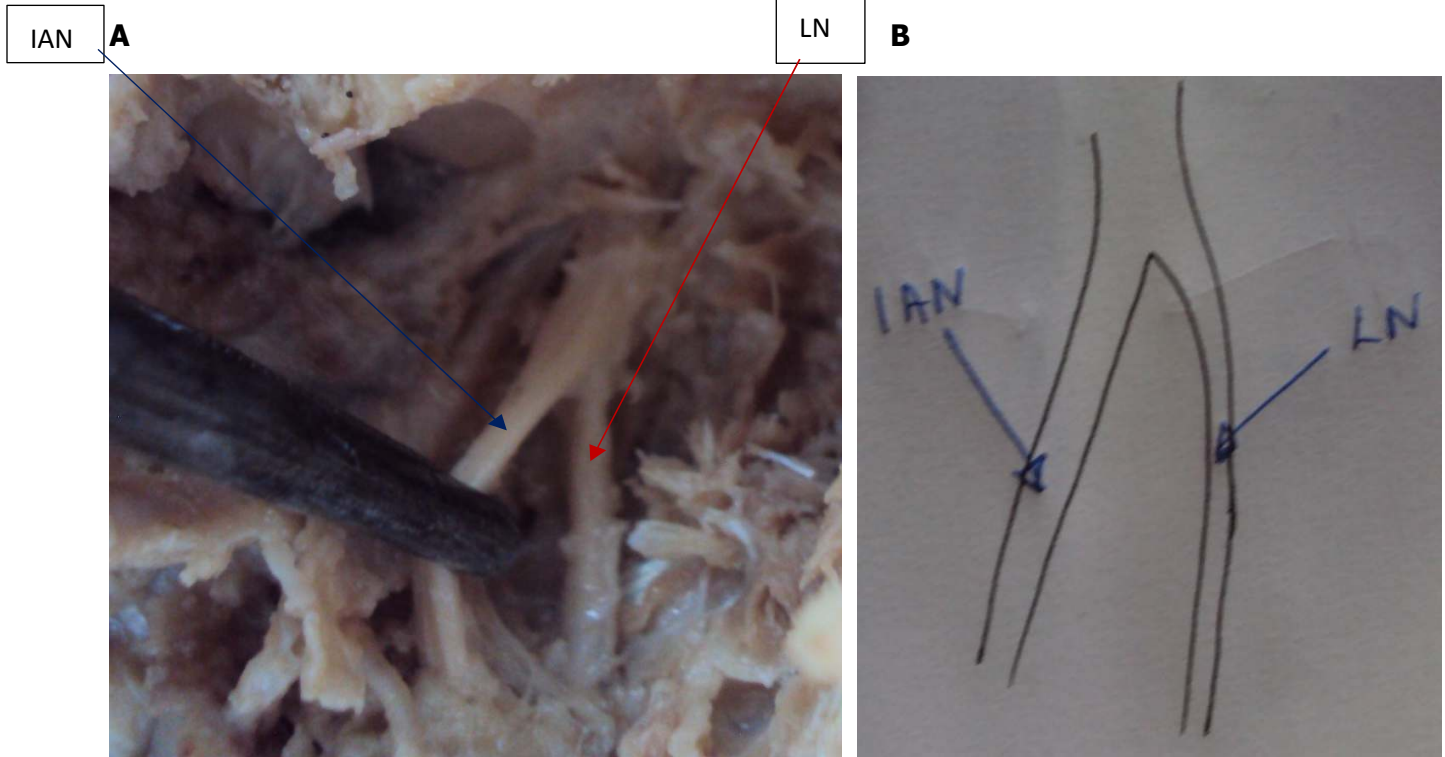
The alveolar nerve is a branch of posterior division of the the mandibular nerve. It originate by either single root or multiple roots which will join and form the

IAN (Bhardwaji, et al., 2016). In this study roots were classified as single, two and three roots as shown on table 2 below.



**Table 2. Number of roots of origin for inferior alveolar nerve**

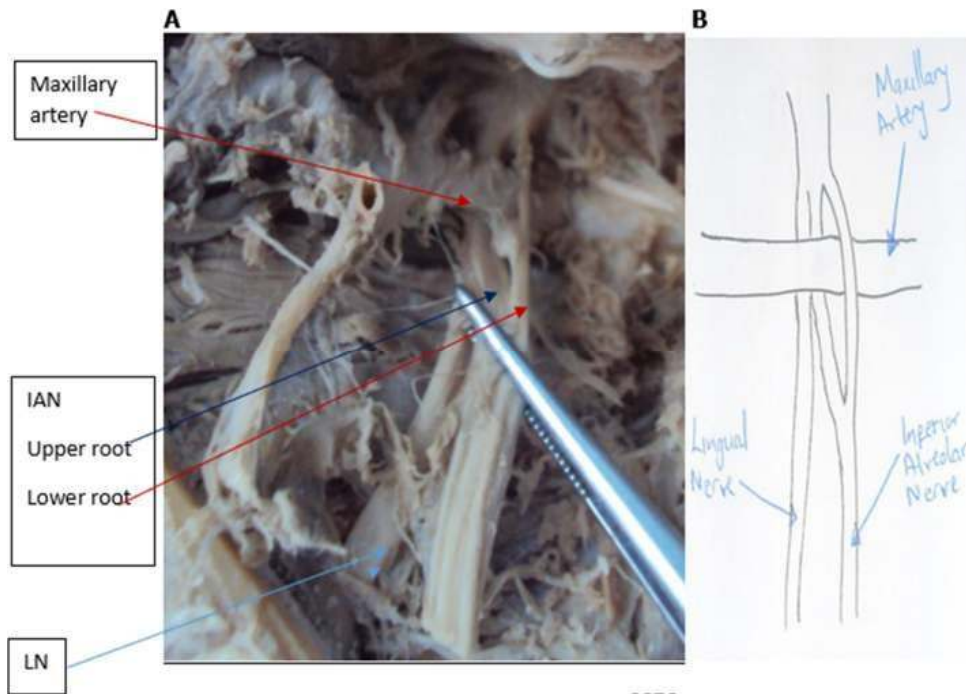
Side	root	roots	roots	Total
Right	(86.7%)	(13.3%)	0	(100)
Left	(86.7%)	(6.7%)	(6.6%)	(100)
Total	(86.7%)	(10.0%)	(3.3%)	(100)



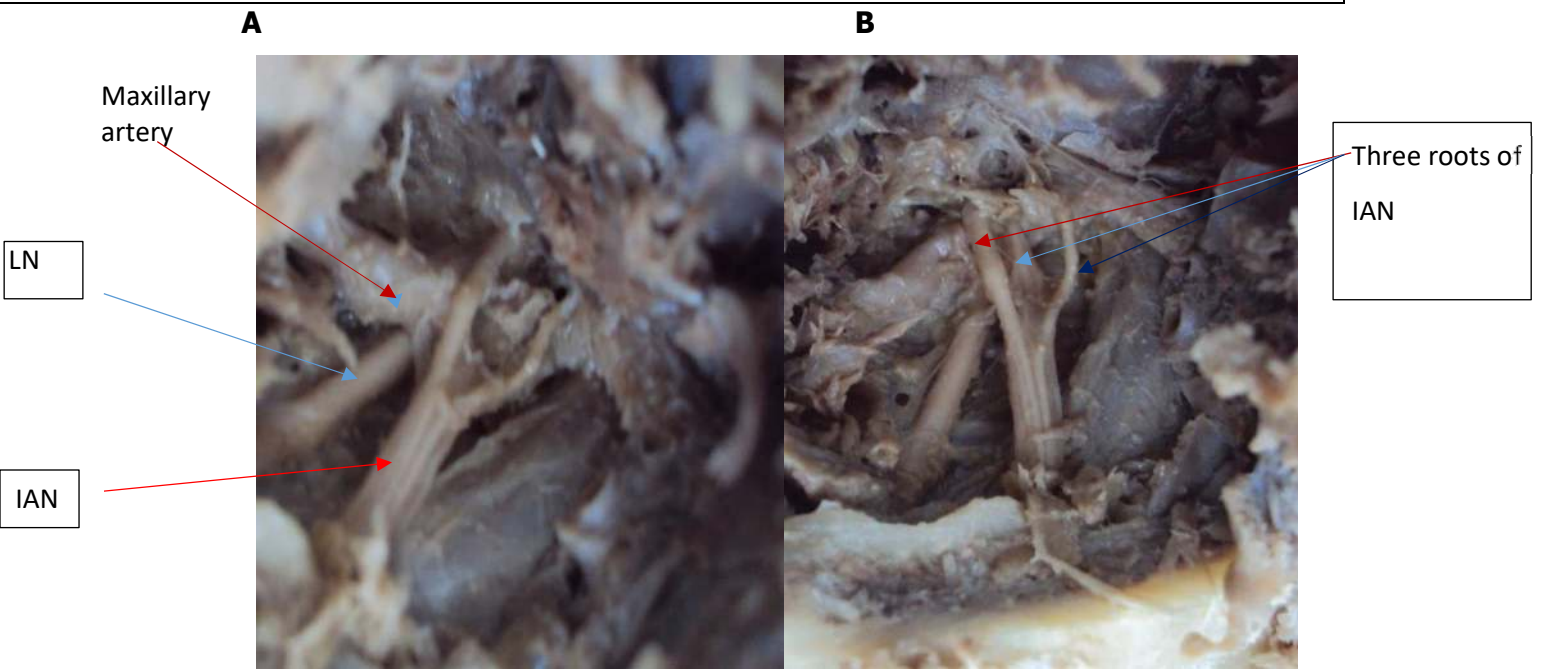
**Figure 3:** A showing the IAN originating as a single root and B is a free hand sketch of A

**A**

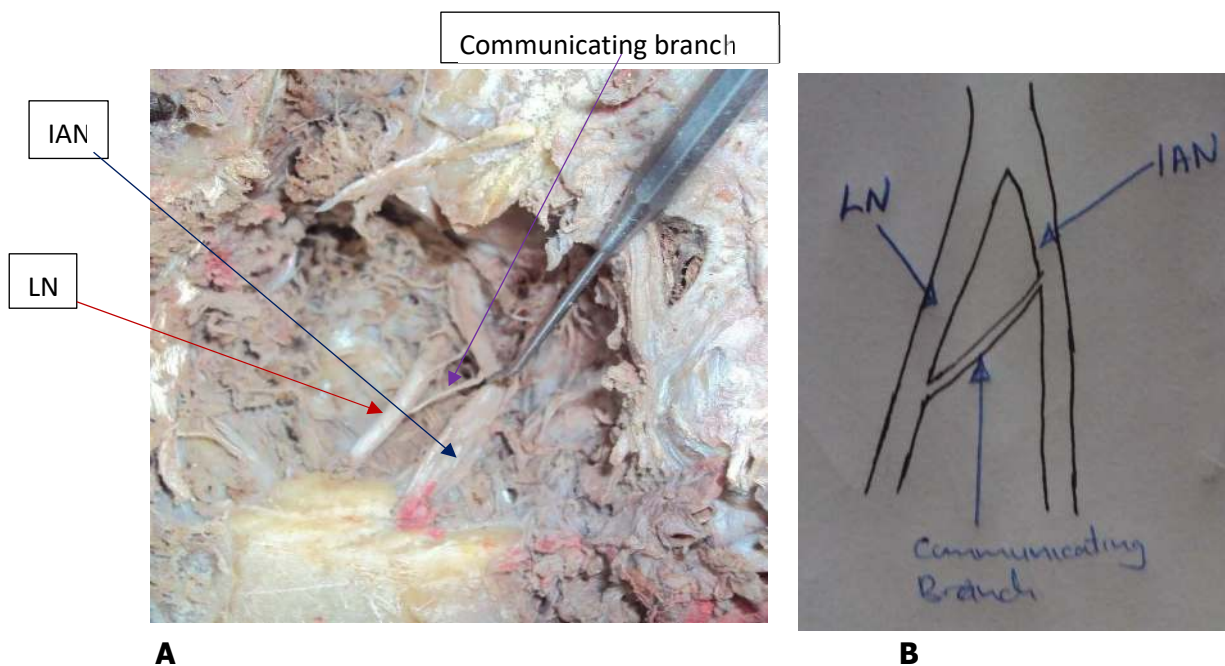
**B**



**Figure 4:** A showing the relationship between IAN, LN and the maxillary artery; B is a free hand sketch of A



**Figure 5:** A showing the IAN originating as three roots that encircle the maxillary artery and B with the maxillary artery removed



**Figure 6.** A showing presence of a communicating branch between the IAN and LN. B is a free hand sketch of A.

## DISCUSSION

A communicating branch is a branch that connects two nerves (branches of mandibular nerve in this case). In this study, a communicating branch was observed joining IAN and LN. Out of 30 hemi-sections, only one (3.3%) showed presence of a communicating branch between IAN and LN as shown on figure 6.

In this present research, out of 30 hemisections most of the MA passed lateral to LPM. Seventeen (56.7%) of MA were found to be lateral and 13 (43.3%) were medial to LPM. The results are comparable to Fujimura et al (69% in blacks) and Warui (62% in Kenyans) (Fujimura, et al., 2006; Warui, 2017). It was interesting to note that on the right side most of the MA (53.3%) were medial to LPM. There is need for further investigation to ascertain this finding since it was not reported in the literature. The overall results show consistence and coherence with other studies on different populations which showed that MA passed lateral LPM in most

of hemi-sections (Kim, et al., 2010) (Hassain, et al., 2008).

The lateral relationship of MA has been reported as 9-55% and 90% in Whites and Japanese respectively (Fujimura, et al., 2006). The MA passed medial to LPM in 43.3% in the current study, which is comparable to a study by Lasker (31% in Africans Americans), and Warui (38% in Kenyans; Lasker, et al., 1951; Warui, 2017). In majority of cadavers, there was symmetry in the anatomical course of the MA on both right and left sides of the head. Only three

(20%) cadavers showed asymmetry whereby the MA passed on the medial side of the LPM on one side while the other side passed on the lateral aspect. The prevalence of asymmetry in course of the left and right MA has been reported to be 6.8% by Takarada and 6.3% by Ikakura, which is not consistence with the current study (Takarada



T, 1958; Ikakura K, 1961). There is need for a further research to ascertain this value in this population.

In the present study, most of the IAN originate as a single root from posterior division of mandibular nerve. Twenty-six 26 (86.7%) of hemi-sections showed the IAN originating as a single root. In three (10.0%) hemi-sections, IAN originate as two roots which later unite to form a single nerve. In one section, the roots were clearly unequal and they encircled the maxillary artery. In the other one, the roots were almost equal and the maxillary artery was not entrapped between the roots. The IAN originating with two roots with maxillary artery incorporated between the roots was reported by Sharma and Khan (Sharma, et al., 2011; Khan, et al., 2010).

Only one (3.3%) hemi-section showed three roots and the maxillary artery was encircled or entrapped by these roots. The three roots of IAN were once published by Quadro, although his scenario was different, in his report one branch was from lingual nerve and the other two from auriculotemporal nerve (Quadros, 2013). Entrapment of the MA between roots of IAN may cause numbness or headache and may interfere with injection of local anaesthetics (Khan, et al., 2010).

Communicating branch is a small nerve that joins two nerves; it can join IAN and auriculotemporal, or LN and auriculotemporal or IAN and LN (Potu, et al., 2009). In the current study, one hemisection showed presence of a communicating branch between IAN and LN as shown on figure 6. The IAN in this case was originating with a single root and this is consistent with a study by Bhardwaji (Bhardwaji, et al., 2016) . Communicating branches between branches of the posterior division of the mandibular

nerve were reported as isolated cases by many authors, which include Bhardwaj and Thotakura (Bhardwaji, et al., 2016; Thotakura, et al., 2013). Communicating branches between nerves found in this study are developmental in origin and thought to maintain functional integrity through an alternative route, such alternative route complicate anaesthetic injection (Thotakura, et al., 2013).

## CONCLUSION

The variation of MA in this population displayed pattern comparable to previous studies in other populations. Overly there was high prevalence of MA passing lateral LPM, which was consistent with studies done elsewhere. Incorporation of the maxillary artery between roots of IAN maybe associated with intravascular injection during mandibular nerve block or any related procedure therefore caution needs to be exercised in procedures involving this region. On the right side there was high prevalence of MA passing medial LPM which is not consistent with previous studies. There was high prevalence of IAN originating with single roots, followed by two roots and one case of three roots. The MA being incorporated between the roots of IAN was consistent with case reports in literature. The presence of communicating branch between branches of the posterior division of the mandibular nerve may be thought to provide functional integrity through alternative route; such route may complicate anaesthetic injection. A prospective study with large sample needs to be conducted to determine their prevalence. Further investigation with large sample size to determine if there is gender variation on MA since there was no female cadaver in this study.

## REFERENCES

1. Anil, A., T, P., HB, T. & IN, G., 2003. Variations in the Anatomy of the inferior alveolar nerve. *Br J Oral Maxillofac Surg*, 41(4), pp. 236 - 239.
2. Bhardwaji, N., Dushyant, A., Tewari, V. & Brijendra, S., 2016. A study of variations in nerves of the infratemporal region and its embryological explanation. *Indian J Clin Anat Physiol* 2(1), pp. 42 - 45.
3. Claire, P. G., Gibbs, K., Hwang, S. H. & Hill, R. V., 2011. Divided and United Maxillary Artery; developmental and clinical consideration. *Anat. Sci. Int.* 86(1), pp. 232-236.
4. Dennison J, Batra A, Herbison P. The maxillary artery and the lateral pterygoid muscle: the New Zealand story. *Oral Surg Oral Med Oral Pathol Oral Radiol Endod.* 2009 Nov;108(5):e269. doi: 10.1016/j.tripleo.2009.07.029. PMID: 19836710.
5. Eravcı FC, Düzlü M, Zorlu ME, Yılmaz M, Ataç MS. Excision of recurrent synovial sarcoma of the infratemporal fossa. *Kulak Burun Bogaz Ihtis Derg.* 2016 Sep-Oct;26(5):293-9. doi: 10.5606/kbbihtisas.2016.09365. PMID: 27888827.
6. Frangiskos, F., Stavrou, E., Merenditis, N. & Vardas, E., 2003. Incidence of penetration of blood vessel during inferior alveolar nerve block. *Br J Oral Maxillofac Surg* 41(3), pp. 188-9.
7. Fujimura, K., Segami, N. & Kobayashi, S., 2006. Anatomical study of the complications of intraoral vertical sagittal ramus osteotomy. *J Oral Maxillofac Surg*, Volume 64, pp. 384 - 389.
8. Harn, S. D. & Durham, T. M., 1990. Incidence of lingual nerve trauma and postinjection complications in conventional mandibular block anesthesia. *J Am Dent Assoc* Oct, 121(4), pp. 519 - 523.
9. Hassain, A., Binahmed, A., Karim, A. & Sandor, G., 2008. Relationship of the maxillary artery and lateral pterygoid muscle in Caucasians. *Oral Surg Oral Med Oral Pathol Oral Radiol*, Volume 105, pp. 32-36.
10. Ikakura K. On the origin, course and distribution of the maxillary artery in Japanese, *Archive Department of Anatomy Tokyo Dental College (Kouku kaibon kenkyu)* 1961; 18: 91-122
11. Iwanaga J, Choi PJ, Vetter M, Patel M, Kikuta S, Oskouian RJ, Tubbs RS. Anatomical Study of the Lingual Nerve and Inferior Alveolar Nerve in the Pterygomandibular Space: Complications of the Inferior Alveolar Nerve Block. *Cureus.* 2018 Aug 6;10(8):e3109. doi: 10.7759/cureus.3109. PMID: 30338184; PMCID: PMC6175254
12. Khan, M., Drwish, H. & Zaher, W., 2010. Perforation of the inferior alveolar nerve by the maxillary: an anatomical study. *Br J Oral Maxillofac Surg*, 48(8), pp. 648-7.
13. Kim, J. K., Cho, K. H., Lee, Y. J. & Kim, C. H., 2010. Anatomical variability of the Maxillary Artery finding from 100 Asian Cadaveric Dissections. *Arch Otolaryngol Head Neck Surg*, Volume 136, pp. 813- 818.
14. Lasker, G., Opdyke, D. & Miller, H., 1951. The position of the internal maxillary artery and its questionable relation to cephalic index. *Anat. Rec.*, 109(1), pp. 119-126.
15. Malamed S.F 2019, *Handbook for local anesthesia*, Seventh edition, Elsevier Inc, page 211, 321
16. McManus LJ, Dawes PJ, Stringer MD. Surgical anatomy of the chorda tympani: a micro-CT study. *Surg Radiol Anat.* 2012 Aug;34(6):513-8. doi: 10.1007/s00276-012-0941-z. Epub 2012 Feb 21. PMID: 22349643

17. Moore K. L, Dalley A. F and Agur A. M 2014 Moore Clinically Oriented Anatomy Seventh Edition Toronto (Ontario) :Lippincott Williams and Wilkins Page 916-918
18. Otake, I., Kangeyama, I. & Mataga, 2011. Clinical Anatomy of Maxillary Artery. *Okajimas Folia Anat Jpn*, Volume 84, pp. 155-164.
19. Potu, B. K., Pulakunta, T., Bhat, K. M. & D'Silver, S. S., 2009. Unusual communication between the lingual nerve and mylohyoid nerves in a South Indian Male Cadaver; its clinical significance, India: *Rom J Morphol*.
20. Pretterlieber, M. L., Skopakoff, C. & Mayr, R., 1991. The human Maxillary artery reinvestigated: Topographical relations in the infratemporal fossa. *Acta Anatomica*, 01 02, 142(1), pp. 281 - 287.
21. Pogrel MA, Bryan J, Regezi J. Nerve damage associated with inferior alveolar nerve blocks. *J Am Dent Assoc*. 1995 Aug;126(8):1150-5. doi: 10.14219/jada.archive.1995.0336. PMID: 7560573
22. Sashi, R., Tomura, N., Hashimoto, M. & Kobayashi, M., 1996. Angiographic anatomy of the first and second segments of the maxillary artery. *J Med Radiat Sci* 14(1), pp. 133-138.
23. Sharma, A., Vohra, H., Sigh, P. & Sood, V., 2011. Unusual origin and variation in topographical relation of inferior alveolar nerve in the leftinfratemporal fossae. *J Indian Med Assoc*, 109(2), pp. 96-8.
24. Sinnatamby C. S 2006, Last's Anatomy 12th Edition. London Elsevier Limited page 361 - 364
25. Takarada T. Anatomical studies on maxillary artery, *J. Tokyo Dental College Society* 58:1-20, 1958
26. Thotakura, B., Rajendran, S., Gnanashndaran, V. & Subramaniam, A., 2013. Variations in the posterior divisions branches of the mandibular nerve in human cadavers. *Singapore Med J*, 54(3), pp. 149-51.
27. Uysal, I., Buynkmumcu, M., Unver, D. N. & Seker, M., 2011. Clinical significance of Maxillary artery and its branches: A Cadaveric Study and Review of Literature. *Int J Morphol*, pp. 1274-1281.
28. Verma, S., Fasil, M., Murugan, M. & Sakkarai, J., 2014. Unique variation in the course of maxillary artery in infratemporal fossa. *Surg Radiol Anat*. Volume 36, pp. 507-509.
29. Warui T. M 2017 Variations and bony landmarks of maxillary artery, A Cadaveric Study. University of Nairobi, Kenya. Page 1-50
30. Webber, B., Orlansky, H., Lipton, C. & Stevens, M., 2001. Complications of the intra-arterial injection from an inferior alveolar nerve block. *J Am Dent Assoc* 132(12), pp. 1702-1704.