

MORPHOLOGICAL CHANGES IN THE SPERM STORAGE TUBULES OF THE JAPANESE QUAIL EXPOSED TO METHYL-2-BENZIMIDAZOLE CARBAMATE

Wahabu Kimaro

Department of Veterinary Anatomy, Faculty of Veterinary Medicine, Sokoine University of Agriculture, P.O.Box 3016, Morogoro – Tanzania. Email: kim16wh@yahoo.com

ABSTRACT

The current investigation was an attempt to establish the effect of various doses of methyl-2-benzimidazole carbamate (carbendazim®) on the morphology of the Sperm Storage Tubules (SST) in the Japanese quail (*Coturnix coturnix japonica*). Carbendazim® in sunflower oil base was administered orally at doses of 0mg/kg (control), 25mg/kg, 100mg/kg, 400mg/kg and 800mg/kg body weight. Tissue samples from Uterovaginal junction were processed for both light (LM) and Transmission electron (TEM) microscopic study following standard procedures. The result showed that, at LM level, no histopathological changes were observed at a dose of 25mg/kg b.w.t. A significant decrease in SST width and luminal diameters was observed at doses of 100mg/kg and 400mg/kg b.w.t ($p < 0.05$). In addition, doses of 400mg/kg and 800mg/kg b.w.t caused leukocytic infiltration and hyperaemia in the *lamina propria-submucosa*. At these doses SST were devoid of spermatozoa. TEM results showed pyknosis, swollen mitochondria, vacuolation and increased number of lysosomes in degenerating SST. The observed morphological changes indicate the ability of carbendazim to disrupt structural integrity of SST as well as its storage capacity. This poses a great threat to the fertility of exposed birds and thus care must be taken to reduce environmental contamination.

Keywords: Carbendazim, histopathology, ultrastructure, Sperm storage tubules, Japanese quail

INTRODUCTION

The structure of sperm storage tubules has been extensively studied in the domestic fowl (Fujii, 1963; Tingari and Lake, 1973; Das, 2003), turkey (Ogasawara & Fuqua 1972; Bakst 1981; Schupp et al., 1984), Japanese quail (Frieß et al., 1978; Birkhead and Fletcher, 1994) and Bengalese finch (Birkhead, 1992). The SST are tubular invaginations of the luminal epithelium which are lined by simple columnar epithelium. The number of SST varies between species (Birkhead and Møller, 1992). Up to 3467 SST have been recorded in the Japanese quail (Birkhead and Fletcher, 1994).

The release of spermatozoa from SST occurs intermittently during fertilization and has been suggested to be controlled by ciliary movement on the apical tubular section or flushing action by gland secretions as well as the presence of myoepithelial cells (Schupp et al., 1984;

Birkhead, 1992; Das, 2003). Studies of ciliary movement have shown the involvement of cytoskeletal elements such as; microtubules, intermediate filaments and microfilaments (Sandoz et al., 1983; Chailley et al., 1989). Based on the fact that fertilization in avian species depends on the release of spermatozoa from SST, active ciliary movement as well as structural integrity of glandular cells are important. Methyl-2-benzimidazole carbamate (carbendazim®) disrupt microtubule by binding to the β tubulin subunit of the microtubule (Burland and Gull, 1984; Cruz and Edlind, 1997). Disruption of the microtubule will affect cellular skeleton as well as ciliary movement, thus impaired fertility in exposed birds. To-date little is known on the possible morphological changes in the SST following carbendazim exposure. This study therefore, investigated the histopathological and

Submitted 3rd June 2016, corrected 17th June 2016. Published online 1st July 2016. To cite: Kimaru W. Morphological changes in the sperm storage tubules of the Japanese quail exposed to methyl-2-benzimidazole carbamate. Anatomy Journal of Africa. 5: 713 – 720.

ultrastructural changes in the SST of Japanese quail exposed to carbendazim.

MATERIALS AND METHODS

A total of 35 sexually mature female Japanese quail purchased from Irene Improvement Research Farm, Pretoria were used. The birds were divided into two groups, the control and treatment groups. The treatment group was further divided into four groups of 7 birds each according to the administered dose. Carbendazim (97% Sigma Aldrich) was dissolved in sunflower oil and administered *per os* to treatment birds at dosages of 25mg/kg, 100mg/kg, 400mg/kg and 800mg/kg bodyweight. The doses were selected based on the previous experiment in the Japanese quails (Kimaro et al. 2013). The control birds were given the sunflower oil base orally. During the experiment, food (growers mash, containing maize grain) and water were provided *ad libitum*. Light was controlled at a ratio of 14:10 hours (light and darkness) throughout the experiment.

Forty-eight hours post-exposure to carbendazim, birds were sacrificed by inhalation anaesthesia using carbon dioxide (CO₂). Following the death of a bird, pleuroperitoneal cavity was opened and the reproductive tract was dissected immediately.

Histomorphometrical observations

Control birds

The mucosal layer in the utero-vaginal junction

Carbendazim-treated birds

Histomorphometry

Table 1 summarises the measured morphometrical parameters of the SST in the control and carbendazim-treated birds. There was a general decrease in the width of the SST following administration of low doses of carbendazim. When compared to the control, a significant decrease in the width of SST was observed at 100 mg/kg and 400 mg/kg bodyweight. A significant decrease was also observed between 25 mg/kg and 100 mg/kg,

Light microscopy

Tissue samples from the Utero-vaginal junction (UVJ) were immersion fixed in 10% buffered formalin for 48 hours. Tissue samples were then processed routinely for light microscopy using automated tissue processor (Shandon excelsior®, Thermo Electron Corporation, Germany) and stained with Haematoxylin and eosin (H&E). Tissue morphometry such as SST width and luminal diameters were evaluated using an image analyzer ((AnalySIS®; Olympus BX 50, Optical Company LTD, Japan). The SST width was measured by drawing a perpendicular line across the gland. Glandular luminal diameter was determined by measuring the perpendicular distance between two opposing gland cells. Morphometrical data were analysed using analysis of variance (ANOVA); SPSS version 17. A probability of 5% was considered significant.

Ultrastructure

Tissue samples from UVJ were immersion fixed in 2.5% glutaraldehyde in 0.1M Millonig's buffer (pH 7.3) for 24 hours. Thereafter, the tissue samples were post-fixed in 2% osmium tetroxide. Following post-fixation, samples were processed for transmission electron microscopy (TEM) using standard techniques.

RESULTS

as well as, between 100 mg/kg and 800 mg/kg bodyweight ($p < 0.05$). At a dose of 800 mg/kg bodyweight, carbendazim increased the width of the SST. However, this increase was not statistically significant when compared to the control ($p < 0.05$). The increase was statistically significant between 400 mg/kg and 800 mg/kg bodyweight ($p < 0.05$). Consistent with glandular width, the glandular lumina diameters were also decreased by carbendazim treatment. A significant decrease in the glandular lumina diameters was recorded at 100 mg/kg when compared to the control and 25 mg/kg bodyweight groups ($p < 0.05$).

was lined by simple ciliated columnar epithelium. In the *lamina propria-submucosa*, sperm storage tubules (SST) were observed

(Fig. 1a). The SST were tubular glands formed by luminal epithelial invagination (Fig. 1b). A simple columnar epithelium lined the SST (Fig. 1c). At the proximal extremity (neck) of the gland, the lining epithelium was simple ciliated columnar (Fig. 1b). Numerous spermatozoa were observed in these glands (Fig. 1a&c). The glands measured between 22.3 and 35.45 μm (27.22 ± 0.98) in width. The glandular lumena were averagely 5.26 μm in diameter.

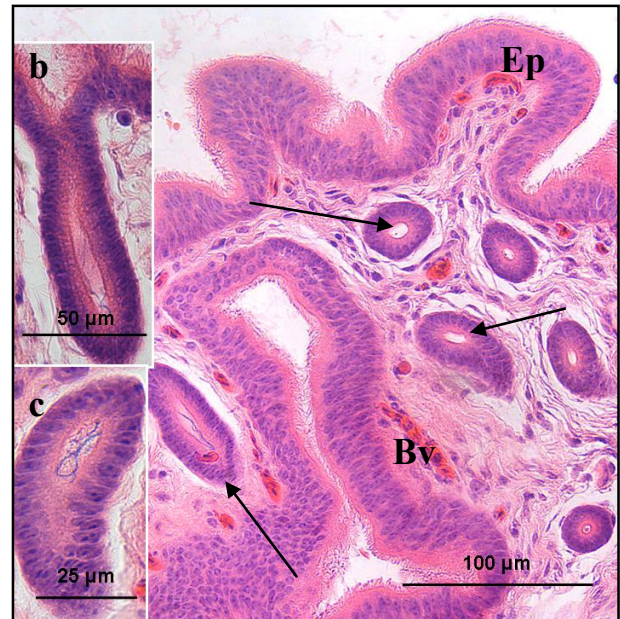


Fig. 1: a. Photomicrograph of the *mucosa* in the UVJ region of control bird. SST (arrows) are observed in the *lamina propria-submucosa*. Ep: luminal epithelium; Bv: blood vessels. b. A SST is seen formed by epithelial invagination. c. A simple columnar epithelium lining the SST.

Table 1: Mean \pm SE histomorphometrical parameters of the SST in the control and carbendazim treatment groups

Carbendazim dose (mg/kg)	Glandular width (μm)	Glandular lumena diameters (μm)
0	27.22 ± 0.98	5.26 ± 0.31
25	$24.48 \pm 0.45^{\text{b}}$	$4.61 \pm 0.21^{\text{b}}$
100	$11.77 \pm 3.36^{\text{abc}}$	$2.13 \pm 0.21^{\text{ab}}$
400	$17.87 \pm 3.36^{\text{ad}}$	3.97 ± 0.92
800	$30.41 \pm 1.3^{\text{cd}}$	3.99 ± 0.33

^a Differs significantly from the control

^{bcd} Significant difference between treatment groups

Histopathology

No histological degenerative changes were observed in the SST at doses of 25 mg/kg and 100 mg/kg bodyweight, 48 hours' post-exposure to carbendazim. At a dose of 400 mg/kg bodyweight carbendazim, a few spermatozoa were observed in the lumena of the SST (Fig. 2a). In some instances, the gland lumena were empty. The SST contained a few cells with pallor cytoplasm and pyknotic nuclei (Fig. 2b). At a dose of 800 mg/kg, hyperaemia, perivascular cuffin and cells with pyknotic nuclei were observed in the *lamina propria-*

submucosa (Fig. 3a-c). The lumena of SSTs contained no spermatozoa.

Ultrastructural observations

Control birds

The SST cells contained round nucleus located basally (Fig. 4a). A cytoplasm which appeared electron lucent, contained a few mitochondria and stacks of Golgi complexes (Fig. 4b). A conspicuous lipid body was observed either in the apical or basal cytoplasmic regions. Desmosomes and occasional tight junctions were observed on the apical plasma membrane (Fig. 4c).

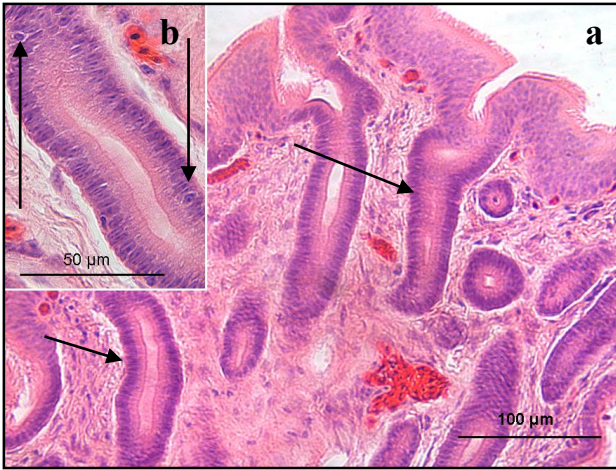


Fig. 2a. Photomicrograph of the *mucosa* in the UVJ region of a bird treated with 400 mg/kg bodyweight. Arrows: empty SST; Bv: blood vessels. **b.** SST higher magnification. Arrow: pyknotic nucleus.

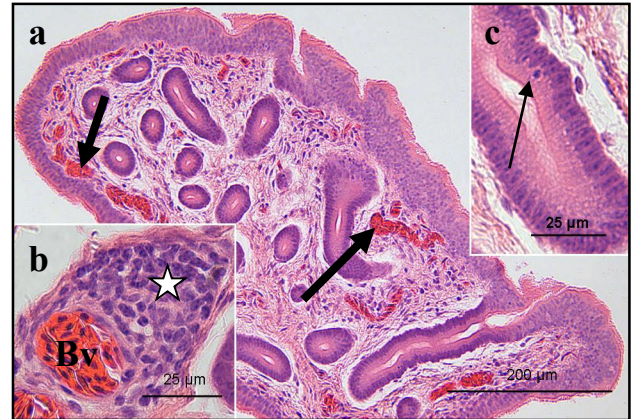

Fig. 3a. Photomicrograph of the *mucosa* in the UVJ region of a bird treated with 800 mg/kg b.w.t. Thick arrows: congested blood vessels. **b.** Asterisk: aggregation of inflammatory cells. Bv: blood vessel. **c.** Arrow: pyknotic nucleus.

Along the lateral plasma membrane, infolding and formation of lateral process were observed. The length of the lateral processes was increasing toward the basal cellular region.

The cells rested on a basal lamina (approximately 55nm thick). The basal lamina displayed both the lamina densa and lamina lucida (Fig. 4d)

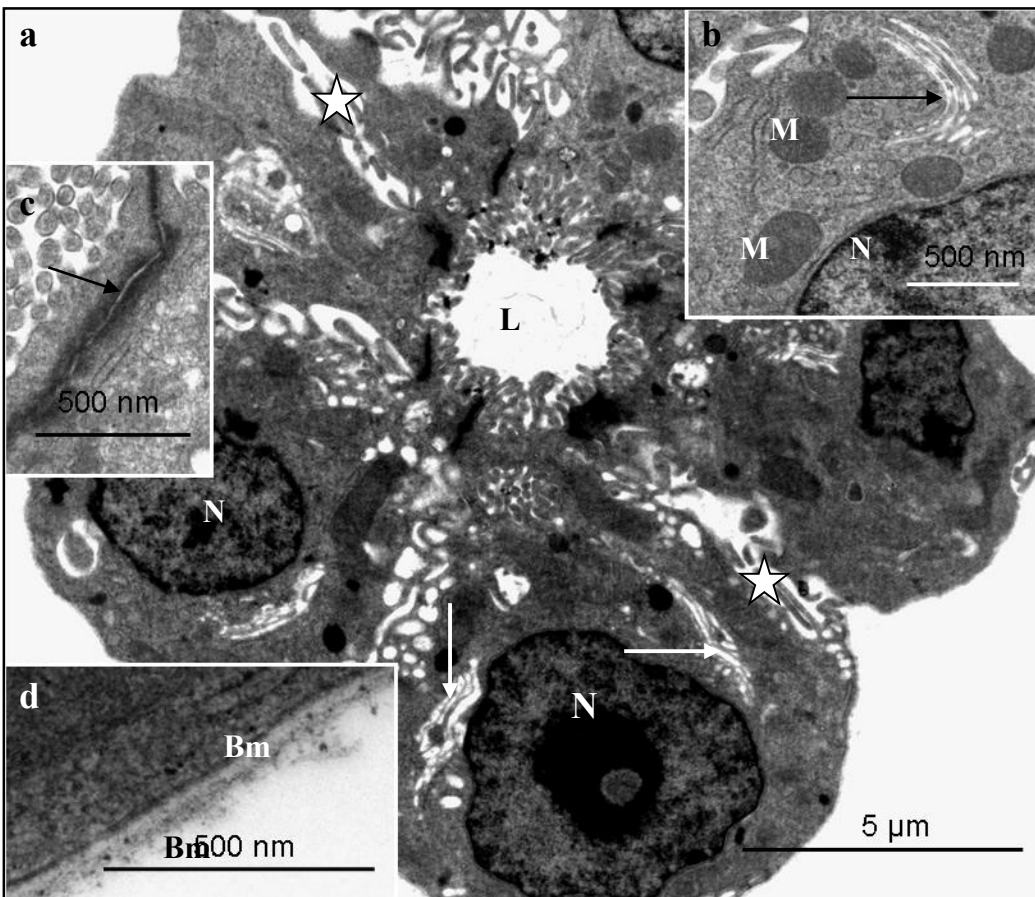


Fig. 4a. TEM photomicrograph of a SST from control bird. N: nucleus; arrows: golgi complexes; asterisks: processes along the lateral plasma membranes; L: glandular lumen. **b.** Golgi complex (arrow) and mitochondria (M) adjacent nucleus (N). **c.** Arrow: Desmosome. **d.** Bm: basal lamina supporting SST.

Carbendazim-treated birds

There were no ultrastructural changes observed in the SST cells at doses of 25 mg/kg and 100 mg/kg b.w.t. At a dose of 400 mg/kg b.w.t, the SST contained a few cells with pyknotic nuclei, numerous vacuoles and multi-granular bodies (Fig. 5a). In addition, there was an increased number of lysosomes in the apical cytoplasmic regions. In some instances, degenerating nuclei displayed chromatin condensation and margination. Desmosomes and microvilli on the apical plasma membrane were structurally normal. The basal lamina measured approximately 60nm thick. Both lamina densa and lamina lucida were clearly differentiated (Fig. 5b).

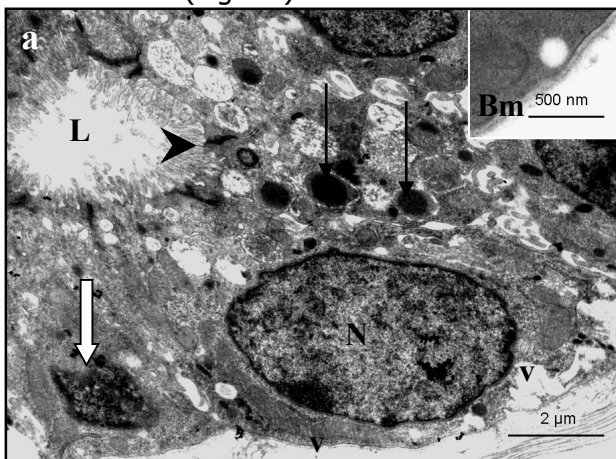


Fig. 5a. TEM photomicrograph of a SST from a bird treated with 400 mg/kg b.w.t. Open arrow: pyknotic nucleus; V: vacuoles; thin arrows: lysosomes; N: normal nucleus; arrowheads: desmosome; L: glandular lumen. **b.** basal region of the SST. Bm: basal lamina.

At a dose of 800 mg/kg bodyweight carbendazim, degenerating SST cells contained

large vacuoles in the basal cytoplasmic regions (Fig. 6a). Swollen mitochondria and numerous lysosomes were observed (Fig. 6b). A few secondary lysosomes were also identified. Nucleolar margination and condensation of nuclear chromatin characterized degenerating nuclei. At this dose, microvilli lining the apical plasma membrane were structurally normal. Desmosomes in this region were intact. However, there was reduced number and length of the lateral plasma membrane processes. The basal lamina underlying the SST cells was 68nm thick. No degenerative changes were observed in the basal lamina.

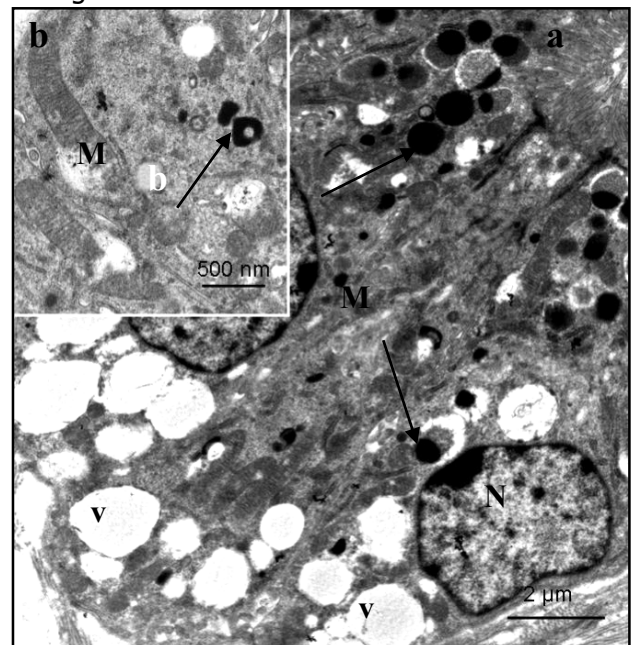


Fig. 6a. TEM photomicrograph of a SST from a bird treated with 800 mg/kg b.w.t. v: vacuoles; Arrows: lysosomes; N: nucleus. **b.** M: degenerating mitochondria; Arrow: secondary lysosome adjacent the swollen mitochondria.

DISCUSSION

The present investigation has highlighted the morphological changes that occur in the SST of the Japanese quail following exposure to methyl-2-benzimidazole carbamate. In this investigation, the results of morphometrical study show that, carbendazim exposure caused atrophy of SST. The atrophy of the SST observed, might cause reduction of the size, amount and storage period of spermatozoa in

carbendazim-exposed birds. This idea is supported by research findings in the domestic fowl (Birkhead and Moller, 1992). According to Birkhead and Moller (1992), there is positive correlation between the volume of SSTs and number of spermatozoa stored. The report further shows that, the size (length) of the SSTs correlates with the length of spermatozoa and duration of storage.

Based on histological results, the morphology of SST observed in the control group was generally consistent with published information in the Japanese quail (Frieß et al., 1978; Holm and Ridderstrale, 2002), domestic fowl (Tingari and Lake, 1973; Bakst, 1998) and turkey (Schuppin et al., 1984; Bakst, 1987). The results show that SST are tubular invaginations lined by simple columnar epithelium. Contrary to the observation made in the domestic fowl (Tingari and Lake, 1973; Das, 2003), no smooth muscle cells were observed around quail's SST. This observation confirms earlier finding by Frieß et al. (1978) in the Japanese quail. Following carbendazim exposure, degenerative changes such as pyknosis and cuboidal metaplasia were observed. Degeneration of SST cells may lead to impaired sperm storage potential in exposed birds.

It has been established that SSTs serve as sperm storage sites for the entire length of fertile period in birds (Schuppig et al., 1984; Pierson et al., 1988; Birkhead, 1992). Reduced number of spermatozoa and presence of empty SSTs observed in carbendazim-treated groups might impact negatively on the fertility of exposed birds. This is based on the fact that fertility in birds depends on the proportion of SST containing viable spermatozoa (Bilgili and Renden, 1984; McDaniel et al., 1981; Brillard and Antoine, 1990). According to these reports, fertility in the domestic fowl correlated to the number of spermatozoa attached to the perivitelline layer, which were influenced by proportion of SST containing spermatozoa.

In the current study, presence of empty SST could have been caused by sperm autolysis

due to epithelial secretion as reported in the domestic fowl by Koyonagi and Nishiyama (1981). However, sperm autolysis was not apparent in the present study. It is likely that empty SST were due to degeneration of spermatozoa as a result of carbendazim toxicity. Carbendazim has been shown to cause degeneration of spermatozoa in mammals (Hess and Nakai, 2000) and birds (Aire, 2005).

At ultrastructural level, the morphology of the SST in the control birds was in accordance to the findings by Frieß et al. (1978). Following carbendazim exposure, degenerating cells were common in the SST. In these degenerating gland cells, swollen mitochondria were frequently observed. Presence of swollen mitochondria suggests an increased cellular permeability induced by carbendazim through cytoskeletal damage. Heggeneset al. (1978) reported association of cytoskeleton and mitochondria. The report shows that, mitochondria are tightly connected with cytoskeletal elements. Destruction of cytoskeletal elements by colchicine or taxol increased mitochondrial membrane permeability in Ehrlich ascites tumour cells (Evtodienko et al., 1996). In addition, administration of colchicine induced release of *cytochrome c* in cultured cerebellar granule cells (Gorman et al., 1999). *Cytochrome c* is an apoptotic-inducing factor released by damaged mitochondria (Kroemer et al., 1998).

Based on the finding of this study, it is concluded that carbendazim causes pathological changes in the SST at high doses. Thus care must be taken when using this chemical in the field to avoid environmental contamination.

Acknowledgement

This study was funded by The South African Veterinary Foundation. The author thanks

Professors M-C Madekurozwa and HB Groenewald for their professional guidance.

REFERENCES

1. Aire TA. 2005. Short-term effects of carbendazim on the gross and microscopic features of the testes of Japanese quails (*Coturnix coturnix japonoca*). *Anat Embryol* 210:43-49.
2. Bakst MR. 1981. Sperm recovery from oviducts of turkeys at known intervals after insemination and oviposition. *J Reprod Fert* 62:159-164.
3. Bakst MR. 1998. Structure of the avian oviduct with emphasis on sperm storage in poultry. *J Exp Zool* 282:618-626.

4. Bilgili SF, Renden JA. 1986. Sperm release from the uterovaginal storage gland of the chicken: A perfusion study. *Theriogenol* 26:77-88.
5. Birkhead TR, Fletcher F. 1994. Sperm storage and release of sperm from the sperm storage tubules in the Japanese quail *Coturnix japonica*. *Comments* 136:101-105.
6. Birkhead TR. 1992. Sperm storage and the fertility period in the Bengalese finch. *Auk* 109:620-625.
7. Birkhead TR, Moller AP. 1992. Numbers and size of sperm storage tubules and the duration of sperm storage in birds: a comparative study. *Biol J Linnean Soc* 45:363-372.
8. Brillard JP, Antoine H. 1990. Storage of sperm in the uterovaginal junction and its incidence on the numbers of spermatozoa present in the perivitelline layer of hen's eggs. *B Poult Sci* 31:635-644.
9. Burke WH, Ogasawara FX, Fuqua CL. 1972. A study of the ultrastructure of the uterovaginal sperm storage glands of the hen (*Gallus domesticus*), in relation to a mechanism for the release of spermatozoa. *J Reprod Fert* 29:29-36.
10. Burland TG, Gull K. 1984. In: Trinci APJ, Riley JF, editors. *Mode of Action of Antifungal Agents*. Cambridge: University Press. p 299 - 320.
11. Chailley B, Nicolas G, Laine M-C. 1989. Organization of actin microfilaments in the apical border of oviduct ciliated cells. *Biol Cell* 67:81-90.
12. Cruz M-C, Edlind T. 1997. B-tubulin genes and basis for benzimidazole sensitivity of the opportunistic fungus *Cryptococcus neoformans*. *Microbiol* 143:2003-2008.
13. Das SK. 2003. Evidence for the innervation of sperm host glands (SHG) of native chicken's (*Gallus domesticus*) oviduct. *Int J Poult Sci* 2:259-260.
14. Evtodienko YV, Teplova VV, Sidash SS, Ichas F, Mazat JP. 1996. Microtubule- active drugs suppress the closure of the permeability transition pore in tumour mitochondria. *FEBS Lett* 393:86-88.
15. Frieb AE, Sinowatz F, Wrobel K-H. 1978. The uterovaginal sperm host glands of the quail (*Coturnix coturnix japonica*). *Cell Tiss Res* 191:101-114.
16. Fujii S. 1963. Histological and histochemical studies on the oviduct of the domestic fowl with special reference to the region of the uterovaginal juncture. *Arch Hist Jap*, 23:447-459.
17. Gorman AM, Banfoco E, Zhivotovsky B, Orrenius S, Ceccatelli S. 1999. Cytochrome c release and caspase-3 activation during colchicine-induced apoptosis of cerebellar granule cells. *Eu J Neurosci* 11:1067-1072.
18. Heggeness MH, Simon M, Singer SJ. 1978. Association of mitochondria with microtubules in cultured cells. *Proc Nat Acad Sci USA*, 75:3863-3866.
19. Hess RA, Nakai M. 2000. Histopathology of the male reproductive system induced by the fungicide benomyl. *Hist Histopath* 15:207-224.
20. Holm L, Ridderstrale Y. 2002. Development of sperm storage tubules in the quail during sexual maturation. *J Exp Zool* 292:200-205.
21. Kimaro WH, Madekurozwa M-C, Groenewald HB. 2013. Histomorphometrical and ultrastructural study of the effects of carbendazim on the magnum of the Japanese quail (*Coturnix coturnix japonica*). *Onderst J Vet Res* 80:1-17.
22. Koyonagi F, Nishyama H. 1981. Disintegration of spermatozoa in the infundibular sperm host glands of the fowl. *Cell Tiss Res* 214:81-87.
23. Kroemer G, Dallaporta B, Resche-Regon M. 1998. The mitochondrial death/life regulator in apoptosis and necrosis. *Ann Rev Physiol* 60:619-642.
24. McDaniel GR, Brake J, Eckman MK. 1981. Factors affecting broiler breeder performance. 4. The interrelationship of some reproductive traits. *Poult Sci* 60:1792-1797.
25. Ogasawara FX, Fuqua CL. The vital importance of the uterovaginal sperm host glands for the turkey hen. *Poult Sci* 51:1035-1039.
26. Pierson EEM, McDaniel GR, Krista LM. 1988. Relation ship between fertility duration and in vivo sperm storage in broiler breeder hens. *Br Poult Sci* 29:199-203.

27. Sandoz D, Gounon P, Karsenti E, Boisvieux-Ulrich E, Laine M.-C, Paulin D. 1983. Organization of intermediate filament in ciliated cells from quail oviduct. *J Submicrosc Cytol* 15:323-326.
28. Schuppig GT, van Krey HP, Denbow DM, Bakst MR, Meyer GB. 1984. Ultrastructural analyses of uterovaginal sperm storage glands in fertile and infertile turkey breeder hens. *Poult Sci* 63:1872-1882.
29. Tingari MD, Lake PE. 1973. Ultrastructural studies on the uterovaginal sperm host glands of the domestic hen, *Gallus domesticus*. *Journal of Reproduction and Fertility*, 34:423-431.