

Reproductive Biomarkers of Endocrine Disruption in Adult Male *Clarias Gariepinus* Exposed to Sub-Lethal Carbendazim

Aina, Oluwasanmi Olayinka¹, Ozegbe Peter Chuka¹, Adeyemo Olanike Kudirat²

Affiliations:

¹. Department of Veterinary Anatomy, University of Ibadan, Ibadan, Nigeria

². Department of Veterinary Public Health and Preventive Medicine, University of Ibadan, Ibadan, Nigeria.

Corresponding Address: Dr O.O. Aina. Department of Veterinary Anatomy, University of Ibadan, Ibadan, Nigeria.

Email:ainasanmi@gmail.com. Phone +2348130555438

ABSTRACT

This study investigated the morphophysiological effects of Carbendazim in the adult male African catfish (*Clarias gariepinus*). After exposure to a pre-determined sub-lethal concentration (1.4 mg/L) of carbendazim for seven and fourteen days, plasma testosterone and 11-ketotestosterone, the gonadosomatic indices were determined. Histomorphometry and histochemistry of the testes was studied using light microscopy after staining with Hematoxylin-Eosin, Masson's Trichome and Periodic Acid Schiff. Testicular tissues harvested at day 14 were fixed in glutaraldehyde and processed for transmission electron microscopy according to standard procedures. All the treated groups showed significant phase dependent alterations, day 14 being more pronounced. The gonadosomatic indices were decreased. Significant decreases, relative to corresponding controls at day 14, were observed in testosterone and 11-ketotestosterone levels. Histological and ultrastructural studies revealed germinal and Sertoli cell degeneration and necrosis, displacement of Sertoli cysts, capillary endothelial wall necrosis and basement membrane disruption in the testis of the treated groups. There were significant reductions in testicular germinal depth and interstitial width in 14-day treated groups compared to its corresponding control. Carbendazim, at sub-lethal dose, induced histological and ultrastructural changes in the testes of the male African catfish. It also led to altered gonadosomatic index; reduced levels of plasma testosterone and 11-ketotestosterone levels.

Keywords: Carbendazim, Carbendazim, *Clarias gariepinus*, ultrastructure, Histomorphology

INTRODUCTION

Environmental pollution is listed as one of the most significant problems of the twenty first century. Increased introduction of toxic agents into the environment can adversely affect the habitability of the entire planet in the long run. Even before then, evidence abounds, with respect to destructive biological changes in plant and animal species induced by the presence of these toxic agents (Wogan, 1966; Hellawell, 2012; Mooney and Drake, 2012). Endocrine-disruptors rank among general ecotoxins of concern which may adversely affect wildlife, domestic livestock and human populations with respect to general well being and optimum reproductive performance (Thomas and Colborn, 1992;

Sung, and Ye, 2009). The mode in which endocrine disruptors adversely affect both mammalian and aquatic life is believed to be by modulation of endocrine functions (Lerner *et al.*, 2007).

Several chemicals used in agriculture as pesticides and herbicides rank among these pollutants and have been proven to have deleterious effects in animals that are exposed to them in varying quantities (Aire, 2005). Increased agricultural activity and resultant application of these pesticides for agricultural and non-agricultural purposes has also led to increased incidence of pollution of air, soil, ground and surface water.

Submitted 14th November 2015, corrected 5th December 2015. Published online 7th March 2016. To cite: Aina O, Ozegbe PC, Adeyemo OK. 2016 Reproductive Biomarkers of Endocrine Disruption in Adult Male *Clarias gariepinus* Exposed to Sub-Lethal Carbendazim. Anatomy Journal of Africa. 5: 672 – 685.

Carbendazim (Methyl 2-benzimidazole carbamate) is an endocrine disrupting chemical (Lu *et al.*, 2004; Aire, 2005). It is a broad spectrum systemically active fungicide used for pre- and post-harvest protection of food crops, fruits and vegetables.

Carbendazim has been shown to be gonadotoxic in previous studies especially on mammals and avians; inducing decreased testicular weight (Earl *et al.*, 1990; Nakai *et al.*, 1992; Lu *et al.*, 2004; Rajeswary *et al.*, 2007); decreased viability and population of sperm cells (Earl *et al.*, 1990; Nakai *et al.*, 1992; Lu *et al.*, 2004); testicular degeneration and necrosis (Nakai *et al.*, 1992; Junghee and Marion, 1997; Lu *et al.*, 2004; Aire, 2005; Ozegbe and Aina, 2012); decreased androgenesis (Earl *et al.*, 1992; Rajeswary *et al.*, 2007; Ozegbe and Aina, 2012).

The mode of carbendazim's gonadotoxic actions has been linked to disruption of microtubule assembly (Can and Albertini, 1997; Junghee and Marion, 1997), and androgen and androgen receptor mechanisms (Lu *et al.*, 2004). Aquatic ecotoxicity of carbendazim varies across age and species gradient (WHO, 1993).

This is also altered by changes in water temperature, pH, and hardness (Palawski and Knowles, 1986; WHO, 1993)

Carbendazim dressed fields could cause contamination of fish culture establishments located near farm lands. Also, there is the strong possibility of surface run-off of carbendazim - contaminated water from used containers and equipment. Earthen ponds and rivers where African catfish ACF cultivation is carried out could get exposed. Carbendazim -dressed crops are also used as feedstuff in commercial production of cultured fish. In earlier studies of aquatic exposure to carbendazim, (WHO, 1993; Dang and Smit, 2008; Andreu *et al.*, 2011), mortality and bioaccumulation was the main biomonitoring factors used in the of assessment of carbendazim's toxicity to fish. Detailed studies describing the alteration in the reproductive milieu of carbendazim-treated aquatic species, as already documented in mammals and birds, are not available. This paper describes the experimentally induced gonadotoxic effects of carbendazim in adult male African Catfish (*Clarias gariepinus*) exposed to a sub lethal dose.

MATERIALS AND METHODS

Carbendazim (100 g) with the identification name CAS 10605-21-7, C₉H₉N₃O₂; FW 192.19; MP 300°C) and 97% active ingredient was obtained from Aldrich Chemical Company Inc., Milwaukee, USA. The sub-lethal dose was determined by a previous study using Lorke's (1983) method. The daily required weight of powder was determined using a digital balance (Scout Pro. SPU 402, OHAUS Corporation, Pine Brook, New Jersey, USA), solubilised in 15 ml of water before being introduced into the plastic containers containing the test animals

The Fish

Twenty 10-week old, male African Catfish (*C. gariepinus*) with weights of 270±11.28 g were used. They were acclimatized in

well water for seven days in aerated 400 litre plastic containers. The fish were stratified by initial body weight and assigned randomly to one of four treatment groups as shown in Table 1. Sample collection was carried out on the seventh and fourteenth day of exposure to the pesticide. The dose was determined by a pilot study, and carried out by static renewals which involved 100% water and carbendazim renewal every other day.

Determination of Behavioural changes and Gonadosomatic Index

Fish in different groups were monitored and evaluated for behavioural alterations like alertness, and attraction to feed. The body weight of individual fish was determined at each day of collection. The

gross weights of the fish were taken using a digital balance (Scout Pro®. SPU 402, OHAUS Corporation, Pine Brook, New Jersey, USA). Fishes were sedated by cold shock method and sacrificed by cervical dislocation. The testes were wiped dry of fluid, using filter paper and weighed. The relative weights of the testes were calculated as a percentage of the body weight (gonado-somatic index).

Specimen collection and histology

Testicular tissues obtained from both groups (treated and control) and on treatment days (seven and fourteenth), were harvested and fixed in Bouin's fluid for 24 hours and then transferred to 70% ethanol. Fixed tissues were processed routinely using paraffin embedding technique. From each block, sections of 5µm thickness were cut using a Reichert Jung 2030© microtome. The mounted specimen slides were stained with Harris' Hematoxylin and Eosin stain (H & E); Masson's Trichrome (TRI) stain according to Bancroft and Steven, (1990) and Periodic Acid Schiff (PAS). Stained sections were visualized and studied using a digital microscope (Zhejiang, China).

Histomorphometry

Slides were examined under the microscope and the following measurements were taken: the relative depth of the germinal epithelium, interstitium and lumen of the seminiferous tubules; the seminiferous tubular

diameter. For each parameter, ten measurements were made per section using a TSView® Software (Microscopes, America inc. USA).

Ultrastructural Studies using Transmission Electron Microscopy

Testicular tissues obtained from each of MW2 and MC2 groups were fixed in glutaraldehyde (0.1 M Sodium cacodylate buffer at pH 7.2) for 4 hours at 4 °C. They were then thoroughly washed in the same buffer, post-fixed in 1% osmium tetroxide, and dehydrated in a graded series of ethanol solutions. Tissues were then cleared with propylene oxide, infiltrated with a 1:1 solution of propylene oxide: epoxy resin, 1:2 solution of propylene oxide: epoxy resin, and then placed in 100% epoxy resin for 36 hours under vacuum. The samples were embedded in fresh epoxy resin and cured at 60 °C for 48 h. Semi- thin sections were stained with Toluidine blue and observed under the light Microscope (Olympus BX63 + DP72). Thin sections (70-80 nm) were cut with a diamond knife on an ultramicrotome (Ultracut- Rechart, Austria), double-stained with uranyl acetate and lead acetate. They were examined under the transmission electron microscope (Philips CM 10 TEM) operating at 80 kv. Analysis and assembling of composite micrographs were carried out using Adobe Photoshop CS5 (Adobe Systems, San Jose, CA).

Table 1: **Group design of exposure and duration of experiment**

Group	Treatment (dose)	Duration (days)
MW1	Water	7 days
MC1	Carbendazim (1.4mg/l)	7 days
MW2	Water	14 days
MC2	Carbendazim (1.4mg/l)	14 days

Hormone determination

Three ml of blood samples were collected from the caudal vein using 5 ml plastic syringes put in Lithium heparinised sample bottles. They were centrifuged at 3000rpm for 15 minutes using a centrifuge (CF-405 Gallenamp, England). The supernatant was collected for biochemical assay for testosterone and 11 Keto Testosterone, using commercially available kits (Interco Diagnostic Ltd. ®, United Kingdom).

Statistical analysis

Statistical analysis was performed using Graph Pad Prism 4 software. The data was analyzed using two-way ANOVA test followed by multiple comparison test (Duncan, Turkey). Results were presented as mean ± SEM. The level of significance was set as $p < 0.05$.

Gonadosomatic Index

The result of the gonadosomatic index is presented in Figure 1. The mean gonadosomatic index of the MC1 and MC2 groups were significantly lower ($p < 0.05$) than the corresponding MW1 and MW2 groups respectively.

Histopathology of the testis

The results of the histopathological examination are presented in Figures 2 and 3. The control groups did not present visible lesions. The histological feature of the normal seminiferous tubules is characterized by a thin connective tissue surrounding immature spermatogenic stages, which are enclosed by sertoli cysts (cytoplasmic extensions of the sertoli cells). The mature spermatozoa are present abundantly in the lumen.

RESULTS

The testes in the carbendazim-treated group on the seventh day showed cytoplasmic disruption of sertoli cysts. Normal feature of embedded immature cells in the cysts were absent in most of the sections. While 'spent' seminiferous tubular sections were the normal stages in a fish's testis, whereby the lumina of several tubules are devoid of mature spermatozoa, there are more spent seminiferous tubules (arrows) than viable filled ones in this group. In the fourteenth day carbendazim-treated group, there was severe germinal cell necrosis and loss of sertoli cysts of the testes. Clumps of cellular materials and debris were found in the lumen. Very few seminiferous sections had discreet cellular populations of spermatozoa in the lumina.

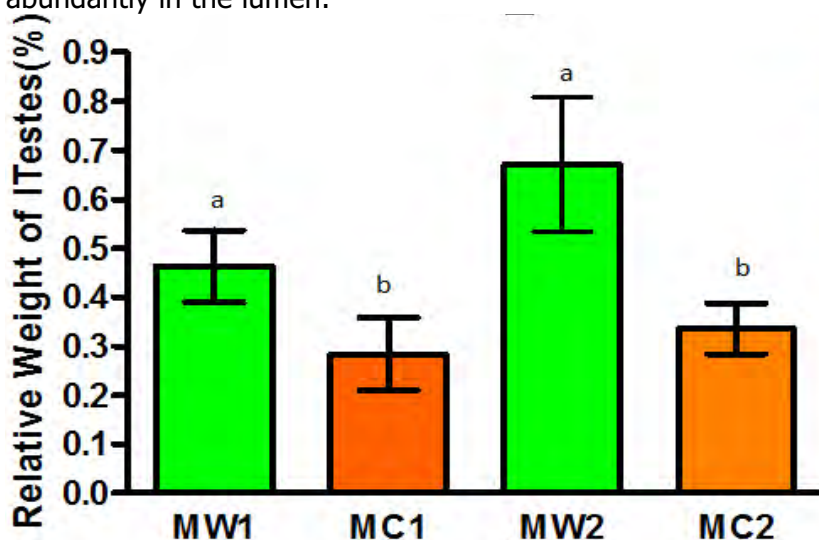


Figure 1: Relative weight of the Testes (%) in Male African Catfish (M) which was exposed to either Water (W) or Carbendazim (C). Values are presented as Mean ± SEM. Values with different superscripts are significantly different ($p < 0.05$)

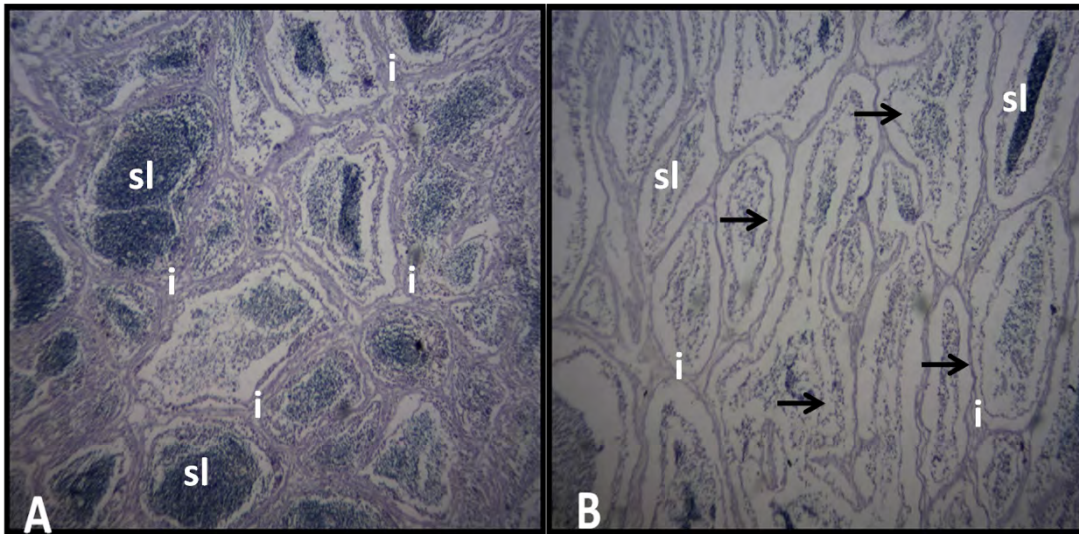


Figure 2: Light micrograph of the Testes of Carbendazim-treated male African Catfish **A: MW1** Control group showing no visible lesions in the seminiferous lumina (sl) and interstitium (i). **B: MC1** Treatment group showing disruption of Sertoli cysts. There are more spent seminiferous tubules (arrows) than viable ones. H&E Mag x100

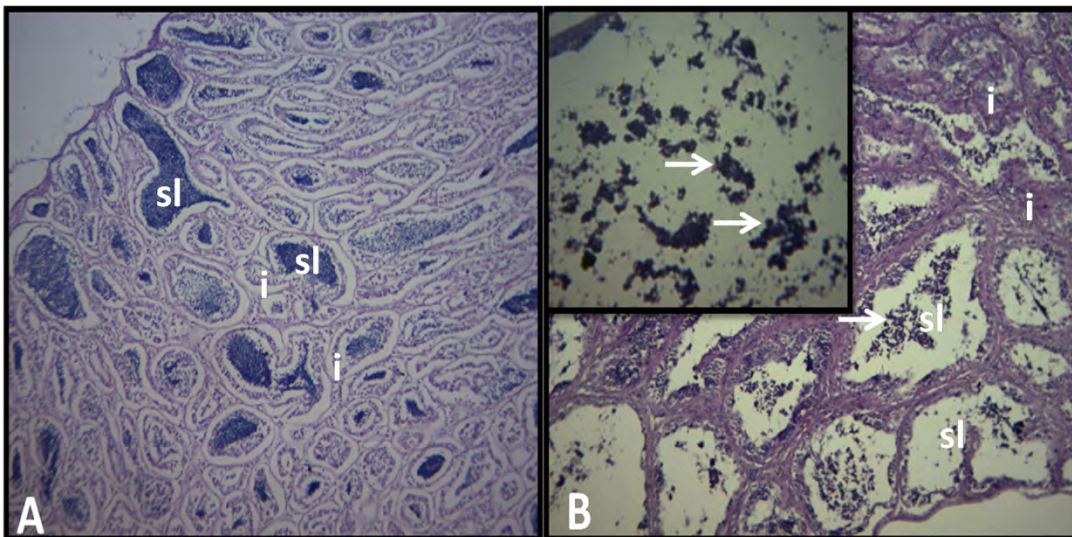


Figure 3: Light micrograph of the Testes of Carbendazim-treated male African Catfish **A: MW2** showing no visible lesions in the seminiferous lumina (sl) and interstitium (i). **B: MC2** showing severe germinal cell necrosis and loss of sertoli cysts (arrows). Clumps of cellular materials and debris are found in the lumen (arrowed in inset M x400) H&E Mag x100

Histomorphometry

The results of the histomorphology of the germinal depth and Interstitial width of the testes are presented in figures 4 and 5. There was a significant reduction in the germinal depth of MC2 compared to its corresponding control (MW2). The results of the histomorphology of the interstitial width of the testes in the four different groups are

presented in figure 5. There was a significant reduction in the interstitial width of the carbendazim treated group at fourteen days of treatment (MC2) compared to its corresponding control group (MW2). There were no significant differences between both treatments (MC1 and MC2) and both control groups (MW1 and MW2).

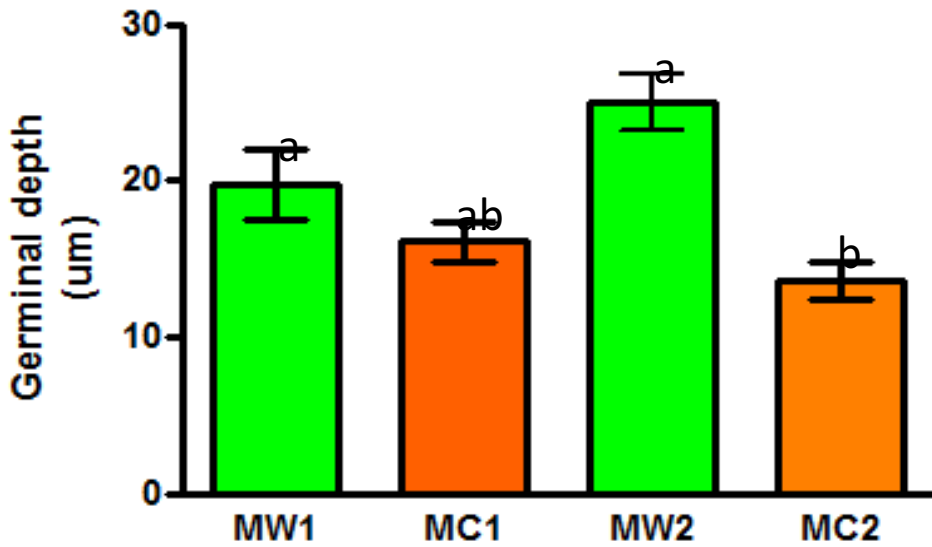


Figure 4: Germinal depth of the Testis (um) of Male African Catfish (M) which was exposed to either Water (W) or Carbendazim (C). Values are presented as Mean \pm SEM. Values with different superscripts are significantly different ($p < 0.05$)

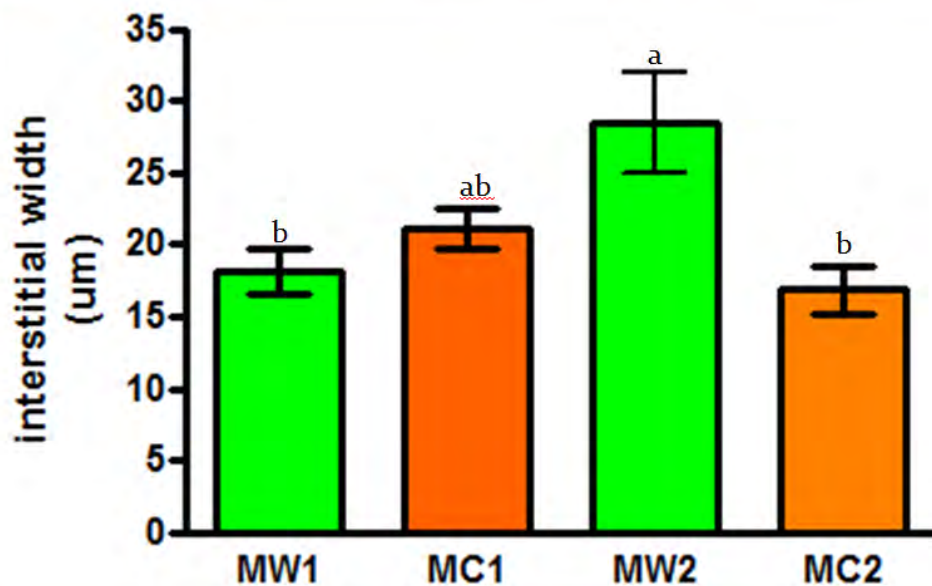


Figure 5: Interstitial width of the Testis (um) of Male African Catfish (M) which was exposed to either Water (W) or Carbendazim (C). Values are presented as Mean \pm SEM. Values with different superscripts are significantly different ($p < 0.05$).

Histochemistry: Masson’s Trichome (MT)

The results of the histochemical evaluation of the testes with Masson’s Trichome stain are presented in Figures 6 and 7. Apart from the histological features already mentioned with the H&E staining, the results of MT staining revealed a collagen rich interstitium of the African Catfish testis and The also showed/accentuated a light staining characteristic background formed by a luminal meshwork supporting the germinal cysts. Through this, a reduced interstitial width of the testicular interstitium was deduced in the sections from the carbendazim-treated groups (MC1 and MC2) when compared with the untreated control groups (MW1 and MW2). Similarly, there was a reduced MT staining intensity in the interstitium of the testis of carbendazim treated groups compared to the control groups. Also the testicular disruption in the carbendazim treated groups previously seen under Hematoxylin and Eosin was accentuated with Masson’s Trichome staining.

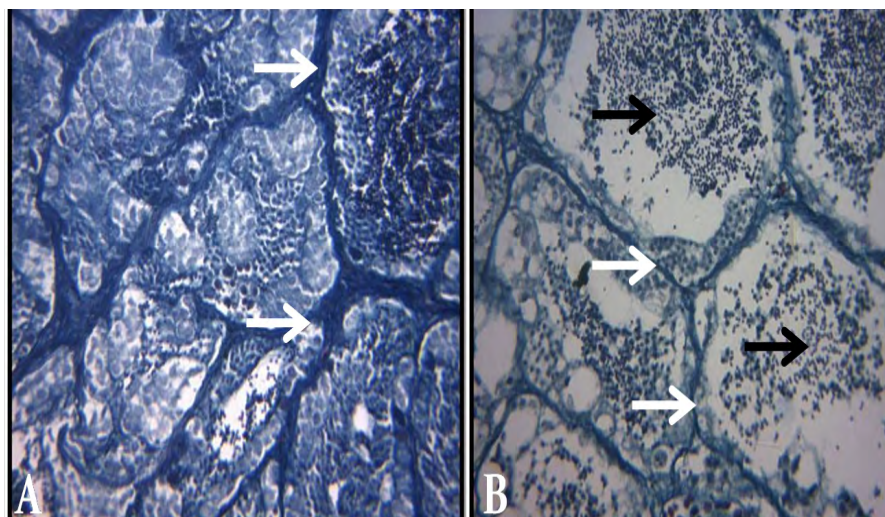


Figure 6: Light micrograph of the Testes of Carbendazim-treated male African Catfish on the seventh day of treatment **A: MW1** Control group showing no visible lesions in the seminiferous lumina and interstitium (white arrows) **B: MC1** Treatment group showing disruption in the architecture of the germinal epithelium (black arrows). **MT** Mag x 400.

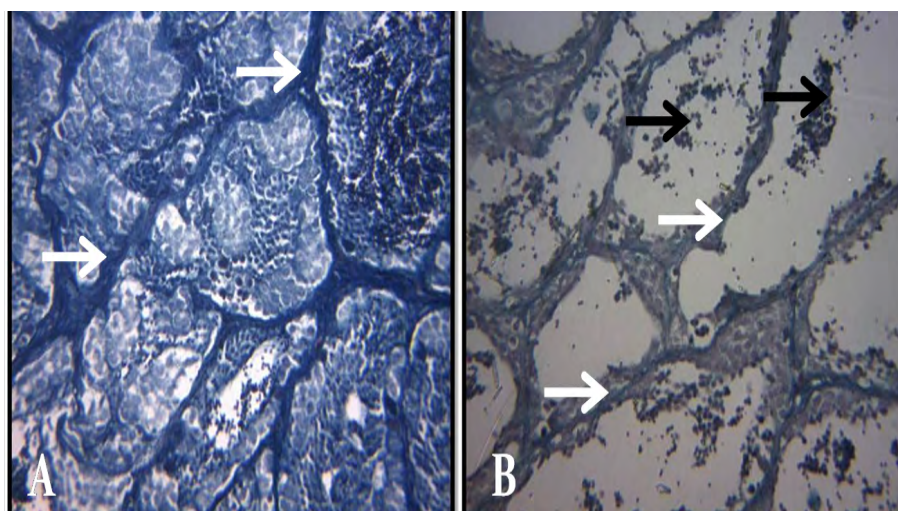


Figure 7: Light micrograph of the Testes of Carbendazim-treated male African Catfish on the fourteenth day of treatment **A: MW2** Control group showing no visible lesions in the seminiferous lumina and interstitium (white arrows) **B: MC2** Treatment group showing disruption of entire germinal epithelium and luminal debris (black arrows). **MT** Mag x 400

Periodic Acid Schiff (PAS) Staining

The results of the histochemical evaluation of the testes with Periodic Acid Schiff stain are presented in Figures 8 and 9. An evidence of distorted germinal epithelium and rich presence of carbohydrates in the interstitium and germinal cells of the African Catfish testis was achieved with PAS stain. Additionally, reduced thickness as well as the staining intensity of the

testicular interstitium was deduced in the sections from the carbendazim-treated groups (MC1 and MC2) when compared with the control groups (MW1 and MW2). However, the germinal cells had a uniform depth of staining in all the groups. The reduction in intensity and width could be ascribed to change in quantity and distribution of the carbohydrate moiety in the structure of the testis.

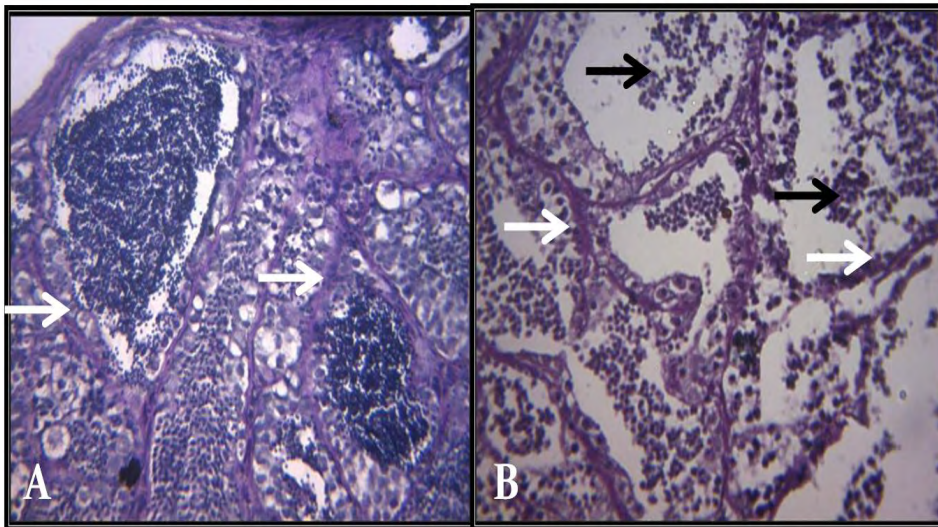


Figure 8: Light micrograph of the Testes of Carbendazim-treated male African Catfish on the seventh day of treatment **A: MW1** Control group showing no visible lesions in the seminiferous lumina and interstitium (white arrows) **B: MC1** Treatment group showing disruption of Sertoli cysts, with 'floating' germinal structures and debris in the lumina (black arrows). **PAS** Mag x 400

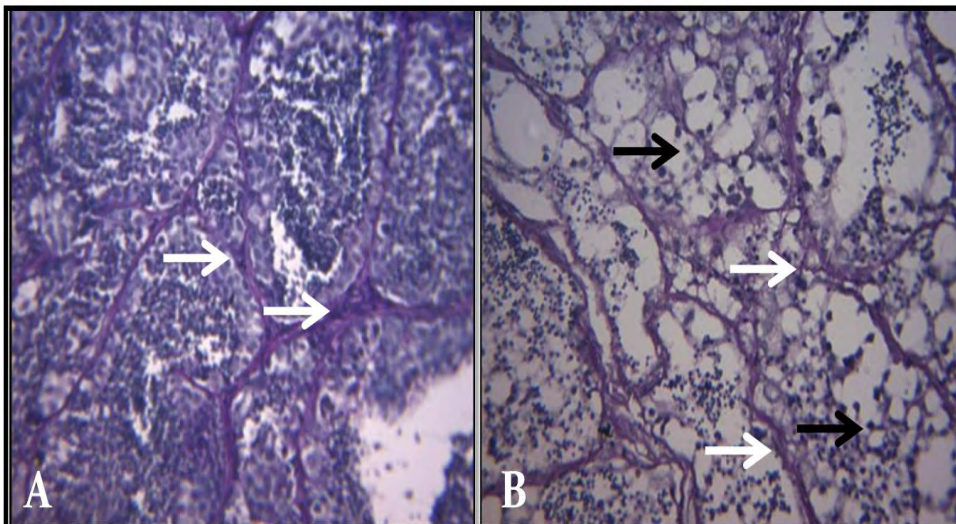


Figure 9: Light micrograph of the Testes of Carbendazim-treated male African Catfish on the fourteenth day of treatment **A: MW2** Control group showing no visible lesions in the seminiferous lumina and interstitium (white arrows) **B: MC2** Treatment group showing disruption of entire germinal epithelium and luminal contents, with emptied Sertoli cysts (black arrows). **PAS** Mag x 400

Ultrastructure

The results of the ultra-structural study are shown in figures 10 to 13. The main features presented are the developing germ cells enclosed in the Sertoli cysts and the testicular interstitium of the testes. The germinal epithelium of the control fish at fourteen days of exposure (MW2) had normal developing germ cells, the cross sections of the Sertoli cell processes were also seen in the micrograph. Normal cross section of blood vessels highlighting the lumen with

nucleated erythrocytes and a normal endothelium was also documented.

Contrary to these, the germinal epithelium of the carbendazim-treated fish at fourteen days of exposure (MC2) had total distortion of the germ cells and Sertoli processes. The affected germ cells had prominent vesicles scattered in the cytoplasm. There was a feature of displaced matured spermatozoa near the basement of the germinal epithelium. The basement membrane of the

seminiferous tubules were also distorted, presenting several finger-like processes

The testicular interstitium also had cross section of blood vessels highlighting empty lumina. The walls of the vessels were severely distorted and the endothelial cells severely necrotic.

Endocrinology

The results of hormonal assay for plasma testosterone in the four treatment groups (MW1, MC1, MW2, MC2) are presented in Figure 14. There was a very significant decrease ($P < 0.001$) in the mean plasma testosterone levels in carbendazim treated

group at fourteen days (MC2) compared to the seven days of carbendazim treatment group (MC1). There was also a non-significant time related reduction between the control untreated groups (MW1 and MW2). The mean testosterone value of MC1 was increased relative to MW1, but the mean testosterone value MC2 was reduced relative to its corresponding control u group (MW2). There was no statistical significance between the groups sampled on the same day. Also there was no significant difference between the two control groups (MW1 and MW2).

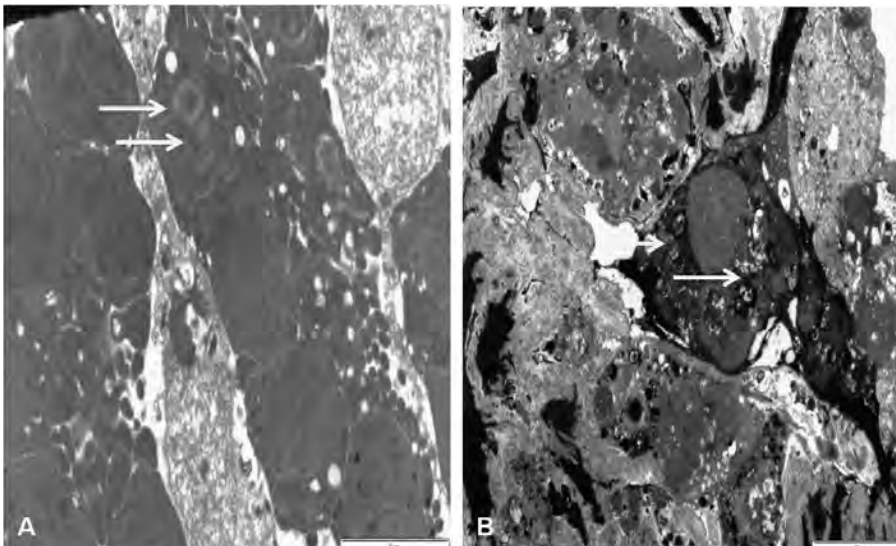


Figure 10: Electron micrograph of Liver of Carbendazim-treated ACF A:MW2 showing normal germinal cells (white arrows) enclosed in cysts (black arrows) B:MC2 showing severe necrosis of the germinal epithelium (white arrows) ,turning it into a nearly homogenous mass. There is a head of a spermatozoa displaced to the basement membrane (long arrow).

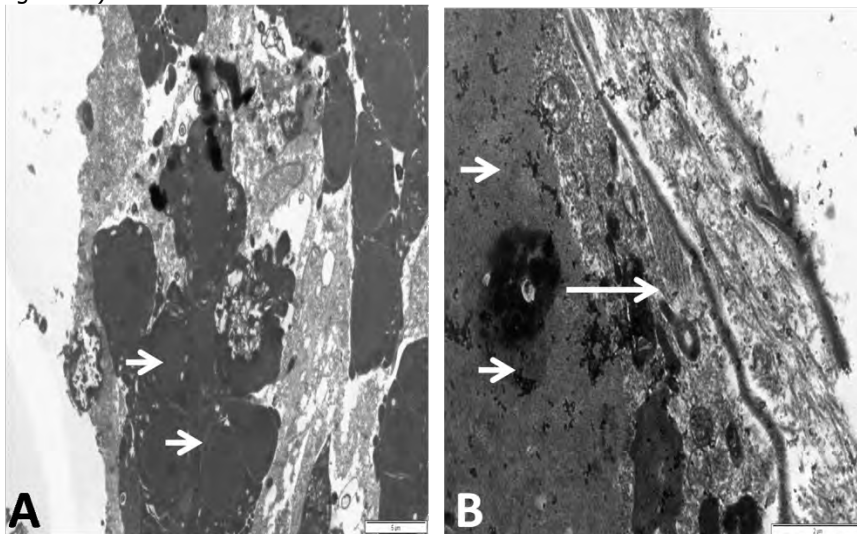


Figure 11: Electron micrograph of the Testis of Carbendazim-treated ACF A: MW2 showing normal Sertoli cells (arrows) B: MC2 Showing a very prominent Sertoli cell with cytoplasmic debris (arrows).

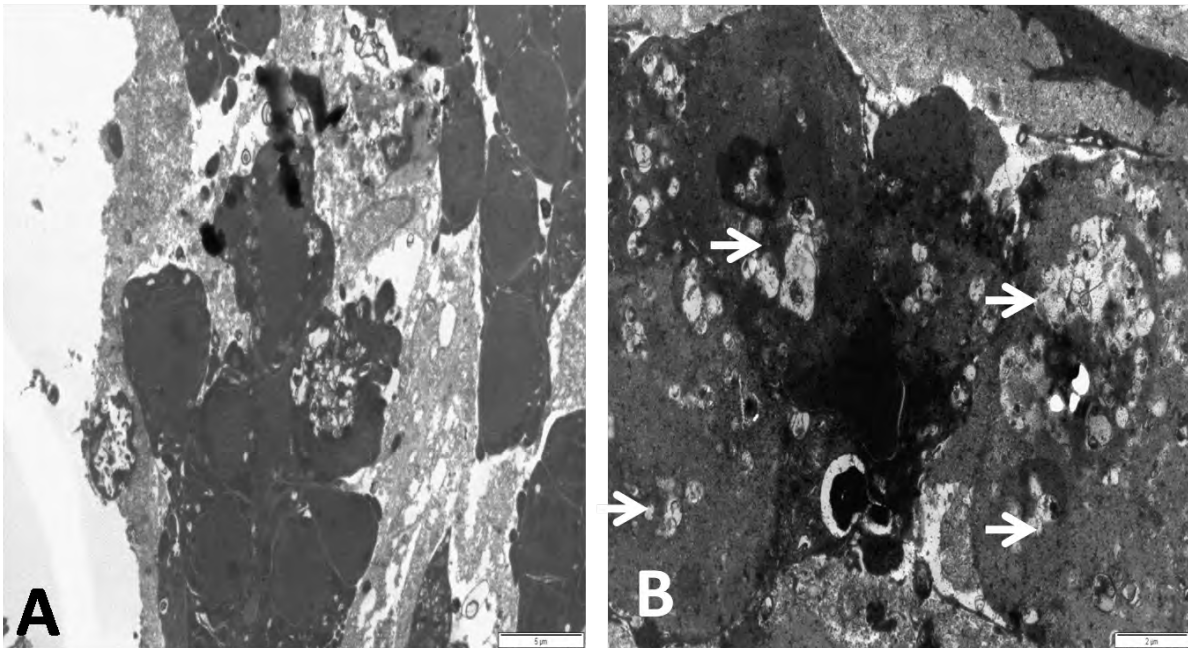


Figure 12: Electron micrograph of Testis of Carbendazim-treated ACF A: MW1 showing normal germinal cells (black arrows) enclosed in cysts (white arrows) B: MC2 prominent cytoplasmic vesiculations of the degenerate germinal cells (arrows)

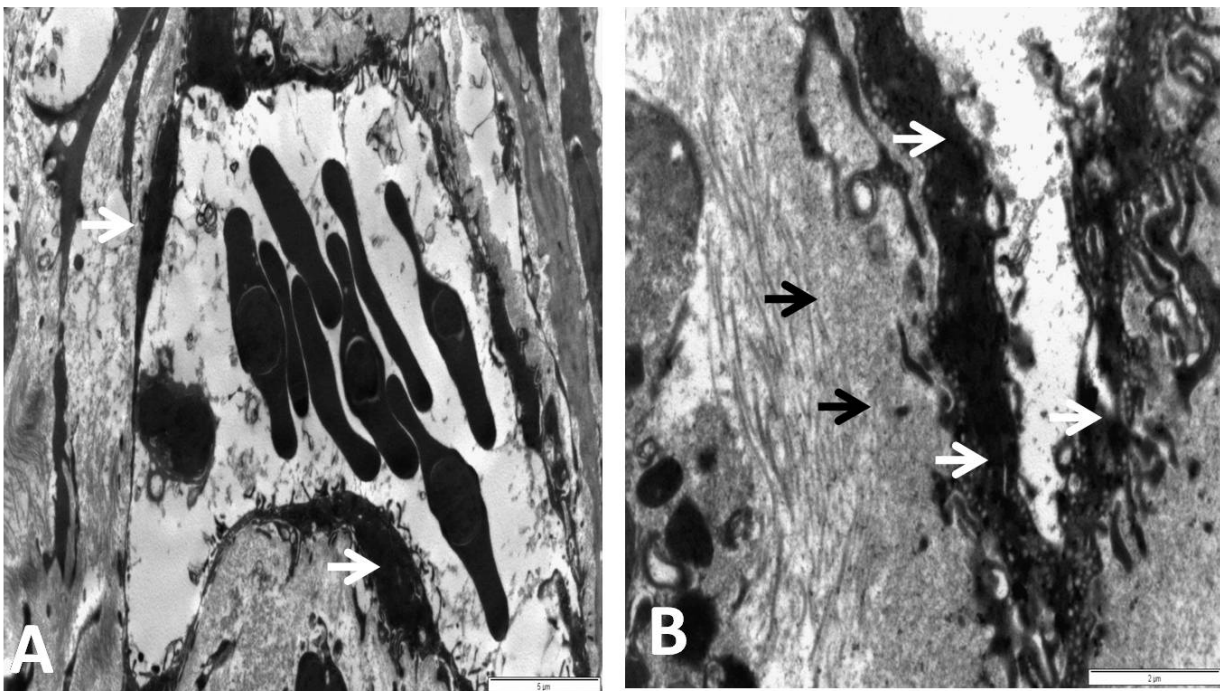


Figure 13: Electron micrograph of the Testis of Carbendazim-treated ACF A: MW2 showing normal endothelial cells of an interstitial blood vessel (white arrows) filaments are not visible in the interstitium (black arrows) B:MC2 showing severe necrosis and disruption of the endothelial walls (white arrows) Clumped filaments prominent in the interstitium (black arrows)

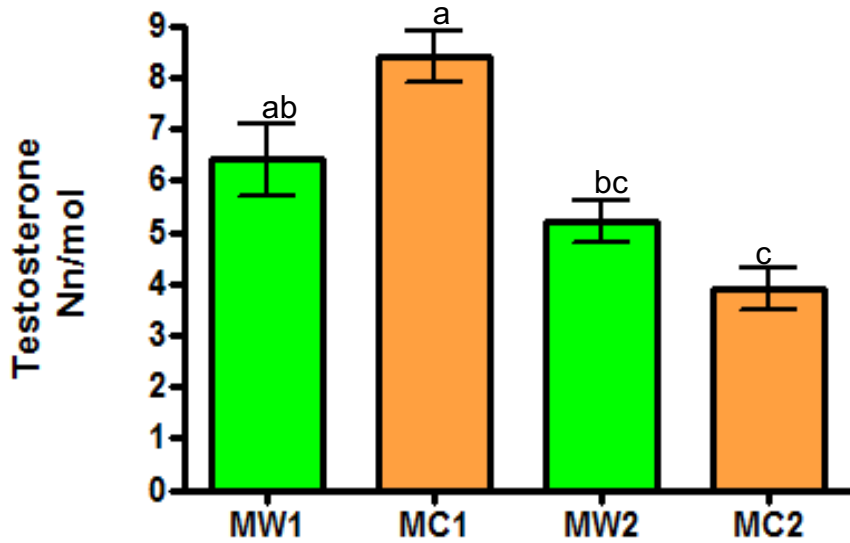


Figure 14: Mean Plasma Testosterone values (Nn/mol) of Male African Catfish (M) which was exposed to either Water (W) or Carbendazim (C). Values are presented as Mean \pm SEM. Values with different superscripts are significantly different ($p < 0.05$; $p < 0.001$)

The results of hormonal assay for plasma 11-Keto testosterone are presented in Figure 15. There was a significant reduction ($P < 0.05$) in mean plasma 11-KetoTestosterone levels in carbendazim treated fish at fourteen days (MC2)

compared to carbendazim treated fish at seven days (MC1). There was no significant change in the mean values between the seven and fourteen days of control groups (MW1 and MW2, respectively).

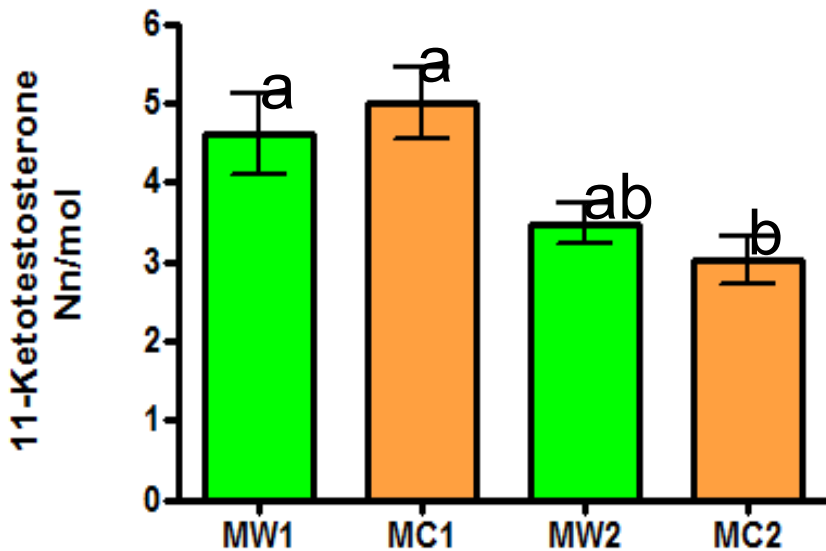


Figure 15: Mean Plasma 11-KetoTestosterone values (Nn/mol) of Male African Catfish (M) which was exposed to either Water (W) or Carbendazim (C). Values are presented as Mean \pm SEM. Values with different superscripts are significantly different ($p < 0.05$)

DISCUSSION

This study adds credence to previous studies on the reproductive and endocrine disruptive activity of Carbendazim across species. Reduced testicular weight and testicular abnormalities seen is in agreement with multiple-dose studies in

rats and dogs (Barnes *et al.* 1983; Carter *et al.* 1987; Linder *et al.* 1988; Hess and Nakai 2000; Rajeswary *et al.* 2007). Similarly in these studies, the severity of the lesions was perceived to occur in a phase dependent manner.

In this study histological and ultrastructural studies revealed degenerated and necrotic germinal and Sertoli cysts. Displacement of Sertoli cysts, capillary endothelial wall necrosis and basement membrane disruption were also observed in the treated testes. Similar features have been reported in mammals (Hess and Nakai, 2000; Kadalmani *et al.*, 2002; Lu *et al.*, 2004; Markelewicz *et al.*, 2004) avians (Aire, 2005; Moffit *et al.*, 2007; Ozegbe and Aina, 2012).

An additional pathology the ultrastructural study revealed in carbendazim treated fish was severe necrosis of the endothelial wall in the interstitium of affected testes. This could be due to a possible breach of the blood-testis barrier and the attendant degeneration of the tissues, especially when secondary pathogens cross over to elicit testicular pathologies that might not be directly associated with carbendazim.

There is a correlation between the phase dependent, significant reduction in plasma levels of the hormones – testosterone and 11-Keto testosterone and the testicular pathology. This corroborates the study of other endocrine disruptors in African catfish (Sayed *et al.*, 2012), and the reproductive pathology of carbendazim in other species (Akbarsha *et al.*, 2000; Aire, 2005; Ozegbe and Aina, 2012). In these works, down regulation of male hormones were similarly highlighted. The dynamics of synthesis and interrelationships of these two androgens and the control of their bioavailability are very essential to the regulation of pubertal development in male African Catfish (Cavaco, 2005).

Several works highlighting the pathological effects of carbendazim in fish have been done, ranging from sensitivity, bioconcentration and mortality (Gillet and Roubaud, 1983; Palawski, and Knowles, 1986; Cuppen *et al.*, 2000; Rico *et al.*, 2011), to morphological and biochemical changes (Sridhar and Joice, 2012; Nwani

et al., 2015) This study appears to be the first to highlight in detail the male gonadotoxic effects in-depth as described for mammals and avians.

The PAS and MT stains accentuated the interstitium of the seminiferous tubules of catfish. Through this, a reduced inter-tubular width of the testicular interstitium was deduced in the sections from the carbendazim-treated groups when compared with the control. Similar inferences could also be made as the intensity of staining appears deeper in the untreated control groups compared to the carbendazim-treated groups. The reduced MT and PAS staining intensity of the carbendazim treated groups could be due to the loss of carbohydrate moiety and connective tissue disruption, respectively.

The collagen fibre integrity of fish testes was also affected by carbendazim treatment. Ultrastructural studies further affirmed in detail the pathology induced by carbendazim in the testes of African catfish. Transmission electron microscopy revealed distorted sertoli cysts and degenerate germ stages; there was a focus which showed a sperm head of displaced spermatozoa at the basement membrane signifying total loss of the seminiferous architecture.

This study is also significant in its use of sublethal concentrations as studies have shown that a much larger percentage of living species suffer from mild non lethal exposures than severe episodes involving higher level of exposures (Jeyaratnam, 1993; Miller 2004).

In conclusion, significant reduction in mean gonadosomatic index supported by testicular and hormonal alterations induced by sub-lethal carbendazim dose could have dire implications on the production and breeding performance of African catfish, as well as other cultured fish on ecotoxic exposure to carbendazim. Also, the anatomical and endocrinological tools used in this study could therefore be used for biomonitoring of carbendazim pollution.

REFERENCES

1. Aire TA. 2005. Short-term effects of carbendazim on the gross and microscopic features of the testes of Japanese quails (*Coturnix coturnix japonica*). *Anat Embryol (Berlin)*;210:43-9.
2. Akbarsha MA, Kadalmani B, Girija R, Faridha A. 2000. Carbenda, im generates symplasts in rat spermatogenic clones. *Indian journal of experimental biology*, 38, 1251-1254.
3. Andreu R, Waichman AV, Geber-Correa R, van den Brink PJ. 2011. Effects of malathion and carbendazim on Amazonian freshwater organisms: comparison of tropical and temperate species sensitivity distributions. *Ecotoxicology* 20:625–634
4. Can A, Albertini DF. 1997. Stage specific effects of carbendazim (MBC) on meiotic cell cycle progression in mouse oocytes. *Mol. Reprod. Dev.*, 46: 351–362
5. Cavaco JEB. 2005. Sex steroids and spermatogenesis in the African catfish (*Clarias gariepinus*). *Systems Biology in Reproductive Medicine*, 51(2), 99-107.
6. Cuppen JG, Van den Brink PJ, Camps E, Uil KF, Brock TC. 2000. Impact of the fungicide carbendazim in freshwater microcosms. I. Water quality, breakdown of particulate organic matter and responses of macroinvertebrates. *Aquatic toxicology*, 48(2), 233-250.
7. Dang Z, Smit CE. 2008. Environmental risk limits for Carbendazim. National Institute for Public Health and the Environment. Letter report 601716014
8. Gray EL, Ostby J, Linder R, Goldman J, Rehnberg G, Cooper R. 1990. Carbendazim-Induced Alterations of Reproductive Development and Function in the Rat and Hamster *Toxicol. Sci.* 15: 281-297
9. Gillet CH, Roubaud P. 1983. Prehatching survival of carp eggs after treatment during fertilization and early development with the antimetabolic fungicide carbendazim. *Water Research*, 17, 1343-1348.
10. Hess RA, Nakai M. 2000. Histopathology of the male reproductive system induced by the fungicide benomyl. *Histology and histopathology*, 15, 207-224.
11. Jeyaratnam J. 1993. Acute pesticide poisoning. *Occupational health and national development, World Scientific, Oxford*, 14-26.
12. Lim J, Miller MG. 1997. The Role of the Benomyl Metabolite Carbendazim in Benomyl-Induced Testicular Toxicity *Toxicology and Applied Pharmacol.* 142: 401–410.
13. Kadalmani B, Girija R, Faridha A, Akbarsha MA. 2002. Male reproductive toxic effects of carbendazim: hitherto unreported targets in testis. *Indian j exp. biol.* 40: 40-44
14. Lerner DT, Björnsson BT, McCormick SD. 2007. Aqueous exposure to 4-nonylphenol and 17 β -estradiol increases stress sensitivity and disrupts ion regulatory ability of juvenile Atlantic salmon. *Environmental Toxicology and Chemistry*, 26: 1433–1440.
15. Lim J, Miller MG. 1997. The role of the benomyl metabolite carbendazim in benomyl-induced testicular toxicity. *Toxicol and applied pharmacol.* 142: 401-410.
16. Lorke D. 1983. A new approach to practical acute toxicity testing. *Arch.* 54:275-28
17. Lu SY, Liao JW, Kuo ML, Wang SC, Hwang JS, Ueng TH. 2004. Endocrine-disrupting activity in carbendazim-induced reproductive and developmental toxicity in rats. *Journal of Toxicology and Environmental Health*. 67: 1501-1515.
18. Markelewicz RJ, Hall SJ, Boekelheide K. 2004. 2, 5-hexanedione and carbendazim coexposure synergistically disrupts rat spermatogenesis despite opposing molecular effects on microtubules. *Toxicological Sciences*. 80: 92-100.
19. Miller TA. 2004. Rachel Carson and the adaptation of biotechnology to crop protection. *American Entomologist* 50: 194.
20. Moffit J S, Bryant BH, Hall SJ, Boekelheide K. 2007. Dose-dependent effects of sertoli cell toxicants 2, 5-hexanedione, carbendazim, and mono-(2-ethylhexyl) phthalate in adult rat testis. *Toxicol Pathol.* 35: 719-727.

21. Mooney HA, Drake JA. 2012. Ecology of biological invasions of North America and Hawaii. Springer Science & Business Media. 58: 37, 138.
22. Mooney HA, Drake BG, Luxmoore RJ, Oechel WC, Pitelka, L. F. 1991. Predicting ecosystem responses to elevated CO₂ concentrations. *BioScience* 41: 96-104.
23. Nakai M, Hess RA. 1994. Morphological changes in the rat Sertoli cell induced by the microtubule poison carbendazim. *Tissue and Cell*. 26:917-927.
24. Nakai M, Hess RA, Moore BJ, Guttroff RF, Strader LF, Linder RE. 1992. Acute and Long-Term Effects Of A Single Dose Of The Fungicide Carbendazim (Methyl 2 Benzimidazole Carbamate) On The Male Reproductive System In The Rat. *J Androl*. 13: 507–518
25. Nwani CD, Omah MC, Ivoke N, Nwamba HO, Ani C, Ogbonna SU. 2015. Biochemical, haematological and morphological variations in juvenile *Clarias gariepinus* exposed to Carbendazim® fungicide. *African Journal of Aquatic Science*. 40: 63-71.
26. Ozegbe PC, Aina OO. 2013. Effects of Dietary Protein-Energy Malnutrition on the Testes of Japanese Quails (*Coturnix coturnix japonica*) Exposed To Carbendazim. *Afr J Biomed Res*. 15:117-121.
27. Palawski DU, Knowles CO. 1986. Toxicological studies of benomyl and carbendazim in rainbow trout, channel catfish and bluegills. *Environ Toxicol Chem*. 5: 1039–1046.
28. Palawski DU, Knowles CO. 1986. Toxicological studies of benomyl and carbendazim in rainbow trout, channel catfish and bluegills. *Environ toxicol and chem*. 5: 1039-1046.
29. Rajeswary S, Kumaran B, Ilangovan R, Yuvaraj S, Sridhar M, Venkataraman Pand Aruldhas MM. 2007. Modulation of antioxidant defense system by the environmental fungicide carbendazim in Leydig cells of rats. *Reproductive Toxicology*, 24(3), 371-380
30. Rico A, Waichman AV, Geber-Corrêa R, van den Brink PJ. 2011. Effects of malathion and carbendazim on Amazonian freshwater organisms: comparison of tropical and temperate species sensitivity distributions. *Ecotoxicol*. 20: 625-634.
31. Sayed Alaa El-Din H, Mekkawy IAA, Mahmoud UM. 2011. Effects of 4-nonylphenol on metabolic enzymes, some ions and biochemical blood parameters of the African catfish *Clarias gariepinus* (Burchell, 1822). *Afr J Bio Res*. 5: 287-297.
32. Sridhar K, Joice PE. 2012. Carbendazim induced histopathological and histochemical changes in liver tissues of common carp *Cyprinus carpio*. *Int. J. Adv. Sci*, 5: 65-70.
33. Sung HH, Ye YZ. 2009. Effect of nonylphenol on giant freshwater prawn (*Macrobrachium rosenbergii*) via oral treatment: toxicity and messenger RNA expression of hemocyte genes. *Aquatic toxicology*. 91: 270-277.
34. Thomas K B, Colborn T. 1992. Organochlorine Endocrine Disruptors in Human Tissue. Source: Chemically-Induced Alterations in Sexual and Functional Development: The Wildlife/Human Connection, T. Colborn and C. Clement, Editors; *Advances in Modern Environmental Toxicology*, Vol.XXI, Princeton Scientific Pub. Co., Inc., Prince, '
35. W.H.O. 1993. Environmental Health Criteria 149: Carbendazim. Geneva, World Health Organization, Food and Agriculture Organization of the United Nations