

VARIABILITY OF THE LATERAL LIGAMENTOUS COMPLEX OF THE KNEE

Ashaolu J.O¹, Makinde E.O¹, Ukwenya V.O², Olajide O.J³, Ojo G.B.¹,
, Osinuga T.S.¹, Adekanmbi A.J¹

1. Department of Anatomy, Faculty of Basic Medical sciences, College of Health Sciences, Bowen University, Osun State, Nigeria.
2. Department of Anatomy, Faculty of Basic Medical sciences, College of Health Sciences, Ekiti State University, Ado-Ekiti, Ekiti State, Nigeria.
3. Department of Anatomy, Faculty of Basic Medical sciences, College of Health Sciences, University of Ilorin, Ilorin, Kwara State, Nigeria.

Corresponding Author *: Ashaolu, James Olumide Department of Anatomy, Faculty of Basic Medical sciences, College of Health Sciences, Bowen University, Iwo, Osun State, Nigeria. Olusco172003@yahoo.com +234-8137609462

ABSTRACT

The current study examined the prevalence and morphometric values of three extracapsular ligaments on the lateral aspect of the knee namely lateral collateral ligament, anterolateral and triradiate collateral ligaments in human cadavers. Twenty knees were used. The lateral collateral ligament, anterolateral and triradiate collateral ligaments were present in 70%, 5% and 25% of the cases respectively. The triradiate collateral ligament had three parts namely femoral, tibial and fibular arms with average lengths of 20.03mm, 18.14mm and 16.20mm respectively. The lateral collateral ligament was attached on the lateral condyle of femur and the apex of head of fibula. The anterolateral ligament was attached on the lateral epicondyle of femur anterior to the origin of the lateral collateral ligament and both posterior to the Gerdy's tubercle and on the lateral meniscus. The triradiate collateral ligament attached on the lateral condyle of femur, descends as the femoral arm and divides at the joint line as the tibial arm (anteriorly) and fibular arm (posteriorly). The tibial arm was attached on the posterior aspect of the Gerdy's tubercle while the fibular arm was attached on the anterior aspect of head of fibula. The triradiate collateral ligament and the anterolateral ligaments possessed internal attachment to the lateral meniscus and could potentiate meniscal damage. There are considerable ligament variations at the lateral side of knee which should be brought to the knowledge of surgeons and radiologists.

Key words: Knee, Lateral complex, lateral collateral ligament, anterolateral ligament, triradiate collateral ligament.

INTRODUCTION

It was commonly believed that the lateral region of the knee consist mainly of the lateral collateral ligament which is usually described as a strong fibrous cord attaching the lateral condyle of the femur to the head of the fibula (Williams *et al.*, 1995). But recent studies in different populations have consistently established the presence of an additional ligament called the anterolateral ligament of the

knee, which is said to play critical role in lateral knee stability and prevention of excessive internal tibia rotation (Claes *et al.*, 2013, Helito *et al.*, 2013; Vincent *et al.*, 2012). Meanwhile, a case report in our laboratory has described a new ligament named as the triradiate collateral ligament of the knee at its anterolateral aspect which originated on the lateral femoral epicondyle and divided at the level of the

joint line to yield the tibial arm and the fibular arm which joins the posterior aspect of the Gerdy's tubercle of tibia and fibular head respectively (Ashaolu *et al.*, 2015). It should be noted that differential ligamentous formation would require informed diagnostic and surgical approach. Again, unresolved injuries to the ligaments of the lateral aspect of knee have been implicated in persistent instability of the knee after damaged anterior cruciate ligaments were repaired.

It therefore becomes imperative to understand the anatomy of the ligaments of the lateral aspect of knee, as dearth of information currently exists. It is believed that studies of anatomical specimens can overcome the limited information. This current study seeks to establish the prevalence of individual ligamentous entity of the anterolateral aspect of the knee in twenty cadaveric knees obtained in Nigeria.

MATERIALS AND METHODS

The study was conducted on twenty cadaveric knees in the Department of Anatomy, Bowen University, Osun State, Nigeria. Three ligaments were identified in the anterolateral aspect of the knee namely, the lateral collateral ligament, anterolateral ligament and the triradiate collateral ligament.

We evaluated the prevalence of the LCL, ALL, TRCL in the twenty cadaveric knees. Only knees that were not previously dissected were included in the study. It was ensured that none of the knees showed sign of pathology. The skin and subcutaneous tissues around the knee was carefully reflected. Then the distal attachment of the biceps femoris on the fibula and the iliotibial tract were carefully removed.

The lateral collateral ligament was recorded and noted as a strong tendinous cord proximally attached to the lateral epicondyle of the femur and distally attached on the head of fibula. The anterolateral ligament was recorded as a ligament proximally attached to the lateral epicondyle of the femur and distally

attached to the lateral meniscus and the tibia, posterior to the Gerdy's tubercle.

The triradiate collateral ligament was recorded when an inverted Y-shaped ligament was found being proximally attached to the lateral epicondyle of the femur via its femoral arm and distally attached to the tibia and fibula via its tibial and fibular arm respectively.

The percentage prevalence of the ligaments was evaluated by descriptive statistics. The co-existence of the ligament was also evaluated. Photographic record was acquired with Sony Camera (DSC-W800). Quantitative measurements were performed with the digital vernier caliper. Parameters recorded included length, width and thickness of the lateral collateral ligament and anterolateral ligament at the proximal, mid and distal region. The femoral, tibial and fibular arms of the triradiate collateral ligaments were also measured proximally, distally and at their mid regions. The average length of the lateral collateral ligament and anterolateral ligament and each arms of the triradiate collateral ligament were recorded.

RESULT

The result of this study showed that the lateral collateral ligament was present in 75 % of the studied knees (Fig. 1A, Table 2). The anterolateral ligament was present in 5% (Fig. 1B & 1C, Table 2). The

triradiate collateral ligament was present in 25% (Fig. 1D, Table 2).

Lateral collateral ligament, anterolateral ligament and triradiate collateral ligament

did not occur simultaneously. The lateral collateral ligament occurred alone in 70% of all occasions, but occurred with anterolateral ligament in 5% of all cases. It did not occur with triradiate collateral ligament. The triradiate collateral ligament did not occur alongside the anterolateral collateral ligament but occur alone in 25 % of all occasions.

The lateral collateral ligament had two shapes; in some instances, it was cord-like and in other instances it was membranous and thick. It originated from the lateral epicondyle of femur, it did not attach to the lateral meniscus of knee but it inserted on the apex of the fibular head (Fig. 1A). We found one case of doubled lateral collateral ligament. The anterolateral ligament of the knee was flat and thin. It originated anterior to the origin of the lateral collateral ligament on the lateral epicondyle of the femur. Along the joint line of the knee, it attached firmly to the lateral meniscus and then terminated on the anterosuperior aspect of tibia, just posterior to the Gerdy's tubercle. The triradiate collateral ligament of the knee possessed three parts; namely, the femoral, tibial and fibular arm. The origin of the femoral arm is on the lateral epicondyle of femur, it then

descends downwards and divided along the joint line into an anterior part called the tibial arm and a posterior part called the fibular arm. The tibial arm inserts on the posterior aspect of the Gerdy's tubercle of tibia while the fibular arm inserts on the fibular head. The triradiate collateral ligament was bounded to the lateral meniscus along the joint line.

The length of lateral collateral ligament was 42.28mm (Table 1). The anterolateral collateral ligament length was 23.53mm. The length of the femoral arm of the triradiate collateral ligament was 20.03 mm, the tibial arm was 18.14 mm while the arm was 16.20 mm (Table 1). The mean width and thickness of the lateral collateral ligament was 6.20 mm and 1.84 mm respectively. The mean width and thickness of the anterolateral ligament was 5.48 mm and 0.94 mm respectively.

The mean width and thickness of the femoral arm of triradiate collateral ligament was 9.33 mm and 3.28mm respectively (Table 1). The mean width and thickness of the tibial arm of triradiate collateral ligament was 8.27 mm and 2.23mm respectively. The mean width and thickness for fibular arm was 5.73mm and 2.15mm.

Table 1: Dimensions of the lateral collateral ligament, anterolateral ligament and different arms of the triradiate collateral ligaments

LIGAMENTS/PARTS	LENGTH (MM)	WIDTH (MM)	THICKNESS (MM)
LCL	42.28	6.20	1.84
ALL	11.27	5.48	0.94
Femoral arm of TRCL	20.03	9.18	3.28
Tibial arm of TRCL	18.14	7.38	2.16
Fibular arm of TRCL	16.20	5.29	2.11

ALL, anterolateral ligament of knee; LCL, Lateral collateral ligament; TRCL, triradiate collateral ligament of knee

Table 2: Coexistence of the fibular collateral ligament, anterolateral ligament and triradiate collateral ligament in percentages

COEXISTENCE OF LIGAMENTS	PERCENTAGES
LCL + ALL + TRCL	0%
LCL + ALL	5%
LCL + TRCL	0%
ALL + TRCL	0%
TRCL alone	25%
LCL alone	70%
ALL alone	0%

ALL, anterolateral ligament of knee; LCL, lateral collateral ligament; TRCL, triradiate collateral ligament of knee

DISCUSSION

This current study has shown that the lateral collateral ligament is not necessarily a constant anatomical structure and that it only occurred in 70 % of the studied knees. Another main finding was that the anterolateral ligament of the knee did not present with high prevalence but was only present in 5% of cases. Thirdly the lately discovered ligament, the triradiate collateral ligament of the knee was present in 25% of the studied knees.

The lateral collateral ligament has been documented previously as a constant structure in anatomy texts and articles (Williams *et al.*, 1995, LaPrade *et al.*, 2003). It was specifically said to limit excessive external tibial rotation, prevent subluxation and limit posterior translation of the knee (LaPrade *et al.*, 2003). Our current findings documents that it is only present in 70% of the studied knees. It existed alongside the ALL in 5% of all occasions and was not present together with the triradiate collateral ligament of the knee. The mean length of the lateral collateral ligament (42.28mm) was shorter in this current study compared to that reported in studies by Laprade *et al.* (69.6mm) and Dodds *et al.* (60.0mm). Meanwhile, the width was higher, being 6.20mm as compared to 5mm reported by Dodds *et al.* (2014).

The anterolateral ligament of the knee was found in 5% of the dissected knees. This current finding contradicts previously reported anterolateral ligament high dominance. Claus *et al.*, (2013) reported 97% prevalence in the Belgian population, Vincent *et al.* (2012) reported 100% prevalence within the French population, Catherine *et al.* (2014) reported 100% prevalence in the Canadian population, Gossner *et al.* (2014) reported 98.2% prevalence within the German population, Helito *et al.* (2013) reported a 100% prevalence in the Brazilian population. The results of the current study therefore indicate that the presence of ALL is population specific. In the current study the anterolateral ligament originated on the lateral condyle of femur at the same point as the lateral collateral ligament. Claes *et al.* (2013) and Helito *et al.* (2013) described the proximal bony attachment of the ALL as being anterior to the origin of the lateral collateral ligament. Meanwhile, in the account of Vincent *et al.* (2012) and Dodds *et al.* (2013), it originated posterior to the origin of the lateral collateral ligament. Distally it inserted posterior to the Gerdy's tubercle and possesses internal attachment to the lateral meniscus and the same has been described in previous studies.

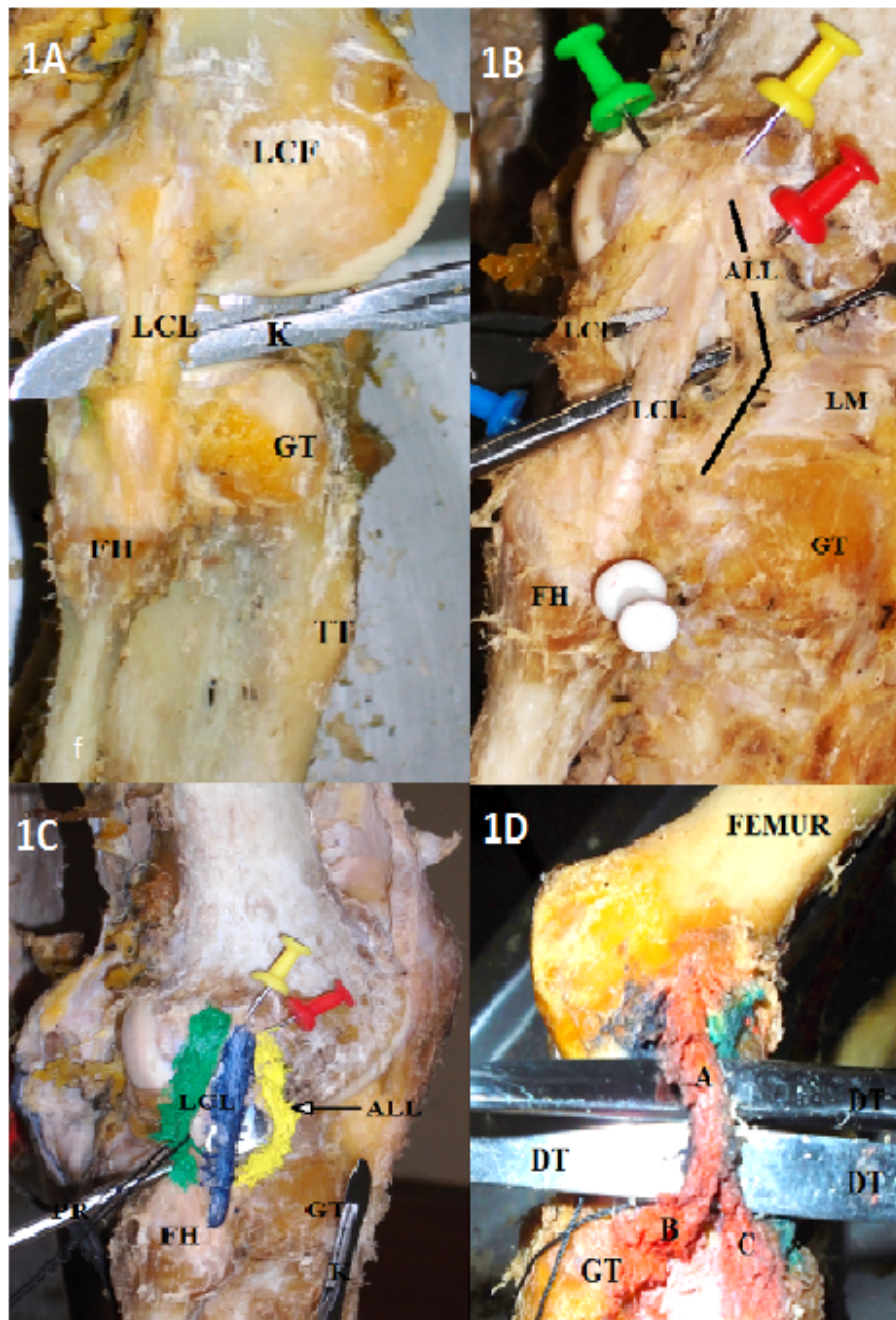


Figure 1: Representative photograph of the lateral aspect of knee. **Plate 1A**, showing the lateral collateral ligament. **Plate 1B**, showing the anterolateral ligament and the doubled lateral collateral ligaments. **Plate 1C**, showing the painted anterolateral ligament and the doubled lateral collateral ligaments. **Plate 1D**, showing the painted triradiate collateral ligament of knee. **LCF**, femoral lateral condyle; **LCL**, lateral collateral ligament; **GT**, Gerdy's tubercle; **FH**, fibular head; **TT**, Tibial tuberosity; **K or DT**;dissecting knife.; **ALL**; anterolateral ligament of knee, **LM**, Lateral meniscus. **A**, femoral arm of triradiate collateral ligament of knee; **B**, tibial arm of triradiate ligament of knee; **C**. Fibular arm of triradiate collateral ligament of knee; **GT**, Gerdy's tubercle; **FH**, fibular head; **DT**, Dissecting tool.

In addition to the sparing prevalence of the ALL, its dimensions in the current study (length; 11.3mm: width; 5.48mm: thickness 0.94mm) are also lesser compared to that reported by Claes *et al.* (length; 41.5mm: width; 6.7mm (at joint line); thickness; 1.3mm) and Helito *et al.* (length; 35.1 mm: width; 6.8mm; thickness; 2.6mm).

The triradiate collateral ligament of the knee was found in 25% of the occasions. This prevalence was unexpectedly high. This ligament is regarded as a functional and structural hybrid of ALL and LCL. It may limit excessive internal and external rotation of the knee. The identification of the ligament and its different limbs will significantly improve diagnoses of ligamentous injury of the anterolateral aspect of the knee. Biomechanical studies are recommended to unravel the physical properties of the triradiate collateral ligament since injuries to different arms of the triradiate collateral ligament will produce differential symptoms

Damage to TRCL, ALL and LCL may be associated with anterior cruciate ligament injury and they could compound pivot

shifting of the knee and cause it rotatory instability even after the anterior cruciate ligament has been repaired. The association of the TRCL and ALL with lateral meniscus could increase the tendency for lateral meniscal tear during sporting activities. Again radiologists should take cognizance of the fact that both the ALL and TRCL are new ligament of high functional significance. When they are properly diagnosed, it will improve surgical reconstruction of lateral aspect of knee. Other studies on the detailed biomechanical properties of the TRCL and ALL will be useful in sport medicine and physiotherapy.

This study concludes that lateral collateral ligament was not a constant anatomy structure in the lateral aspect of the knee and that it could be substituted by the triradiate collateral ligament, coexists with the anterolateral ligament of knee or exist alone. Again, the prevalence of the anterolateral ligament was low in this study. The anatomy of the lateral side of knee is highly variable and it is important that anatomists, surgeons and radiologists are kept abreast of this information.

REFERENCES

1. Ashaolu JO, Makinde OE and Osinuga TS. 2015. The triradiate collateral ligament of knee: Anatomical and clinical implications. *Int. J. Morph* In Press
2. Caterine S, Litchfield R, Johnson M, Chronik B, Getgood A. 2014. A cadaveric study of the anterolateral ligament: re-introducing the lateral capsular ligament. *Knee Surg Sports Traumatol Arthrosc.* 1–10
3. Claes S., Bartholomeeusen S Bellemans J 2014. High prevalence of anterolateral ligament abnormalities in magnetic resonance images of anterior cruciate ligament-injured knees. *Acta Orthop. Belg;* 80:45-49
4. Claes S, Vereecke E, Maes M, Victor J, Verdonk P, Bellemans J 2013. Anatomy of the anterolateral ligament of the knee. *J Anat;* 223(4):321-328.
5. Dodds AL, Halewood C, Gupte C.M, Williams A, Amis AA 2014. The anterolateral ligament: Anatomy, length changes and association with the Segond fracture. *Bone Joint J;* 96-B:325–31.
6. Gossner J 2014. The anterolateral ligament of the knee: Visibility on magnetic resonance imaging. *Rev Bras Ortop;* 49(1): 98-99
7. Helito CP, Miyahara HDS, Bondia MD, Tirico LEP, Gobbi R.G, Demenge MK, Angelini FJ, Pecora JR, Camanho GL. 2013. anatomical study of the anterolateral ligament of the knee. *Rev bras ortop* 48(4):368-373

8. LaPrade RF, Ly TV, Wentorf FA, Engebretsen L. 2003. The posterolateral attachments of the knee : A Qualitative and quantitative morphologic analysis of the fibular collateral ligament, popliteus tendon, popliteofibular ligament and lateral gastrocnemius tendon *The American Journal of Sport Medicine*; 31(6) 854-860
9. Vincent JP, Magnussen RA, Gezmez F, Uguen A, Jacobi M, Weppe F, Al-Saati MF, Lustig S, Demey G, Servien E, Neyret P 2012. The anterolateral ligament of the human knee: an anatomic and histologic study. *Knee Surg Sports Traumatol Arthrosc.* ; 20(1):147-52
10. Williams PL, Bannister LH, Berry MM, Collins P, Dyson M, Dussek JE, Ferguson MW. 1995. Muscle of the leg. In: *Gray's anatomy*, 38th edn. ELBS with Churchill Livingstone, Edinburgh, London, pp 884–885.