

ORIGINAL COMMUNICATION

MORPHOLOGICAL EFFECTS OF LONG-TERM CONSUMPTION OF ENERGY DRINKS ON THE INTRACRANIAL VISUAL RELAY CENTRES OF ADULT WISTAR RATS.

**Josiah Obagwharhievwo ADJENE^{1*}; Victor EMOJEVWE¹;
Patrick Sunday IGBIGBI²**

Correspondence to Josiah Adjene, DEPARTMENT OF MEDICAL LABORATORY SCIENCE, ACHIEVERS UNIVERSITY, OWO, ONDO STATE, NIGERIAE-mail: joadjene@yahoo.com.
Telephone: +2288028084016, +2288052878526.

ABSTRACT

Morphological effects of long-term consumption of energy drinks on the intracranial visual relay centres namely superior colliculus and lateral geniculate body of adult wistar rats were carefully studied. The study included rats of both sexes (N = 20), with average weight of 200g randomly assigned into treated (n₁=10) and control (n₂=10) groups. The rats in the treated group received energy drinks and distilled water alternatively on a daily basis for 10hrs and 14hrs liberally in thirty days, while the control group received distilled water liberally for the thirty days. The rats were sacrificed by cervical dislocation on the thirty-first day of the experiment and the superior colliculus and lateral geniculate body were carefully dissected out, weighed using the Mettler Toledo weighing balance, and quickly fixed in 10% formal saline for further histological study. The findings indicated that there was a significant (p < 0.05) increase in the weight (g) and relative weight (%) of the treated superior colliculus and a significant (p < 0.05) decrease in the weight (g) and relative weight (%) of the treated lateral geniculate body as compared to their corresponding control group. The microanatomy of the superior colliculus and lateral geniculate body of the rats treated with energy drinks revealed cellular degenerative changes, sparse cellular population, hypertrophy, pyknotic nuclei with microcystic changes and vacuolation in the stroma of the superior colliculus and lateral geniculate body as compared to the control group. It was therefore concluded that long-term consumption of energy drinks might have an adverse effect on the intra cranial visual sensibilities by affecting the microanatomy of the superior colliculus and lateral geniculate body of adult wistar rats. We therefore recommended that further studies aiming at corroborating these findings be done.

Key words: Morphological effects, Energy drink, Superior colliculus, Lateral geniculate body, Wistar rats.

INTRODUCTION

Energy drinks are flavored beverages containing high amounts of caffeine and typically other additives, such as vitamins, taurine, herbal supplements, creatine, sugar, and guarana, a plant product containing concentrated caffeine. These energy drinks are marketed to improve energy, weight loss, stamina, athletic performance, and concentration (McCarthy,

2009; Lee, 2011). The drinks sold in cans and bottles, are readily available in grocery stores, vending machines, convenience stores, bars and other venues where alcoholic drinks are sold. Consumption of energy drinks can lead to a rising public health problem because medical and behavioural consequences can result from excessive caffeine intake, which is a content

of the drinks. A growing body of scientific evidence documents harmful health effects of energy drinks, particularly for children, adolescents, and young adults (Seifert et al., 2011). Research has established that among college students, there are associations between energy drinks consumption and problematic behaviours such as marijuana use, sexual risk taking, fighting, smoking and drinking and prescription drug misuse (Miller, 2008; Thombs et al., 2010). Although healthy people can tolerate caffeine in moderation, heavy caffeine consumption, such as drinking energy drinks, has been associated with serious consequences such as seizures, mania, stroke and sudden death (Reissiget et al., 2009; Babuet et al., 2008; Lipshultz, 2008; Hedges et al., 2009; Heneman and Zidenberg-Cherr, 2011). In children especially those with cardiovascular, renal, or liver disease, epilepsy, diabetes mellitus, mood and behaviour disorders, hyperthyroidism or those who take certain medications may be at higher risk for adverse events from energy drinks consumption (Lipshultz, 2000; Mone et al., 2004; Lipshultz, 2005; Cohen, 2008; Chrissos, 2008; Lipshultz et al., 2009; Temple, 2009; Heneman and Zidenberg-Cherr, 2011). Although, caffeine has been reported to have detrimental health consequences, Riesenhuber and colleagues found it is caffeine, not taurine in energy drinks that promote diuresis and natriuresis (Lee et al., 2005). Furthermore, acute caffeine consumption has been reported to reduce insulin sensibility (Lee et al., 2005) and increase mean arterial blood pressure (Bichler et al., 2006). High caffeine consumption has been associated with chronic daily headaches, particularly among young women and among those with chronic episodic headaches of recent onset (Scher et al., 2004). Aspartame is a synthetic sweetener and preservatives, which is of low caloric value added to soft drinks, chewing gum, fruit juices, gelatins

and jellies (Grenby, 1991; Sanyudes, 1990). Aspartame is metabolized in the gastrointestinal tract into aspartic acid, methanol, and phenylalanine (Camfield et al., 1992). The methanol is later oxidized to formaldehyde and formate in many tissues. Formic acid is the principal metabolite responsible for the deleterious effects of acute intoxication by methanol in humans and animals (Butchko et al., 2002). In intoxication, it causes blindness and hepatic injury since the liver and retina concentrate the greatest quantity of the metabolic by-products of aspartame (Trochoet al., 1988).

The superior colliculus and lateral geniculate body constitute the intracranial visual relay centres. The lateral geniculate body in mammals processes visual information and participates in the regulation of circadian function through its projection to the circadian pacemaker of the hypothalamus (Altman and Bayer, 1981; Moore and Card, 1984). The superior colliculus is a paired structural component of the mid-brain. It is concerned with ocular movement. It acts as an integrative center, sub-serving visual perception. It coordinates responses evoked by a variety of sensory signals with behavioural movements that direct the head, eyes and ear towards the environmental stimulus. Thus, the superior colliculus has a critical role in visual localization, orientation tracking movements, accommodation and pupillary reflex (Lund, 1972; Altman and Bayer, 1981; Moore and Card, 1984; Sparks, 1986). Any pathology of superior colliculus may impair vision and vision dependent responses. The cognitive functions of the superior colliculi have also been documented to include a critical role in the ability to direct behaviours toward specific objects, even in the absence of the cerebral cortex (Sprague, 1996). There is no known document on any adverse effects of energy drinks on the intracranial visual relay centres. This study aimed at investigating

any possible morphological effects of long-term consumption of energy drinks on the superior colliculus and lateral geniculate body of adult Wistar rats. This study is based on the premise that any

morphological distortion on the superior colliculus and lateral geniculate body could affect cognition and vision dependent responses (Ogundele et al., 2010).

MATERIALS AND METHODS

EXPERIMENTAL ANIMALS: The ethical committee of the Achievers University, Owo granted the approval before the commencement of the research. Twenty adult wistar rats of both sexes of average weight 200g, caged based on same sex to avoid mating and pregnancy, were randomly assigned into two groups: A and B of (n=10) in each group. Animals in group A served as treated group (n₁=10) while animals in group B (n₂=10) served as the control. The rats (between 3-4 months old), were obtained and maintained in the Animal Holding of the Department of Medical Laboratory Science, College of Natural and Applied Sciences, Achievers University, Owo, Ondo State, Nigeria. The animals were fed with grower's mash obtained from Edo Feeds and Flour Mill Limited, Ewu, Edo State, Nigeria and given feeds liberally. The energy drinks were obtained from retailer store, Owo, Ondo State, Nigeria.

ENERGY DRINKS CONSUMPTION: The rats in the treated group received energy drinks and distilled water alternatively on a daily basis for 10hrs and 14hrs liberally in thirty days, while the control group received distilled water liberally for the thirty days in line with an improved method of Adjene et al., (2010). The ingredients contained in the energy drinks were as follows: Water, Citric acid, Carbon dioxide, Taurine (0.38%), acidity regulator (Sodium citrate), Sweeteners (Acesulfame and Aspartame), Flavouring, Caffeine (31.5mg), Glucoronolactone (0.01%), Nicotinamide (7.92mg/100ml, 49.5% RDA) Colour ammonia caramel, inositol, Niacin,

Pantothenic acid (33% RDA, about 1.98/100ml), vitamin B₆ (143% RDA about 2mg/100ml) vitamin B₁₂ (80% RDA, 2ug/100ml). The rats were sacrificed through cervical dislocation on the thirty-first day of the experiment and the superior colliculus and lateral geniculate body extracted, weighed using the Mettler Toledo weighing balance and quickly fixed in 10% formal saline for routine histological techniques.

HISTOLOGICAL STUDY: The tissues were dehydrated in ascending grade of ethanol, cleared in xylene and embedded in paraffin wax. Serial sections of 7 microns thick were obtained using a rotatory microtome. The de-paraffinised sections were stained routinely with haematoxyline and eosin method (Drury et al., 1976). Photomicrographs of the desired results were obtained using the Olympus research photographic microscope in the Department of Medical Laboratory Science, College of Natural and Applied Sciences, Achievers University, Owo, Ondo State, Nigeria. At the end of the experiment, the size, shape and numbers of nuclei in the section were carefully examined.

Statistical Analysis

For statistical comparisons, data were evaluated by Student paired *t*-Test. All values are given as mean ± SEM with n values indicating the numbers of sample analyzed. 95% confidence (P<0.05) was considered significant in this experiment.

RESULTS

The findings indicated that there was a significant ($p < 0.05$) increase in the weight (g) and relative weight (%) of the treated superior colliculus and a significant ($p < 0.05$) decrease in the weight (g) and relative weight (%) of the treated lateral geniculate body as compared to their corresponding control group (Table 1).

The sections of the superior colliculus and lateral geniculate body from the control animals showed normal histological features with the neurons appearing distinct and of

various sizes. The neuron and glial cells appeared normal and showed no signs of vacuolation in the stroma of the superior colliculus and lateral geniculate body. The section from the treated group with energy drinks revealed some cellular degenerative changes, sparse cellular population, hypertrophy, pyknotic nuclei with some microcystic changes and vacuolation in the stroma of the superior colliculus and lateral geniculate body as compared to the control group (Figures 1, 2, 3 & 4).

Table 1: The Mean SEM Weight (g) and Relative Weight (%) of the Superior Colliculus

(SC) and Lateral Geniculate Body (LGB) of the Animals.

PARAMETERS	GROUP OF ANIMALS	
	CONTROL ($n_1 = 10$)	TREATED ($n_2 = 10$)
Brain weight (g)	*1.649± 0.027	*1.790 ± 0.035
Superior colliculus weight (g)	*0.079± 0.007	*0.317 ± 0.103
Relative Superior colliculus weight (%)	*4.841± 0.480	*17.405 ± 5.531
Lateral geniculate body weight (g)	*0.284 ± 0.018	*0.176 ± 0.014
Relative Lateral geniculate body weight (%)	*17.279±1.111	*9.875 ± 0.790

***Significant ($P < 0.05$)**

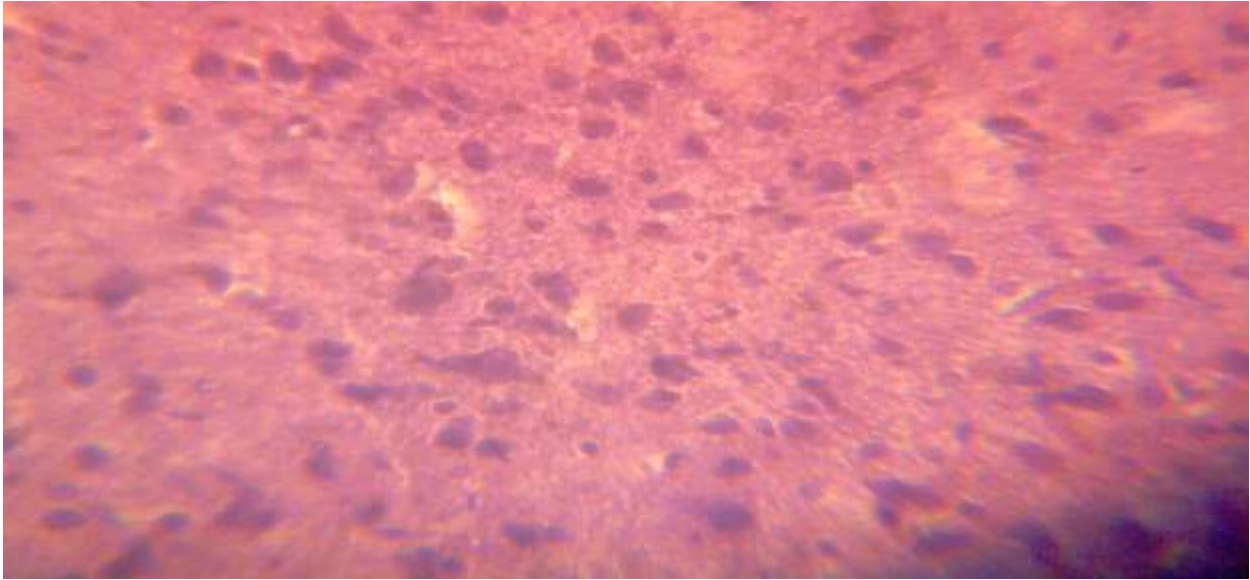


Figure 1: Control section of the superior colliculus. (H & E x400)

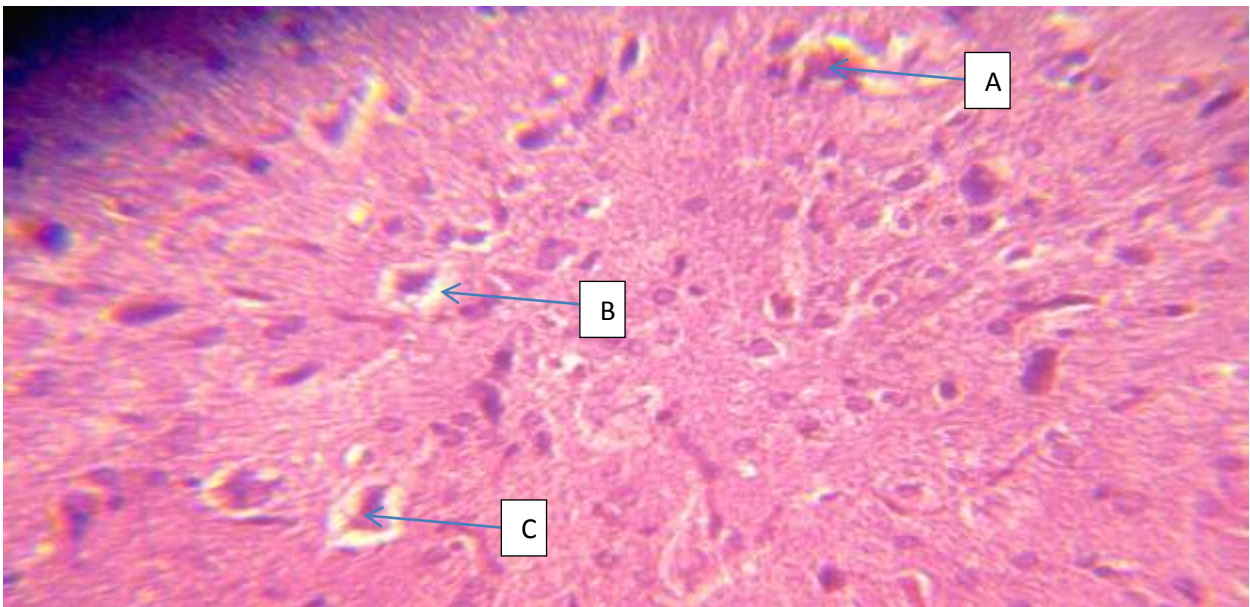


Figure 2: Treated section of the superior colliculus showing; Hypertrophy (A), Vacuolation (B), Pyknotic Nucleus(C) (H & E x400)

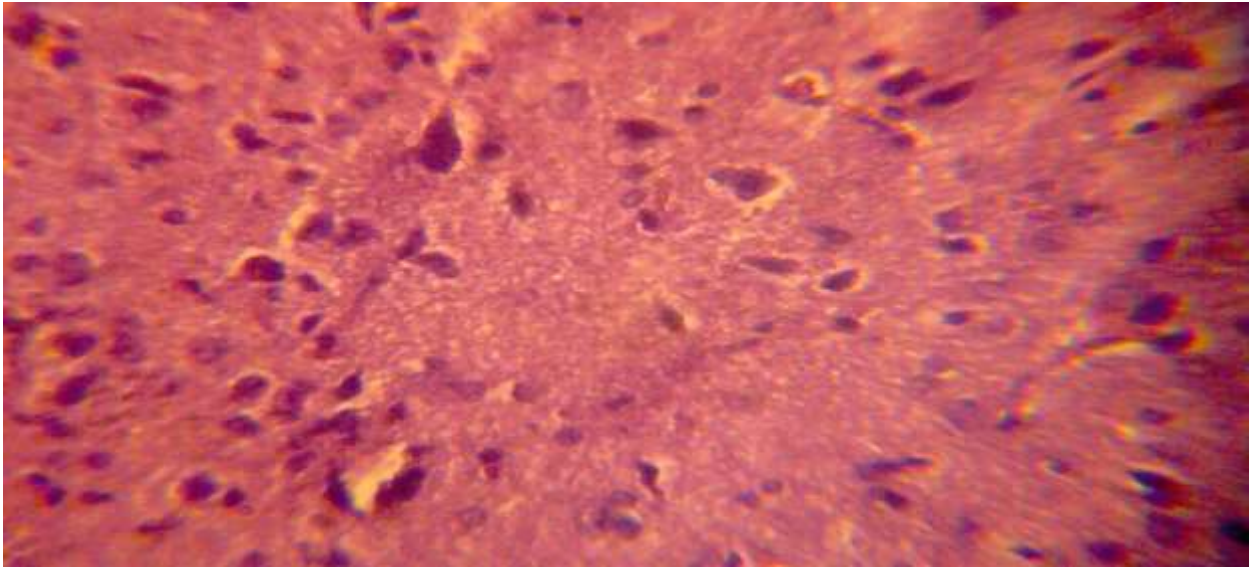


Figure 3: Control section of the Lateral Geniculate Body (LGB). (H & E x400)

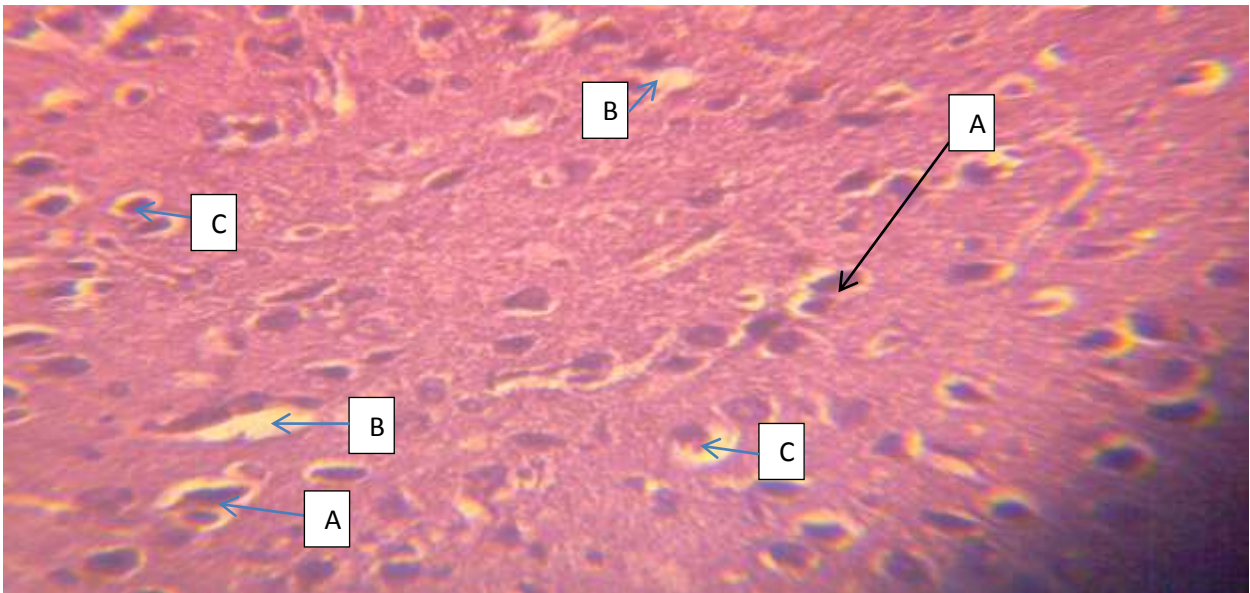


Figure 4: Treated section of the Lateral Geniculate Body (LGB) Showing; Hypertrophy (A), Vacuolation (B), Pyknotic Nucleus(C) (H & E x400)

DISCUSSION

It could be inferred from the results of this experiment that prolonged consumption of

energy drinks resulted in increased toxic effects on the intracranial visual relay centres of adult wistar rats. This could be as a result sleeplessness effects of caffeine component of the energy drinks as proposed by Howard and Marczinski, (2010) and this can further lead to blurred vision (Ogundele et al., 2010). It has been reported previously that chronic administration of chloroquine and efavirenz resulted in the cellular degenerative changes, sparse cellular population and vacuolation appearing in the brain of adult wistar rats (Adjene and Adenowo, 2005; Adjene, 2006; Adjene and Momah, 2010; Adjene and Igbigbi, 2010; Adjene et al., 2010).

Ischemic or pharmacologic disruption of cellular transporters can cause swelling or shrinking of the brain parenchyma (Johanson, 1995), explaining the increased weight of the treated superior colliculus and decreased weight of the treated lateral geniculate body in this study respectively. This may be due to the neurotoxic effects of the energy drinks on the cells of the intracranial visual relay centres of the adult wistar rats. Under such conditions, there is a net shift of water from the extracellular space to the interior of the brain cells (Johanson, 1995). Cytotoxic edema usually involves intracellular swelling of glial, endothelia and neurons (Johanson, 1995). Regulation of brain water content and therefore of the volume is critical for maintaining the intracranial pressure within tolerable limits (Johanson, 1995). In this study, energy drinks could have acted as toxins to the cells of the superior colliculus and lateral geniculate body thus affecting their cellular integrity and causing a defect in membrane permeability and cell volume homeostasis. As brain tissue swells or shrinks as reported in this study, the activity of the cellular transporters is modified by the up or down regulation as reported in the case of hyponatremia or hypernatremia

(Johanson, 1995). The pharmacologic disruption of the superior colliculus and lateral geniculate body caused by energy drinks is a cardinal feature of the results of this experiment. However, there are many different causes of cell swelling or shrinkage, including drug poisoning, water intoxication, hypoxia, and acute hyponatremia (Johanson, 1995). Brain cell swellings can lead to severe cytotoxic edema and may lead to marked reduction in the size of the ventricular system and basal cisterns (Johanson, 1995).

Decrease in cellular population was observed in the group treated with energy drinks. Neuronal degeneration due to toxic agents could be progressive and may include shrinkage of the neurons (Martins, 2001). Energy drinks may have acted as toxin to the cells of the superior colliculus and lateral geniculate body thus affecting their cellular integrity which could be because of the effect of Formic acid as proposed by Carrillo and Benitez, (2000) and Trocho et al., (1988). It could be inferred from this experiment that prolonged consumption of energy drinks resulted in increased toxic effects on the superior colliculus and lateral geniculate body microanatomy.

The sparse cellular population observed in this study may have been due to cell death caused by the toxic effect of energy drinks. Beside the aspartame content of energy drinks being an excitoneurotoxic agent (Potenza and el-Mallakh, 1989), caffeine may be implicated in oxidative damage of these cells. This report advances further the vulnerability of the brain, and the intracranial visual relay centres in particular to long-term consumption of energy drinks. Therefore, one salient factor common to toxic potential of energy drinks is the microanatomical damage hypothesis. Cognitive functions and neuronal change as in neurodegeneration is impacted by

oxidative stress.

The process of cellular necrosis involves disruption of the membranes structural and functional integrity (Martins, 1978). There is need to further investigate the actual mechanism by which energy drinks induced neuronal degeneration in the superior colliculus and lateral geniculate body. Extensive cell death in the central nervous system is present in all neurodegenerative diseases (Waters, 1994). The type of nerve cell loss and the particular part of the brain affected dictate the symptoms associated with an individual disease (Waters, 1994). In this study, energy drinks may have acted as toxin to the cells of the superior colliculus and lateral geniculate body.

It can be inferred from these results that

prolonged consumption of energy drinks resulted in increased toxic effects on the superior colliculus and lateral geniculate body of adult wistar rats.

The decrease in cellular population, vacuolations and microcystic changes observed in the stroma of the treated superior colliculus and lateral geniculate body in this study may be due to energy drinks interference, since some of its constituents have an excitoneurotoxic and excitotoxic effects that could help in the breaking down of the blood brain barrier. This report presents evidence of the possibility of such microanatomical damage to the intracranial visual relay centres of adult wistar rat. Therefore, we recommend biochemical analysis as adjunct study to corroborate these observations.

Limitations

The energy drinks used in this experiment contain aspartame and caffeine. We acknowledge that consumption of energy drinks is not as liberally provided to humans as in the experimental animals. However, our report provides indication of toxic potential to cognitive function with the morphological perspective that has applicability in post-mortem examinations. To our knowledge, this is the first report on the morphological effects of energy drinks on the intracranial visual relay centres using adult wistar rats.

CONCLUSION

The study revealed that long-term consumption of energy drinks resulted in the morphological changes in the stroma of the superior colliculus and lateral geniculate body of adult wistar rats. These changes may affect the visual sensibility functions of the superior colliculus and lateral geniculate body in the adult wistar rats. We suggest further studies aimed at corroborating these observations in humans.

REFERENCES

1. Adjene, J. O., Adenowo, T. K. (2005). Histological studies of the effect of chronic administration of Chloroquine on the inferior colliculus of adult wistar rat. *J Med Biomed Res*; 4 (1): 83-87.
2. Adjene, J. O., Adenowo, T. K. (2005). Histological studies of the effect of chronic

- administration of Chloroquine on the inferior colliculus of adult wistar rat. *JMBR*. 4(1): 83-87
3. Adjene, J. O., Caxton-Martins, A. E. (2006). Some histological effect of chronic administration of Chloroquine on the medial geniculate body of adult wistar rat. *Afr J Med Sci*. 35:131-5.
 4. Adjene, J. O., Caxton-Martins, A. E. (2006). Some histological effects of chronic administration of Chloroquine on the medial geniculate body of adult wistar rats. *Afri. J. Med. Sci.*; 35: 131-135.
 5. Adjene, J. O., Ezeoke, J.C., Nwose, E. U. (2010). Histological effects of chronic consumption of soda pop drinks on kidney of adult wistar rats. *North Am J Med Sci*. 2: 215-217
 6. Adjene, J. O., Igbigbi, P. S. (2010). Histological effects of chronic administration of efavirenz on the inferior colliculus of adult Wistar rats. *Fooyin J. Health Sci.*; 2(3-4):105-108
 7. Adjene, J. O., Igbigbi, P. S., Nwose, E. U. (2010). Histological effects of chronic administration of efavirenz on the lateral geniculate body of adult Wistar rats. *North Am J Med Sci*. 2(1):381-384.
 8. Adjene, J. O., Momah, V. (2010). Histological effects of chronic administration of efavirenz on the superior colliculus of adult Wistar rats. *Biosci. Res. Commun*. 22(6):47-52
 9. Altman, J., Bayer, S. A. (1981). Time of origin of neurons of the rat superior colliculus in relation to other components of the visual and visuomotor pathways. *Exp Brain Res*; 42:424-34.
 10. Babu, K. M., Church, R. J., Lewander, W. (2008). Energy drinks: the new eye-opener for adolescents. *Clin Pediatr Emerg Med*. 9(1): 35– 42
 11. Bichler, A., Swenson, A., Harris, M. A. (2006). A combination of caffeine and taurine has not effect on short-term memory but induces changes in heart rate and mean arterial blood pressure. *Amino Acids*, 31:471-476.
 12. Butchko, H. H., Stargel, W. W., Comer, C. P., Mayhew, D. A., Benninger, C., Blackburn, G. L et al (2002). Aspartame: *Review of Safety Regul. Toxicol. Pharmacol*. 35 (2 pt 2):S1-93.
 13. Camfield, P. R., Camfield, C. S., Dooley, J. M., Gordon, K., Jollymore, S., Weaver, D. E. (1992). Aspartame exacerbates EEG spike- wave discharge in children with generalized absence epilepsy: a double – blind controlled study. *Neurology*. 42:1000-1003
 14. Chrissos, J. (2008). Cold medicines taboo for kids under 4: further restricting the use of cold medicines for young children, drug companies now say they shouldn't be used in children younger than 4. *Miami Herald: Living-Health*
 15. Cohen H. (2008). Dangerous jolt: energy drinks dangers for children. *Miami Herald*. E10, 10E
 16. Drury, R. A. B., Wallington, E. A, Cameron, R. (1976). *Carleton's Histological Techniques*. 4th ed., Oxford University Press NY USA. 1998; 279-280.
 17. Grenby, T. H. (1991). Update on low calories sweeteners to benefit dental health. *Int. Dent. J*. 41(4): 217-224

18. Hedges, D. W., Woon, F. L., Hoopes, S. P. (2009). Caffeineinduced psychosis. *CNS Spectr.* 14(3):127–129
19. Heneman, K. Zidenberg-Cherr, S. (2009). Some facts about energy drinks. Available at: <http://nutrition.ucdavis.edu/content/infosheets/EnergyDrinks.pdf>. Accessed January 17, 2011
20. Howard, M. A., Marczynski, C. A. (2010). "Acute effects of a glucose energy drink on behavioral control". *Experimental and Clinical Psycho-pharmacology* 18 (6): 553–61.
21. Johanson, C. E. (1995). Effects of Fluid in Balances. *Neuroscience in Medicine*. P. Michael conn, J.B. Lippincott Company, pp.187-189.
22. Lee, J. (2009). Energy drinks vs. sports drinks: know thy difference. Available at: <http://speedendurance.com/2009/07/09/energy-drinks-vs-sports-drinks-know-thy-difference>. Accessed January 17, 2011
23. Lee, S. J., Hudson, R., Kilpatrick, K., Graham, T.E, Ross, R. (2005). Caffeine ingestion is associated with reductions in glucose uptake independent of obesity and Type 2 diabetes before and after exercise training. *Diabetes Care*, 28:566-572.
24. Lipshultz SE. Ventricular dysfunction clinical research in infants, children and adolescents. *Prog Pediatr Cardiol.* 2000;12(1): 1–28
25. Lipshultz, S. (2008). High risk: Ban energy drinks from schools. *Miami Herald.* 4(20): 4L, L4
26. Lipshultz, S. E. (2005). Realizing optimal care for children with cardiovascular disease: funding challenges and research approaches. *Prog Pediatr Cardiol.* 20(1):71–90
27. Lipshultz, S. E., Wilkinson, J. D., Messiah S. E., Miller, T. L. (2009). Clinical research directions in pediatric cardiology. *Curr Opin Pediatr.* 21(5):585–593
28. Lund RD. Anatomic studies on the superior colliculus. *Invest Ophthalmol Vis Sci.*1972;11: 434- 441.
29. Martins, L. J. (2001). Neuronal cell death in nervous system development, disease, and injury. *Int. J. Mol. Med.*, 7:455-478.
30. Martins, L. J., Al-Abdulla, N. A., Kirsh, J. R., Sieber, F. E. (1978). Portera-Cailliau C: Neurodegeneration in excitotoxicity, global cerebral ischaemia and Target Deprivation: A perspective on the contributions of apoptosis and necrosis. *Brain Res. Bull.* 46(4): 281-309.
31. McCarthy, M. (2009). Overuse of energy drinks worries health pros. Available at: www.usatoday.com/sports/2009-07-01-Drinks_N.htm. Accessed January 17,2011
32. Miller, K. E. (2008). Energy drinks, race, and problem behaviors among college students. *J Adol. Health*, 43(5), 490-497.
33. Mone, S.M, Gillman, M. W., Miller, T. L., Herman, E. H., Lipshultz, S. E. (2004). Effects of environmental exposures on the cardiovascular system: prenatal period through adolescence. *Pediatrics*, 113(4 suppl):1058 –1069
34. Moore, R. Y., Card, J. P. (1984). Intergeniculate leaflet: An anatomically and Functionally Distinct subdivision of the lateral geniculate complex. *J. comparative*

- Neurology. 344: 403-444
35. Ogundele, O. M., Caxton-Martins, E. A., Ghazal O. K, Jimoh, O. R. (2010). Neurotoxicity of cassava: 4:119-24.
 36. Potenza, D. P., el-Mallakh, R. S. (1989). Aspartame:clinical update. *Conn Me.* 53:395-400.
 37. Reissig. C. J., Strain, E. C., Griffiths, R. R. (2009). Caffeinated energy drinks: a growing problem. *Drug Alcohol Depend.* 99(1–3):1–10
 38. Riesenhuber, A., Boehm, M., Posch, M., Aufricht, C. (2006). Diuretic potential of energy drinks. *Amino Acid*, 31:81-83.
 39. Sanyudes, S. (1990). Alternative Sweeteners. *Can. Pharmaceutical J.*; 123:455-60
 40. Scher, A. I., Stewart, W. F., Lipton, R. B. (2004). Caffeine as a risk factor for chronic daily headache: A population-based study. *Neurology*, 63:2022-2027.
 41. Seifert SM, Schaechter JL, Hershorin ER & Lipshultz SE. Health effects of energy drinks on children, adolescents, and young adults. *Pediatrics*, 2011; 127(3), 511-528.
 42. Sparks, D. L. (1986). Translation of sensory signals into commands for control of saccadic eye movements: role of primate superior colliculus. *Physiol Rev.* 66:118-71.
 43. Sprague, J. M. (1996). Neural mechanisms of visual orienting responses. *Prog Brain Res.* 112:1-15
 44. Temple, J. L. (2009). Caffeine use in children: what we know, what we have left to learn, and why we should worry. *Neurosci Biobehav Rev.*33(6):793– 806
 45. Thombs, D. L., O'Mara, R. J., Tsukamoto, M., Rossheim, M. E., Weiler R. M., Merves, M. L, & Goldberger, B. A. (2010). Event-level analyses of energy drink consumption and alcohol intoxication in bar patrons. *Addictive Behaviors*, 35(4), 325-330.
 46. Trocho, C., Pardo, R., Rafecas, I., Virgili, J., Remesar, X., Fernandez-Lopes., J. A. (1988). Formadehyde derived from dietary Aspartame binds to tissue components in vivo. *Life Science*, 63 (5); 337-349
 47. Waters, C. M. (1994). Glutamate induced apoptosis of striatal cells in rodent model for Parkinsonism. *Neuroscience* 63:1-5