

PORTAL VENOUS BRANCHES TO THE CAUDATE LOBE: NUMBER AND ORIGIN

Jeremiah Munguti, Mercy Sammy, Paul Odula, Kirsteen Awori

Correspondence: Jeremiah Munguti donaldjrmh86@gmail.com , Department of Human Anatomy, University of Nairobi, P.O. Box 00100 – 30197, Nairobi, Kenya.

ABSTRACT

Caudate lobectomy is an important procedure commonly used in the treatment of caudate lobe tumors. Hemorrhage prevention and control during this procedure is key in the reduction of intra operative complications but depends on the knowledge of potential bleeders from caudate lobe venous branches. These vessels are known to vary in number and their origin but local statistics are limited. This study therefore aimed at describing the number and origin of portal venous branches to the caudate lobe. Sixty six livers from adult black Kenyans were obtained during autopsy at the Department of Human Anatomy, University of Nairobi – Kenya. The porta hepatis was carefully dissected and the number and origin of the portal venous branches to the caudate lobe observed and recorded. The collected data was analyzed using SPSS version 16. The caudate lobe received 1 portal venous branch in 17 cases (25.8%), 2 branches in 32 cases (48.5%), 3 branches in 13 cases (19.7%) and 4 branches in 4 cases (6%). It received at least 1 branch from the main portal vein in 18 cases (27.3%), from the left portal vein in 56 cases (84.8%) and from the right portal vein in 35 cases (53%). From the results of the current study, a right sided approach for caudate lobectomy would be safer due to less portal venous branches arising from the right portal vein.

Key words: lobectomy, tumors, hemorrhage, metastasis

INTRODUCTION

The segments of the liver can be resected individually without damaging the other segments (Eleazer et al., 2008). This is made possible because of the segmental division of the liver by its main vessels: the 3 hepatic veins and the portal vein. The caudate lobe has been regarded as an independent lobe (Couinaud, 1981; Foucou et al., 1983; Eleazer et al., 2008) and as such can be safely resected as a treatment option of caudate tumors. However, the fact that the caudate lobe is located posteriorly may pose challenges in its resection (Fan et al., 2001). Furthermore, the division of the liver along the Cantlies's line makes the liver have functional left and right lobes. This line however goes through the caudate lobe making it functionally part of both the right

and left lobes of the liver (Eleazer et al., 2008; Niu et al., 2001). Furthermore, the caudate lobe receives its portal venous supply from both the right and left portal veins (Yamane et al., 1988; Janargin et al., 2003). Metastatic tumors from both the inferior and superior mesenteric venous beds are thus prone to lodge in the caudate lobe thus making its resection a key interventional option (Kuniya et al., 2006; Eleazer et al., 2008).

Hemorrhage control in such a procedure is of paramount importance and would depend on a good understanding of venous bleeders originating from the portal vein. These veins originate mainly from the left portal vein (LPV) and to a varied extent

To cite. Jeremiah Munguti, Mercy Sammy, Paul Odula, Kirsteen Awori. Portal venous branches to the caudate lobe: number and origin. *Anatomy Journal Of Africa* 2014; 3 (1): 200-204.

from the main trunk of the portal vein (PV) and the right portal vein (RPV) (Van et al., 1992). The incidence of the origins of these portal venous branches and their numbers is however varied (Van et al., 1992;

Franceschini and Ortale, 1995) but there is scarcity of this data in the local population.

This study therefore aimed to describe the number and origin of portal venous branches to the caudate lobe.

METHODOLOGY

Sixty six livers from adult black Kenyans were obtained during autopsy at the Department of Human Anatomy, University of Nairobi, Kenya. Ethical approval for the study was granted by Kenyatta National Hospital-University of Nairobi Ethics and Research Committee. Cirrhotic livers and those that had the porta hepatis tampered with were excluded from the study. The livers were harvested en masse from the abdominal cavity and the Glisson sheath around the porta hepatis dissected off. The level of termination of the PV was then determined and any branches to the caudate lobe given extra hepatic noted. Part of the liver was then carefully dissected out to reveal any intra hepatic branches to the caudate lobe. Photographs were taken using a Sony digital camera. The observed number and origins of the portal venous branches to the caudate lobe were then recorded and data analyzed using SPSS version 16.

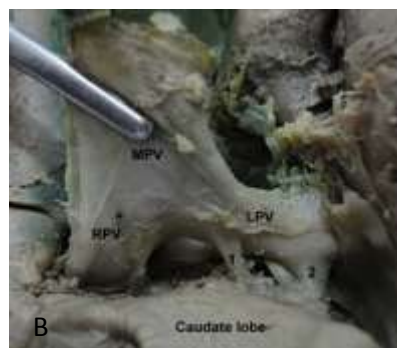
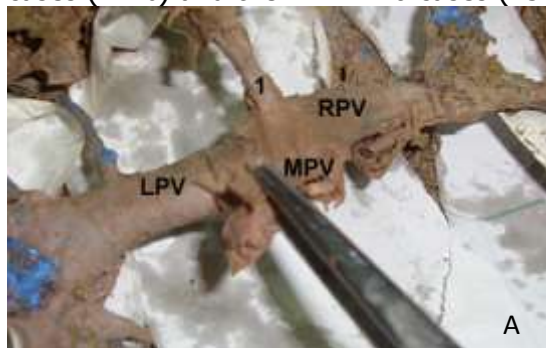
RESULTS

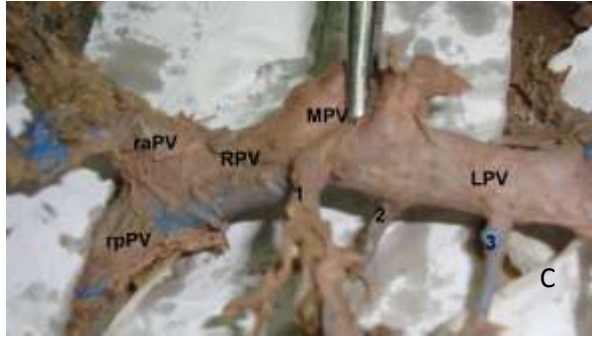
The caudate lobe received portal venous branches from the PV, the LPV and the RPV. It received only one branch in 17 cases (25.8%), 2 branches in 32 cases (48.5%) and 3 branches in 13 (19.7%) cases. In 4 instances (6%) it received 4 branches. Where the caudate lobe received only one branch, it originated from the PV in 5 cases (7.6% of total), from the RPV in 2 cases (3%) and from the LPV in 10 cases (15.2%). Of all the specimens studied, the PV gave at least one branch to the caudate lobe in 18 cases (27.3%) while for the RPV and LPV it was in 35 (53%) and 56 cases (84.8%) respectively. The origins of the branches to the caudate lobe from each vessel are as summarized in table 1 below.

Table 1. Origin and number of venous branches to the caudate lobe

Origin of branches to caudate lobe	Number of branches to the caudate lobe				
	1	2	3	None	Total
PV	14	4	0	48	66
RPV	30	4	1	31	66
LPV	45	10	1	10	66

A branch to the caudate lobe did not originate from the PV in 48 cases (72.7%), the RPV in 31 cases (47%) and the LPV in 10 cases (15.2%).





Images A-C. Branches to the caudate lobe are labeled 1-3. MPV is main portal vein, LPV is left portal vein, RPV is right portal vein, raPV is right anterior portal vein and rpPV is right posterior portal vein.

DISCUSSION

From previous reports, the caudate lobe receives its portal venous blood supply from mainly the left portal vein (LPV) with variable contribution from the PV and the right portal vein (RPV) (Van et al., 1992). The findings of our current study support this observation since the LPV gave at least 1 branch to the caudate lobe in 84.8% of the cases. Malignant colorectal tumors are thus likely to metastasize to the caudate lobe due to the lamina pattern of blood flow found in the portal vein. The caudate lobe should thus be thoroughly examined for possible secondary tumors in patients with colorectal carcinoma.

As reported in previous findings, the caudate lobe receives multiple portal branches ranging from 1-6 (Kimitika et al., 2000). In this study, the caudate lobe received between 1 and 4 branches. We further confirm, as reported in previous literature, that the caudate lobe predominantly receives at least two branches (Franceschini and Ortale, 1995; Kimitika et al., 2000). Care should thus be taken in the tying and ligation of these vessels in order to avoid massive hemorrhage during caudate lobectomies.

Ortale et al., 2004 (n=40) reported that the caudate lobe received only one branch in 37.5% of cases which is slightly more than our current findings at 25.8% (n=66). However, another study reported this figure at 8.1% (Kimitika et al., 2000) (n=88) which is much lower than our current findings. This could possibly be due to inter-population variation since the sample sizes are comparable and the three studies employed a similar methodology. Great care thus needs to be observed in caudate lobectomy due to this much variability in the number of portal venous branches to the caudate lobe.

Caudate lobectomy is done via two main approaches: a right sided approach or a left sided approach (Eleazer et al., 2008). Tumor location and liver function, and not vascular structures, are the key determinants in considering which approach to use (Sastha et al., 2013). Knowledge on the vascular anatomy of the caudate lobe is therefore vital in preventing and controlling hemorrhage. In the left approach in our local setting, more portal venous branches are likely to be encountered because of the high number of branches given from the LPV. Thus, keen precaution needs to be observed when using this approach in order to minimize blood loss. On the other hand, the right sided approach would also pose similar risks albeit at a lower level. This is because from the results of the current study, the caudate lobe received only 1 branch from the RPV for every 2 it got from the LPV. Furthermore, multiple branches to the caudate lobe are less likely to be given off the RPV relative to the LPV. Similarly, in close to half of the time (47%) the RPV did not give a branch to the caudate lobe further highlighting that

the right sided approach is a safer route to caudate lobectomy. This is unlike the LPV that failed to give a branch to the caudate lobe in only 15.2% of the cases.

CONCLUSION

From the results of the current study, a right sided approach for caudate lobectomy would be safer than a left sided approach due to the less portal venous branches that arise from the right portal vein.

REFERENCES

1. Sastha Ahanatha Pillai, Jeswanth Sathyanesan, et al. 2013. Isolated caudate lobe resection: technical challenges. *Annals of Gastroenterology* 26, 1-6
2. Ortale JR and Borges KLC. 2004. Anatomy of the portal branches and the hepatic veins in the caudate lobe of the liver. *Surg Radiol Anat.* 26(5): 384-391
3. Franceschini LJ and Ortale JR. 1995. Ramification of the portal vein at the porta hepatis in humans. *Surg. Radiol Anat.* 17(1): 35-39
4. Van MT, Galizia G, Lieto E. 1992. Anatomy of the caudate lobe of the liver: New aspects and surgical applications. *Ann Chir.* 46(4): 309-317.
5. Foucou B, Ould SH, Joyeux A, M'Jahed A, Saint-Aubert B, Hamdouch Z, Joyeux H, Solassol C. 1983. Segment 1 of the liver or Spigelian lobe. Anatomic study and surgical value. *J Chir (Paris).* 120(3): 179-186.
6. Yamane T, Mori K, Sakamoto K, Ikei S, Akagi M. 1988. Intrahepatic ramification of the portal vein in the right and caudate lobes of the liver. *Acta Anat (Basel)* 133(2): 162-163
7. Fan J, Wu ZQ, Tang ZY, Zhou J, Qiu SJ, Ma ZC, Zhou XD, Yu YQ. 2001. Complete resection of the caudate lobe of the liver with tumor: technique and experience. *Hepatogastroenterology.* 48(39): 808-811.
8. Eleazer C, Marcelo A, Francisco, William A, Ivan C. 2008. Caudate lobectomy: tumor location, topographic classification and technique using right- and left-sided approaches to the liver. *The American journal of Surgery.* 196: 245-251
9. Kuniya T, Hiroshi S, Michiyo Y, Tetsuya S, Michio U, Kenichi M, Yasuhiko N, Shinji T. clinical features and surgical outcomes of the hepatic caudate lobe metastases from colorectal cancer. *Anticancer research.* 26: 1447-1454.
10. Kimitaka K, Hiroyuki K, Noboru F, Masatoshi M. 2000. Relation among the portal segmentation, proper hepatic vein, and external notch of the caudate lobe in the human liver. *Annals of surgery.* 2:223-228
11. Sastha A, Jeswanth S, Senthilkumar P, et al,. 2013. Isolated caudate lobe resection: techniques and challenges. *Annals of gastroenterology.* 26: 1-6
12. Niu CX, Li CL, Yang Y. 2001. Applied anatomy of the hepatic caudate lobectomy. *Zhongguo Linchuang. Jiepouxue Zazhi.* 19: 151-154
13. Couinaud C. 1994. The paracaval segments of the liver. *Journal of Hepatic, Biliary and Pancreatic Surgery.* 2: 45-151
14. Janargin W, Blumgart LH. 2003. Caudate lobectomy. In: Poston G, Blumgart LH, editors. *Surgical Management of Hepatobiliary and Pancreatic Disorders.* London, England: Martin Dunitz. 29-39