

CASTRATION CAUSES PROGRESSIVE REDUCTION OF LENGTH OF THE RABBIT PENIS

Olabu B, Gichangi P, Saidi H, Ogeng'o J

Department of Human Anatomy, University of Nairobi

SUMMARY

Androgenic hormones are important in normal embryonic development and maintenance of the structural integrity of the penis. This structural integrity is vital in the physiology of penile erection. Its alteration may therefore lead to functional impairment resulting in erectile dysfunction as seen in hypogonadic conditions. The link between hypogonadism and erectile dysfunction is partly anatomical, involving alteration of normal structural elements of the penis such as smooth muscle cells, connective tissue fibers and vascular sinusoids. The penile length, although considered controversial issue, may also be influenced by such tissue alterations. Understanding of the alterations of the penile size in hypogonadism is important in clinical examination of hypogonadic patients. The aim of this study was to describe the changes in the rabbit penile length after castration. Fifteen adult male rabbits were used for the study. Nine of these were castrated under local anesthesia to induce hypogonadism and six remained as controls. The penile lengths were measured using a digital Vernier caliper (accuracy 0.5mm). There was progressive reduction in the average non-erect penile length by 0.7%, 3.4% and 8.7% in the castrated group at the end of the third, sixth and ninth week respectively. Castration causes progressive reduction in the non-erect penile length. Such length reduction may impair the normal penile physiology hence contribute to anatomical basis of erectile dysfunction in hypogonadism.

Key words:

INTRODUCTION

The penile length varies between different animals. Although there are no previously documented rabbit penile lengths, the average penile length in adult men is about 9.0-9.5 cm when flaccid, 14.5-15.0 cm when stretched in the flaccid state and 12.8-14.5cm when maximally erect (Dillon et al., 2008). Although there is no standard technique for measuring penile size, there appears to be consensus among researchers that penile length should be measured on the dorsum of the penis beginning from the pubopenile junction (base of the penis) to the glans' most

distant point (Wessells et al., 1996; Dillon et al., 2008). This measurement applies to the flaccid, stretched and erect states. Evaluation of penile size is a routine clinical procedure in the diagnosis and prognosis of patients who are candidates for reconstructive surgery of the penis (Chen et al., 2000).

Androgenic hormones are important in maintaining the structural integrity of the penis (Traish, 2009). Accordingly, decline in androgen levels is associated with erectile dysfunction (Gurbuz et al., 2008; Iacono et

al., 2012). The anatomical link between hypogonadism and erectile dysfunction include, among others, depletion of smooth muscle cells, deposition of connective tissue matrix, collapse of vascular spaces and accumulation of fat cells (Traish et al., 2005; Traish, 2009; Shafika et al., 2010; El-

Sakka and Yassin, 2010; Iacono et al., 2012). How these changes affect the non-erect penis however has not been described. This knowledge is important when clinical assessment of patients suffering from hypogonadism and are unable to achieve erection.

MATERIALS AND METHODS

This was a quasi-experimental study where gonadal hypogonadism was induced by bilateral orchiectomy. Fifteen adult male rabbits obtained from one rabbit farm were used for the study. Nine of these underwent orchiectomy under local anesthesia (intervention group) and six were not (non-intervention group).

The penile lengths were measured using a digital Vernier caliper (accuracy 0.5mm) from the palpable lower border of the pubic symphysis (pubopenile junction) to the tip of the glans penis (Wessells et al., 1996; Dillon et al., 2008). These measurements were taken for each animal at the

beginning, and every three weeks until the specific rabbit was perfused for light microscopy studies. The three weekly measurements were taken just before the perfusion. The values were recorded for each rabbit to study the trend. The mean lengths of each rabbit category was determined and compared to the mean lengths of other rabbit categories. The data was coded and analyzed by computer software, Statistical Package of Social Sciences (SPSS) version 17.0. The Student's t test was used for mean comparisons of the penile lengths. A p-value of less than 0.05 was considered statistically significant.

RESULTS

The mean non-erect penile length was 28.7 mm and 28.8mm for castrated and non-castrated groups respectively. These ranged between 27mm and 30mm. There was a statistically significant (p-value < 0.05) reduction in the average non-erect penile length by 0.7%, 3.4% and 8.7% in the

castrated group at the end of the third, sixth and ninth week respectively (Table 1 and Figure 1). The penile length in the non-castrated group remained fairly constant during the study period (Table 1 and Figure 1).

Table 1: Penile lengths in different rabbit categories in mm

Category/Timing		Start	3 weeks	6 weeks	9 weeks
Non-castrated (N) Group	N1	29.5	29.5	-	-
	N2	30.0	30.0	-	-
	N3	28.0	28.5	28.5	
	N4	28.5	28.0	28.5	
	N5	29.0	29.5	30.0	29.5
	N2	27.5	28.0	29.0	28.5
	Average	28.8	28.9	29.0	29.0
Castrated (C) Group	C1	28.5	28.0	-	-
	C2	30.0	29.5	-	-
	C3	29.0	28.5	-	-
	C4	28.5	28.5	28.0	-
	C5	29.0	28.5	27.5	-
	C6	27.0	27.0	26.5	-
	C7	28.0	28.0	27.5	26.0
	C8	29.5	29.5	28.5	26.5
	C9	28.5	29.0	28.0	26.0
	Average	28.7	28.5	27.7	26.2

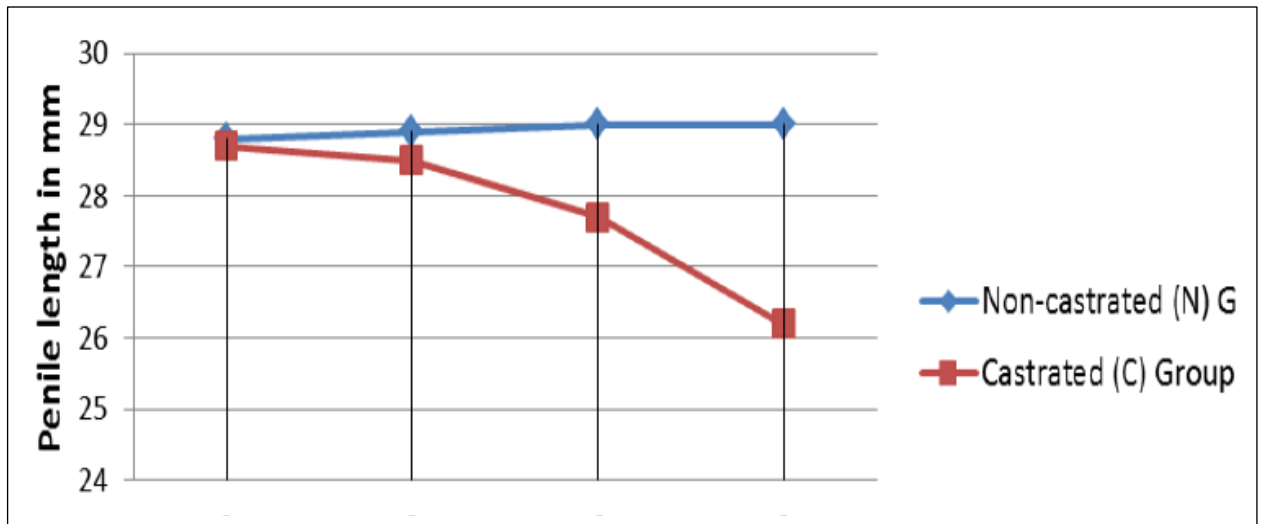


Figure 1: Comparisons of the penile length in Castrated and Non-castrated Rabbits over time

DISCUSSION

There are hardly any published reports of normal rabbit penile lengths. The present study has shown that bilateral orchietomy

causes a reduction in non-erect penile length. The reduction in penile length is proportional to the duration of hypogonadic

exposure. To the best of our knowledge, there are no published reports that have taken the penile length measurements of the non-erect rabbit penis. Previous studies focused mainly on the erect penile length (Haliloglu et al., 2007; McCullough, 2008; Park et al., 2011). Irrespective of the methodology however, all are concordant that the penile length reduces in hypogonadal states. This length reduction may be attributed to many factors such as penile erectile tissue fibrosis (Shafika et al., 2010; Iacono et al., 2012), reduction in trabecular smooth muscle density (McCullough, 2008; Shafika et al., 2010) and vascular collapse (El-Sakka and Yassin, 2010).

Concordant with current observations, subnormal penile sizes have also been reported in androgenic hormone deficiency occurring during embryonic development (Bin-Abbas et al., 1999). The occurrence of congenital micropenis has been shown to depend largely on a critical period of genital development called the "masculinization programming window (MPW)" when the level of androgenic activity is high (Welsh et al., 2008; Welsh et al., 2010). However, even though androgens are important

during this period in programming the penile size, a normal postnatal androgenic action is vital for the penis to achieve this size (Welsh et al., 2008; Macleod et al., 2010).

Current observation shows that penile size can be reduced even after normal development in the setting of gonadal androgen deficiency. Normal postnatal androgen levels are therefore vital in maintaining the normal penile size. Accordingly, subnormal penile sizes have been reported in humans suffering from androgen insensitivity (Hlaskova et al., 2009), in postprostatectomy patients (McCullough, 2008; Yu et al., 2010; Park et al., 2011; Vasconcelos et al., 2012) and patients undergoing radiotherapy (Haliloglu et al., 2007; Parekh et al., 2013). Although penile shortening has been documented, there is no reliable data to support or refute the overall effect of this on male sexuality.

In conclusion, Castration causes progressive penile length reduction due to gonadal androgen deficiency. This length reduction should be considered when analyzing patients with hypogonadism.

REFERENCES

1. Bin-Abbas B, Conte FA, Grumbach MM, Kaplan SL. 1999. Congenital hypogonadotropic hypogonadism and micropenis: effect of testosterone treatment on adult penile size why sex reversal is not indicated. *Journal of Pediatrics* 134: 579-583.
2. Chen J, Gefen A, Greenstein A, Matzkin H, Elad D. 2000. Predicting penile size during erection. *International Journal of Impotence Research* 12:328-333.
3. Dillon BE, Chama NB, Honig SC. 2008. Penile size and penile enlargement surgery: a review. *International Journal of Impotence Research* 20:519-529.
4. El-Sakka AI, Yassin AA. 2010. Amelioration of penile fibrosis: myth or reality. *Journal of Andrology* 31:324-335.
5. Gurbuz N, Mammadov E, Usta MF. 2008. Hypogonadism and erectile dysfunction: an overview. *Asian Journal of Andrology* 10: 36-43.

6. Haliloglu A, Baltaci S, Yaman O. 2007. Penile length changes in men treated with androgen suppression plus radiation therapy for local or locally advanced prostate cancer. *Journal of Urology*, 177:128-130.
7. Hlaskova A, Danilova L, Vashchula V, Orlov D, Mitukova T. 2009. Androgen insensitivity in the genesis of the mild penile size abnormalities in young Belarussian men. *Endocrine Abstracts* 20:676.
8. Iacono F, Prezioso D, Ruffo A, Illiano E, Romis L, Lauro GD, Romeo G, Amato B. 2012. Testosterone deficiency causes penile fibrosis and organic erectile dysfunction in aging men. Evaluating association among Age, TDS and ED. *Boston Medical Center Surgery* 12:S24.
9. Macleod DJ, Sharpe RM, Welsh M, Fiskin M, Scott HM, Hutchison GR, Drake AJ, Driesche S. 2010. Androgen action in the masculinization programming window and development of male reproductive organs. *International Journal of Andrology* 33:279-287.
10. McCullough A. 2008. Penile change following radical prostatectomy: size, smooth muscle atrophy, and curve. *Current Urology Reports* 9:492-499.
11. Parekh A, Chen MH, Hoffman KE, Choueiri TK, Hu JC, Bennett CL, Kattan MW, Sartor O, Stein K, Graham PL, D'Amico AV, Nguyen PL. 2013. Reduced penile size and treatment regret in men with recurrent prostate cancer after surgery, radiotherapy plus androgen deprivation, or radiotherapy alone. *Urology* 81:130-134.
12. Park KK, Lee SH, Chung BH. 2011. The effects of long term androgen deprivation therapy on penile length in patients with prostate cancer: a single-center, prospective, open-label, observational study. *Journal of Sexual Medicine* 8:3214-3219.
13. Shafika A, Sibaib O, Shafika A, Shafika I. 2010. Corpora cavernosa histological changes in testosterone deficiency. *Current Urology* 4:57-61.
14. Traish AM. 2009. Androgens play a pivotal role in maintaining penile tissue architecture and erection: a review. *Journal of Andrology* 30:363-369.
15. Traish AM, Toselli P, Jeong SJ, Kim NN. 2005. Adipocyte accumulation in penile corpus cavernosum of the orchietomized rabbit: a potential mechanism for veno-occlusive dysfunction in androgen deficiency. *Journal of Andrology* 26: 242-248.
16. Vasconcelos JS, Figueiredo RT, Nascimento FL, Damião R, da Silva EA. 2012. The natural history of penile length after radical prostatectomy: a long-term prospective study. *Urology* 80:1293-1296.
17. Welsh M, MacLeod DJ, Walker M, Smith LB, Sharpe RM. 2010. Critical androgen-sensitive periods of rat penis and clitoris development. *International Journal of Andrology* 33:144-152.
18. Welsh M, Saunders PT, Fiskin M, Scott HM, Hutchison GR, Smith LB, Sharpe RM. 2008. Identification in rats of a programming window for reproductive tract masculinization, disruption of which leads to hypospadias and cryptorchidism. *Journal of Clinical Investigation* 118:1479-1490.
19. Wessells H, Lue TF, McAninch JW. 1996. Penile length in the flaccid and erect states: Guidelines for penile augmentation. *Journal of Urology* 156:995-997.
20. Yu KWF, Degner LF, Hack TF, Schroeder G. 2010. Penile length shortening after radical prostatectomy: men's responses. *European Journal of Oncology Nursing* 14:160-165.